

UDC: 616.314.16-002-089.27

DOI: 10.2298/SGS1101029A

# Evaluation of Sealing Ability of Chemically Softened Gutta-Percha Technique

Radmila Arbutina<sup>1</sup>, Aleksandra Djeri<sup>1</sup>, Nataša Gajić<sup>1</sup>, Zorica Trnić<sup>1</sup>, Nataša Trtić<sup>2</sup>

<sup>1</sup>Clinic of Endodontics, Dental Department, University of Banja Luka, Banja Luka, Bosnia and Herzegovina;

<sup>2</sup>Clinic of Periodontology, Dental Department, University of Banja Luka, Banja Luka, Bosnia and Herzegovina

## SUMMARY

**Introduction** Obturation of the root canal is the final phase of endodontic therapy and it is usually used to assess the quality of endodontic treatment. The objective of this study was to examine the quality of apical sealing of the root canal after application of chemically softened gutta-percha.

**Material and Methods** Thirty extracted single rooted and multi rooted teeth, divided into two groups according to the material for obturation, were used in the study. After root canal instrumentation using step-back technique, obturation was completed using chemically softened gutta-percha and AH Plus and Apexit paste. The effect of apical sealing was assessed regarding the type of material used for the obturation. After obturation, teeth were coated with two coats of varnish and immersed in 50% solution of silver nitrate for twelve hours, and then longitudinally cut using diamond disc. Linear dye penetration was observed using light microscope and twenty five times magnification. The apical leakage was calculated using the measuring scale, previously mounted on microscope lens.

**Results** The results showed that the average penetration of silver nitrate in single rooted teeth obturated with the AH Plus paste was 132.8  $\mu\text{m}$ , while in teeth obturated with Apexit, it was 148.6  $\mu\text{m}$ . The difference was not statistically significant. Apical leakage in multi rooted teeth obturated with softened gutta-percha and AH Plus paste was 117.3  $\mu\text{m}$  while in teeth obturated with Apexit, it was 158.5  $\mu\text{m}$ . The difference was statistically significant.

**Conclusion** The lowest dye penetration in the apical portion of the canal was observed in multi rooted teeth obturated with AH Plus paste and the highest penetration of silver nitrate was in multi rooted teeth obturated with Apexit paste.

**Keywords:** apical obturation; chemically softened gutta-percha

## INTRODUCTION

After appropriate instrumentation and disinfection, root canal should be adequately obturated using appropriate material and technique. Despite the existence of numerous techniques and materials for root canal obturation, none of them meets all the requirements.

Recently, a great number of methods and techniques for root canal obturation has been developed: thermoplastic gutta-percha, injection method, chemically softened gutta-percha and core carrier method [1, 2]. Although lateral compaction technique is one of the most commonly used techniques for root canal obturation, gutta-percha is not always well adapted to the canal walls (especially in irregular canals). Thus, the application of thermoplastic gutta-percha is more appropriate in the root canal with several irregularities [3, 4].

There are numerous methods available for evaluation of the apical sealing quality in vitro; however, techniques with dye solutions (silver nitrate, methylene blue, basic fuchsine) are most commonly used. They are proven as very accurate in assessing the quality of the root canal apex sealing, whether used passively, in vacuum conditions or centrifugation [5, 6].

The objective of the study was to test the quality of apical sealing of root canals obturated with softened gutta-percha and two different pastes, AH Plus and Apexit.

## MATERIAL AND METHODS

The study was conducted on 30 extracted single rooted and multi rooted teeth obtained from persons of different gender and age. The teeth were divided into two groups. In one group AH Plus paste (Dentsply, USA) was used for final obturation, while in the other group the paste used for obturation was Apexit (Ivoclar Vivadent, Liechtenstein). The root canals were instrumented using step-back technique and copious irrigation with 2% NaOCl and 3% H<sub>2</sub>O<sub>2</sub>. The smear layer was removed using 15% EDTA for 1 minute. The final rinse was performed with saline; the root canals was dried and obturated.

All root canals were obturated using the paste and gutta-percha previously softened in chloroform. A softened gutta-percha technique is based on gutta-percha characteristic to become soft when dipped into chloroform, eucalyptol and other organic solvents. After drying the root canal, the main gutta-percha point was selected,

two to three sizes larger in the diameter than the final apical instrument, and 2-3 mm shorter to the working length. Using Lentulo spiral, the paste was administered on the walls in a thin layer. The main gutta-percha point was dipped in chloroform for about 5-10 seconds, placed into the canal and with stronger pressure pushed in the apical direction.

After the final obturation, the teeth were wrapped in wet cotton wool and kept in absolute humidity for 7 days. After this time, the roots were washed under running water, dried, and coated with two coats of varnish in the entire length of the root, except the area of 2 mm around the apex. The next step was to submerge the tips of the roots into the silver nitrate solution for 12 hours. After this procedure, the teeth were immersed passively in a photo developer for 2 hours. After the procedure completion, the teeth were washed with distilled water and dried. Varnish was mechanically removed. The teeth were then longitudinally cut using diamond disc (Disco Plan-TS) from the tip to the coronal part of the tooth, including the apical third. Linear dye penetration in the apical part was observed by detecting diffused color from the apical opening to the coronal part using the light microscope. Magnification was twenty-five times, and apical leakage was calculated using the measuring scale, previously mounted on the lens. All values were expressed in micrometers ( $\mu\text{m}$ ).

## RESULTS

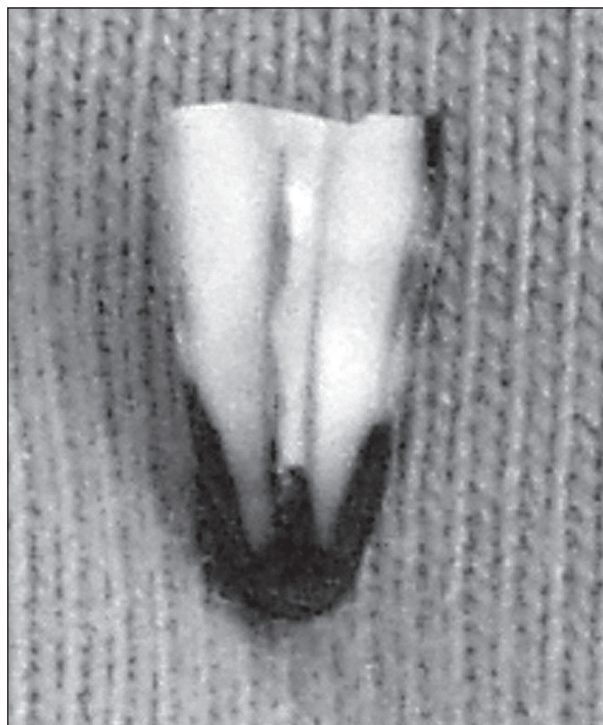
The results obtained from single rooted teeth showed slightly lower dye penetration in the apex of the teeth obturated with AH Plus (132.8  $\mu\text{m}$ ) compared to the teeth obturated with Apexit (148.6  $\mu\text{m}$ ). However, this difference was not statistically significant ( $p > 0.05$ ). The mean value of linear dye penetration in the apex of multi rooted teeth was also lower in the samples obturated with AH Plus (117.3  $\mu\text{m}$ ) than in the samples obturated with Apexit (158.5  $\mu\text{m}$ ). The difference was statistically significant ( $p < 0.05$ ).

Comparative analysis of the results in both groups of samples showed no statistically significant difference in dye penetration in single rooted teeth obturated with AH Plus or Apexit, but this difference was statistically significant in multi rooted teeth (Figures 1 and 2).

## DISCUSSION

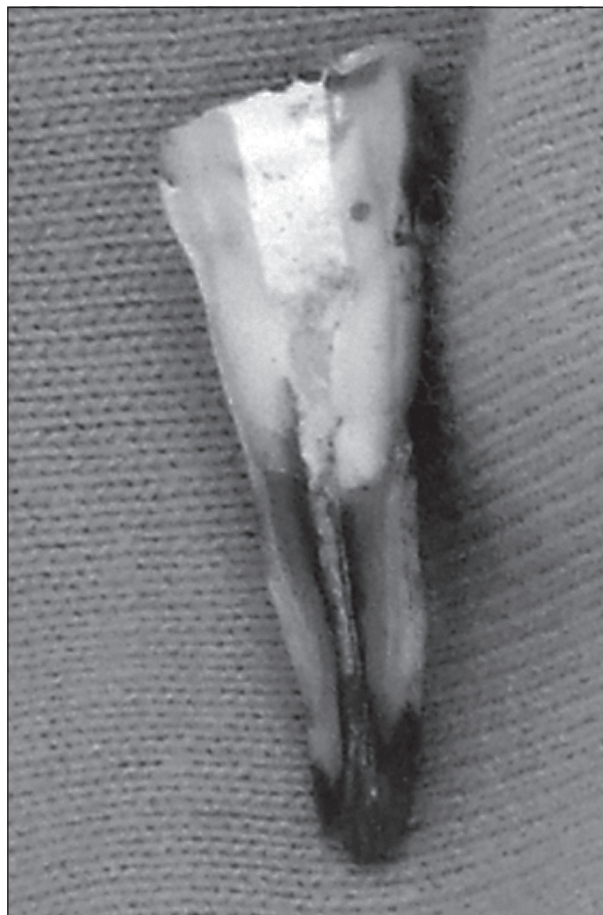A lot of methods have been used in order to assess the quality of apical sealing after root canal obturation in vitro. One of most commonly used methods is dye penetration providing good visualization and precise information about the quality of obturation. This method has its disadvantages (small molecules in solution), but it can be considered as valid if the experimental conditions are standardized, and paste in the root canal has the thickness as small as possible [7].

A method of root canal obturation by chemically softened gutta-percha with two different pastes AH Plus and Apexit was assessed in the study. This technique is based



**Figure 1.** Dye penetration in teeth obturated using AH Plus and gutta-percha softened in chloroform

**Slika 1.** Linearni prodor boje kod zuba opturisanog pastom AH Plus i gutaperkom razmekšanom u hloroformu



**Figure 2.** Dye penetration in teeth obturated using Apexit and gutta-percha softened in chloroform

**Slika 2.** Linearni prodor boje kod zuba opturisanog pastom Apexit i gutaperkom razmekšanom u hloroformu

on an important feature of gutta-percha that it becomes soft when dipped in chloroform, eucalyptol and other organic solvents. When used as softened, gutta-percha provides three-dimensional obturation of the root canal. For this technique, a root canal should be instrumented to have a continuous conical preparation or preparation with the apical matrix. The main gutta-percha point should be two or three sizes larger in diameter than the final apical instrument. After the application of paste on the walls of the root canal, gutta-percha, previously softened in chloroform is applied in the root canal and pushed toward the apex.

Apexit contains calcium hydroxide, and often is used as material for final obturation. However, in addition to inadequate apical sealing and apical microleakage, materials based on calcium-hydroxide have low adhesiveness, dimensionally are not stable, and show sensitivity to moisture [8], eventually being dissolved in the root canal. By this fact, a great number of researchers explained poor sealing ability of Apexit [9, 10, 11], as also confirmed in the current study where Apexit showed greater apical leakage than AH Plus. The main problem of the pastes based on calcium hydroxide is that they are absorbed after some time, leaving empty space in the apex [11].

The results of various studies found greater apical leakage in single rooted as well as in multi rooted teeth when Apexit was used as compared to AH Plus. The reason is the instability of the preparations based on calcium hydroxide, which are unbalanced and highly soluble. AH Plus paste has a good adhesion and makes a good connection between canal walls and gutta-percha points. Moreover, AH Plus possesses a distinct fluidity and act as lubricant, which helps it to achieve „stickiness” on dentin walls [12, 13].

Maden et al. [14] compared the method of lateral gutta-percha compaction, obturation using laser and softened gutta-percha technique and got similar results as the current study. They believe that apical leakage in lateral gutta-percha compaction technique is lower than in soft gutta-percha technique. According to their research, gutta-percha contraction contributes to increased apical permeability.

Beer and Gangler suggest that quality parameter of hermetic obturation when gutta-percha compaction method is tested should be related to the percentage of gutta-percha mass relatively to the surface of the entire canal [15]. Because of great expansion and contraction of gutta-percha, often is recommended to warm and soften gutta-percha, however, changes in volume after cooling can lead to micro cracks.

Torabinejad et al. examined the quality of obturation using lateral gutta-percha compaction technique, warm vertical compaction and gutta-percha softened in chloroform. On longitudinal sections the adaptation of filling to the surrounding walls was examined. Empty micro spaces were noted in lateral and warm vertical compaction technique. Obturation quality in the apical third of the canal was similar in both tested techniques while in the middle part of the root canal, vertical compaction showed better results [15, 16].

Pommel et al. [17] found that the assessment of obturation using cold, warm or soften gutta-percha, depends on used technique, dye penetration, fluid filtration or electrochemical method. However, it was noticed that contraction of warm and softened gutta-percha affects the quality of obturation, as confirmed in single rooted and multi rooted teeth by using soften gutta-percha technique.

Thermoplastic techniques are more sensitive to work conditions than techniques that use cold gutta-percha [18, 19, 20]. If thermoplasticised material is quickly and deeply injected, sealing ability is good, but the canals are often overfilled. If gutta-percha is injected slowly and not enough deep, obturation fails [21]. Thus, different speed and/or different cooling can affect the results of sealing quality by thermoplastic gutta-percha [3, 22].

Scanning-electron microscopy analysis of the soften gutta-percha and lateral compaction technique showed better adaptation of the filling in soften gutta-percha method as compared to lateral compaction [23].

## CONCLUSION

Based on these results it can be concluded that the lowest dye penetration in the apical part of root canals obturated with chemically softened gutta-percha was in multi rooted teeth using AH Plus paste, while the greatest dye penetration occurred in multi rooted teeth when Apexit paste was used.

## REFERENCES

1. Yee FS, Marlin J, Krakow AA, Gron P. Three-dimensional obturation of the root canal injection-molded, thermoplasticized dental gutta-percha. *J Endod.* 1977; 3:168-74.
2. Johnson WB. A new gutta-percha technique. *J Endod.* 1978; 4:184-8.
3. McSpadden J. Multiphase gutta-percha obturation technique. *Dent Econ.* 1993; 83:95, 97.
4. Smith RS, Weller RN, Loushine RJ, Kimbrough WF. Effect of varying the depth of heat application on the adaptability of gutta-percha during warm vertical compaction. *J Endod.* 2000; 26:668-72.
5. Tagger M, Tamse A, Katz A, Tagger E. An improved method of three-dimensional study of apical leakage. *Quintessence Int Dent Dig.* 1983; 14:981-98.
6. Živković S, Mijušković D. Endodontska terapija hroničnih apeksnih parodontita. Beograd: Danubius-Dental; 2003.
7. Ingle JJ, Newton CW, West JD, Gutmann JL, Glickman GN, Korzon BH, et al. Obturation of the radicular space. In: Ingle JJ, Bakland LK. *Endodontics.* 5th ed. London: BC Decker Inc.; 2002. p.599-615.
8. Tronstad L. Klinička endodoncija. Beograd: Data status; 2005.
9. Wu MK, Wesselink PR. Endodontic leakage studies reconsidered. Part I. Methodology, application and relevance. *Int Endod J.* 1993; 26:37-43.
10. Lussi A, Imwinkelried S, Stich H. Obturation of root canals with different sealers using non-instrumentation technology. *Int Endod J.* 1999; 32:17-23.
11. Hovland EJ, Dumsha TC. Leakage evaluation in vitro of the root canal sealer cement Sealapex. *Int Endod J.* 1985; 18:179-82.
12. Yang SE, Bae KS. Scanning electron microscopy study of the adhesion of *Prevotella nigrescens* to the dentin of prepared root canals. *J Endod.* 2002; 28:433-7.
13. Miletić I, Ribarić SP, Karlović Z, Jukić S, Bošnjak A, Anić I. Apical leakage of five root canal sealers after one year of storage. *J Endod.* 2002; 28: 431-2.

14. Maden M, Görgül G, Tinaz AC. Evaluation of apical leakage of root canals obturated with Nd: YAG laser-softened gutta-percha, System-B, and lateral condensation techniques. *J Contemp Dent Pract.* 2002; 3:16-26.
15. Medojević-Jovanović M. Anatomomorfološka istraživanja apeksne trećine korena prvog donjeg molara [magistarski rad]. Beograd: Stomatološki fakultet Univerziteta u Beogradu; 2004.
16. Willershhausen B, Marroquín BB, Schäfer D, Schulze R. Cytotoxicity of root canal filling materials to three different human cell lines. *J Endod.* 2000; 26:703-7.
17. Pommel L, Jacquot B, Camps J. Lack of correlation among three methods for evaluation of apical leakage. *J Endod* 2001; 27:347-50.
18. Shipper G, Teixeira FB, Arnold RR, Trope M. Periapical inflammation after coronal microbial inoculation of dog roots filled with gutta-percha or resilon. *J Endod.* 2005; 31:91-6.
19. Lea CS, Apicella MJ, Mines P, Yancich PP, Parker MH. Comparison of the obturation density of cold lateral compaction versus warm vertical compaction using the continuous wave of condensation technique. *J Endod.* 2005; 31:37-9.
20. Kytridou V, Gutmann JL, Nunn MH. Adaptation and sealability of two contemporary obturation techniques in the absence of the dentinal smear layer. *Int Endod J.* 1999; 32:464-74.
21. Levitan ME, Himmel VT, Luckey JB. The effect of insertion rates on fill length and adaptation of a thermoplasticized gutta-percha technique. *J Endod.* 2003; 29:505-8.
22. Gutmann JL. Adaptation of injected thermoplasticized gutta-percha in the absence of the dentinal smear layer. *Int Endod J.* 1993; 26:87-92.
23. Gençoğlu N, Samani S, Günday M. Dentinal wall adaptation of thermoplasticized gutta-percha in the absence or presence of smear layer: a scanning electron microscopic study. *J Endod* 1993; 19:558-62.

---

Received: 01/09/2010 • Accepted: 31/01/2011

# Ispitivanje kvaliteta apeksnog zaptivanja kanala korena zuba nakon primene hemijski razmekšane gutaperke

Radmila Arbutina<sup>1</sup>, Aleksandra Đeri<sup>1</sup>, Nataša Gajić<sup>1</sup>, Zorica Trnić<sup>1</sup>, Nataša Trtić<sup>2</sup>

<sup>1</sup>Klinika za bolesti zuba, Stomatološki odsek, Univerzitet u Banja Luci, Banja Luka, Bosna i Hercegovina;

<sup>2</sup>Klinika za parodontologiju, Stomatološki odsek, Univerzitet u Banja Luci, Banja Luka, Bosna i Hercegovina

## KRATAK SADRŽAJ

**Uvod** Opturacija kanala korena zuba je završna faza endodontske intervencije, prema kojoj se najčešće procenjuje kvalitet endodontskog lečenja. Cilj ovog rada je bio da se proverí kvalitet apeksne opturacije kanala korena zuba nakon primene hemijski razmekšane gutaperke.

**Materijal i metode rada** U ispitivanju je korišćeno 30 ekstrahovanih jednokorenihi i višekorenihi zuba, svrstanihi u dve grupe prema materijalu primenjenom za opturaciju. Nakon preparacije svih kanala tehnikom *step-back*, opturacija je urađena metodom hemijski razmekšane gutaperke i primenom pasti AH plus i Apexit. Efekat apeksnog zaptivanja proveravan je u funkciji vrste materijala za opturaciju. Zubi su nakon opturacije premazani sa dva sloja laka i potopljeni u pedesetoprocenitni rastvor srebro-nitrata tokom dvanaest sati, a potom uzdužno presečeni dijamantskim diskom. Očitavanje linearnog prodora boje vršeno je svetlosnim mikroskopom pri uvećanju od 25 puta, a apeksna propustljivost je izračunata pomoću merne skale koja je prethodno montirana na objektiv mikroskopa.

**Rezultati** Srednja vrednost prosečnog prodora boje rastvora srebro-nitrata kod jednokorenihi zuba punjenih pastom AH plus bila je 132,8 µm, a kod zuba punjenih pastom Apexit 148,6 µm. Razlika nije bila statistički značajna. Kod višekorenihi zuba opturiranihi hemijski razmekšanom gutaperkom i pastom AH plus prosečan linearni prodor boje bio je 117,3 µm, a kod zuba punjenih pastom Apexit 158,5 µm. Ova razlika bila je statistički značajna.

**Zaključak** Najmanji linearni prodor boje u apeksnom delu kanala uočen je kod višekorenihi zuba opturiranihi pastom AH plus, a najveći kod višekorenihi zuba ispunjenih pastom Apexit.

**Cljučne reči:** apeksna opturacija; hemijski razmekšana gutaperka

## UVOD

Nakon uobičajene instrumentacije i dezinfekcije, kanal korena zuba je potrebno ispuniti odgovarajućim materijalom. I pored postojanja brojnih tehnika za opturaciju kanala korena zuba, nijedna od njih ne ispunjava zahteve ovako složene intervencije.

Poslednjih godina razvijeno je mnogo metoda i tehnika s termoplastičnom gutaperkom, uključujući i metodu ubrizgavanja, tehniku opturacije s hemijski razmekšanom gutaperkom, odnosno metodu sa gutaperkom na nosaču [1, 2]. Iako je tehnika lateralne kompakcije jedna od najčešće korišćenih za punjenje kanala korena zuba, gutaperka se ovde ne adaptira dobro na zidove kanala (posebno kod nepravilnih kanala), pa je primena termoplastične gutaperke pogodnija, naročito ako postoje nepravilnosti u kanalnom sistemu zuba [3, 4].

Postoje razne metode za proveru kvaliteta apeksnog zaptivanja u studijama *in vitro*, ali se ipak najčešće koriste tehnike sa bojenim rastvorima (srebro-nitrat, metilen-plavilo, bazni fuksin). One su se pokazale vrlo preciznim u proceni kvaliteta zaptivanja apeksa kanala korena zuba, bilo da su primenjene pasivno, u uslovima vakuuma, ili centrifugiranjem [5, 6].

Cilj ovog rada je bio da se proverí kvalitet apeksnog zaptivanja kanala korena zuba tehnikom hemijski razmekšane gutaperke i primenom dve različite paste, AH plus i Apexit.

## MATERIJAL I METODE RADA

Ispitivanje je vršeno na 30 ekstrahovanihi jednokorenihi i višekorenihi zuba osoba različitoi polai i starosti. Zubi su svrstani u dve grupe, gde je u prvoj kao materijal za konačnu opturaciju zuba korišćena pasta AH plus (*Dentsply, USA*), a u drugoi pasta Apexit (*Ivoclar Vivadent, Liechtenstein*). Kanali su obrađivani

tehnikom *step-back*, uz obilnu irigaciju dvoprocentnim NaOCl i tropercentnim H<sub>2</sub>O<sub>2</sub>, i uklanjanjem razmaznog sloja petnaestoprocenitnim rastvorom EDTA u trajanju od jednog minuta. Ispiranje je završeno fiziološkim rastvorom, a potom je kanal osušen i konačno opturisan.

Kod svih kanala konačna opturacija je urađena pastom i gutaperka-kočićem koji je prethodno razmekšan u hloroformu. Tehnika razmekšavanja gutaperke umakanjem zasnovana je na osobini gutaperke da postaje mekša kada dođe u dodir sa hloroformom, eukaliptolom i drugim organskim rastvaračima. Posle sušenja kanala korena odabran je glavni gutaperka-poeti koji je od dve do tri veličine većeg prečnika nego završni apeksni instrument i 2-3 mm kraći od radne dužine. Potom je pomoću lentulo spirale nanosena pasta na zidove kanala korena u tankom sloju. Glavni gutaperka-poeti je prvo umočen u hloroform 5-10 sekundi, a potom u kanal, gde je jačim pritiskom potiskivan u apeksnom smeru.

Posle konačne opturacije zubi su ostavljeni u bočice u uslovima apsolutne vlažnosti, umotani u vlažnu vatu, tokom sedam dana. Po isteku ovog perioda, površine korenova su isprane pod mlazom vode i osušene, a potom premazane lakom u dva sloja celom dužinom korena, osim površine od 2 mm oko apeksnog dela korena. U sledećoi fazi vrhovi korenova su potopljeni u rastvor srebro-nitrata u trajanju od 12 sati. Nakon ove procedure zubi su pasivno potapani u fotorazvijlač, gde su držani dva sata. Posle kompletne procedure bojenja i potapanja, isprani su destilovanom vodom, zatim posušeni, a nakon toga se pristupilo mehaničkom uklanjanju laka. Posle uklanjanja laka zubi su uzdužno presečeni dijamantskim diskom (*Disco Plan-TS*) od vrha korena, obuhvatajući apeksnu trećinu. Očitavanje linearnog prodora boje u apeksnom delu vršeno je na osnovu uočene difundovane boje od apeksnog otvora prema koronarnom delu pomoću svetlosnog mikroskopa pri uvećanju od 25

puta. Apeksna propustljivost je izračunata pomoću merne skale koja je prethodno montirana na objektiv. Sve dobijene vrednosti predstavljene su u mikrometrima ( $\mu\text{m}$ ).

## REZULTATI

U uzorku jednokorenih zuba uočen je nešto manji linearni prodor boje u apeksu zuba opturiranih pastom AH plus (132,8  $\mu\text{m}$ ) u odnosu na zube opturirane pastom Apexit (148,6  $\mu\text{m}$ ). Razlika nije bila statistički značajna ( $p > 0,05$ ). Srednja vrednost linearnog prodora boje u apeksu kod višekorenih zuba takođe je bila manja kod uzoraka opturiranih pastom AH plus (117,3  $\mu\text{m}$ ), nego kod zuba punjenih pastom Apexit (158,5  $\mu\text{m}$ ). Ova razlika bila je statistički značajna ( $p < 0,05$ ).

Uopredna analiza dobijenih rezultata kod obe grupe uzoraka pokazala je da ne postoji statistički značajna razlika u linearnom prodoru boje između pasti AH plus i Apexit kod jednokorenih zuba, ali da je ova razlika statistički značajna kod višekorenih zuba (Slike 1 i 2).

## DISKUSIJA

Za procenu kvaliteta apeksnog zaptivanja kanala korena nakon opturacije zuba u uslovima *in vitro* primenjuju se mnoge metode. Jedna od najčešće korištenih je metoda bojenog rastvora, koja obezbeđuje dobru vizuelizaciju i daje precizne podatke o kvalitetu opturacije. Ova metoda, međutim, ima i nedostatke (mali molekuli rastvora), ali se može smatrati dovoljno validnom ukoliko su eksperimentalni uslovi standardizovani, a debljina paste u kanalu što manja [7].

U ovom istraživanju analizirana je metoda hemijski razmekšane gutaperke u hloroformu primenom dve paste – AH plus i Apexit. Ova tehnika je zasnovana na važnoj osobini da gutaperka postaje mekša kada se potopi u hloroform, eukaliptol i druge organske rastvarače. Kada se omekša i ubaci u kanal, ona obezbeđuje trodimenzionalnu opturaciju kanala korena zuba. Za ovu tehniku kanal treba pripremiti tako da ima neprekidnu konusnu preparaciju ili preparaciju s apeksnom matricom. Glavni gutaperka-poen treba da je dve-tri veličine veći u prečniku nego završni apeksni instrument. Nakon nanošenja paste na zidove kanala unosi se gutaperka koja je prethodno razmekšana u hloroformu i potom nabijačima potiskuje prema apeksu.

Apeksit je preparat kalcijum-hidroksida i često se upotrebljava kao materijal za konačnu opturaciju zuba. Međutim, pored neodgovarajućeg apeksnog zaptivanja i velike apeksne propustljivosti, ovi materijali imaju slabu adhezivnost, dimenzionalno su nestabilni, veoma su osetljivi na vlagu i vremenom se rastvaraju u kanalnom sistemu [8]. Veliki broj istraživača ovim činjenicama objašnjava slabu zaptivnu moć paste Apexit [9, 10, 11], što se potvrdilo i u ovom istraživanju, gde je Apexit pokazao veću apeksnu propustljivost u odnosu na pastu AH plus. Osnovni problem pasti na bazi kalcijum-hidroksida jeste to što se nakon nekog vremena resorbuju i ostavljaju slobodan prostor u apeksu [11].

Rezultati našeg istraživanja su pokazali veću apeksnu propustljivost i kod jednokorenih i kod višekorenih zuba paste Apexit nego AH plus. Razlog za to je što su preparati kalcijum-hidroksida dimenzionalno nestabilni i rastvorljivi. Pasta AH plus

poseduje dobru adhezivnost i ostvaruje dobru vezu između zidova kanala i gutaperka-poena. Takođe, ona ima osobine izrazite fluidnosti i lubrikantnosti, kojima se postiže efekat „lepljivosti“ za zidove kanala korena zuba [12, 13].

Maden (*Maden*) i saradnici [14] su u svom istraživanju upoređivali tehniku lateralne kompakcije, opturaciju laserom i tehniku razmekšane gutaperke, i dobili slične rezultate kao u ovom istraživanju. Oni smatraju da je apeksno curenje u uzorku zuba kod kojih je primenjena tehnika lateralne kompakcije manje u odnosu na zube kod kojih je korišćena razmekšana gutaperka. Kontrakcija gutaperke je, prema njihovim zapažanjima, doprinela povećanoj apeksnoj propustljivosti.

Ber (*Beer*) i Gangler (*Gangler*) smatraju da kod ispitivanja kompacionih metoda opturacije parametar kvaliteta hermetičnosti treba tražiti u procentualnoj zastupljenosti gutaperka mase u odnosu na površinu celokupnog ispunjenog kanala [15]. Zbog izrazite ekspanzije i kontrakcije gutaperke, često se preporučuju zagrevanje i razmekšavanje gutaperke, jer promena volumena materijala nakon hlađenja može dovesti do pojave mikropukotine.

Torabinedžad (*Torabinejad*) i saradnici su ispitivali kvalitet opturacije kanala lateralnom kompakcijom, vertikalnom vrućom i hloroperka tehnikom na uzdužnim preseccima. Posmatrana je adaptacija ispuna prema okolnim zidovima. Primećeni su česti slobodni mikroprostori u kanalu korena ispunjenih vertikalnom i lateralnom kompacionom tehnikom. Ispuni dobijeni lateralnom i vertikalnom kompakcijom gutaperke su po kvalitetu bili u apeksnoj trećini slični, dok se u srednjoj trećini vertikalna kompakcija pokazala kvalitetnijom [15, 16].

Pomel (*Pommel*) i saradnici [17] su otkrili da punjenje hladnom, toplom ili termoplastičnom gutaperkom drugačije zaptiva, u zavisnosti od toga da li se primenjuje metoda penetracije boje, metoda filtracije tečnosti ili elektrohemijaska metoda. Međutim, uočeno je da se zagrejana i razmekšana gutaperka skuplja, što utiče na kvalitet opturacije kanala, što je potvrđeno i kod jednokorenih i kod višekorenih zuba nakon primene tehnike hemijski razmekšane gutaperke.

Termoplastične tehnike su osetljivije pri radu u odnosu na tehnike gde se primenjuje nezagrejana gutaperka [18, 19, 20]. Ukoliko se termoplastični materijal ubrizga brzo i duboko, sposobnost zaptivanja je dobra, ali kanali su često prepunjeni; ako se materijal ubrizga srazmerno sporo i nedovoljno duboko, ispun kanala korena zuba propušta [21]. To upozorava na činjenicu da različita brzina, odnosno drugačije hlađenje mogu uticati na različite rezultate kvaliteta zaptivanja termoplastične gutaperke [3, 22].

Skening-elektronskom mikroskopijom je analizirana tehnika razmekšane gutaperke i tehnika lateralne kompakcije, pri čemu je uočena bolja adaptacija punjena kod tehnike razmekšane gutaperke [23].

## ZAKLJUČAK

Na osnovu rezultata istraživanja može se zaključiti da je najmanji linearni prodor boje u apeksnom delu kanala korena zuba opturiranih tehnikom hemijski razmekšane gutaperke bio kod višekorenih zuba kod kojih je primenjena pasta AH plus, dok je najveći linearni prodor boje uočeno kod višekorenih zuba za čije zaptivanje je korišćena pasta Apexit.