



Eosinophilia as a first sign of Hodgkin's lymphoma – A case report

Eozinofilija kao prvi znak Hodžkinove bolesti

Rajko Milošević*, Danijela Leković*†, Nebojša Antonijević*‡,
Andrija Bogdanović*†

Clinical Center of Serbia, *Clinic for Hematology, ‡Emergency Center, Clinic for
Cardiology, Belgrade, Serbia; University of Belgrade, †Faculty of Medicine, Belgrade, Serbia

Abstract

Introduction. It is well known that eosinophilia appears in a malignant disease. Frequency of all Hodgkin's lymphoma patients is estimated to about 15%. Prognostic importance of this phenomenon is not completely investigated. Therefore we decided to present a female patient with eosinophilia, six months before lymphoma appearance. **Case report.** We presented a 51-years old female, from Serbia, who had eosinophilia (1,530–2,040 eosinophils *per* μ L of blood), six months before Hodgkin's lymphoma appearance. Eosinophilic granuloma was confirmed by tumor's biopsy and histopathologic examination, from the right femoral region. As eosinophilia was increasing, lymph nodes became enlarged (120 \times 65 mm diameter), in the right parailiac region. All infectious and allergic examinations did not reveal eosinophilia's cause. Histopathologic revision was made with added immunohistochemical stains 17 months after tumor's biopsy. The diagnosis was changed from eosinophilic granuloma to mixed cellularity Hodgkin's lymphoma. After conducted Ann Arbor staging classification, II B clinical stage was established. The treatment was done by chemotherapy according to adriamycin, bleomycin, vinblastine, dacarbazine (ABVD) protocol, with 6 courses. Complete remission of the disease was achieved after 4 courses. Eosinophils number dropped to 640 *per* μ L blood. **Conclusion.** Eosinophilia without revealed cause can precede Hodgkin's lymphoma. We suggest careful search for enlarged lymph nodes, anywhere in the patients' body who suffer from eosinophilia. Timely and accurate histopathologic diagnostic is a right way to resolve such conditions.

Key words:
eosinophilia; hodgkin disease; signs and symptoms;
diagnosis; abvd protocol; treatment outcome.

Apstrakt

Uvod. Dobro je poznato da se eozinofilija može javiti u okviru malignih bolesti. Učestalost je procenjena na oko 15% svih obolelih od Hodžkinovog limfoma. Prognostički značaj ovog fenomena nije u potpunosti razjašnjen. Smatrali smo korisnim da prikazemo bolesnicu sa eozinofilijom koja se javila nekoliko meseci pre pojave Hodžkinovog limfoma. **Prikaz bolesnice.** Prikazana je bolesnica, stara 51 godinu, iz Srbije, koja je 6 meseci pre pojave Hodžkinovog limfoma imala eozinofiliju (1 530–2 040 eozinofila u μ L krvi). Biopsijom i histopatološkim pregledom tumorske promene na desnoj butini postavljena je inicijalna dijagnoza eozinofilnog granuloma. Kako je eozinofilija rasla, došlo je do pojave uvećanih limfnih čvorova, promera 120 \times 65 mm u parailiačnom prostoru, desno. Sva infektološka i alergološka ispitivanja nisu ukazala na uzrok eozinofilije. Posle 17 meseci učinjena je revizija histopatološkog nalaza biopsije tumora uz dodatna imunohistoheksijska ispitivanja. Dijagnoza je promenjena od eozinofilnog granuloma u Hodžkinov limfom, tipa mešovite celularnosti. Posle sprovedene Ann Arbor "stejdžing" procedure zaključeno je da se radi o II B kliničkom stadijumu Hodžkinovog limfoma. Lečenje je sprovedeno hemioterapijom po protokolu adriamicin, bleomicin, vinblastin, dekarbazin (ABVD) sa 6 ciklusa. Uspostavljena je kompletna remisija bolesti već posle 4 ciklusa. Broj eozinofila se sveo na 640/ μ L krvi. **Zaključak.** U retkim slučajevima, eozinofilija bez otkrivenog uzroka, može prethoditi Hodžkinovom limfomu. Kod takvih bolesnika trebalo bi pažljivo ispitati moguće prisustvo uvećanih žlezda bilo gde u organizmu. Pravovremena i tačna histopatološka dijagnostika se pokazala kao pravi put u rešavanju ovakvih stanja.

Ključne reči:
eozinofilija; hodžkinova bolest; znaci i simptomi;
dijagnoza; abvd protokol; lečenje, ishod.

Introduction

Eosinophilia becomes a diagnostic challenge for hematologists. It is defined as the presence of > 500 eosinophils per μ L of blood are eosinophilic leukocytes¹. Precise characterization of eosinophilia is very important because

successful treatment relies on the underlying disease aetiology². Currently, eosinophilia can be divided into three types: secondary, clonal and idiopathic. Secondary (reactive) eosinophilia is a consequence of a cytokine-induced phenomenon that most often results from an upsurge in interleukin-5 secretion, leading to the proliferation of eosinophils and

their precursors³. The main causes include parasitic infections, allergic conditions or vasculitis, drug reactions and non-myeloid malignancies. It is well known that reactive eosinophilia appears in lymphoid malignancies. Its frequency is estimated to be about 15% of all Hodgkin's lymphoma (HL) patients⁴. Reactive eosinophilia is based on treating the underlying condition.

We here presented a diagnostic challenge in a female patient with persistent eosinophilia just six months before lymphoma appearance.

Case report

A female patient aged 51, from Serbia had leukocytosis of 12,000/ μ L of blood, with eosinophilia 17% (2,040/ μ l in absolute number) first time recorded in May 2012. She also had pain and swellings in hand joints, spine and hips. The first visit was at general practitioner in Kovačica city.

General symptoms were not present besides periodic malaise. A rheumatologist prescribed prednisone 5 mg daily, orally, mostly because of the left forearm swelling. The treatment lasted 10 days.

In November 2012, for the first time, a wen appeared in the right femoral region, upper third of thighs. Therefore, further investigation and treatment were continued in Pančevo General Hospital.

The first ultrasound examination showed the soft tissues tumor, hypoechoogenic, not homogenous, 60 \times 35 mm in size, in the frontal region of right thighs. Enlarged lymph nodes were not seen in the right hurdle and in abdomen, too. The finding was from November 20, 2012.

Computed tomography (CT) examination confirmed a limited tumour, pseudobulobated, expansive, 50 \times 80 \times 100 mm in size, without infiltrative features. The normal finding was shown on other organs, without enlarged lymph nodes in abdomen.

The surgical removal and histopathologic examination were indicated.

During the preoperative preparation, leukocytosis (16,5/ μ L of blood), with eosinophilia of 23% (absolute number 8,745/ μ L) were registered. Middle thrombocytopenia degree, with 82,000 of platelets *per* μ L of blood, was found, as well.

Routine biochemical analyses were within normal range.

Tumor was surgically removed. Histopathological result showed eosinophilic granuloma.

Thereafter, gynecologic examination was performed showing normal finding. The breast and armpits ultrasound examination revealed cystic formations in glandular tissue. Lymph nodes were not enlarged.

The patient was sent to detailed bronchological and infectological examinations for persistent eosinophilia.

Chest roentgenogram and spirometry showed normal results. Oxygen saturation was 98%, partial oxygen pressure was 10,7 kPa. Skin allergic tests and methacholine test were negative. Stool tests for parasites and helminth eggs were negative for three times. Bronchial asthma and hypereosinophilic syndrome were excluded. Besides a haematologist and other specialist's efforts from Pančevo General Hospital, clear cause of eosinophilia

was not found and the patient was sent to the Clinic for Haematology of the Clinical Centre of Serbia, Belgrade, for further examinations.

We saw the patient for the first time on March 23, 2014 and she complained of itchy skin. Physical finding was without signs of anaemia, hemorrhagic syndrome and enlarged lymph nodes in typical sites (neck, armpits and groin).

Blood parameters were: hemoglobin (HB) 140 g/L, hematocrit (HT) 0.40, mean corpuscular volume (MCV) 93 fL, platelet count (PLT) 137×10^9 /L, white blood count (WBC) 20.4×10^9 /L, with 54% (11,016/ μ L) absolute eosinophils number, segmented neutrophils 24.7%, lymphocytes 17.3 % and monocytes 4.0 %.

Myelogram analysis from March 25, 2014 showed reactive, normal bone marrow, with slight eosinophilia in hypocellular specimen (Figure 1).

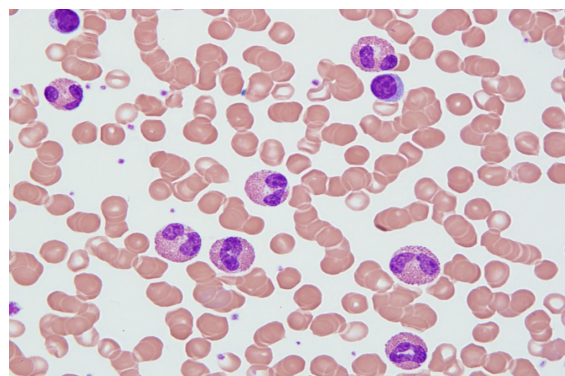


Fig. 1 – Blood eosinophilia.

Another ultrasound of abdomen was undertaken. Normal finding on parenchymal organs was found again, but for the first time, enlarged lymph nodes in conglomerate, size 70 mm, were found. They were right sided in the parailiac region.

On May 7, 2014 CT examination was also performed. It revealed conglomerate of enlarged lymphnodes, now 120 \times 65 mm in size, in the parailiac right region, imprinting right bladder contour (Figure 2). Enlarged lymph nodes were found too in left-sided inguinal region, 15 mm in diameter.

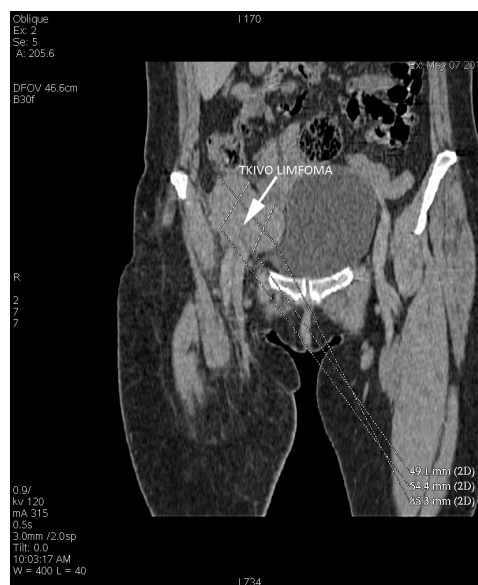

Fig. 2 – Lymph nodes conglomerate (parailiac right region).

It was necessary to perform revision of patient's whole condition. The patient was hospitalized at the Clinic for Allergology and Immunology, Clinical Centre of Serbia, Belgrade, Serbia, from June 12 to July 7, 2014 when some of diagnostic procedures were repeated and extended.

Biochemical analysis in the serum showed: glucose level 4,19 mmol/L, urea 5,4 mmol/L, creatinine 67 μ mol/L, cholesterol 5,16 mmol/L, triglycerides 1,12 mmol/L, C reactive protein (CRP) 4,14 mg/mL, fibrinogen 4,22 g/L, bilirubin 98,9 μ mol/L, total proteins 75 g/L, aspartate-aminotransferase (AST) 15 U/L, alanine aminotransferase (ALT) 17 U/L, alkaline phosphatase (AF) 96 U/L, gamma-glutamyl transferase (γ GT) 31 U/L, lactate dehydrogenase (LDH) 423 U/L, β -2 microglobulin 2,49 mg/mL.

Protein immunoelectrophoresis showed suspicious M paraprotein finding but below detectability limit. Thereby M paraprotein was not defined clearly.

There were no parasites and protozoa in stool, 5 times determined.

Toxocara canis IgG antibodies were positive twice [19,6 novaghost units (NU) first, and 15,1 NU second time]. IgM class titer was normal. This indicated former infection time not the acute disease.

Lung X-ray examination showed no pathologic changes in pulmonary tissue and mediastinum.

Spirometry showed slightly decreased lung diffusion capacity with the negative metacholine test. Lung capacity was as shown: vital capacity (VC) 100%, forced vital capacity (FVC) 103%, forced expiratory volume in the first second (FEV)-1 100%, peak expiratory flow (PEF) 122%, maximum expiratory flows (MEF)_{50%FVC}, 115%, MEF_{25%FVC}, 67%.

Ultrasound heart examination revealed mitral and tricuspid regurgitation +1. Small interventricular aneurism was observed, too.

Infectologist prescribed albendazole, 400 mg *per os* twice daily for two weeks.

There were no systemic connective tissue disease and no signs of vasculitis according to final allergist's conclusion.

On September 16, 2014 the patient was presented to the oncology team of the Hematology Clinic, Clinical Centre of Serbia. Pathohistological (PH) finding revision of the removed tumor from 2013 was suggested.

PH revision finding, from September 29, 2014, showed: Morphologic and immunophenotype finding of classic Hodgkin lymphoma, mixed cellularity type.

Immunophenotype was: CD 20-, CD 3-, CD 15+, CD 30+, MUM 1+, CD 68-, EBV -, Ki 67+ in most tumour cells (Figure 3).

After such conclusion, staging of lymphoma was performed. According to Ann Arbor classification staging (CS) the patient was classified into II B CS, International Prognostic Score (IPS) 2, infradiaphragmal localisation.

As the patient had $37,9 \times 10^3$ the leukocytes/ μ L (eosinophils 59% or 22,361/ μ L) we started corticosteroid therapy with prednisone orally in a total daily dose of 70 mg, (1mg/kg/body mass). Treatment was continued with chemotherapy: adriamycin, bleomycin, vinblastine, decarbazine (ABVD) regimen protocol. The patient received on the

first and fifteenth day doxorubicine 45 mg i.v; vinblastine 10 mg i.v; bleomycine 15 mg i.v; and dacarbazine 700 mg i.v.

After fourth ABVD course, abdomen and pelvis control CT examination was done. The finding was normal, without lymph nodes enlargement and tumour mass. The complete remission (CR) was achieved after four courses of chemotherapy. Treatment was discontinued in March 2015, after six courses of ABVD protocol.

After that, the blood analysis showed normal findings except for slight eosinophilia – 640/ μ L.

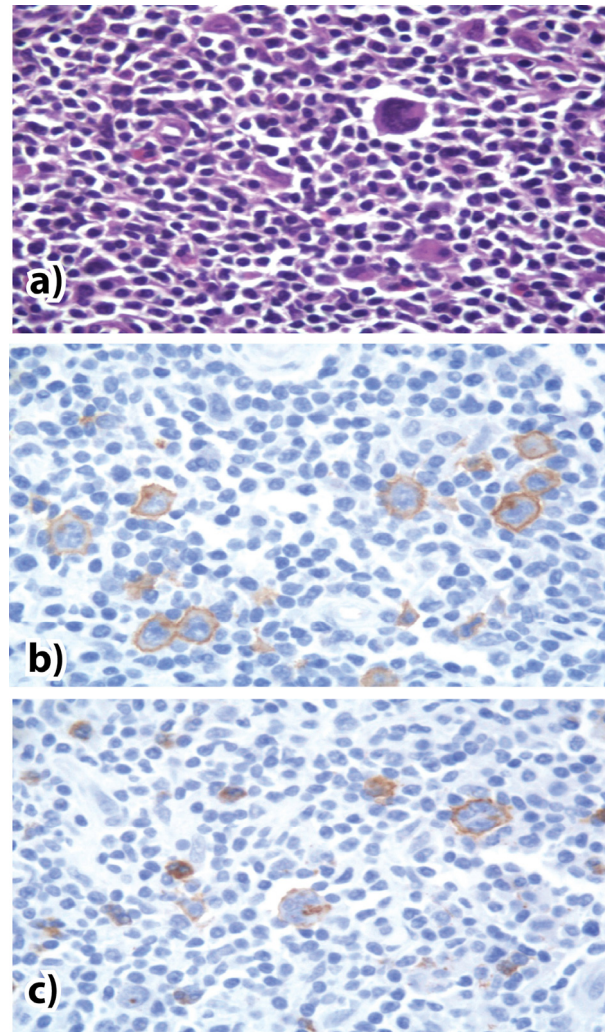


Fig. 3 – Classic Hodgkin lymphoma, mixed cellularity type: a) HE, $\times 400$; b) CD 30+; c) CD 15+.

Discussion

The female patient was presented with blood eosinophilia (1,530–2,040/ μ L blood) 6 months before HL diagnosis. Despite of many examinations made by several physicians (a general practitioner, surgeon, radiologist, infectologist, allergologist and haematologist) eosinophilia cause was not defined.

Key point was histopathological revision of the removed tumour, unfortunately primarily classified as eosinophilic granuloma. These two diseases are not easy to differ and mistakes are possible. In German publication from 2002 there was a suspicion that two patients had lymphoma and eosinophilic granu-

loma at the same time⁵. 18 fluoro-2-deoxy-D-glucose (FDG) elevated uptake with mediastinal positive positron emission tomography (PET) lesions were found in the second case. Further specimen histopathological revision confirmed that eosinophilic granuloma was a crucial diagnosis while lymphoma was not.

Eosinophilia and HL association is estimated to be present in 15–38% of all lymphoma patients^{4,6}. Its prognostic significance is not entirely clear.

In the article published in 2000⁶ authors analysed 1,511 specimens of HL patients. Significant tissue eosinophilia was found in 38% of the patients. The finding negatively affected patients with nodular sclerosis type. Comparing to the other histopathologic types shorter survival and disease free survival were recorded.

There are few cases referring to association between eosinophilia and HL. One of them is almost identical to our case. This case described by Ayyub et al.⁷ from 2003 had hypereosinophilic syndrome that preceded HL even four

years. In the other one, reported by Chinese authors, Hodgkin's lymphoma with multifocal spine involvement, was observed with eosinophilia that preceded 6 months before⁸.

Eosinophils role in lymphoma pathogenesis is yet unequivocally. Eosinophils provide ligands for receptors originated from tumor necrosis factor (TNF), CR 30, CD 40, and CD 95 Fas; also they can stimulate growth and send anti-apoptotic signals on Reed Sternberg cells⁹.

Therefore it should be kept in mind that eosinophilia, without obvious reason, can precede HL.

Conclusion

Eosinophilia without revealed cause can precede HL. We suggest careful searching for enlarged lymph nodes, anywhere in the body of patients with eosinophilia. Timely and accurate histopathologic diagnostic is a right way to resolve such conditions.

R E F E R E N C E S

1. Paige L, Darryl JA, Redvan M. The human eosinophil. In: *In: Greer JP, Foerster J, Rodgers GM, Paraskevas F, Glader B, Arber DA, Means Jr RT*, editors. *Wintrobe's Clinical Hematology*. 13th ed. Philadelphia: Lippincott Williams & Wilkins; 2013. p. 323.
2. Montgomery ND, Dunphy CH, Mooberry M, Laramore A, Foster MC, Park SI, et al. Diagnostic complexities of eosinophilia. *Arch Pathol Lab Med* 2013; 137(2): 259–69.
3. Valent P. Pathogenesis, classification, and therapy of eosinophilia and eosinophil disorders. *Blood Rev* 2009; 23(4): 157–65.
4. Cyriac S, Sagar TG, Rajendranath R, Rathnam K. Hypereosinophilia in Hodgkin lymphoma. *Indian J Hematol Blood Transfus* 2008; 24(2): 67–8.
5. Naumann R, Beuthien-Baumann B, Fischer R, Kittner T, Bredow J, Kropp J, et al. Simultaneous occurrence of Hodgkin's lymphoma and eosinophilic granuloma: A potential pitfall in positron emission tomography imaging. *Clin Lymphoma* 2002; 3(2): 121–4.
6. von Wasielewski R, Seth S, Franklin J, Fischer R, Hübner K, Hansmann ML, et al. Tissue eosinophilia correlates strongly with poor prognosis in nodular sclerosing Hodgkin's disease, allowing for known prognostic factors. *Blood* 2000; 95(4): 1207–13.
7. Ayyub M, Anwar M, Luqman M, Ali W, Bashir M. A case of hypereosinophilic syndrome developing Hodgkin's disease after 4 years. *Br J Haematol* 2003; 123(5): 955–6.
8. Geng YH, Wang CX, Tan YB, Xu XM, Cao Y, Liu ZY, et al. Primary Hodgkin disease of the spine could mimic eosinophilic granuloma initially. *Chin Med J (Engl)* 2013; 126(18): 3584–6.
9. Pinto A, Aldinucci D, Gloghini A, Zagonel V, Degan M, Perin V, et al. The role of eosinophils in the pathobiology of Hodgkin's disease. *Ann Oncol* 1997; 8 Suppl 2: 89–96.

Received on June 4, 2015.

Revised on December 12, 2015.

Accepted on December 15, 2015.

Online First September, 2016.