



The value of brush cytology and biopsy for the diagnosis of colorectal cancer

Vrednost citologije tehnikom četkice i biopsije u dijagnozi kolorektalnog karcinoma

Željka Tatomirović^{*†}, Vesna Škuletić^{*†}, Ivana Tufegdžić^{*†}, Ljiljana Tomić^{*},
Jelena Džambas^{*}, Dino Tarabar^{†‡}

Military Medical Academy, ^{*}Institute of Pathology and Forensic Medicine, [‡]Clinic for Gastroenterology and Hepatology, Belgrade, Serbia; University of Defence, [†]Faculty of Medicine of the Military Medical Academy, Belgrade, Serbia

Abstract

Background/Aim. Although it is well-known the high sensitivity of brush cytology for the diagnosis of colorectal adenocarcinoma, this kind of diagnostics is not routinely used, and for the past years it has even been declining. The purpose of this study was to evaluate the value of brush cytology for the diagnosis of colorectal carcinoma, by comparison the results of brush cytology and biopsy, and then the results of both diagnostic methods with the final patohistological diagnosis of colorectal resection. **Methods.** This retrospective study included 173 patients with brush cytology of colorectal region during colonoscopy. In 166 patients concomitant biopsy specimens were obtained, and in 116 of them resection of the intestine as well. A total of the 106 patients underwent to all three diagnostic procedures. **Results.** Out of 166 patients who went through both brush cytology and biopsy, the congruent diagnosis was made in 129 (77.7%) patients: in 109 (65.7%) adenocarcinoma was diagnosed, which was confirmed after the resection of the intestine in 75 of the patients, and in 14 (8.4%) benign lesion, so there was no need for resection of the intestine. In 6 (3.6%) of the patients, both cytology and biopsy were negative, but the resected specimen was malignant. In 10 of the patients with malignant cytology

in whom biopsy was not done, resection of the intestine confirmed malignancy. The sensitivity of detecting malignancy by brush cytology and biopsy were 87.9% and 78.3%, respectively (but this difference was not statistically significant, $p = 0.083$). Both methods had specificity and positive predictive values 100%. Negative predictive values for cytology and biopsy were 50% and 37.8%, respectively. The accuracy of cytology and biopsy was 89.2% and 80.8%, respectively. The combination of the results of brush cytology and biopsy increased the sensitivity of preoperative diagnostics to 94.8% which was significantly higher than sensitivity of biopsy ($p < 0.001$), but not than sensitivity of cytology ($p = 0.102$). **Conclusion.** Brush cytology could be a routine method, along with biopsy, in the diagnosis of colorectal malignancy. Both methods have comparable both sensitivity and accuracy, and its combination increases sensitivity of preoperative diagnostics of colorectal adenocarcinoma, which gives opportunity to better estimation of further diagnostic and therapeutic approach.

Key words:
colorectal neoplasms; adenocarcinoma; diagnosis; biopsy; cytological techniques; sensitivity and specificity.

Apstrakt

Uvod/Cilj. Iako je dobro poznat visok senzitivitet citologije tehnikom četkice u dijagnozi kolorektalnog karcinoma, ova vrsta dijagnostike nije u rutinskoj upotrebi, a poslednjih godina je čak i u padu. Cilj ove studije bila je procena vrednosti citologije tehnikom četkice u dijagnozi kolorektalnog karcinoma, poređenjem rezultata ove citološke tehnike i biopsije, a zatim rezultata obe ove dijagnostičke metode sa konačnom patohistološkom dijagnozom resektata creva. **Metode.** U ovu retrospektivnu studiju bila su uključena 173

bolesnika sa citološkim uzorcima lezije kolorektalne regije, uzetim tokom kolonoskopije. Kod 166 bolesnika urađena je i biopsija, a kod 116 i resekcija creva. Ukupno 106 bolesnika imalo je sve tri dijagnostičke procedure. **Rezultati.** Od 166 bolesnika koji su imali i citološke i biopsijske uzorke, dijagnoze su se slagale kod njih 129 (77,7%): kod 109 (65,7%) dijagnostikovao je adenokarcinom, što je potvrđeno na resektatu creva kod 75 bolesnika, a kod 14 (8,4%) dijagnostikovana je benigna lezija, tako da nije bilo potrebe za resekcijom creva. Kod 6 (3,6%) bolesnika, i citologija i biopsija su bile negativne, ali je resektat bio malignan. Kod 10 bolesnika

s malignom citologijom kojima nije rađena i biopsija, resekcijom creva potvrđen je malignitet. Senzitivnost detekcije maligniteta citologijom iznosila je 87,9%, a biopsijom 78,3% (ali ova rezlika nije dosegla i statističku značajnost, $p = 0,083$). Obe metode imale su specifičnost i pozitivnu prediktivnu vrednost 100%. Negativna prediktivna vrednost za citologiju iznosila je 50%, a za biopsiju 37,8%. Tačnost citologije bila je 89,2%, a biopsije 80,8%. Kombinacija rezultata citologije i biopsije povećala je senzitivitet preoperativne dijagnostike na 94,8%, što je statistički značajno više od sen-

zitiviteta biopsije ($p < 0,001$), ali ne i od senzitiviteta citologije ($p = 0,102$). **Zaključak.** Obe metode imaju komparabilne i senzitivitet i tačnost. Njihovom kombinacijom povećava se senzitivnost preoperativne dijagnostike kolorektalnog adenokarcinoma, a time dobija i bolja mogućnost procene daljeg dijagnostičkog i terapijskog pristupa.

Ključne reči:

kolorektalne neoplazme; adenokarcinom; dijagnoza; biopsija; citološke tehnike; senzitivnost i specifičnost.

Introduction

Colorectal carcinoma is the third most frequently diagnosed cancer and the third cause of death for both sexes in the USA¹. In Serbia, it is the second by frequency and mortality of all cancers for both sexes, which puts our country within those with the high mortality rate from this disease². These data speak well of the significance of the early and quality diagnostics of colorectal carcinoma.

No matter how great the progress in the development of diagnostic procedures, the golden standard in the diagnostics of colorectal carcinoma still remains histopathological diagnostics. Introducing endoscopic methods (at the beginning it was rigid and later on flexible colonoscopy, and new ultrasound guided endoscopy), by visualization of this region it is possible not only to take samples for histological diagnostics of intestinal lesions, but also remove adenomatous polyps.

Although cytological diagnostics of colorectal malignancies dates back to the end of 1940s³ cytology of large intestine is not used for the routine diagnostics or prevention of colon cancer⁴. Lopes Cardoso⁵ in 1980s considered colorectal cytology as "a neglected field in the clinical cytology", expecting that introduction of endoscopic techniques would change that, since nonpractical lavage of the intestine was substituted by brush cytology. The introduction of novel methods such as endoscopic ultrasound-guided fine needle aspiration (EUS FNA) and liquid-based cytology, could have been a new impulse for more use of cytological diagnostics⁶⁻⁸.

Although papers from the last two decades of the last century, as well as from the first decade of this century, point out to high sensitivity to brush cytology of the colorectal region⁸⁻¹³, sometimes even higher than to biopsy¹⁴, complementarity of those two diagnostics as well as insufficiency of small biopsies^{15, 16}, cytological diagnostics of this region has been declining for the past years¹⁷.

For the last 15 years, we have found only four papers on evaluation of cytological diagnostics of the lower gastrointestinal (GI) tract by brush cytology^{8, 12, 13, 18}.

At our hospital, for the diagnostics of colorectal carcinoma besides biopsy, also brush cytology is used, though cytology is not completely accepted as part of the routine diagnostics.

The aim of this retrospective study was to compare the results of brush cytology and biopsy, and then the results of both diagnostic methods with the final pathohistological diagnosis of colorectal resection.

Methods

This retrospective study included 173 patients, aged 21–88, with brush cytology of colorectal region hospitalized at the Clinic for Gastroenterology and Hepatology, Military Medical Academy, Belgrade, in the period 2008–2013. There were 115 males and 61 females.

Analysis of cytological and pathohistological materials was performed at the Institute of Pathology and Forensic Medicine, Military Medical Academy. The findings of brush cytology were compared with biopsy, and later on both cytology and biopsy results were compared with the definitive diagnosis of resection.

Sampling procedure

The patients were submitted to sigmoidoscopy or colonoscopy under short analosedation. After visualization of the lesion, a brush was introduced *via* the endoscope to take a sample which was applied directly on 2 slides. After that, biopsy of the same lesion was performed.

Preparation of materials for cytological and pathohistological analysis

Cytological smears were air dried and stained with May-Grünwald Giemsa and biopsy samples immediately fixed in 10% buffered formalin, treated in the usual way, and stained with hematoxylin and eosin.

Interpretation of cytological and pathohistological findings

Cytological smears were interpreted by the three cytologists, independently from interpretation of biopsy samples, as negative of malignancy, atypical, suspicious of malignancy, and malignant. For statistical analysis, a finding of atypia was considered as negative finding, and suspicious of malignancy as malignant one.

Criteria for malignancy of cytological smears covered both architectural and cytological morphological features: enlarged nuclei, high nuclear/cytoplasm ratio, enlarged nucleoli, multiplied nucleoli, irregular structure of chromatin, hyperchromasia, pleomorphism of cells, loss of polarity of cells and overlapping and/or loss of cohesion, single cells and naked, single nuclei, pathological mitoses (Figures 1 and 2).

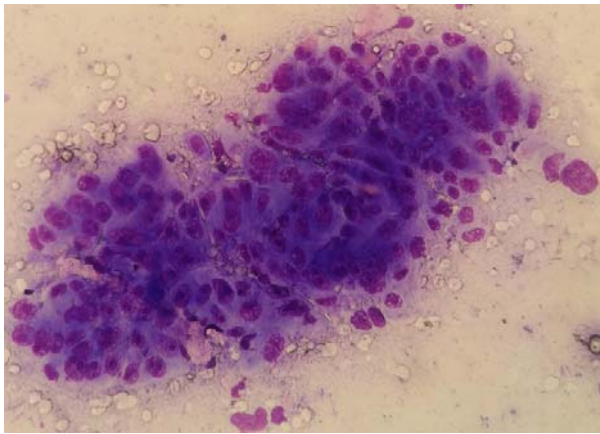


Fig. 1 – Brush cytology: architectural characteristics of colonic adenocarcinoma. Crowded groups, lack of polarity and overlapping cells, bare, single, enlarged nuclei (May Grunwald-Giemsa-MGG, ×200).

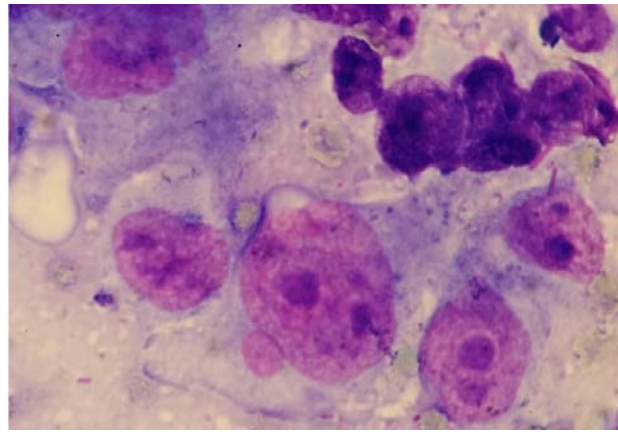


Fig. 2 – Brush cytology: cytological characteristics of colonic adenocarcinoma. Enlarged nuclei, enlarged and prominent nucleoli, nuclear pleomorphism, decreased cohesiveness, nuclear crowding and overlap (May Grunwald-Giemsa-MGG, ×1000)

Biopsy samples, as well as the final interpretation of the resected material, was done by the single pathologist. The diagnosis of malignancy (adenocarcinoma) was established on the basis of the World Health Organization (WHO) criteria¹⁹.

Statistical analysis

Besides the usual parameters of descriptive statistics for the age of patients (mean values \pm SD), the standard definitions of sensitivity, specificity, positive predictive value (PPV) and negative predictive value (NPV) for brush cytology and biopsy were used. The unit of analysis was a patient. True positive were considered all malignant cytological and biopsy findings concordant with resection. True negative were considered the findings with both brush cytology and biopsy negative for malignancy. Because of that, resection was not done, and further follow up excluded malignancy. Statistical evaluation for comparison of the sensitivity of both biopsy and cytology was performed using the *t*-test of proportion (PASW Statistics 18, SPSS, Inc., USA). The results were considered significant at the level of $p < 0.05$.

Results

Within a 3-year period brush cytology of colorectal region was applied to 176 patients, the average age of 68.82 ± 11.98 . In 166 patients biopsy of the lesion was also

performed (in 116 of them colorectal resection was also done), and 106 patients underwent all the diagnostic techniques (brush cytology, biopsy and resection).

Out of 60 patients not submitted to colorectal resection, in 14 was no need for that because it was benign lesion (both cytology and biopsy were negative in the sense of malignancy, as well as further follow-up), while 46 patients continued with the treatment in other hospitals, so they were excluded from statistical analysis.

Comparison of the results of brush cytology, biopsy and resection

Out of 166 patients who went through both brush cytology and biopsy, the congruent diagnosis was in 129 (77.7%) of the patients: in 109 (65.7%) adenocarcinoma was diagnosed, which was confirmed after the resection of the intestine in 75 patients (in 34 patients colorectal resection was not applied in our hospital), and in 14 (8.4%) patients the benign lesion was diagnosed, so there was no need for resection of the intestine (as already mentioned). In 6 (3.6%) of the patients, both cytology and biopsy were negative, but the resected specimen was malignant. In 10 patients with malignant cytology in whom biopsy was not done, resection of the intestine confirmed malignancy (Table 1).

Out of 37 patients with noncongruent findings of cytology and biopsy, 25 underwent resection of the intestine: in 17 (16.0%) of them cytology was congruent with resection

Table 1
Results of brush cytology, biopsy and resection of the intestine in 176 patients submitted to brush cytology

Type of material	c b r	c b r	c b r	c b r	c b r	c b r	c b r	c b r	c b r	Total
Diagnosis (+, -, 0)	+++	++0	--0	+ - +	- + +	- - +	+0+	+ - 0	- + 0	
Number of patients, (n)	75	34	14	17	8	6	10	9	3	176

c – cytology; b – biopsy; r – resection; + – malignant (adenocarcinoma); -- benign; 0 – not done.

(malignant) and biopsy was negative, and in 8 (7.5%) biopsy was congruent with the resection (malignant) but cytology was negative (Tables 1 and 2).

Table 2

Results of brush cytology and biopsy in 106 patients with adenocarcinoma proved on resection of the intestine

Cytology	Biopsy	Patients n (%)
+	+	75 (70.6)
+	-	17 (16.0)
-	+	8 (7,5)
-	-	6 (5,7)
Total number		106

+ – malignant (adenocarcinoma); - – negative for malignancy.

For 12 patients who did not undergo colorectal resection, nor follow-up at our hospital, we had no definitive diagnosis. In 9 of them cytology was positive and biopsy negative, and in 3 it was the other way round (Table 1).

False negative brush cytology

There were 14 false negative findings of brush cytology (in 6 of them biopsy was negative as well, and in 8 biopsy was positive). By subsequent revision of cytology it was found out that in 10 brush cytologies there were sampling errors: in 7 only the normal tissue particles were found (Figure 3), and in 3 it was scant cellularity. For 2 brush cytologies interpretation of atypia remained. One brush cytology was reinterpreted as malignant (Figure 4) and another one was suspicious of malignancy, and those were only two interpretative errors.

False negative biopsy

In 23 of the patients with false negative biopsies (in 6 of them cytology was negative, as well), the diagnoses were: tubulovillous and tubular adenoma with dysplasia of low-grade (7), dysplasia of medium to high and high-grade (4), dysplasia of high-grade to intraepithelial carcinoma (3), villous adenoma with dysplasia of high-grade (1), villous and

tubular adenoma (2), tubular adenoma with dysplasia of low-grade to carcinoma *in situ* (1), chronic colitis (3) and without the elements of malignancy (2).

The results of statistical analysis

For the purpose of statistical evaluation, comparison of cytology and biopsy with the definitive diagnosis of resection, to the group of 116 patients with brush cytology and resection of the intestine, and also to the group of 106 patients with biopsy and resection of the intestine, were added 14 patients in whom colorectal resection was not done due to both negative cytology and biopsy, and a subsequent follow-up period excluded malignancy, and such findings were considered true negative.

There were 14 (13.2%) false negative cytological findings and 23 (22.3%) false negative biopsy. There were no false positive findings at all both for cytology and biopsy.

The sensitivity of cytology was 87.9% and of biopsy 78.3%, but this difference was not statistically significant ($p = 0.083$). Both methods had specificity and PPV 100%, because there were no false negative findings. NPV was 50% for cytology and 37.8% for biopsy. The accuracy of cytology was 89.2% and for biopsy 80.8%. The combination of the two methods increased the sensitivity of preoperative diagnostics to 94.8% which was significantly higher than sensitivity of biopsy alone ($p < 0.001$), but not than sensitivity of cytology alone ($p = 0.102$).

Discussion

There are numerous pathological processes which may involve the lower GI tract, from infections and inflammatory conditions until tumors, as well. Such enlarged etiology requires multidisciplinary approach which involves serological, microbiological and various radiological diagnostics. However, because benign lesions could imitate GI malignancy both clinically and radiologically and the finding of neoplasm requires to determine definitive type, the most precise diagnostics is histopathological, for which the specimen is obtained by endoscopy.

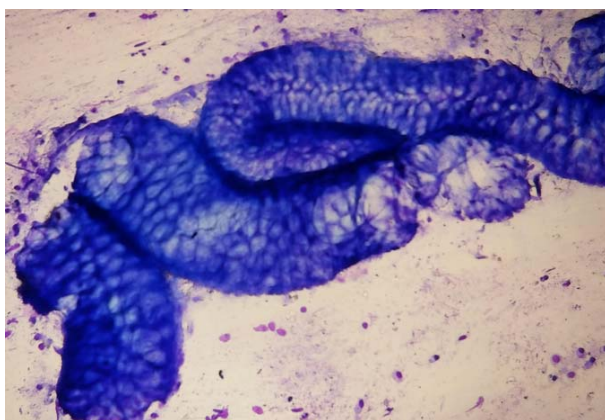


Fig. 3 – Brush cytology, tissue microparticle, normal colorectal mucosa. (May Grunwald-Giemsa-MGG, ×100).

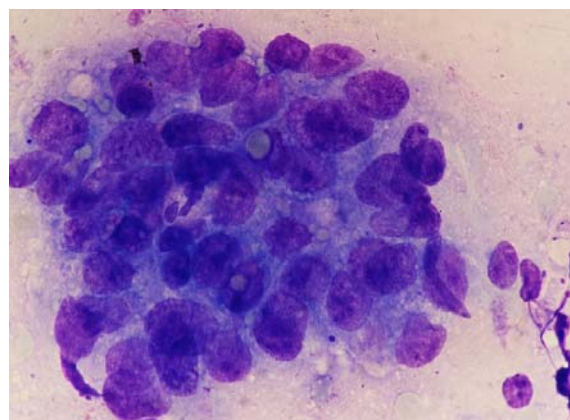


Fig. 4 – Brush cytology, false negative. Crowded group, overlapping cells with enlarged hyperchromatic nuclei. (May Grunwald-Giemsa-MGG, ×1000).

Among various methods and instruments for obtaining material in endoscopy, such as pinch biopsy, endoscopic ultrasound guided fine needle aspiration (EUS-FNA), true cut needle biopsy, snare excision, suction biopsy, endoscopic mucosal resection, there is also brush cytology²⁰.

Pinch biopsy is the most used diagnostic method that allows relatively easy to obtain a specimen from various points of a specific region during endoscopy, which increases the possibility of obtaining representative material and thus precise diagnostics. That could be one of the reasons for brush cytology not to be always a part of the routine diagnostic procedure. But brush cytology has its own significant advantages regarding the possibility of obtaining specimens from larger areas as well as from the point of strictures with the limited possibilities for forceps biopsy²¹, also regarding the simplicity of processing specimens, rapid finalizing of report, satisfactory accuracy and economic benefit.

Limitations of brush cytology are mainly difficulties in discerning reactive/inflammatory alterations on cells from malignant cells, differentiation adenoma out of well differentiated adenocarcinoma²¹, insufficiency of specimen for special staining (usually it takes only two slides) which makes more difficult and prevents precise diagnosis of primary lymphoproliferative, neuroendocrine and mesenchymal, as well as tumors which might spread from near by organs to the GI tract, and also metastatic ones.

Besides all of these limitations, papers published in the last 25 years show that the sensitivity of brush cytology of colorectal region is not only almost equal to the sensitivity of biopsy, but even a little bit higher. For brush cytology the sensitivity ranges from 78.1% to 95.7% and for biopsy from 74% to 96%^{8, 9, 11-13}. The highest sensitivity (95.7%) of brush cytology of colorectal region have been shown by Kontzoglou et al.⁸ who evaluated the role of Thin-Prep[®] liquid-based cytology in the investigation of colorectal lesions, and the largest group of patients (918) have been processed by Brouwer et al.¹³ who have found out the sensitivity of brush cytology to be 88.2% and of biopsy 86.9%.

The sensitivity of brush cytology (87.9%) and of biopsy (78.3%) obtained in our study are in compliance with the published results, especially with papers that report somewhat higher sensitivity of cytology^{8, 9, 13, 14}. We found out higher agreement between cytology and biopsy (86.1%), and also higher percentage of positive cytology alone (16.0%) from positive biopsy alone (7.5%) as compared to the results of Petrelli et al.¹¹ (68.5%, 9.6%, 12.3%, respectively).

Although our sensitivity of brush cytology was higher than sensitivity of biopsy, this difference was not statistically significant ($p = 0.083$). A combination of both techniques increased the sensitivity to 94.8%, which was statistically significantly higher than the sensitivity of biopsy alone ($p < 0.001$), but not superior to cytology alone ($p = 0.102$), opposite to the results of Petrelli et al.¹¹ who found the combination of both techniques not significantly superior to biopsy alone ($p = 0.16$), but tend to be superior to cytology alone ($p = 0.07$).

A positive predictive value of 100% both for cytology and biopsy in our paper is a consequence of the fact that there were no false positive findings. Brouwer et al.¹³ have fo-

und a positive predictive value of brush cytology of 98.6%, and of biopsy 99.5%. However, a negative predictive values for our both cytology and biopsy (50%, 37.8%, respectively) were lower than those for both methods found by Brouwer et al.¹³ in their group of patients (61.5%, 60.3%, respectively).

Revision of 12 negative cytological findings showed that 10 were sampling errors and 2 interpretative errors, and 2 findings were still characterized as atypical. A sampling error is possible to avoid by rapid on sight evaluation (ROSE) which we did not apply.

Disadvantages of the cytological diagnostics, beside already specified, are in the fact that it is not possible to estimate the depth of invasion, whether the cells with cytological features of malignancy break the basal membrane, and invade mucosis or submucosis, respectively whether it is dysplasia, intraepithelial or intramucosal carcinoma or invasive one. In that way, in high-grade dysplasia, when cells could morphologically have features of malignant cells, there is the possibility of false positive cytological findings. Fearing of overdiagnosis, we made the cytological diagnosis of adenocarcinoma only if we had undoubtedly both cytological and architectural morphological features of malignancy. That is why we had no false positive cytological findings, and among false negative findings, by revision, we found one positive as well as one finding suspicious of malignancy. In 13 brush cytologies we were cautious and characterized them as suspicious of malignancy (in statistical analysis we counted them into positive findings).

As it was already mentioned, brush cytology proved itself as more sensitive method then biopsy in our study (although this difference was not statistically significant). The reason of somewhat higher number of false negative biopsies (less sensitivity biopsies) is in disadvantages of the method itself, respectively of higher possibility for sampling error due to scant specimen, but also due to criteria for making the diagnosis for malignancy (adenocarcinoma).

According to the WHO¹⁹ an obligatory criterion for the diagnosis of colorectal adenocarcinoma is invasion of the submucosis or beyond, which is an indicator of metastatic potential. If preoperative biopsy does not identify submucosal invasion, there is a great possibility for underestimation of the depth of invasion, and thus invasive carcinoma is diagnosed as high-grade intraepithelial neoplasia¹⁶.

If the basal membrane, mucosis and submucosis are not shown on small biopsies, or if it is not possible to get these structural tissues because of necrotic or stenosing tumor, the precise diagnosis of pathological process, which is necessary for opting on further treatment – endoscopic or surgical local resection, or surgical resection, is disabled.

The smaller the area from which a specimen is obtained, unlike brush cytology, could result to end up with the piece of tumor tissue without invasive part respectively, where tumor is limited only to mucosis.

Contrary to the Western pathologists Japanese pathologists do not consider invasion of submucosal layer obligatory for the diagnosis of colorectal adenocarcinoma, and they pay more attention to morphological features of nucleus and glandular structures, similar to cytological diagnostics, which

gives high sensitivity to biopsy, but could lessen specificity, leading into more radical approach than it is necessary²². These differences in diagnostic approach have been coordinated by the Vienna classification of GI epithelial neoplasia in which an intramucosal carcinoma has been accepted as the earliest form of invasive carcinoma²³. In the revised Vienna classification it is recommended to qualify a biopsy finding of intramucosal carcinoma as "at least"²⁴. However, the estimation of efficiency of the revised Vienna classification for biopsy diagnostics of colorectal epithelial neoplasia has shown its high positive predictive value, and low sensitivity in the diagnostics of colorectal carcinoma, if pathologists use the invasion of submucosa or deeper invasion as an obligatory criterion for the diagnosis of carcinoma²⁵.

Analysis of our 23 false negative biopsies showed a sampling error. In 14 biopsies adenoma was diagnosed, dysplasia of low to medium-grade, chronic inflammation, while in 9 biopsies with high-grade dysplasia to intraepithelial carcinoma, invasion of muscular mucosa and deeper could not be confirmed.

Having considered the advantages and disadvantages of both methods for sampling specimens, we find that in estimation of further diagnostic and therapeutic approach to colorectal lesions, brush cytology could be of great help when it is undoubtedly malignant, in cases when simultaneously biopsy could not estimate whether there is an invasion of submucosa. Brush cytology could reduce the need for rebiopsy, especially if there is a clear-cut clinical malignancy picture. In our 10 patients with a clear-cut local finding of carcinoma, only brush cytology was done.

Conclusion

We think that brush cytology could be the routine method along with biopsy in the diagnosis of colorectal malignancy. Both methods have comparable both sensitivity and accuracy, and their combination increases sensitivity of the preoperative diagnostics of colorectal adenocarcinoma providing better estimation of further diagnostic and therapeutic approach.

R E F E R E N C E S

1. Ferlay J, Soerjomataram I, Ervik M, Dikshit R, Eser S, Mathers C, et al. GLOBOCAN 2012 v1.0, Cancer Incidence and Mortality Worldwide: IARC CancerBase No 11. Lyon, France: International Agency for Research on Cancer; 2013.
2. Vlajinac H, Sipetić-Grujić S, Janković S, Marinković J, Kocov N, Marković-Denić L, et al. Burden of cancer in Serbia. *Croat Med J* 2006; 47(1): 134–41.
3. Wisseman CL Jr, Lemon HM, Lawrence KB. Cytologic diagnosis of cancer of the descending colon and rectum. *Surg Gynecol Obstet* 1949; 89(1): 24–30.
4. Schmitt F, Oliveira MH. Oesophagus and gastrointestinal tract. In: Gray W, Kocjan G, editors. *Diagnostic cytopathology*. London: Churchill Livingstone Elsevier; 2010. p. 279–81.
5. Cardoso L. Cytology of colorectal carcinoma In: Welvaart K, Blumgart LH, Kreuning J, editors. *Colorectal Cancer*. Hague: Leiden University Press; 1980. p. 43–52.
6. Vander Noot MR 3rd, Eloubeidi MA, Chen VK, Eltoum I, Jhala D, Jhala N, et al. Diagnosis of gastrointestinal tract lesions by endoscopicultrasound-guided fine-needle aspiration biopsy. *Cancer* 2004; 102(3): 157–63.
7. Fernández-Esparrach G, Alberghina N, Subtil JC, Vázquez-Sequeiros E, Florio V, Zozaya F, et al. Endoscopic ultrasound-guided fine needle aspiration is highly accurate for the diagnosis of perirectal recurrence of colorectal cancer. *Dis Colon Rectum* 2015; 58(5): 469–73.
8. Kontzoglou K, Moulakakis KG, Alexiou D, Safioleas MC, Nikiteas N, Giabnaki A, et al. The role of liquid-based cytology in the investigation of colorectal lesions: A cytohistopathological correlation and evaluation of diagnostic accuracy. *Langenbecks Arch Surg* 2007; 392(2): 189–95.
9. Farouk R, Dodds J, MacDonald AW, Young W, Duthie GS, Lee PW, et al. Feasibility study for use of brush cytology as a complementary method for diagnosis of rectal cancer. *Dis Colon Rectum* 1997; 40(5): 609–13.
10. Halpern M, Gal R, Rath-Wolfson L, Koren R, Weil R, Avni A. Brush cytology and biopsy in the diagnosis of colorectal cancer. A comparison. *Acta Cytol* 1997; 41(3): 628–32.
11. Petrelli NJ, Létourneau R, Weber T, Nava ME, Rodríguez-Bigas M. Accuracy of biopsy and cytology for the preoperative diagnosis of colorectal adenocarcinoma. *J Surg Oncol* 1999; 71(1): 46–9.
12. Geramizadeh B, Hooshmand F, Kumar PV. Brush Cytology of Colorectal Malignancies. *Acta Cytol* 2003; 47(3): 431–4.
13. Bronner R, MacDonald A, Matthews R, Gunn J, Monson JR, Hartley JE. Brush cytology for the diagnosis of colorectal cancer. *Dis Colon Rectum* 2009; 52(4): 598–601.
14. Elhya H, O'Hara BJ. Brush cytology in the diagnosis of colonic neoplasms. *Cancer* 1990; 66(7): 1563–7.
15. MacDonald AW, Tayyab M, Arsalani-Zadeh R, Hartley JE, Monson JR. Intramucosal carcinoma on biopsy reliably predicts invasive colorectal cancer. *Ann Surg Oncol* 2009; 16(12): 3267–70.
16. Wei XB, Gao XH, Wang H, Fu CG, Zheng WQ, Zheng JM, et al. More advanced or aggressive colorectal cancer is associated with a higher incidence of "high-grade intraepithelial neoplasia" on biopsy-based pathological examination. *Tech Colo-proctol* 2012; 16(4): 277–83.
17. Kini SR. Alimentary tract: Esophagus, gastrointestinal, gall bladder and extrahepatic biliary tract (Exfoliative and aspiration cytology). In: Kini SR, editor. *Color atlas of differential diagnosis in exfoliative and aspiration cytopathology*. Baltimore: Lippincott Williams&Wilkins; 2011. p. 305–7.
18. Yu GH, Nayar R, Furth EE. Adenocarcinoma in colonic brushing cytology: High-grade dysplasia as a diagnostic pitfall. *Diagn Cytopathol* 2001; 24(5): 364–8.
19. Hamilton SR, Aaltonen LA. World Health Organisation classification of tumors: Pathology and genetics of tumours of the digestive system. Lyon: IARC Press; 2000.
20. Technology Assessment Committee, Barkun A, Liu J, Carpenter S, Choti Prasadhi P, Chuttani R, et al. Update on endoscopic tissue sampling devices. *Gastrointest Endosc* 2006; 63(6): 741–5.
21. Conrad R, Castelino-Prabhu S, Cobb C, Raza A. Role of cytopathology in the diagnosis and management of gastrointestinal tract cancers. *J Gastrointest Oncol* 2012; 3(3): 285–98.
22. Schlemper RJ, Itabashi M, Kato Y, Levin KJ, Riddell RH, Shimoda T, et al. Differences in the diagnostic criteria used by Japanese and Western pathologists to diagnose colorectal carcinoma. *Cancer* 1998; 82(1): 60–9.

23. *Schlemper RJ, Riddell RH, Kato Y, Borchard F, Cooper HS, Dawsey SM, et al.* The Vienna classification of gastrointestinal epithelial neoplasia. *Gut* 2000; 47(2): 251–5.
24. *Dixon MF.* Gastrointestinal epithelial neoplasia: Vienna revisited. *Gut* 2002; 51(1): 130–1.
25. *Tominaga K, Fujinuma S, Endo T, Saida Y, Takahashi K, Maetani I.* Efficacy of the revised Vienna Classification for diagnosing colorectal epithelial neoplasias. *World J Gastroenterol* 2009; 15(19): 2351–6.

Received on January 12, 2016.

Revised on March 6, 2016.

Accepted on March 7, 2016.

Online First May, 2016.