



# A case of carcinoma of the breast with metaplasia to chondrosarcoma: light microscopic and immunohistochemical features

**Attila FENYVESI**

*The breast carcinomas with metaplasia are rare neoplasms showing both carcinomatous and sarcomatous elements. We described clinical behavior, radiology findings and pathological features in case of breast carcinoma with heterologous chondrosarcomatoid metaplasia. The light microscopic features and the immunohistochemical markers of metaplastic carcinomas were highlighted in this paper with discussion focusing on histogenesis of this type of tumor.*

GENERAL HOSPITAL SENTA, DEPARTMENT OF PATHOLOGY,  
SENTA, SERBIA AND MONTENEGRO

**KEY WORDS:** Breast Neoplasms; Carcinoma; Metaplasia; Chondrosarcoma; Immunohistochemistry

## INTRODUCTION

**C**arcinoma of the breast arises from the mammary glandular epithelium and shows ductal or lobular differentiation. However, few cases of breast cancer transform into a non-glandular growth pattern and they are postulated as metaplasia of carcinoma. Metaplastic carcinoma of the breast is rare and it has been classified into two groups: squamous metaplasia (3.7% of all breast cancers) and heterologous metaplasia (0.2%) (1). Heterologous metaplasia is most commonly encountered as connective tissue, bone or cartilage that may appear histologically benign or malignant (1,2).

## Clinical history

A 41-year-old woman noticed a rapidly growing mass in her right breast and was admitted at the Department of Surgery in General Hospital Senta. Physical examination confirmed the tumefaction in lower lateral quadrant of the right breast. The tumor was approximately 3 cm in size, well defined and of elastic consistency, with no fixation to the skin or pectoral fascia. Laboratory findings, chest X ray, ECG, and heart and respiratory functions were in normal ranges. Mammographic examination detected an adenoid pattern with well-defined oval lesion in lower lateral quadrant with-

out microcalcifications and associated architectural distortion.

There were no certain signs of malignancy. Sonographically lesion was hypoechogenic. Both mammogram and ultrasound results rendered probable benign lesion. Despite radiology results a surgeon, considering the rapid clinical course, decided to biopsy with extempore diagnosis. The results of the frozen section analysis revealed malignant lesion - carcinoma. Operation was quadrantectomy of the right breast with evacuation of axilla sec. Veronesi. The postoperative period was normal. Scar healed up per primam, and patient left hospital on day 8 after the operation. The patient received postoperative treatment of combined, "sandwich" chemotherapy, six cycles of FEC (Fluorouracil, Epirubicin, Cytoxan), and radiation therapy (TD 50 Gy, 25 fractions, and BOOST TD 12 Gy, 6 fractions). She was in good condition at the latest follow-up, 6 months postoperatively.

## Gross examination

The resected breast tissue in dimension of 6x5x4 cm and dissected axillary lymph nodes were, after formalin fixation, submitted to our laboratory. The tumor tissue was in dimension of 2.5x1.5x1.5 cm, well demarcated with nodular surface, of white color, partly elastic and partly firm in consistency. The cut surface was white and flashy without hemorrhage or necrosis. In the adipose tissue of axilla 21 lymph nodes were found, the largest of them was 15 mm.

## Histopathology

Tissue was fixed in 10% buffered formalin, routinely processed, and paraffin embedded. Five microns thick sections were cut and hematoxylin-eosin (H and E) staining was done. Histologically, the

Address correspondence to:

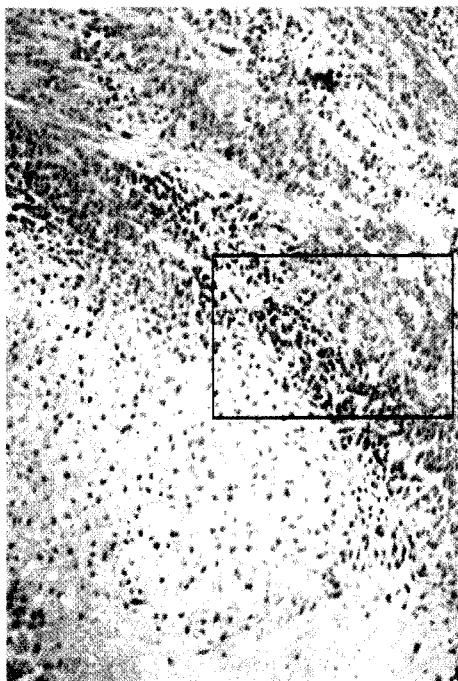
Attila Fenyvesi MD, M.Sc., General Hospital Senta, Department of Pathology, Karađorđeva b.b., 24000 Senta, Serbia and Montenegro, E-mail: attila@zdravstvosenta.co.yu

The manuscript was received: 21. 10. 2003

Provisionally accepted: 21. 11. 2003

Accepted for publication: 21. 11. 2003

tumor was mainly composed of poorly differentiated invasive ductal carcinoma with intermingled chondrosarcomatoid components (Figure 1).

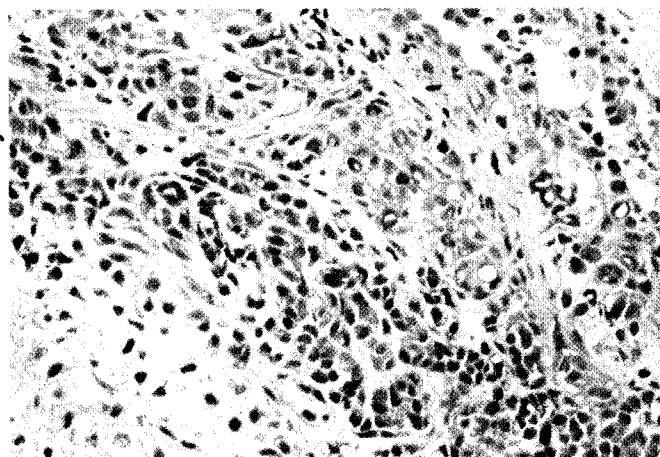


**Figure 1.** Breast carcinoma with heterologous metaplasia: a mixture of poorly differentiated ductal carcinoma (above) with chondrosarcomatous component (below) (H and E, x 100)

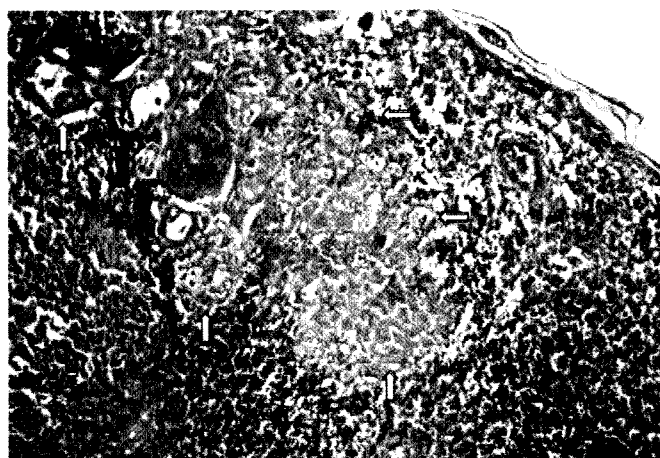
Epithelial elements of the tumor formed solid nest, fascicles, and rare tubular formation of large polygonal and cuboid anaplastic tumor cells. The cytoplasm was scanty or moderately abundant, and frequently vacuolated. The nuclei were large, variable in size, and hyperchromatic, with visible nucleolus and with large number of mitoses. Heterologous metaplastic component was constructed of chondroid matrix with large number of embedded cells with irregularity in the size of cells and their nuclei and presence of numerous cells with multiple nuclei. The epithelial and metaplastic components were divided by a layer of small undifferentiated and pleomorphic sarcomatoid cells (Figure 2). There were no associated ductal carcinomas in situ or atypical ductal hyperplasia.

Among the 21 dissected lymph nodes, only in one, we found small subcapsular metastatic deposit composed of poorly differentiated ductal carcinoma cells (Figure 3).

The diagnosis of carcinoma with heterologous metaplasia (cartilaginous-type chondrosarcoma) of the breast was made with pathologic staging pT 2, pN 1a, and pM X.



**Figure 2.** Transition of ductal carcinoma cells (upper right corner) through small, undifferentiated tumor cells to chondrosarcoma (lower left corner) (magnified view of Figure 1. H and E, x 400)



**Figure 3.** Small subcapsular metastatic deposit (arrows) in regional lymph node, composed entirely of poorly differentiated ductal carcinoma cells (H and E, x 200)

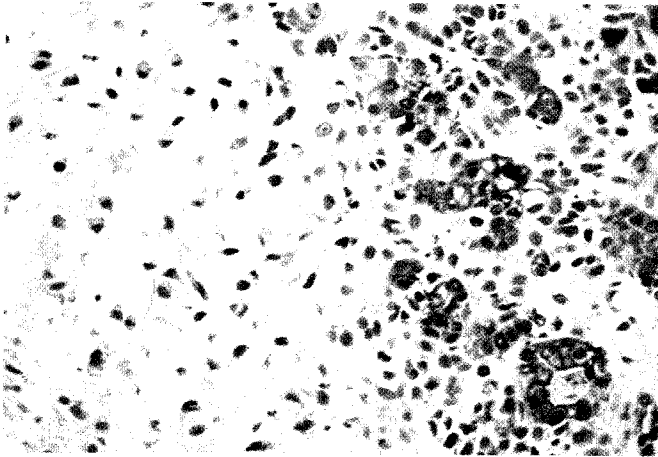
### Immunohistochemistry

Four-micrometer-thick sections from the selected original paraffin blocks were cut and rehydrated as usual. Immunohistochemical staining was carried out in the Ventana ES automated Immunohistochemistry System (Ventana Medical System Inc., Tucson, AZ, USA) using original Ventana reagents, with the exception of the primary antibodies.

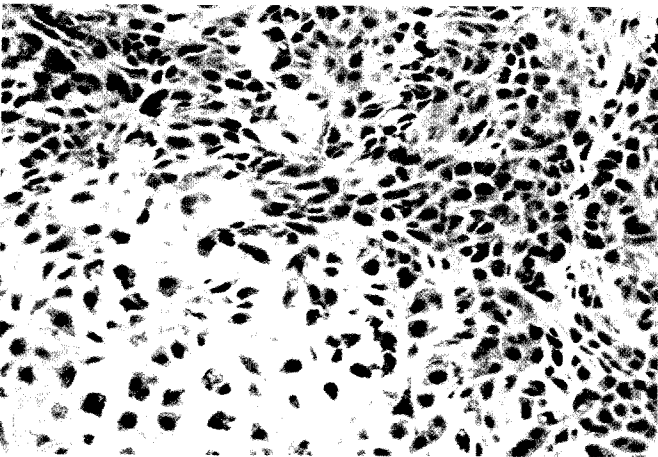
Immunohistochemistry was done by using antibodies against: c-erbB-2 (DakoCytomation, polyclonal), estrogen receptor (DakoCytomation, clone 1D5), progesterone receptor (DakoCytomation, clone PgR636), epithelial membrane antigen (DakoCytomation, clone E29), cytokeratins 8/18 (Becton Dickinson, clone cam5, 2), vimentin (DakoCytomation, clone Vim 3B4), and S-100 (DakoCytomation, polyclonal). Antigen retrieval was performed in Tris-EDTA in pH9.

Epithelial antigens, cytokeratins and epithelial membrane antigen were found only within epithelial elements and not apparent in mesenchymal chondrosarcomatoid tissue (Figure 4).

Cartilaginous components stain diffusely for vimentin and S-100. Vimentin and S-100 are also expressed in both carcinoma and pleomorphic sarcoma-like components (Figure 5). There was no immunoreactivity for estrogen and progesterone receptors and c-erbB-2.



**Figure 4.** Immunoreactivity for cytokeratins in ductal carcinoma cells with absence of reaction in undifferentiated pleomorphic cells and in chondrosarcoma (CK8/18, x 400)



**Figure 5.** Strong immunoreactivity for S-100 in both chondrosarcomatous and carcinomatous elements (S-100, x 400)

## DISCUSSION

In the breast, the most common metaplastic pattern is focal squamous metaplasia in an otherwise typical invasive ductal carcinoma (1). Tumors showing both carcinomatous and sarcomatous features are very uncommon and occur in various anatomical sites (2). In the breast this tumor is often called metaplastic carcinoma (1), but other authors prefer the term sarcomatoid carcinoma (2). Classic sarcomatoid carcinoma is a tumor with both epithelial and mesenchymal components, hence the term biphasic sarcomatoid carcinoma. The monophasic variant appears purely mesenchymal on light microscopy, with epithelial component only demonstrable by immunohistochemistry for cytokeratins (2). The mesenchymal components (heterologous metapla-

sia) are most commonly encountered as nodular fasciitis, malignant fibrous histiocytoma, osteosarcoma or chondrosarcoma (2), but seldom rhabdomyoid, adipose and angiosarcomatous metaplasia have also been seen (1). The evidence suggests developing of this type of tumor by transformation of carcinoma cells into sarcoma with detection of epithelial features in sarcomatous cells by electron microscopy or immunohistochemistry, and the predominance of epithelium in metastases (1). The cartilaginous component in this case is probably the result of direct cartilaginous metaplasia of carcinoma cells and cartilaginous metaplasia followed upon carcinoma cells turned into small, undifferentiated tumor cells and pleomorphic sarcomatous cells (1,3). In the breast, the most popular theory regarding the histogenesis of the metaplastic components is through transformation of myoepithelial cells (2,4). Wang et al. in their study consider that the tumor may have been derived from the same duct progenitor cells, and that these cells still remain multipotential after a p53 point mutation. The lineage of cells bound for luminal cells differentiate to ductal carcinoma, cells for basal cells differentiated to squamous carcinomatous element, and cells for myoepithelial cells differentiate to chondrosarcomatoid element (5). By light microscopy, a highly suggestive metaplastic transition can be traced from cells within the epithelial nests to those within the sarcomatous lobules. The cartilaginous component immunohistochemically expresses both epithelial and myoepithelial markers, such as smooth muscle actin. This observation also leads to conclusion that the sarcomatoid component of this tumor shows differentiation of myoepithelial cells (5).

The patients usually describe rapid growth and short duration prior to diagnosis. The tumors tend to have circumscribed contour radiologically. Breast carcinomas with metaplasia are largely poorly differentiated duct carcinomas. Metaplasia has been also seldom reported in lobular, tubular, medullary and mucinous breast carcinomas (1). There are literature data about complex immunoreactivity for epithelial and mesenchymal markers both in carcinoma and sarcomatous cells (1,3). Metaplastic carcinoma only rarely exhibits nuclear immunoreactivity for estrogen and progesterone receptors (1,6). Expression of markers 34BE12, p53, retinoblastoma protein, HER/2neu, epidermal growth factor receptor, and cyclin D1 do not correlate with clinicopathologic features such as patient age, tumor size, tumor type, relative proportion of metaplastic elements, and axillary nodal status and were not predictive of disease-free survival (3). The patients with metaplastic breast carcinomas may have a favorable prognosis (7). Although the lesion is relatively large in size, it tends to lack local or distant metastasis at presentation (2). Duration of symptoms, TNM stage, tumor size and axillary nodal status are significant factors of survival (6). The difference in survival among the

various subgroups of sarcomatoid carcinoma are said to be minor (2). Chieng et al. in their study of clinicopathologic features of 32 metaplastic carcinomas with heterologous osteocartilaginous elements have found a 5-year survival of 60% (3). Metastases derived from a metaplastic carcinoma may consist entirely of adenocarcinoma, entirely of metaplastic elements, or a mixture of these components (1). Metaplastic carcinomas of the breast commonly bypass axillary lymph nodes and present as distant metastases (2,7). Surgical and adjuvant treatment should follow the guidelines for the other most common breast cancers even if the need for chemotherapy is unknown due to the absence of large series of randomized or observational data (8).

**Acknowledgment:**

*I thank Tibor Toth, MD, PhD from Falun, Sweden, for help in immunohistochemical preparation of specimens.*

**REFERENCES**

---

1. Rosen PP, Oberman HA. Tumors of the mammary gland. Washington DC: Armed Forces Institute of Pathology; 1992. p.194-203.
2. Kurian KM, Al-Nafussi A. Sarcomatoid/metaplastic carcinoma of the breast: a clinicopathological study of 12 cases. *Histopathology* 2002;40:58-64.
3. Chhieng C, Cranor M, Lesser ME, Rosen PP. Metaplastic carcinoma of the breast with osteocartilaginous heterologous elements. *Am J Surg Pathol* 1998;22:188-94.
4. Wargotz ES, Norris HJ. Metaplastic carcinomas of the breast. I. Matrix-producing carcinoma. *Hum Pathol* 1989;20:628-35.
5. Wang X, Mori I, Tang W, Yang Q, Nakamura M, Nakamura Y et al. Metaplastic carcinoma of the breast: p53 analysis identified the same point mutation in the three histologic components. *Mod Pathol* 2001;14:1183-6.
6. Chao TC, Wang CS, Chen SC, Chen MF. Metaplastic carcinomas of the breast. *J Surg Oncol* 1999;71:220-5.
7. Catroppo JF, Lara JF. Metastatic metaplastic carcinoma of the breast (MCB): an uncharacteristic pattern of presentation with clinicopathologic correlation. *Diagn Cytopathol* 2001;25:285-91.
8. Bellino R, Arisio R, D'Addato F, Attini R, Durando A, Danese S et al. Metaplastic breast carcinoma: pathology and clinical outcome. *Anticancer Res* 2003;23(1B):669-73.