

Clinical, histological and immunohistochemical features of ceruminous adenoma

Dejan Rančić¹, Miško Živić¹, Ivan Ilić², Vuka Katić², Zoran Radovanović³

SUMMARY

Ceruminous gland tumors are infrequent lesions of the external auditory canal (EAC). Controversy exists regarding several aspects of these tumors. In this report we presented a case of 63 years old woman with an 8-year history of a painless mass in the left EAC. Physical examination showed a skin-covered mass, occupying all its lumen. First superficial biopsy led to an initial erroneous diagnosis of papilloma. Local wide resection of the lesion was performed one month later. Histological examination revealed a lesion composed of solid nests and papillomatous and cystic glands surrounded by a hyaline sheath. Immunohistochemically, two different cell layers were demonstrated: a luminal epithelial cell layer with positive staining with cytokeratin 7 (CK7) and an outer myoepithelial cell layer, with positive staining with actin and S-100 protein. The proliferative index (Ki-67) was very low. The diagnosis was ceruminous gland adenoma. Two years after the operation, the patient is in good health and with normal ultrasound and laboratory results. We believe that conservative surgery seems to be ideal treatment in case of ceruminous adenoma.

Key Words: Adenoma; Ear Canal; Cerumen; Adenoma, Sweat Gland; Immunohistochemistry; Keratins; S100 Proteins; Ki-67 Antigen

INTRODUCTION

The ceruminous glands are modified apocrine glands, confined to the skin lining of the cartilaginous part of the external auditory meatus (1-4). Together with sebaceous glands they produce the cerumen, the ear wax. Cerumen plays an important role in the protection of the ear canal against physical damage and microbial invasion (5). Tumors arising from these glands are extremely rare and with benign clinical behavior (6-9). Less than 150 cases have been reported to date (3,5,8,9). Controversy still exists regarding the nomenclature *ceruminoma*, classification, tissue of origin, accurate diagnosis and management of these tumors (1,2,4,9,11). The pointed facts and unpredictable clinical behavior of ceruminous adenoma are induced the following report.

CASE REPORT

A 63-year-old woman presented with an 8-year history of a painless mass in the left EAC. She had no hearing loss, discharge, vertigo, or tinnitus. No history of traumas, hearing aids or surgery was noted. The only significant patient's data was the burn of the external auditory canal (EAC) with lime, eight years ago. Physical examination showed a 1.2 x 0.5 cm a skin-covered nonulcerated mass from the connection of posterior and superior portion of the left EAC, occupying all its lumen. A coronal CT revealed a soft lesion occupying the EAC with no signs of bone destruction. First superficial biopsy led to an initial erroneous diagnosis of papilloma. Second, a wide local resection of the lesion, was performed, one month later. Histological examination revealed a lesion composed of solid nests, or papillomatous and cystic glands of epithelial cells surrounded by a hyaline sheath (Figure 1). Histological examination also showed proliferation of well-differentiated ceruminous glands with no capsule, separating the adjacent normal tissue (Figure 2). Surface involvement was not seen. Two different cell layers were demonstrated by histochemical labeled streptavidin-biotin (LSAB) method: a luminal epithelial cell layer with positive staining with cytokeratin 7 (CK7) (Figure 2), and an outer myoepithelial cell layer, with positive staining with actin and S-100 protein (Figure 3). The proliferative index (Ki-67) was very low (<3%). The diagnosis was ceruminous gland adenoma. Two years later there was no evidence of recurrence.

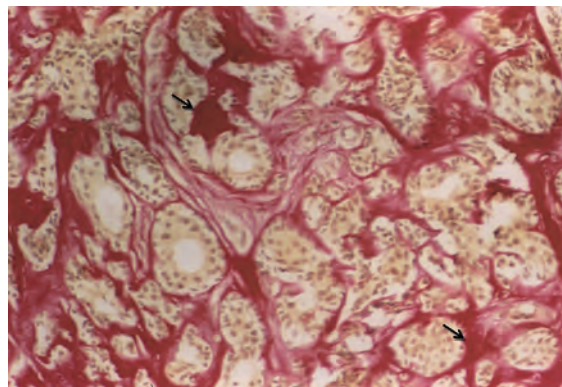


Figure 1. Ceruminous adenoma: adenomatous proliferation of epithelial cells surrounded by a hyaline sheath (arrows). Van Gieson x 250

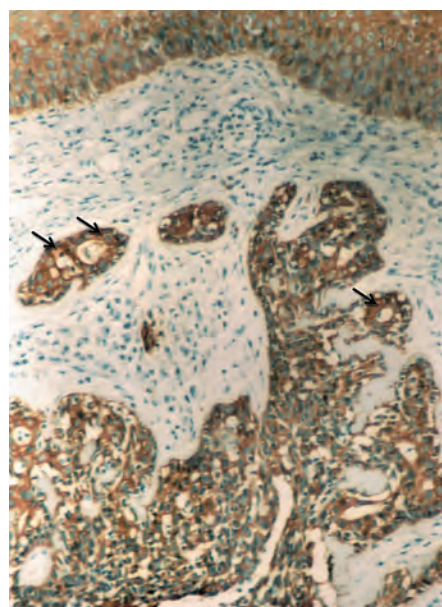


Figure 2. Proliferation of well-differentiated ceruminous glands with no capsule, separating the adjacent normal tissue with positive CK7 staining for epithelial cells (arrows). LSABx200

Arch Oncol 2007;15(3-4):89-90.

UDC: UDC:

617.7-006:611.774:616-091.8

DOI: 10.2298/A000704089R

¹Clinic of Otorhinolaryngology, Medical Faculty Niš, Serbia,

²Institute of Pathology, Medical Faculty Niš, Serbia,

³Institute of Radiology, Medical Faculty Niš, Serbia.

Correspondence to:

Dejan Rančić, Miloša Crnjanskog 9,

18000 Niš, Serbia

E-mail: dsrancic@ptt.yu

Received: 14.11.2007

Provisionally accepted: 20.11.2007

Accepted: 14.12.2007

© 2007, Oncology Institute of Vojvodina, Sremska Kamenica

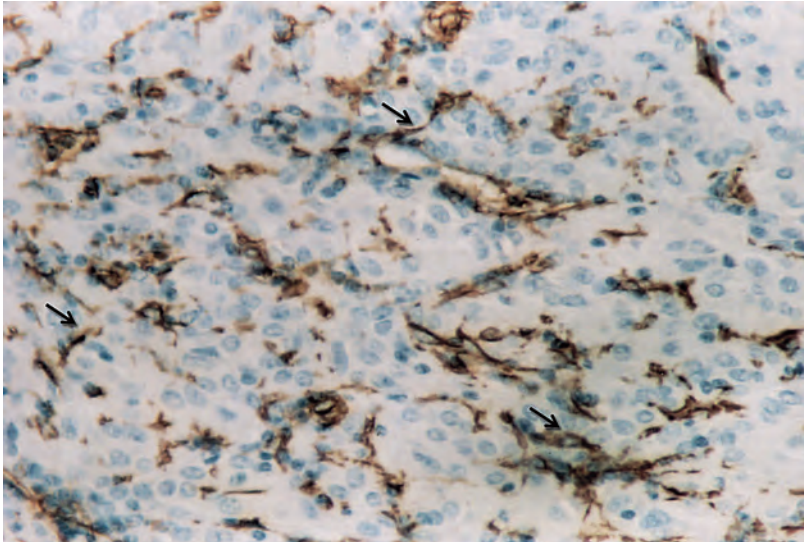


Figure 3. Myoepithelial cell layer positive staining with S-100 protein (arrows). LSABx300

DISCUSSION

Ceruminous glands are modified sweat glands, confined to the skin of the cartilaginous part of the external auditory canal. Tumors arising from these glands are extremely rare and resemble those arising from sweat glands elsewhere in the body (2,9,11,12). Wetli et al. (1972) indicated that malignant tumors out-number benign (2.5:1) with equal male to female distribution. Clinically, these tumors may have a long history and many years may lapse before presentation (2,3,7,8) that has been confirmed by our case.

The pathology of ceruminous gland tumors is not well described in standard pathology texts as they fall between the fields of dermatology and ear, nose and throat pathology (ENT) (4,5). Confusion exists regarding the nomenclature „ceruminoma“, a term which misleadingly suggests a benign adenoma of ceruminous glands when over half of such tumors are, in fact, malignant (2,3). Further confusion exists from the use in the older literature of the term *cylindroma* for a lesion that would now be referred to as adenoid cystic carcinoma (7). The most important confusion there is between ceruminous adenoma and ceruminous well-differentiated adenocarcinoma (11,12). So, in contrast to adenomas that do not show significant cytological atypia and mitotic activity and that have well-circumscribed margins, a well-differentiated adenocarcinomas show an infiltrating margin or any evidence of perineural invasion (2). Ceruminous gland adenomas demonstrate a dual cell population of basal myoepithelial-type cells and luminal ceruminous cells. Both diffusely and strongly immunoreactivity with CK7 of the luminal cells and with actin and S-100 protein of the basal myoepithelial-type cells, helps us to distinguish this tumor from other neoplasms that occur in the region.

Conflict of interest

We declare no conflict of interest.

REFERENCES

- 1 Iqbal A, Newman P. Ceruminous gland neoplasia. *Br J Plast Surg.* 1998;51:317-20.
- 2 Lassaletta L, Patron M, Oloriz J, Perez R, Gavilan J. Avoiding misdiagnosis in ceruminous gland tumors. *Auris Nasus Larynx.* 2003;30(3):287-90.
- 3 LeBoit PE. Appendageal skin tumors. In: LeBoit, Burg G, Weedon D, Sarasin A, editors. *Pathology and Genetics – Skin tumors.* IARC Press Lyon; 2006. p. 123-24.
- 4 Mansour P, George MK, Pahor AL. Ceruminous gland tumors: a reappraisal. *J Laryngol Otol.* 1992;106:727-32.

- 5 Rancić D, Mihajlović D, Mijović Ž. Mucoepidermoid carcinoma of the external auditory canal – A case report. *Arch Oncol.* 2003;11(1):281-3.
- 6 Stoeckelhuber M, Matthias C, Andratschke M, Stockelhuber BM, Koehler C, Herzmann S, et al. Human ceruminous glands: ultrastructure and histochemical analysis of antimicrobial and cytoskeletal components. *Anat Rec A Discov Mol Cell Evol Biol.* 2006;288(8):877-84
- 7 Mills RG, Douglas-Jones T, Williams RG. 'Ceruminoma' - a defunct diagnosis. *J Laryngol Otol.* 1995;109:180-8.
- 8 Namyslowski G, Sciersky W, Misiolek M, Czecior E, Lange D. Ceruminous gland adenoma of the external auditory canal: a case report. *Otolaryngol Pol.* 2003;57(5):755-9.
- 9 Thompson LD, Nelson BL, Barnes EL. Ceruminous adenoma: a clinicopathologic study of 41 cases with a review of the literature. *Am J Surg Pathol.* 2004;28(3):308-18.
- 10 Wetli CV, Pardo V, Millard M, Gerston K. Tumors of ceruminous glands. *Cancer.* 1972;29:1169-78.
- 11 Elsürer C, Senkal HA, Baydar DE, Sennaroglu L. Ceruminous adenoma mimicking furunculosis in the external auditory canal. *Eur Arch Otorhinolaryngol.* 2007;264(3):223-5.
- 12 Mashkevich G, Undavia T, Iacob C, Arigo J, Linstrom C. Malignant cylindroma of the external auditory canal. *Otol Neurotol.* 2006;27(1):97-101.