

Iatrogenic Ureteral Trauma: A 16-Year Single Tertiary Centre Experience

Dragoslav Bašić^{1,2}, Ivan Ignjatović^{1,2}, Milan Potić^{1,2}

¹Clinic of Urology, Clinical Center Niš, Niš, Serbia;

²University of Niš, Faculty of Medicine, Niš, Serbia

SUMMARY

Introduction Iatrogenic ureteral injuries can occur during various abdominopelvic and retroperitoneal surgical procedures including gynecological, urological, colorectal and vascular.

Objective The aim of our study was to examine the incidence and types of iatrogenic ureteral injuries occurred over the period of 16 years, as well as to evaluate the values of applied diagnostic and therapeutic procedures.

Methods A retrospective analysis of clinical data (medical records and operative reports) of 55 patients (11 male and 44 female; mean age 54.5 years) with verified iatrogenic ureteral injury from 1998 to 2014, was performed.

Results Iatrogenic ureteral injuries occurred during gynecological procedures in 55%, urological in 25%, colorectal in 15% and vascular in 5% of cases. Mechanisms of injury were incomplete transection (n=23), complete transection (n=1), ligation (n=7), partial perforation (mucosal abrasion) (n=13) and total perforation (n=1). The most frequent diagnostic procedures for postoperative identification of ureteral injuries were abdominal ultrasonography, excretory urography, antegrade pyeloureterography and retrograde ureteropyelography. Early therapeutic procedures were applied in 35 (64%), while delayed in 20 cases (36%). Early (<30 days) or late (>30 days) postoperative complications were verified in 14 cases (25%).

Conclusion Among different surgeries that may lead to the development of iatrogenic ureteral injury, gynecological procedures represent the most common cause. Rapid diagnosis enables immediate ureteral repair and is associated with low morbidity rates, representing a major factor contributing to the treatment success and ultimately preserving the renal function.

Keywords: iatrogenic ureteral injury; diagnostics; treatment

INTRODUCTION

Injuries to the ureter whether from the external or iatrogenic trauma are very rare and account for 1%-2.5% of all urinary tract traumas [1]. Retroperitoneal anatomic position of the ureter, as well as its mobility and flexibility, enable good protection from external trauma. In the majority of cases (>90%), either a partial or total ureteral injury is due to penetrating trauma, predominantly gunshot wounds and is often associated with collateral damage to other abdominal and retroperitoneal structures. Blunt trauma rarely occurs [2]. Iatrogenic ureteral injuries are more frequent and are usually isolated. The most common causes include complications of abdominopelvic procedures like gynecological, endourological, urological, vascular and colorectal, whether open or laparoscopic [3, 4, 5]. The mechanisms of operative injury to the ureter encompass partial or complete clamping, suture ligation, incomplete or complete transection, ureteral angulations with secondary obstruction, ureteral ischemia due to excessive denudation or electro coagulation, and partial or total perforation. Risk factors include re-do surgery, advanced tumors, inflammation, Ormond's disease, previous irradiation, ureteral duplication, and renal ectopia. The symptoms may appear immediately or after some delay [6, 7, 8].

OBJECTIVE

The aim of our study was to investigate the incidence and types of iatrogenic ureteral injuries over the period of 16 years, as well as to evaluate the value of applied diagnostic and therapeutic procedures.

METHODS

During the period January 1998 – January 2014 a total of 55 patients (11 male and 44 female), mean age 54.5 years (range 19-72 years), were verified with iatrogenic ureteral injury at the Urological Clinic of Clinical Center Niš. In this retrospective study, the medical records and radiographic studies of all patients were reviewed. For the purpose of the study, any adverse or inattentive injury to ureter during any surgical procedure, whether urological, gynecological, colorectal or vascular, was considered iatrogenic ureteral injury. All injuries were identified and verified by the urologist and necessitated some of the following procedures: intraoperative ureteral repair, postoperative endourologic or open urologic procedure. Iatrogenic ureteral injuries were classified by the affected ureteral segment (lumbar, iliac, pelvic), the type of surgical procedure that caused the

Correspondence to:

Dragoslav BAŠIĆ
Clinic of Urology
Clinical Center
Bulevar dr Zorana Djindjića 48
18000 Niš
Serbia
basicdr@gmail.com

injury as well as characteristics and mechanisms of iatrogenic injury by the type of the procedure. Diagnostic and therapeutic procedures were analyzed depending on the time of performance, as early – intraoperative or immediate – postoperative (<24 hours) and delayed procedures. Surgical complications were assessed by the type of the procedure and the time of appearance. Statistical analysis was done using Chi-square and Fisher's exact tests for variables comparison. P values of 0.5 were considered statistically significant.

RESULTS

A total of 55 patients were diagnosed with iatrogenic ureteral injury. In respect of the anatomic localization of the injury, the lumbar ureter was affected in 5 (9%), iliac in 13 (24%) and pelvic in 37 cases (67%).

Iatrogenic ureteral injuries occurred during the following surgical procedures: gynecological, urological, colorectal and vascular. Iatrogenic ureteral injuries by etiology are summarized in Table 1.

Mechanisms of iatrogenic ureteral injuries included: incomplete transection (23 cases) (Figure 1), complete transection (11 cases), ligation (7 cases), partial perforation (mucosal abrasion) (13 cases) and total perforation (1 case). Table 2 shows characteristics and mechanisms of iatrogenic ureteral injury by the type of the procedure.

Intraoperative or immediate postoperative procedures for iatrogenic injuries were applied in 35 cases and are summarized in Table 3.

Table 1. Etiology of iatrogenic ureteral injuries

Surgery	Number of patients	%
Gynecological	30	55
Urological	14	25
Colorectal	8	15
Vascular	3	5
Total	55	100

Table 2. Characteristics and mechanisms of iatrogenic ureteral injury by the type of the procedure

Procedure	Gynecological	Urological	Colorectal	Vascular	Total
Incomplete transection	20	-	2	1	23
Complete transection	7	-	2	2	11
Ligation	7	-	-	-	7
Partial perforation	-	13	-	-	13
Total perforation	-	1	-	-	1
Total	34	14	4	3	55

Table 3. Intraoperative or immediate postoperative procedures

Procedure	Gynecological		Urological		Colorectal		Vascular		Total
	Early	Late	Early	Late	Early	Late	Early	Late	
Incomplete transection	3	17	-	-	2	-	1	-	23
Complete transection	6	-	-	-	2	-	2	1	11
Ligation	5	2	-	-	-	-	-	-	7
Partial perforation	-	-	13	-	-	-	-	-	13
Total perforation	-	-	1	-	-	-	-	-	1
Total	14	19	14	-	4	-	3	1	55

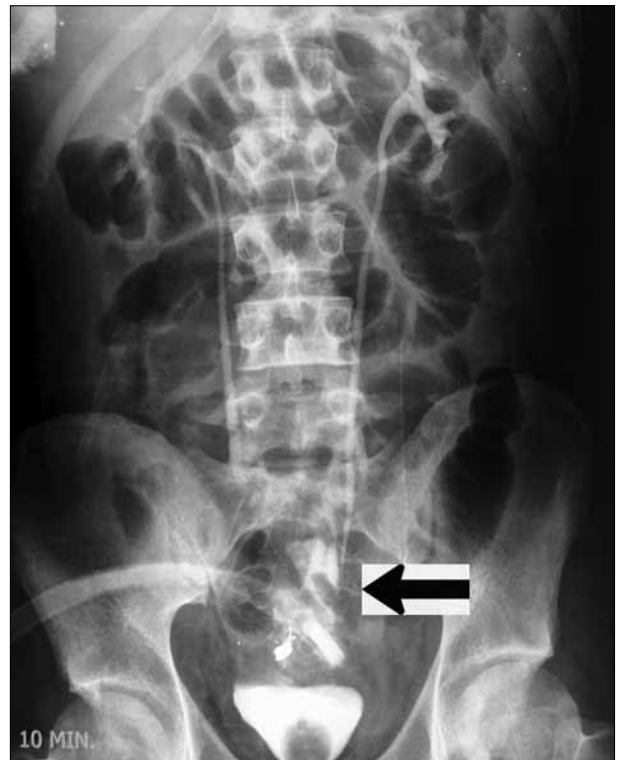


Figure 1. Excretory urogram on the 1st postoperative day shows urinary extravasation due to incomplete ureteral transection

Surgical procedures for ureteral repair were performed in all cases. Depending on the type, extent and localization of the injury, early (<24 h) or delayed treatment were applied.

Early treatment was applied in 35 (64%) (Table 4).

All cases (n=20) with intraoperatively recognized injury underwent primary repair. In 15 cases, during the immediate postoperative period, the diagnosis was established by abdominal ultrasonography, excretory or multislice computer tomography (MSCT) and excretory urography. Additional antegrade pyeloureterography was performed in all cases with percutaneous nephrostomy and retrograde

Table 4. Early treatment

Procedure	Gynecological	Urological	Colorectal	Vascular	Total
Suture+DJ	2	-	1	1	4
UUS	-	1	1	1	3
PCN	5	9	-	-	14
UCN dir.	4	-	2	-	6
Psoas hitch	2	-	-	1	3
Boari	1	-	-	-	1
DJ	-	4	-	-	4
Total	14	14	4	3	35

UUS – ureteroureterostomy; PCN – percutaneous nephrostomy; UCN dir. – direct ureteroneocystostomy; DJ – double J stent

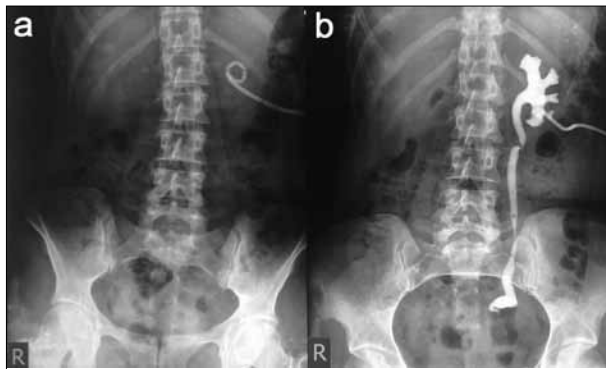


Figure 2. (a) Left-side percutaneous nephrostomy tube due to ureteral ligation; (b) Antegrade pyeloureterogram shows left pelvic ureteral ligation site

ureteropyelography in cases with ureteroscopic ureteral injury (Figure 2a,b).

Ureteral suture (primary closure) with double J stenting was performed in four cases with incomplete ureteral transection (two gynecological, one colorectal and one vascular). Uretero-ureterostomy was performed in three cases after complete ureteral transection (one due to urological, one due to colorectal and one due to vascular surgery). In 14 cases, percutaneous nephrostomy was applied due to ureteral ligation because of gynecological procedure (n=5) or partial perforation (mucosal abrasion) due to endoscopic urological interventions (n=9). Of these, 5 cases with percutaneous nephrostomy after gynecological ligation underwent further (delayed) treatment. In the remaining 9 urological cases, since ureteral damage had resolved after 2-4 weeks, percutaneous nephrostomy had been extracted. Ureteroneocystostomy was undertaken in 10 cases, seven after gynecological (five with complete and two with incomplete ureteral transection), two after colorectal (one with complete and one with incomplete ureteral transection) and one after vascular surgery (due to complete transection). In one case a complete ureteral transection was overlooked during a colorectal procedure, and during the early postoperative period urinary drainage was the indication for revision and ureteroneocystostomy. By the type of the ureteroneocystostomy procedure, Lich-Gregoire was applied in six, psoas bladder hitch in three and Boari flap in one case. In all cases ureteral stenting by double J stent was performed during the procedure. Double J stenting for 4-6 weeks was used in four cases with a partial ureteral perforation (mucosal abrasion) due

to endoscopic urologic instrumentation. In all of them it was successful treatment option.

In the remaining 25 cases with iatrogenic trauma (including five with temporary percutaneous nephrostomy due to ureteral ligation), delayed operative treatment was applied. Diagnosis was established by radiographic studies, including MSCT urography with additional retrograde ureteropyelography for assessing the length of ureteral stump. Antegrade pyeloureterography was performed in all cases with temporary percutaneous nephrostomy tube.

Delayed procedures included ureteroneocystostomy (Lich-Gregoire, psoas bladder hitch or Boari flap), ureteral reconstruction by ileal segment interposition and nephrectomy (Table 5).

Ureteroneocystostomy was applied in a total of 21 cases (16 with ureterovaginal fistula due to incomplete ureteral transection and five with ligated ureter and temporary percutaneous nephrostomy). Direct ureterovesical anastomosis (Lich Gregoire) was performed in 15 cases (12 with ureterovaginal fistula due to incomplete ureteral transection during gynecological procedures and three with ligated ureter). Psoas bladder hitch technique was applied in three cases (two with incomplete ureteral transection and one with ligated ureter), while the Boari flap in the remaining three cases (two with incomplete ureteral transection and one with ligated ureter). In all cases, intraoperative a double J stent placement was performed. Double J stent was exteriorized at 21st postoperative day. In two cases, since ureteral ligation after gynecological procedure was detected late with grade IV hydronephrosis and severe deterioration of renal function, nephrectomy was done. In one case, nephrectomy was performed due to a complicated post-radiation urinary fistula. In one case, due to a high ureteral position of the fistula after incomplete transection, ileal ureteral reposition was applied (Figure 3).

Table 5. Delayed operative procedures

Procedure	Gynecological	Urological	Total
UCN dir.	15	-	15
Psoas hitch	3	-	3
Boari	3	-	3
Nephrectomy	3	-	3
Ileum	1	-	1
Total	25	-	25

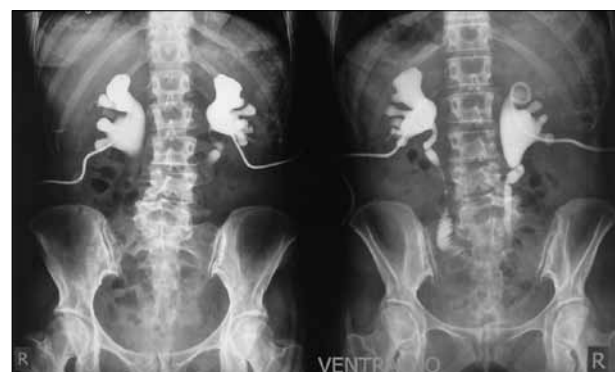

Figure 3. Bilateral antegrade pyeloureterography shows good renal drainage after ileal ureteral replacement

A total of 14 cases (25%) were verified with early (<30 days) or late (>30 days) postoperative complications.

After intraoperative or immediate postoperative procedures, of 35 cases surgical complications were verified in four (11%). Of these, there were two cases of gynecological origin (both with direct ureteroneocystostomy Lich Gregoire), one colorectal (postoperative urinoma) and one vascular (stenosis at the ureteroureterostomy anastomotic site). One gynecological case developed stenosis of ureteroneocystostomy so that a re-do surgery was performed successfully (re-ureteroneocystostomy Lich-Gregoire). Due to early postoperative double J stent migration in the second case, endoscopic replacement of the stent was performed. In the colorectal case with ureteroneocystostomy, urinoma was verified due to double J stent obstruction and the stent was replaced. There was one case with late stenosis at the ureteroureterostomy anastomotic site, following by the loss of ipsilateral renal function. In this case, nephrectomy was performed.

Major late complications were observed in five cases (20%); three with gynecological origin (one stenosis of ureteroneocystostomy and two prolonged drainage due to urinary extravasation) and two with urological origin (one urinoma due to double J stent obstruction and one lumbar ureteral stenosis at the ureteroureterostomy anastomotic site). In a case with neocystostomy (UNC) stenosis, the re-do surgery with reureteroneocystostomy Lich-Gregoire was performed successfully, while in the remaining two cases with gynecological origin of urinary extravasation that ceased after prolonged drainage. Urinoma in the urologic group discontinued after a double J stent replacement. In the case of late lumbar ureteral stenosis following ureteroureterostomy after complete ureteral perforation, a renal autotransplantation was performed.

Compared to early, delayed diagnosis and treatment were associated with higher major surgical complication rate, but the difference is not statistically significant ($\chi^2=0,458$; Fisher = 0.3489).

DISCUSSION

In 1868, Alfred Poland described ureteral avulsion in a young women and it was the first report on ureteral trauma [9]. Later, in 1904, the first ureteral procedure was described by Henry Morris [10].

Iatrogenic ureteral injuries are usually caused by abdominopelvic surgery including gynecological, urological, colorectal or vascular procedures, with reported incidence between 0.3% and 10% in most series [4, 11, 12]. With regard to the type of surgical procedure, the majority of more than 50% of all ureteral injuries arises from gynecological surgery, with general surgery traditionally accounted as a second frequent cause with the reported incidence of 5-15%. Nevertheless, the latest reports demonstrate that improvements in gynecological and general surgical operative techniques have made it possible to reduce the incidence of ureteral injuries.

However, in recent years a widespread use of minimally invasive endoscopic and laparoscopic, as well as anti-incontinent procedures have increased urologically-induced ureteral trauma. It has been reported that urological procedures share 30% of all iatrogenic ureteral injuries [5, 13-16].

There are three groups of risk factors for iatrogenic ureteral injury: anatomical, anatomic-pathological and technical. Few normal anatomical circumstances complicate intraoperative identification of the ureter including ureteral adherence to the parietal peritoneum and its similarity to adjacent structures such as the lumbo-ovarian ligament and uterine artery. However, the ureter can be easily mistaken and transected or ligated. Moreover, since it is poorly vascularized by terminal arterial branches, it is highly vulnerable to stripping and any vascular periureteral damage can induce avascular necrosis, which usually becomes manifest a few days after surgery. The anatomic-pathological risk factors, as aforementioned, include the presence of congenital anomalies, retroperitoneal or pelvic tumors, uterine prolapse, endometriosis, previous surgery or radiation therapy. Numerous technical factors can increase the risk of ureteral injury. Some of these are associated injuries of abdomen or retroperitoneum, bleeding in the operating field that complicates the identification of ureter, blind clamping for hemostasis, the presence of advanced tumors, and inexperienced surgeons [17].

Iatrogenic ureteral injuries most commonly affect distal one third and pelvic ureter. It is consistent to our experience, since the lumbar ureter was affected in 9%, while in the remaining 91% it was ilio-pelvic segment [3, 6].

In our series, gynecological surgery accounts for 54% of all iatrogenic injuries, followed by urological, colorectal and vascular procedures, which is similar to pooled data from most studies [6, 7, 11]. The overall incidence of ureteral injuries due to gynecological surgery is 1.6 per 1000 procedures [3].

Diagnosis of ureteral injuries depends on the type and the extent of injury. Although the recognition of injury and the diagnostic procedure are typically delayed, the most preferred is early (intraoperative) diagnosis, if possible. Despite some controversies regarding the time of repair, it has been approved by most authors since late identification is commonly associated with high rates of complications including the loss of the renal unit [5, 18, 19].

Dobrowski et al. [3], reported that only 11.5% of all iatrogenic ureteral injuries are diagnosed and managed intraoperatively. However, 70%-80% of iatrogenic injuries are diagnosed with a delay [20].

During open surgery, urinary extravasation in the operative field represents the most obvious event that enables easy recognition of ureteral injury. If it is not possible to identify the exact site of extravasation, intravenous administration of indigo carmine along with Lasix, or on-table excretory urography could be useful. In case of suspected ureteral ligation, it should be explored and deliberated from the ligature or clip. Afterwards, ureteral viability should be inspected. If it does not provide sufficient information, a retrograde ureteral catheterization through the

cystotomy should be attempted. In cases of partial ureteral transection, a primary repair by direct suture or spatulated anastomosis over the double J stent is recommended.

However, the degree of early iatrogenic injury recognition depends on the type of the procedure. Since the high suspicion index of injury is present in ureteroscopy, this procedure is associated with a high degree of early injury recognition. During the last two decades, the growing experience of urologists performing ureteroscopic procedures along with novel instruments have led to a dramatic decrease of iatrogenic injuries [21, 22, 23]. Nevertheless, most laparoscopy-induced ureteral injuries are still lately recognized [24-28].

Late recognition of injury is often associated with symptoms including fever, flank pain, hematuria, ileus or urinary fistula. If symptoms are present, urinary tract ultrasound should be done as a first choice tool. It can show the presence of hydronephrosis or urinoma. Although rare, bilateral ureteral injuries produce anuria, which can be easily recognized. In our series ultrasound was very useful since it can provide quick and non-invasive diagnosis. Besides, ultrasound-guided percutaneous nephrostomy can be easily performed as a temporary therapeutic solution enabling additional diagnostic procedures. It includes antegrade pyeloureterography (to assess ureteral injury) or ureteral stent placement. In our series, percutaneous nephrostomy was applied in the majority of cases and we strongly support it regarding all aforementioned advantages. The use of percutaneous nephrostomy in the initial diagnosis and/or treatment has been proposed by several authors [3, 6].

In the presence of symptoms, if ultrasound does not provide sufficient data, MSCT urography is preferred, since some authors have reported a low diagnostic value of excretory urography and frequent false-negative results [29]. However, any uncertainties from excretory urography require further investigation. It includes retrograde ureteropyelography. According to our experience which is consistent with several reports, it is a sensitive and specific tool in assessing characteristics of injury, such as the level and degree. Nonetheless, it could have therapeutic effect if the stent is placed safely and appropriate [30, 31, 32].

In our series, early diagnosis and treatment were applied in 35 cases (64%), 17 intraoperatively and 18 immediate postoperatively. Of these, 14 cases underwent percutaneous nephrostomy during the immediate postoperative period (<24 hours). Five of them (gynecological origin) were operated by delayed procedures while the rest of nine cases were with a nephrostomy tube without complications. Early identification of ureteral injury was carried out intraoperatively in 17 cases due to urine leak recognition (incomplete transection of dilated ureter - six cases; complete ureteral transection - 10 cases; total ureteral perforation - one case). In these cases, immediate ureteral repair was performed using the following urologic procedures: ureteral suture in four, end-to-end uretero-ureterostomy in three (with ipsilateral renal mobilization in one), Lich-Gregoire ureteroneocystostomy in six, psoas bladder hitch in three and Boari flap in one case. In all cases, the double J catheter stenting was performed along

with the procedure. As proposed by Koukuras et al. [33], we selected four cases for endourologic treatment of mucosal abrasion with double J stenting and it was a definite and successful treatment option.

In the remaining 18 cases, the diagnosis was established during the immediate postoperative period by renal ultrasound, MSCT urography and/or retrograde ureteropyelography. Intraoperative primary ureteral repair is reported to be in 30% of cases [34]. In a recent report by Papanikolaou et al. [35] more than half ureteral injuries during hysterectomy have been identified intraoperatively with a consequent primary repair.

In our series, a total of 20 (36%) cases were diagnosed with a delay. In all, including five with temporary percutaneous nephrostomy due to ureteral ligation, there were a total of 25 cases who underwent delayed operative treatment. Delayed procedures included ureteroneocystostomy (Lich-Gregoire, psoas bladder hitch or Boari flap), ureteral reconstruction by ileal segment interposition and nephrectomy. Ureteroneocystostomy was applied in a total of 21 cases (16 with ureterovaginal or ureterocutaneous fistula due to incomplete ureteral transection and five with ligated ureter and temporary percutaneous nephrostomy). As aforementioned, in three cases, nephrectomy was done and in one case ileal ureteral reposition was applied. According to our experience, delayed diagnosis and treatment were associated with a higher major surgical complication rate, but the difference is not statistically significant.

It has been reported that maintaining a high index of suspicion along with full recognition of predisposing pathology are of utmost importance for managing ureteral injuries, since urine analysis and imaging studies are often unsafe [3].

Several studies have shown that the majority of lower ureteral iatrogenic injuries are caused by clamping or transection and do not produce extensive ureteral defects [36]. Cormio et al. [37] noted 25 mm (range 5 to 50 mm) as the average length of iatrogenic ureteral injury in their series. Utrie et al. [38] proposed ureteral reimplantation if the length of distal ureteral defect was up to 50 mm from its bladder entry. Nevertheless, several authors proposed end-to-end ureterostomy over the double J stent in all cases with 20-25 mm length of distal ureteral stump. In addition, they consider that at least 60 mm of the ureteral defect can be compensated by renal mobilization, allowing regular tension free anastomosis [39]. In order to assess the distal ureteral stump precisely, ureteropyelography is strongly recommended [36]. It is widely accepted that ureterocystoneostomy procedures, whether direct, psoas hitch or Boari flap, have demonstrated a great potential for the distal ureteral repair, especially if detected late [4, 31]. In our series, it was confirmed with the low rate of ureteral reimplantation-associated complications.

Undoubtedly, the advantages of ureteroureterostomy include preservation of physiologic antireflux mechanism and intact bladder. Anyhow, it has been emphasized that successful ureteroureterostomy requires a precise diagnosis and strict respect of certain surgical principles [30, 40-43].

In all cases in our series, ureteral repair in the acute setting was performed according to the principles proposed

by Brandes et al. [6] in evidence-based analysis Consensus on Genitourinary Trauma. It includes appropriate ureteral debridement and mobilization, implantation of double J ureteral stent and tension-free anastomosis, isolation of the repaired segment, placement of retroperitoneal drain and performing proximal urinary diversion (if necessary) [6, 36]. Based on these principles, primary repair can be successful in most cases.

Otherwise, it has been proposed that prior to difficult abdominopelvic surgical procedures prophylactic placement of double J stent facilitates identification of the ureter and thus decreases the possibility of potential injuries [12].

Other techniques include ileal loop, renal autotransplantation and transureteroureterostomy, but they have been rarely performed as recorded by published series. In our series, the ileal loop was applied in one case due to a long defect of midureter while renal autotransplantation was applied in one case due to a long upper ureteral defect. The rate of nephrectomy, performed in 3/55 cases (5%) from our series is consistent with large published series [5, 12].

REFERENCES

- Summerton DJ, Djakovic N, Kitrey ND, Kuehhas FE, Lumen N, Serafetinidis E, et al. Guidelines on urological trauma. In: EAU Guidelines. Arnhem (The Netherlands): European Association of Urology (EAU); 2014. p.30-33.
- Elliot SP, Mc Aninch JW. Ureteral injuries from external violence: the 25-year experience at San Francisco General Hospital. *J Urol.* 2003; 170(4 Pt 1):1213-6.
- Dobrowolski Z, Kusionowicz J, Drewniak T, Habrat W, Lipczyński W, Jakubik P, et al. Renal and ureteric trauma: diagnosis and management in Poland. *BJU Int.* 2002; 89(7):748-51.
- St Lezin MA, Stoller ML. Surgical ureteral injuries. *Urology.* 1991; 38(6):497-506.
- Selzman AA, Spirnak JP. Iatrogenic ureteral injuries: a 20-year experience in treating 165 injuries. *J Urol.* 1996; 155(3):878-81.
- Brandes S, Coburn M, Armenakas N, McAninch J. Diagnosis and management of ureteric injury: an evidence-based analysis. *BJU Int.* 2004; 94(3):277-89.
- Pfitzenmaier J, Gilfrich C, Haferkamp A, Hohenfellner M. Trauma of the ureter. In: Hohenfellner RAS, editor. *Emergencies in Urology.* New York, NY: Springer; 2007. p.233-45.
- Delacroix Jr SE, Winters JC. Urinary tract injuries: recognition and management. *Clin Colon Rectal Surg.* 2010; 23:104-12.
- Poland A. On rupture of the ureter. *Guy's Hospital Reports.* 1869; 14(85):189-90.
- Morris HC. *Surgical Diseases of the Kidney.* Philadelphia: Lea Brothers & Co; 1904.
- Liapis A, Bakas P, Giannopoulos V, Creasas G. Ureteral injuries during gynecological surgery. *Int Urogynecol J.* 2001; 12:391-3.
- Al-Awadi K, Kehinde EO, Al-Hunayan A, Al-Khayat A. Iatrogenic ureteric injuries: incidence, aetiological factors and the effect of early management on subsequent outcome. *Int Urol Nephrol.* 2005; 37(2):235-41.
- Assimos DG, Patterson LC, Taylor CL. Changing incidence and aetiology of iatrogenic ureteric injuries. *J Urol.* 1994; 152: 2240-6.
- Stoller ML, Wolf JS Jr. Endoscopic ureteral injuries. In: McAninch JW, editors. *Traumatic and Reconstructive Urology, Chapter 15.* Philadelphia: WB Saunders Co; 1996. p.199-212.
- Preston JM. Iatrogenic ureteric injury: common medicolegal pitfalls. *BJU (Inter).* 2000; 86:313-7.
- Meng MV, Freise CE, Stoller ML. Expanded experience with laparoscopic nephrectomy and autotransplantation for severe ureteral injury. *J Urol.* 2003; 169:1363-7.
- Cirstoiu M, Munteanu O. Strategies of preventing ureteral iatrogenic injuries in obstetrics-gynecology. *J Med Life.* 2012; 5(3):277-9.
- Blandy JP, Badenoch DF, Fowler CG, Jenkins BJ, Thomas NW. Early repair of iatrogenic injury to the ureter or bladder after gynaecological surgery. *J Urol.* 1991; 146:761-6.
- McGinty DM, Mendez R. Traumatic ureteral injuries with delayed recognition. *Urology.* 1977; 10:115-7.
- Summerton DJ, Kitrey ND, Lumen N, Serafetinidis E, Djakovic N. EAU Guidelines on Iatrogenic Trauma. *Eur Urol.* 2012; 62:628-39.
- Harmon WJ, Sershon PD, Blute ML, Patterson DE, Segou JW. Ureteroscopy: current practice and long-term complications. *J Urol.* 1997; 157:28-32.
- Kramolowsky EV. Ureteral perforation during ureterorenoscopy treatment and management. *J Urol.* 1987; 138:36-8.
- Schuster TG, Hollenbeck BK, Faerber GJ, Wolf JS Jr. Complications of ureteroscopy: Analysis of predictive factors. *J Urol.* 2001; 166:538-40.
- Grainger DA, Soderstrom RM, Schiff SF, Glickman MG, DeCherney AH, Diamond MP. Ureteral injuries at laparoscopy: insights into diagnosis, management, and prevention. *Obstet Gynecol.* 1990; 75:839-43.
- Hung MJ, Huang CH, Chou MM, Liu FS, Ho ES. Ultrasonic diagnosis of ureteral injury after laparoscopically assisted vaginal hysterectomy. *Ultrasound Ob Gynecol.* 2000; 16:279-83.
- Oh BR, Kwon DD, Park KS, Ryu SB, Park YL, Presti JC Jr. Late presentation of ureteral injury after laparoscopic surgery. *Obstet Gynecol.* 2000; 95:337-9.
- Saidi MH, Sadler RK, Vancaillie TG, Akright BD, Farhart SA, White AJ. Diagnosis and management of serious urinary complications after operative laparoscopy. *Obstet Gynecol.* 1996; 87:272-6.
- Tamussino KF, Lang PF, Breinl E. Ureteral complications with operative gynecologic laparoscopy. *Am J Obstet Gynecol.* 1998; 178:967-70.
- Palmer LS, Rosenbaum RR, Gershbaum MD, Kreutzer ER. Penetrating ureteral trauma at an urban trauma center: 10-year experience. *Urology.* 1999; 54:34-6.
- Carlton CE, Scott R Jr, Guthrie AG. The initial management of ureteral injuries: a case report of 78 cases. *Urology.* 1971; 105:340-55.
- Ghali AM, El Malik EM, Ibrahim AI, Ismail G, Rashid M. Ureteric injuries, diagnosis, management, and outcome. *J Trauma.* 1999; 46:150-8.
- Sharfi AR, Ibrahim F. Ureteric injuries during gynecological surgery. *Int Urol Nephrol.* 1994; 26:277-81.
- Koukouras D, Petsas T, Liatsikos E, Kallidonis P, Sdralis EK, Adonakis G, et al. Percutaneous minimally invasive management of iatrogenic ureteral injuries. *J Endourol.* 2010; 24(12):1921-7.

CONCLUSION

Among different surgeries that may lead to the development of iatrogenic ureteral injury, gynecological procedures represent the most common cause. Rapid diagnosis enables immediate ureteral repair and is associated with low morbidity rates, representing a major factor contributing to the treatment success and ultimately preserving the renal function. Regardless of the etiology, iatrogenic ureteral damage is almost always finally addressed to urologist. Hence, it is of utmost importance for surgeons performing procedures within or adjacent to the ureter, to sustain a high index of suspicion, foreseeing potential ureteral injury and therefore facilitate the diagnostic procedure. In cases with delayed diagnosis, urinary leak is commonly managed by percutaneous nephrostomy as a temporary minimally invasive urinary diversion which safely enables further diagnostic and therapeutic approach. Surgical management encompasses a wide range of ureteral reconstructive procedures that can be successfully used depending on the type, extent and localization of the injury.

34. Rock J, Jones A, Howard W. Operative injuries to the ureter: prevention, recognition and management. In: Te Linde's Operative Gynecology, 10th ed. Philadelphia: Williams & Wilkins; 2008. p.961-71.
35. Papanikolaou A, Tsolakidis D, Theodoulidis V, Ioannidis E, Vatopoulou A, Kellartzis D. Surgery for ureteral repair after gynaecological procedures: a single tertiary centre experience. Arch Gynecol Obstet. 2013; 287(5):947-50.
36. Paick JS, Hong SK, Park MS, Kim SW. Management of postoperatively detected iatrogenic lower ureteral injury: should ureteroureterostomy really be abandoned? Int J Urol. 2005; 12(11):976-83.
37. Cormio L, Battaglia M, Traficante A, Selvaggi FP. Endourological treatment of ureteric injuries. Br J Urol. 1993; 72:165-8.
38. Utrie JW. Bladder and ureteral injury: prevention and management. Clin Obstet Gynecol 1998; 41:755-63.
39. Bright TC. Emergency management of the injured ureter. Urol Clin North Am. 1982; 9:285-91.
40. Fry DE, Milholen L, Harbrecht PJ. Iatrogenic ureteral injury. Arch Surg. 1983; 118:454-7.
41. Pearse HD, Barry JM, Fuchs EF. Intraoperative consultation for the ureter. Urol Clin North Am. 1985; 12:423-37.
42. Hamm FC, Weinberg SR. Management of the severed ureter. J Urol. 1957; 77:407-13.
43. Thompson JD. Operative injuries to the ureter: prevention, recognition and management. In: Thompson JD, Rock JA, editors. Te Linde's Operative Gynecology. 7th ed. Philadelphia: JB Lippincott; 1992. p.749-83.

Јатрогене повреде уретера: шеснаестогодишње искуство једног центра терцијарног нивоа здравствене заштите

Драгослав Башић^{1,2}, Иван Игњатовић^{1,2}, Милан Потих^{1,2}

¹Клиника за урологију, Клинички центар Ниш, Ниш, Србија;

²Универзитет у Нишу, Медицински факултет, Ниш, Србија

КРАТАК САДРЖАЈ

Увод Јатрогене повреде уретера могу настати током различитих абдоминално-пелвичних и ретроперитонеалних хируршких захвата, укључујући гинеколошке, уролошке, колоректалне и васкуларне.

Циљ рада Циљ рада је био да се испитају учесталост и врсте јатрогених повреда уретера насталих током 16 година и процени вредност примењених дијагностичких и терапијских поступака.

Методе рада Урађена је ретроспективна анализа клиничких података (историја болести и хируршких извештаја) 55 болесника (11 мушкараца и 44 жена, просечне старости од 54,5 година) с потврђеном јатрогеном повредом уретера током периода 1998–2014. године.

Резултати Јатрогене повреде уретера настале су током гинеколошких захвата код 55% испитаника, уролошких код 25%, колоректалних код 15% и васкуларних код 5% болесника. Механизми повређивања били су: непотпуна трансекција (код 23 испитаника), потпуна трансекција (1), лигату-

ра (7), парцијална перфорација – абразија мукозе (13) и тотална перфорација (1). Најчешћи дијагностички поступци за постоперационо препознавање уретералних повреда били су ултразвучни преглед абдомена, интравенска урографија, антероградна пијелоуретерографија и ретроградна уретеропијелографија. Рани терапијски поступци примењени су код 35 болесника (64%), а одложени код 20 (36%). Ране (до 30 дана) или касне (после више од 30 дана) постоперационе компликације забележене су код 14 испитаника (25%).

Закључак Међу различитим операцијама које могу довести до јатрогених повреда уретера, гинеколошки захвати су најчешћи узрок. Брза и ефикасна дијагностика омогућава непосредну реконструкцију уретера и удружена је с ниским стопама морбидитета, чиме представља главни фактор који доприноси успеху лечења и крајњем очувању функције бубрега.

Кључне речи: јатрогена повреда уретера; дијагностика; лечење

Примљен • Received: 03/06/2014

Прихваћен • Accepted: 18/07/2014