

CBCT analysis of apical distance between second lower premolars, first and second lower molars and mandibular canal

Aleksandra Đeri¹, Nataša Brestovac², Sanja Subotić³, Irena Radman Kuzmanović¹,
Adriana Arbutina⁴, Saša Marin⁵

¹University of Banja Luka, Faculty of Medicine, Division of Dental Diseases, Banja Luka, Republika Srpska;

²Dental Office „Dr Marčeta“, Banja Luka, Republika Srpska;

³University of Banja Luka, Faculty of Medicine, Division of Prosthodontics, Banja Luka, Republika Srpska;

⁴University of Banja Luka, Faculty of Medicine, Division of Orthodontics, Banja Luka, Republika Srpska;

⁵University of Banja Luka, Faculty of Medicine, Division of Oral Surgery, Banja Luka, Republika Srpska

SUMMARY

Introduction Mandibular canal with the associated neurovascular bundle may be closely related to the apices of mandibular teeth. In order to avoid injuries and damages to the inferior alveolar nerve during invasive dental procedures, it is important to know its localization.

The aim of this study was to determine the average vertical distances of the root apices of second premolars, first molars and second molars mesially and distally from the upper projection of the mandibular canal on the sagittal section of CBCT images, and determine if there were statistically significant differences between the age and gender groups.

Material and methods The research was conducted at the Faculty of Medicine of the University of Banja Luka, and the sample consisted of 146 CBCT images of patients. CBCT images were obtained using Planmeca ProMax 3D Mid instrument (Planmeca, Helsinki, Finland) and analyzed using Planmeca Romexis Viewer software. In the sagittal section, the vertical distance from the root apex to the upper projection of the mandibular canal was measured for each examined tooth.

Results The distal root of the first molar (4.88 mm) had the greatest average vertical distance of the root apex from the mandibular canal, and the distal root of the second molar had the smallest average vertical distance (2.76 mm). There was statistically significant difference between certain age groups in the values of individual roots, for the second molar mesially and distally ($p < 0.05$), while for the first molar mesially the value of p was at the limit of significance ($p = 0.05$).

Conclusion The results of this study showed that distal root of the mandibular second molar had the smallest vertical distance from mandibular canal, therefore an extra caution during a root canal treatment and careful planning of oral surgery in this region is recommended.

Keywords: CBCT; mandibular canal; vertical distance of tooth apex; lower premolars; lower molars

INTRODUCTION

Cone-beam computerized tomography (CBCT) is a modern radiological imaging system, designed specifically for use in the maxillofacial region. The system overcomes many limitations of conventional radiography, creating a non-distorted, three-dimensional image of the examined area. It is used in endodontics to determine the morphology and dimensions of root canals, periapical lesions, detection and localization of resorptions, postoperative control and monitoring of treatment outcomes. It is also used in orthodontic treatment, as well as implant prosthodontics, facilitating prosthetic planning, selection of implants and the place of its installation [1, 2, 3]. Also, successful endodontic treatment largely depends on an adequate radiographic method, which should provide critical information about examined teeth and their surrounding

anatomy. Since its beginning, conventional radiography has remained the mainstay of auxiliary diagnostic methods in endodontics.

Data from the literature indicate that there are differences when comparing the distances of the tips of mandibular teeth from mandibular canal in relation to gender and age. However, numerous individual variations of the position of the canal in the mandible can occur, as well as the position of teeth and their mutual relationship [4]. Mandibular canal extends through the lower jaw from the mandibular opening (foramen mandibulae). In most cases, it is bilaterally symmetrical and in the form of one main canal on each side of the mandible, but variations are also possible. The contents of the mandibular canal are inferior alveolar nerve (nervus alveolaris inferior) and blood vessels of the same name. Inferior alveolar nerve is mixed and its terminal branch with its sensitive part

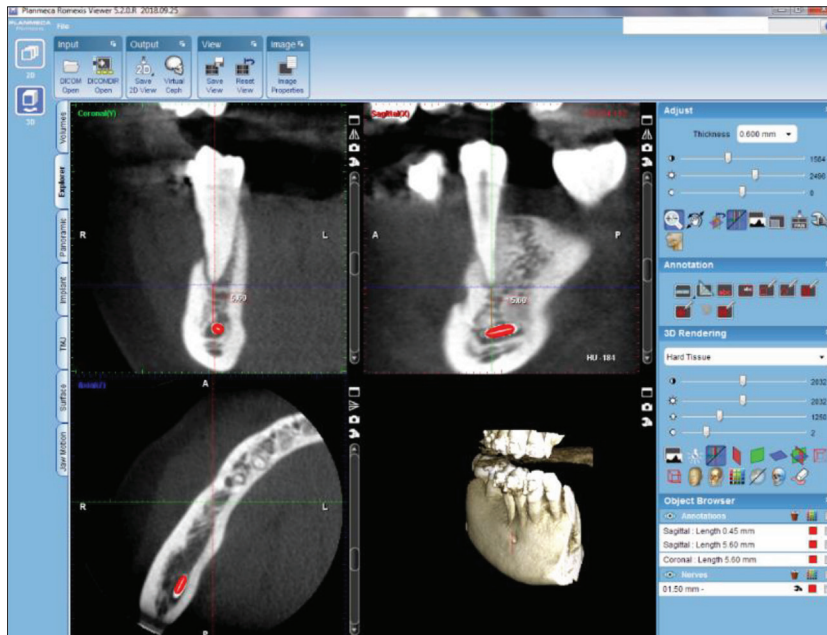

Figure 1. Planmeca Romexis Viewer software
Slika 1. Softver Planmeca Romexis Viewer

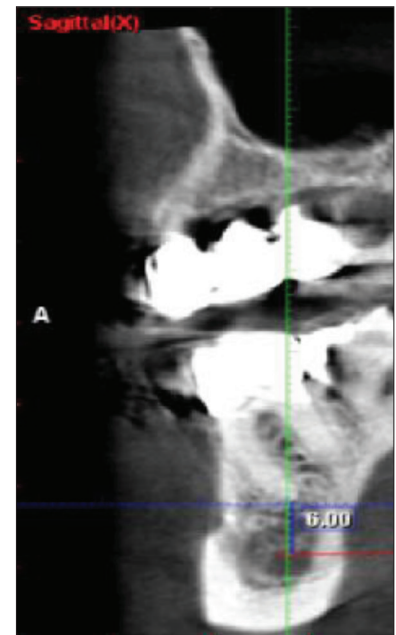


Figure 2. Measuring the distance between canal and a tooth; sagittal 3D image
Slika 2. Merenje udaljenosti kanala od zuba; sagitalni 3D snimka

innervates teeth and gums of the lower jaw, while motor part controls mylohyoid muscle and anterior belly of digastric muscle [5, 6].

Many authors have confirmed that iatrogenic injuries of the inferior alveolar nerve are common (64.4%). Therefore, it is necessary to know the exact location of the mandibular canal and its contents for adequate endodontic treatment of lower posterior teeth as well as adequate resection of their root tips. Endodontic treatment includes mechanical use of instruments combined with chemical irrigation, medication agents and materials for final obturation of the canal system. During all these phases, the occurrence of unwanted complications is possible - mechanical, chemical or thermal injury to the nerve that can cause neuropathic pain or anesthesia in its innervation zone. During endodontic treatment of 1% of lower premolars and even 10% of the lower second molars there is possibility of an injury to lower alveolar nerve. Injury to the content of the mandibular canal is also possible during oral surgery. Such injuries sometimes require treatment in the form of microsurgical decompression of the inferior alveolar nerve [7–10].

The aim of this retrospective study was to determine the average vertical distances of the root apices of second premolars, first molars and second molars mesially and distally from the upper projection of the mandibular canal on the sagittal section of the CBCT, and determine whether there were statistically significant differences between the age and gender groups.

MATERIAL AND METHODS

The research was approved by the Ethics Committee of the Faculty of Medicine at the University of Banja Luka (18/4.141/21). The sample included 146 CBCT images of

patients where the vertical canal distance of the second premolar, first molar and second molar was measured distally and mesially and statistical significance of the difference in relation to gender and age was examined. The initial database included 174 images, of which 146 met the criteria for sample selection: the presence of at least one tooth of importance for research (second mandibular premolar, first mandibular molar and second mandibular molar) and visibility of the mandibular canal on the image. Teeth with internal and external root resorption and endodontically treated teeth were not included in the study. The research included images made in the period from January 1st 2018 until December 31st 2018.

The imaging process was performed using Planmeca ProMax 3D Mid camera (Planmeca, Helsinki, Finland), and CBCT images were analyzed using Planmeca Romexis Viewer software (Figure 1). On the sagittal section, for each tooth (second mandibular premolar, first mandibular molar, second mandibular molar), vertical distance of the root apex to the upper projection of the mandibular canal was measured (Figure 2). For teeth with two roots, the distance was measured for each root separately (Figure 3).

Mandibular canal on sagittal section shows variability in appearance and usually appears as a radiolucent circle, which can be up to 4 mm in diameter. To facilitate the identification of mandibular canal, mental opening was identified on sagittal section, and the canal was followed to the level of the apex of the corresponding tooth [11].

A total of 406 measurements were performed, of which 146 for the second premolar, 42 for the first molar mesially, 42 for the first molar distally, 88 for the second molar mesially, and 88 for the second molar distally (Table 1). After the measurements, obtained values were divided according to the gender and age of the patients (Table 2). Based on age, the sample was divided into the three groups: group

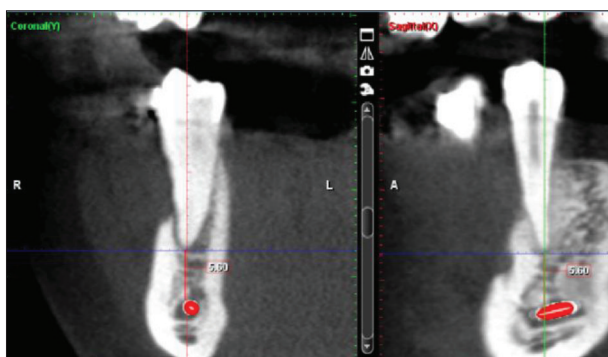


Figure 3. Distance of the mandibular canal from the apex of the mesial root of the tooth

Slika 3. Udaljenost mandibularnog kanala od vrha mezijalnog korena zuba

Table 1. Total number of measurements by gender and age groups for each root

Tabela 1. Ukupan broj merenja po polnim i starosnim grupama za svaki koren

GENDER POL	GROUP GRUPA	FMD PMD	FMM PMM	SMD DMD	SMM DMM	SP DP	TOTAL UKUPNO
FEMALE ŽENE	A	2	2	2	2	2	10
	B	9	9	22	22	29	91
	C	3	3	12	12	24	54
MALE MUŠKARCI	A	3	3	2	2	3	13
	B	18	18	30	30	48	144
	C	7	7	20	20	40	94
TOTAL UKUPNO		42	42	88	88	146	406

A – ≤17 years; B – 18–49 years; C – ≥50 years; FMD – first molar distally; FMM – first molar mesially; SMD – second molar distally; SMM – second molar mesially; SP – second premolar

A – ≤17 godina; B – 18–49 godina; C – ≥50 godina; PMD – prvi molar distalno; PMM – prvi molar mezijalno; DMD – drugi molar distalno; DMM – drugi molar mezijalno; DP – drugi premolar

Table 2. Average vertical distance by age groups

Tabela 2. Prosečna vertikalna udaljenost po starosnim grupama

AVERAGE VERTICAL DISTANCE BY AGE GROUPS PROSEČNA VERTIKALNA UDALJENOST PO STAROSNIM GRUPAMA					
GROUP GRUPA	FMD PMD	FMM PMM	SMD DMD	SMM DMM	SP DP
A	4.48	4.62	4.63	4.69	3.20
B	4.39	4.40	2.20	2.56	4.17
C	6.40	6.22	3.44	3.54	4.39

A – ≤17 years; B – 18–49 years; C – ≥50 years; FMD – first molar distally; FMM – first molar mesially; SMD – second molar distally; SMM – second molar mesially; SP – second premolar

A – ≤17 godina; B – 18–49 godina; C – ≥50 godina; PMD – prvi molar distalno; PMM – prvi molar mezijalno; DMD – drugi molar distalno; DMM – drugi molar mezijalno; DP – drugi premolar

A, which included CBCT images of patients younger than 17, group B, which included CBCT images of patients aged 18 to 49, and group C, which included CBCT images of patients older than 50.

STATISTICAL ANALYSIS

All data were presented in tables and figures. R Studio Version 3.6.2 was used to analyze the obtained data. Data were processed with a 95% significance level using The

Kruskal-Wallis and The Mann-Whitney U test. Based on the measured values, the average vertical distances for each root were determined, as well as average vertical distances for each root by age groups. It was also examined what this statistical significance is reflected in, by comparing individual groups separated by gender. In groups of teeth where significant statistical deviation was observed, CBCT images of persons of one gender, from one age group, were compared with CBCT images of persons of the same gender from another age group.

RESULTS

Analysis of the results of the average vertical distance for each root from the upper projection of mandibular canal showed that distal root of first molar (4.88 mm) had the highest average vertical distance and distal root of second molar (2.76 mm) the smallest. The average distance for first molar mesially was 4.86 mm, for second molar mesially 3.01 mm, and for second premolar 4.23 mm (Figure 4).

Observed by age groups, in the group A, second molar had the greatest distance from the mandibular canal mesially (4.69 mm), and second premolar had the smallest distance (3.2 mm).

In the group B, the greatest average vertical distance of the root apex from mandibular canal was shown in first molar mesially (4.4 mm) and the smallest in second molar distally (2.2 mm). In the group C, first molar distally had the highest average vertical distance (6.4 mm), and second molar distally had the smallest distance (3.44 mm). With statistical significance of 95% and using The Kruskal-Wallis test, the average vertical distance by types of premolars and molars in relation to age groups was observed (Table 2) but there was no statistically significant difference, $p > 0.05$. With statistical significance of 95% and using The Mann-Whitney U test, it was observed whether there was a statistically significant difference between age groups for each individual root and found that in the first molar mesially there was a statistically significant difference between groups B and C, with note that the value of p was at the significance limit ($p = 0.05$). In the second molar distally, statistically significant difference was observed between groups A and B, as well as between B and C ($p < 0.05$), and in second molar mesially between groups B and C ($p < 0.05$). No statistically significant difference was observed in other groups.

Previously mentioned groups, where statistically significant difference was found were further divided by gender in the analysis, after which persons of one gender from one age group were compared with persons of the same gender from another age group.

Comparing the vertical distance between CBCT images of females by age groups B and C for the first molar mesially, it was found that the difference was not statistically significant ($p > 0.05$), while in males there was significant difference ($p < 0.05$) (Figure 5).

Comparing the vertical distance between females by age groups B and C for the second molar distally, it was found that the difference was not statistically significant

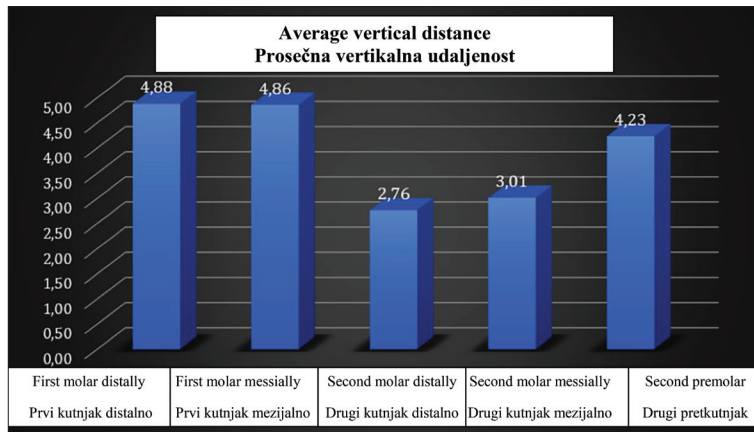


Figure 4. Average vertical distance for each root from the upper projection of the mandibular canal

Slika 4. Prosečna vertikalna udaljenost za svaki koren od gornje projekcije mandibularnog kanala

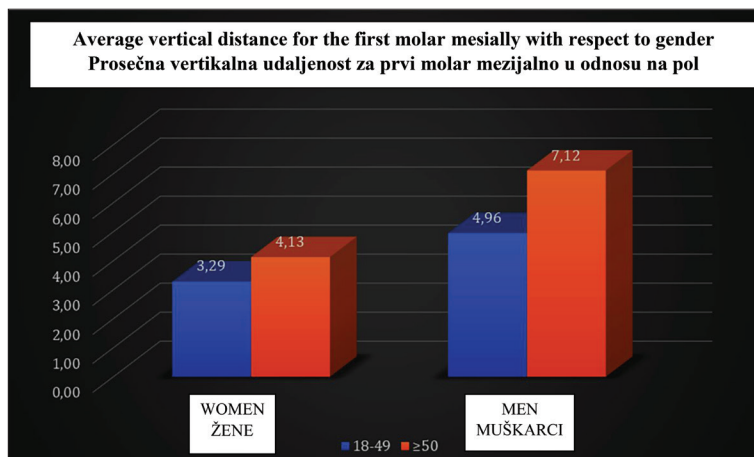


Figure 5. Average vertical distance for the first molar mesially with respect to gender

Slika 5. Prosečna vertikalna udaljenost za prvi molar mezijalno u odnosu na pol

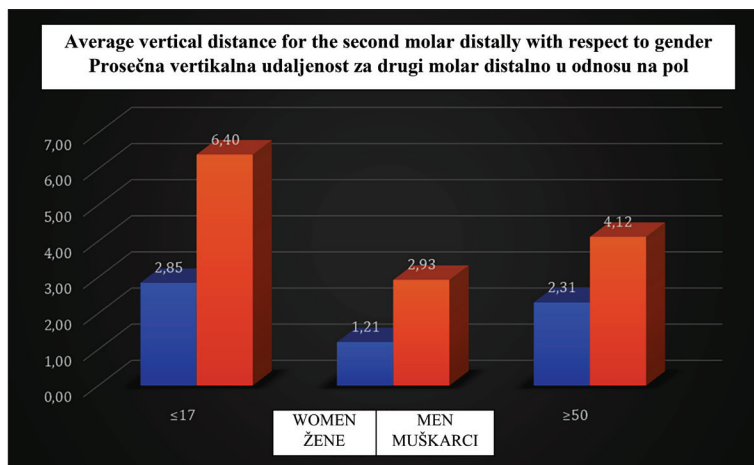


Figure 6. Average vertical distance for the second molar distally with respect to gender

Slika 6. Prosečna vertikalna udaljenost za drugi molar distalno u odnosu na pol

($p > 0.05$), while for the same groups in males statistically significant difference was found ($p < 0.05$) (Figure 6).

Although there is a statistically significant difference for the whole age groups B and C in the second molar mesially, observing the same by gender, and from different age

groups no statistically significant difference was found ($p > 0.05$) (Figure 7).

No statistically significant difference between different age groups in women was found, while in men it was observed only in the first molar mesially and the second molar distally, between groups A and B.

Comparing the average vertical distances for each root by gender, it was observed that all average values were higher in males. For men, the greatest average vertical distance was present in the root of first molar distally (5.57 mm) and the smallest in second molar distally (3.52 mm). In women, also, first molar distally had the greatest average vertical distance (3.50 mm), and second molar mesially had the smallest (1.64 mm) (Figure 8).

DISCUSSION

Development of modern radiological imaging system and CBCT, designed specifically for use in maxillofacial region, allowed obtaining timely information relevant to endodontic, surgical or endodontic-surgical treatment [12, 13, 14]. CBCT overcomes many of the limitations of conventional radiography, creating a non-distorted, three-dimensional image of the examined area and allowing visualization of the images by layers and sections in all three dimensions [15].

The results of our study showed that distal root of the first molar (4.88 mm) had the greatest average vertical distance of the apex from mandibular canal. Distal root of second molar (2.76 mm) had the smallest average vertical distance, it is more gracile than the mesial and slightly distally oriented, and its close relationship with the mandibular canal can be attributed to the trajectory and its position in the mandible. Uğur Aydın et al. obtained partially similar results in Turkish population, where they found, based on CBCT images, that distal root of second molar (2.75 mm) had the smallest average distance from mandibular canal, while the greatest average distance was registered in the mesial root of the first molar (4.98 mm) [16].

In their study on CBCT images, Lvovsky et al. concluded that mesial root of the first molar (6.18 mm) had the greatest average distance, and distal root of the second molar (3.42 mm) had the smallest distance to mandibular canal [17]. The mean value for the mesial root of the first molar in our study was 4.86 mm.

Aksoy et al., by measuring the shortest distance from the mandibular canal, also found that the roots of the

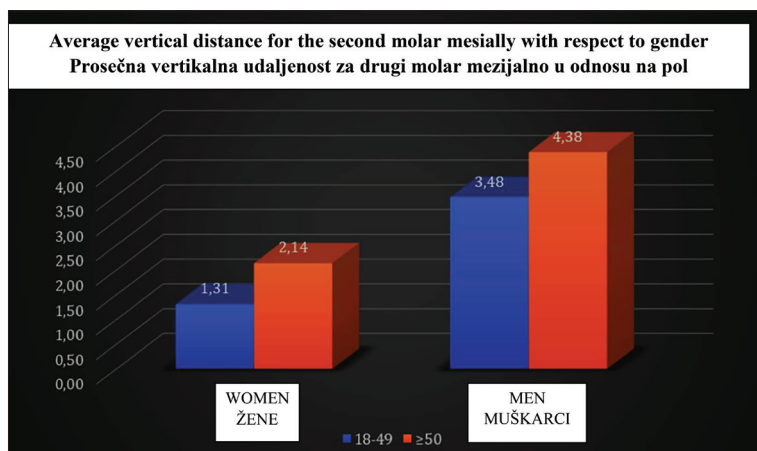


Figure 7. Average vertical distance for the second molar mesially with respect to gender

Slika 7. Prosečna vertikalna udaljenost za drugi molar mezijalno u odnosu na pol

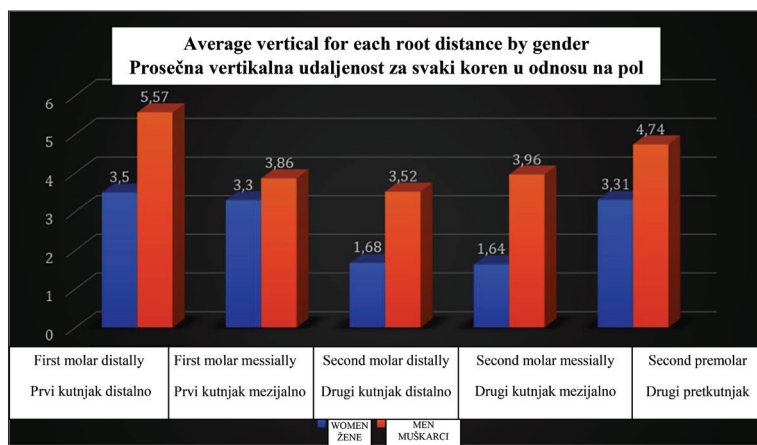


Figure 8. Average vertical distances for each root by gender

Slika 8. Prosečna vertikalna udaljenost za svaki koren u odnosu na pol

second molar were significantly closer to mandibular canal than the roots of the first molars, first, and second premolars [18]. In the study of Denio et al. that analyzed anatomical relationships of the mandibular canal and lateral teeth by dissecting 22 mandibles, it was concluded that second mandibular premolar and second mandibular molar had the smallest distance from mandibular canal [19].

Using CBCT images, Kosumarl et al. found that mesial root of the first molar had the greatest average distance from mandibular canal, while the shortest was in distal root of second molar, both in persons with normal skeletal jaw ratio or skeletal open bite [20]. With the exception of the third molar, Pucilo et al. concluded in a systematic review that distal root of the second molar was closest to the mandibular canal, which coincided with the results of our study [21]. Littner et al. measured the average values of the distance from the apex of first and second molars from the canal on radiographic images of the cadaver and they were between 3.50 and 5.40 mm, and according to a study conducted by Kovisto et al. on CBCT images, these average values were between 1.51 and 3.43 mm [22, 23]. In our study, the average values of the distance of the apices in lower lateral teeth from the mandibular canal ranged between 2.76 and 4.88 mm.

Observing the average vertical distances for each root by gender, it was noticed that all average values were higher in males, which could be related to more gracile constitution of women and smaller dimensions of the lower jaw. Similar findings were reported by other researchers (Aksoy et al. 2017; Simonton et al. 2009), who found that distances between the apices of the lower premolars and lower molars and mandibular canal were smaller in female population [18, 24].

Sato et al. performed research on cadavers, and with the help of CT images and panoramic radiography measured the distances from the root apex to the upper projection of the mandibular canal. Data were grouped by gender and side of mouth. They recorded slightly lower values of the distance in first and second molars from the mandibular canal in women, compared to men [25].

It has been shown that there is four times higher possibility of developing chronic pain after endodontic treatment, if the patient is a female person, as the incidence of postoperative pain in women is also higher [26].

For a definitive conclusion on the reliability of such measurements of the distance of the tooth apices from the mandibular canal, verification in a larger group of teeth is necessary. The deviations in the measurements can be explained by the fact that they were obtained through different sagittal sections of the CBCT, which could affect the repeatability of these measurements.

CONCLUSION

Measurements obtained in our study and statistical analyses showed that distal root of mandibular second molars had the smallest vertical distance from the mandibular canal, so careful canal instrumentation and careful planning of oral surgery in this region is recommended.

Interventions in the lateral region of the mandible can lead to damage of the neurovascular bundle of the canal, and unwanted complications, such as paresthesia or neuropathic pain. Therefore, it is important that the therapist is familiar with these relations and performs treatment in compliance with biological principles.

REFERENCES

1. Durack C, Patel S. Cone beam computed tomography in endodontics. *Braz Dent J.* 2012;23(3):179–91. [DOI: 10.1590/s0103-64402012000300001] [PMID: 22814684]

2. Kruse C, Spin-Neto R, Reibel J, Wenzel A, Kirkevang LL. Diagnostic validity of periapical radiography and CBCT for assessing periapical lesions that persist after endodontic surgery. *Dentomaxillofac Radiol.* 2017;46(7):20170210. [DOI: 10.1259/dmfr.20170210] [PMID: 28707526]
3. Beals DW, Parashar V, Francis JR, Agostini GM, Gill A. CBCT in Advanced Dental Education: A Survey of U.S. Postdoctoral Periodontics Programs. *J Dent Educ.* 2020;84(3):301–7. [DOI: 10.21815/JDE.019.179] [PMID: 32176341]
4. Kovisto T, Ahmad M, Bowles WR. Proximity of the mandibular canal to the tooth apex. *J Endod.* 2011 Mar;37(3):311–5. [DOI: 10.1016/j.joen.2010.11.030.] [PMID: 21329813.]
5. Krishnaraj Somayaji S, Mohandas Rao KG. Relevance of maxillofacial anatomy in endodontics. *Acta Stomatologica Naissi.* 2012;28:1129–32. [DOI: 10.5937/asn1265128S]
6. Vieira CL, Veloso SDAR, Lopes FF. Location of the course of the mandibular canal, anterior loop and accessory mental foramen through cone-beam computed tomography. *Surg Radiol Anat.* 2018;40(12):1411–7. [DOI: 10.1007/s00276-018-2081-6] [PMID: 30120507]
7. Kawashima Y, Sakai O, Shosho D, Kaneda T, Gohel A. Proximity of the Mandibular Canal to Teeth and Cortical Bone. *J Endod.* 2016;42(2):221–4. [DOI: 10.1016/j.joen.2015.11.009] [PMID: 26725176]
8. Knowles KI, Jergenson MA, Howard JH. Paresthesia associated with endodontic treatment of mandibular premolars. *J Endod.* 2003;29(11):768–70. [DOI: 10.1097/00004770-200311000-00019] [PMID: 14651287]
9. Chong BS, Quinn A, Pawar RR, Makdissi J, Sidhu SK. The anatomical relationship between the roots of mandibular second molars and the inferior alveolar nerve. *Int Endod J.* 2015;48(6):549–55. [DOI: 10.1111/iej.12348.] [PMID: 25070206.]
10. Bianchi B, Ferri A, Varazzani A, Bergonzani M, Sesenna E. Microsurgical Decompression of Inferior Alveolar Nerve After Endodontic Treatment Complications. *J Craniofac Surg.* 2017;28(5):1365–8. [DOI: 10.1097/SCS.0000000000003672] [PMID: 28570409]
11. Claeys V, Wackens G. Bifid mandibular canal: literature review and case report. *Dentomaxillofac Radiol.* 2005;34(1):55–8. [DOI: 10.1259/dmfr/23146121] [PMID: 15709108]
12. Castro R, Guivarc'h M, Foletti JM, Catherine JH, Chossegros C, Guyot L. Endodontic-related inferior alveolar nerve injuries: A review and a therapeutic flow chart. *J Stomatol Oral Maxillofac Surg.* 2018;119(5):412–8. [DOI: 10.1016/j.jormas.2018.04.012] [PMID: 29730463]
13. Zahedi S, Mostafavi M, Lotfirikan N. Anatomic Study of Mandibular Posterior Teeth Using Cone-beam Computed Tomography for Endodontic Surgery. *J Endod.* 2018;44(5):738–43. [DOI: 10.1016/j.joen.2018.01.016] [PMID: 29550011]
14. Wang X, Chen K, Wang S, Tiwari SK, Ye L, Peng L. Relationship between the Mental Foramen, Mandibular Canal, and the Surgical Access Line of the Mandibular Posterior Teeth: A Cone-beam Computed Tomographic Analysis. *J Endod.* 2017;43(8):1262–6. [DOI: 10.1016/j.joen.2017.03.043] [PMID: 28648488]
15. Lo Giudice R, Nicita F, Puleio F, Alibrandi A, Cervino G, Lizio AS, et al. Accuracy of Periapical Radiography and CBCT in Endodontic Evaluation. *Int J Dent.* 2018;2018:2514243. [DOI: 10.1155/2018/2514243] [PMID: 30410540]
16. Uğur Aydın Z, Göller Bulut D. Relationship between the anatomic structures and mandibular posterior teeth for endodontic surgery in a Turkish population: a cone-beam computed tomographic analysis. *Clin Oral Investig.* 2019;23(9):3637–44. [DOI: 10.1007/s00784-019-02834-y] [PMID: 30712074]
17. Lvovsky A, Bachrach S, Kim HC, Pawar A, Levinzon O, Ben Itzhak J, et al. Relationship between Root Apices and the Mandibular Canal: A Cone-beam Computed Tomographic Comparison of 3 Populations. *J Endod.* 2018;44(4):555–8. [DOI: 10.1016/j.joen.2017.12.020] [PMID: 29426647]
18. Aksoy U, Aksoy S, Orhan K. A cone-beam computed tomography study of the anatomical relationships between mandibular teeth and the mandibular canal, with a review of the current literature. *Microsc Res Tech.* 2018;81(3):308–14. [DOI: 10.1002/jemt.22980] [PMID: 29285826]
19. Denio D, Torabinejad M, Bakland LK. Anatomical relationship of the mandibular canal to its surrounding structures in mature mandibles. *J Endod.* 1992;18(4):161–5. [DOI: 10.1016/S0099-2399(06)81411-1] [PMID: 1402570]
20. Kosumarl W, Patanaporn V, Jotikasthira D, Janhom A. Distances from the root apices of posterior teeth to the maxillary sinus and mandibular canal in patients with skeletal open bite: A cone-beam computed tomography study. *Imaging Sci Dent.* 2017;47(3):157–64. [DOI: 10.5624/isd.2017.47.3.157] [PMID: 28989898]
21. Pucilo M, Lipski M, Sroczyk-Jaszczynska M, Pucilo A, Nowicka A. The anatomical relationship between the roots of erupted permanent teeth and the mandibular canal: a systematic review. *Surg Radiol Anat.* 2020;42(5):529–42. [DOI: 10.1007/s00276-019-02404-7] [PMID: 31900577]
22. Littner MM, Kaffe I, Tamse A, Dicapua P. Relationship between the apices of the lower molars and mandibular canal--a radiographic study. *Oral Surg Oral Med Oral Pathol.* 1986;62(5):595–602. [DOI: 10.1016/0030-4220(86)90326-9] [PMID: 3466132]
23. Kovisto T, Ahmad M, Bowles WR. Proximity of the mandibular canal to the tooth apex. *J Endod.* 2011;37(3):311–5. [DOI: 10.1016/j.joen.2010.11.030.] [PMID: 21329813]
24. Simonton JD, Azevedo B, Schindler WG, Hargreaves KM. Age- and gender-related differences in the position of the inferior alveolar nerve by using cone beam computed tomography. *J Endod.* 2009;35(7):944–9. [DOI: 10.1016/j.joen.2009.04.032] [PMID: 19567312]
25. Sato I, Ueno R, Kawai T, Yosue T. Rare courses of the mandibular canal in the molar regions of the human mandible: a cadaveric study. *Okajimas Folia Anat Jpn.* 2005;82(3):95–101. [DOI: 10.2535/ofaj.82.95] [PMID: 16350422]
26. Polycarpou N, Ng YL, Canavan D, Moles DR, Gulabivala K. Prevalence of persistent pain after endodontic treatment and factors affecting its occurrence in cases with complete radiographic healing. *Int Endod J.* 2005;38(3):169–78. [DOI: 10.1111/j.1365-2591.2004.00923.x] [PMID: 15743420]

Received: 20.05.2021 • 28.07.2021

Primena CBCT analize u proceni udaljenosti korenova drugih donjih premolara, prvih i drugih donjih molara od mandibularnog kanala

Aleksandra Đeri¹, Nataša Brestovac², Sanja Subotić³, Irena Radman Kuzmanović¹, Adriana Arbutina⁴, Saša Marin⁵

¹Univerzitet u Banjoj Luci, Medicinski fakultet, Katedra za bolesti zuba, Banja Luka, Republika Srpska;

²ZU „Dr Marčeta“, Banja Luka, Republika Srpska;

³Univerzitet u Banjoj Luci, Medicinski fakultet, Katedra za stomatološku protetiku, Banja Luka, Republika Srpska;

⁴Univerzitet u Banjoj Luci, Medicinski fakultet, Katedra za ortodontiju, Banja Luka, Republika Srpska;

⁵Univerzitet u Banjoj Luci, Medicinski fakultet, Katedra za oralnu hirurgiju, Banja Luka, Republika Srpska

KRATAK SADRŽAJ

Uvod Mandibularni kanal sa pripadajućim neurovaskularnim snopom može biti u bliskom odnosu sa vrhovima mandibularnih zuba. Da bi se izbegle povrede i oštećenja donjeg zubnog živca tokom invazivnih dentalnih procedura, važno je poznavati njegovu lokalizaciju.

Cilj ovog istraživanja je bio da se na osnovu sagitalnog preseka CBCT snimka odrede prosečne vrednosti udaljenosti korenova drugih donjih premolara, prvih i drugih donjih molara mezijalno i distalno od gornje projekcije mandibularnog kanala, te utvrdi da li postoji statistička značajnost u odnosu na pol i starosnu dob.

Materijal i metode Istraživanje je sprovedeno na Medicinskom fakultetu Univerziteta u Banjoj Luci, a uzorak je činilo 146 CBCT snimaka pacijenata. CBCT snimci su dobijeni sa aparatom Planmeca ProMax 3D Mid (Planmeca, Helsinki, Finska) i analizirani pomoću softvera Planmeca Romexis Viewer. Na sagitalnom preseku je za svaki zub izmerena vertikalna udaljenost vrha korena do gornje projekcije mandibularnog kanala.

Rezultati Najveću prosečnu vertikalnu udaljenost apeksa korena zuba od mandibularnog kanala imao je distalni koren prvog molara (4,88 mm), a najmanju distalni koren drugog molara (2,76 mm). Statistički značajna razlika postoji između određenih starosnih grupa kod vrednosti pojedinačnih korenova i to za drugi molar mezijalno i drugi molar distalno ($p < 0,05$), za prvi molar mezijalno vrednost r je na granici značajnosti ($p = 0,05$).

Zaključak Rezultati ovog istraživanja pokazuju da najmanju vertikalnu udaljenost od mandibularnog kanala ima distalni koren mandibularnih drugih molara, pa se preporučuje pažljiva obrada kanala ovog korena i pažljivo planiranje oralnih hirurških zahvata u ovoj regiji.

Ključne reči: CBCT; mandibularni kanal; vertikalna udaljenost apeksa zuba; donji premolari; donji molari

UVOD

Kompjuterizovana tomografija Cone-beam (CBCT) savremeni je radiološki sistem za snimanje, dizajniran posebno za upotrebu u maksilofacijalnoj regiji. Sistem prevazilazi mnoga ograničenja konvencionalne radiografije, stvaranjem neiskrivljenje, trodimenzionalne slike područja koje se ispituje. Koristi se u endodontici za određivanje morfologije i dimenzija kanala korena, periapikalnih lezija, otkrivanje i lokalizaciju resorpcija, za postoperativnu kontrolu i praćenje ishoda terapije. Primenu je našao i u ortodontskoj terapiji, kao i u implantoprotetici, budući da olakšava protetsko planiranje, izbor implantata i mesta njegove ugradnje [1, 2, 3].

Uspešan endodontski tretman uveliko zavisi od adekvatne rendgenografske metode, koja bi trebalo da pruži kritične informacije o ispitivanim zubima i njihovoj okolnoj anatomiji. Od svog osnivanja, konvencionalna radiografija je ostala glavni oslonac pomoćnim dijagnostičkim metodama u endodontici.

Podaci iz literature ukazuju da postoje razlike kada se uporede udaljenosti vrhova mandibularnih zuba od mandibularnog kanala u odnosu na pol i godine pacijenta. Međutim, mogu se javiti brojne individualne varijacije položaja kanala u mandibuli, kao i položaja zuba i njihovog međusobnog odnosa [4].

Mandibularni kanal se pruža kroz donju vilicu od donjoviličnog otvora (*foramen mandibulae*). On je u najvećem broju slučajeva bilateralno simetričan i u vidu jednog glavnog kanala

sa svake strane mandibule, ali su moguće i varijacije. Sadržaj mandibularnog kanala čine donjovilični živac (*nervus alveolaris inferior*) i istoimeni krvni sudovi. Donji zubni živac je mešovita i završna grana mandibularnog živca, svojim senzitivnim delom inervise zube i desni donje vilice, a motornim delom milohioidni mišić i prednji trbuh digastričnog mišića [5, 6].

S obzirom na to da su mnogi autori potvrdili da su jatrogene povrede donjoviličnog živca najčešće (64,4%), neophodno je poznavanje tačne lokalizacije mandibularnog kanala i njegovog sadržaja radi adekvatne endodontske terapije donjih bočnih zuba, kao i adekvatne resekcije vrhova korena donjih bočnih zuba. U okviru protokola endodontske terapije koriste se instrumenti za mehaničku obradu kanala, kombinovani sa hemijskim sredstvima za irigaciju, medikamentozna sredstva i materijali za definitivnu opturaciju kanalnog sistema. U toku svih ovih faza moguć je nastanak neželjenih komplikacija – mehanička, hemijska ili termalna povreda nerva, što može izazvati neuropatski bol ili anesteziju u njegovoj inervacionoj zoni. Kod endodontske terapije 1% donjih premolara i čak kod 10% donjih drugih molara zabeležena je mogućnost povrede donjoviličnog živca. Povreda sadržaja mandibularnog kanala rotirajućim i hirurškim instrumentima moguća je u toku oralnih hirurških zahvata. Takve povrede nekada zahtevaju terapiju u vidu mikrohirurške dekompresije donjoviličnog živca [7–10].

Cilj ovog retrospektivnog istraživanja je bio da se na sagitalnom preseku CBCT-a odrede prosečne vertikalne udaljenosti

vrhova korenova drugih premolara, prvih molara i drugih molara mezijalno i distalno od gornje projekcije mandibularnog kanala, te utvrditi da li postoji statistička značajnost u odnosu na pol i starosnu dob.

MATERIJAL I METODE

Istraživanje je odobreno od strane Etičkog komiteta Medicinskog fakulteta Univerziteta u Banjoj Luci (18/4.141/21).

Uzorak je obuhvatao 146 CBCT snimaka pacijenata pomoću kojih je merena vertikalna udaljenost kanala drugog premolara, prvog molara i drugog molara distalno i mezijalno i ispitivana statistička značajnost razlike u odnosu na pol i starosnu dob. Početna baza podataka obuhvatala je 174 snimka, od kojih je 146 ispunilo kriterijume za izbor uzorka: prisustvo minimum jednog zuba od značaja za istraživanje (drugi mandibularni premolar, prvi mandibularni molar i drugi mandibularni molar) i vidljivost mandibularnog kanala na snimku. Zubi sa internom i eksternom resorpcijom korena i enodontski lečeni zubi nisu bili uključeni u istraživanje. Istraživanje je obuhvatilo snimke urađene u periodu od 1. 1. 2018. do 31. 12. 2018. godine.

Proces snimanja je obavljen sa aparatom Planmeca ProMax 3D Mid (Planmeca, Helsinki, Finska), a CBCT snimci su analizirani pomoću softvera Planmeca Romexis Viewer (Slika 1). Na sagitalnom preseku je za svaki zub (drugi mandibularni premolar, prvi mandibularni molar, drugi mandibularni molar) izmerena vertikalna udaljenost vrha korena do gornje projekcije mandibularnog kanala (Slika 2). Za zube sa dva korena merena je udaljenost za svaki koren posebno (Slika 3).

Mandibularni kanal na sagitalnom preseku pokazuje varijabilnost u izgledu i obično se pojavljuje kao radiolucetni krug, koji može biti do 4 mm u prečniku. Za lakše identifikovanje mandibularnog kanala, na sagitalnom preseku je identifikovan mentalni otvor, te je kanal praćen do nivoa apeksa odgovarajućeg zuba [11].

Kupno je izvršeno 406 merenja, od toga 146 za drugi premolar, 42 za prvi molar mezijalno, 42 za prvi molar distalno, 88 za drugi molar mezijalno i 88 za drugi molar distalno (Tabela 1). Nakon izvršenih merenja sve dobijene vrednosti su podeljene prema polu i starosnoj dobi pacijenata (Tabela 2). Na osnovu starosne dobi, uzorak je podeljen u tri grupe: grupa A, koja je obuhvatala CBCT snimke pacijenata mlađih od 17 godina, grupa B, koja je obuhvatala CBCT snimke pacijenata starosti od 18 do 49 godina i grupa C, koja je obuhvatala CBCT snimke pacijenata starijih od 50 godina.

Statistička analiza

Svi podaci su prikazani tabelarno i grafički. Za analizu dobijenih podataka korišćen je program R Studio Version 3.6.2. Podaci su obrađeni uz stepen značajnosti od 95% korišćenjem testova Kruskal–Wallis i Mann–Whitney U. Na osnovu izmerenih vrednosti određene su prosečne vertikalne udaljenosti za svaki koren, kao i za svaki koren po starosnim grupama. Takođe je ispitivano u čemu se ogledaju ove statističke značajnosti, poredeći pojedine grupe razdvojene po polu. Kod grupa zuba gde je uočeno značajno statističko odstupanje, CBCT snimci osoba jednog pola iz jedne starosne grupe poređene su sa CBCT snimcima osoba istog pola iz druge starosne grupe.

REZULTATI

Analiza rezultata prosečne vertikalne udaljenosti za svaki koren od gornje projekcije mandibularnog kanala je pokazala da najveću prosečnu vertikalnu udaljenost ima distalni koren prvog molara (4,88 mm), a najmanju distalni koren drugog molara (2,76 mm). Prosečna udaljenost za prvi molar mezijalno je 4,86 mm, za drugi molar mezijalno 3,01 mm, a za drugi premolar 4,23 mm (Slika 4).

Posmatrano po starosnim grupama, u grupi A najveću udaljenost od mandibularnog kanala imao je drugi molar mezijalno (4,69 mm), a najmanju drugi premolar (3,2 mm).

U grupi B najveću prosečnu vertikalnu udaljenost apeksa korena od mandibularnog kanala pokazao je prvi molar mezijalno (4,4 mm), a najmanju drugi molar distalno (2,2 mm).

U grupi C je najveću prosečnu vertikalnu udaljenost imao prvi molar distalno (6,4 mm), a najmanju drugi molar distalno (3,44 mm).

Sa statističkom značajnosti od 95% i koristeći Kruskal–Wallis test, posmatrana je prosečna vertikalna udaljenost po vrstama premolara i molara u odnosu na starosne grupe (Tabela 2) i utvrđeno je da ne postoji statistički značajna razlika, $p > 0,05$.

Sa statističkom značajnosti od 95% i koristeći Mann–Whitney U test, posmatrali smo da li postoji statistički značajna razlika između pojedinih starosnih grupa za svaki pojedinačni koren i utvrđeno je da kod prvog molara mezijalno postoji statistički značajna razlika između grupa B i C, uz napomenu da je vrednost p na granici značajnosti ($p = 0,05$). Kod drugog molara distalno uočena je statistički značajna razlika između grupa A i B, kao i između B i C ($p < 0,05$), a kod drugog molara mezijalno između grupa B i C ($p < 0,05$). Kod ostalih grupa nije uočena statistički značajna razlika.

Prethodno pomenute grupe, kod kojih je uočena statistički značajna razlika, u daljoj analizi su razdvojene prema polu, nakon čega su osobe jednog pola iz jedne starosne grupe poređene sa osobama istog pola iz druge starosne grupe.

Poredeći vertikalnu udaljenost između CBCT snimaka osoba ženskog pola po starosnim grupama B i C za prvi molar mezijalno, utvrđeno je da razlika nije statistički značajna ($p > 0,05$), dok kod osoba muškog pola postoji značajna statistička razlika ($p < 0,05$) (Slika 5).

Poredeći vertikalnu udaljenost između osoba ženskog pola po starosnim grupama B i C za drugi molar distalno, utvrđeno je da razlika nije statistički značajna ($p > 0,05$), dok je za iste grupe kod osoba muškog pola utvrđeno da postoji značajna statistička razlika ($p < 0,05$) (Slika 6).

Iako postoji statistički značajna razlika za cele starosne grupe B i C kod drugog molara mezijalno, posmatrajući iste po polu, a iz različitih starosnih grupa, utvrđeno je da razlika nije statistički značajna ($p > 0,05$) (Slika 7).

Utvrdeno je da ne postoji statistički značajna razlika između različitih starosnih grupa kod žena, dok je kod muškaraca ona uočena samo kod prvog molara mezijalno i drugog molara distalno, između grupa A i B.

Posmatrajući prosečne vertikalne udaljenosti za svaki koren po polu, uočeno je da su sve prosečne vrednosti veće kod osoba muškog pola. Za muškarce je najveća prosečna vertikalna udaljenost prisutna kod korena prvog molara distalno (5,57 mm), a najmanja kod drugog molara distalno (3,52 mm). Kod žena je najveću prosečnu vertikalnu udaljenost takođe imao prvi

molar distalno (3,50 mm), a najmanju drugi molar mezijalno (1,64 mm) (Slika 8).

DISKUSIJA

Zahvaljujući savremenom radiološkom sistemu za snimanje, CBCT-u, koji je dizajniran posebno za upotrebu u maksilofacijalnoj regiji, moguće je pravovremeno dobiti informacije od značaja za endodontsku, hiruršku ili endodontsko-hiruršku terapiju [12, 13, 14].

CBCT prevazilazi mnoga ograničenja konvencionalne radiografije stvaranjem neiskrivljenje, trodimenzionalne slike područja koje se ispituje i omogućava vizuelizaciju snimaka po slojevima i presek u sve tri dimenzije [15].

Rezultati ove studije su pokazali da je najveću prosečnu vertikalnu udaljenost apeksa od mandibularnog kanala imao distalni koren prvog molara (4,88 mm). Najmanju prosečnu vertikalnu udaljenost imao je distalni koren drugog molara (2,76 mm), koji je gracilniji u odnosu na mezijalni i blago distalno usmeren, a njegov blizak odnos sa mandibularnim kanalom može se pripisati putanji kanala i njegovom položaju u mandibuli. Do delimično sličnih rezultata merenjem na CBCT snimcima su došli Uğur Aydın i saradnici koji su, na uzorku iz turske populacije, ustanovili da je najmanju prosečnu udaljenost od mandibularnog kanala takođe imao distalni koren drugog molara (2,75 mm), dok je najveća prosečna udaljenost registrovana kod mezijalnog korena prvog molara (4,98 mm) [16].

Lvovsky i saradnici su u svom istraživanju na CBCT snimcima zaključili da je najveću prosečnu udaljenost imao mezijalni koren prvog molara (6,18 mm), a najmanju distalni koren drugog molara (3,42 mm) [17].

Prosečna vrednost za mezijalni koren prvog molara u našem istraživanju bila je 4,86 mm.

Aksoy je sa saradnicima merenjem najkraće udaljenosti od mandibularnog kanala takođe ustanovio da su korenovi drugog molara značajno bliži mandibularnom kanalu u odnosu na korenove prvih molara, prvih i drugih premolara [18].

Denio i saradnici su u svojoj studiji, u kojoj su proučavali anatomske odnose mandibularnog kanala i bočnih zuba seciranjem 22 mandibule, zaključili da najmanju udaljenost od mandibularnog kanala pokazuju drugi mandibularni premolar i drugi mandibularni molar [19].

Kosumarli i saradnici su merenjem na CBCT snimcima ustanovili da je najveću prosečnu udaljenost od mandibularnog kanala imao mezijalni koren prvog molara, a najkraću distalni koren drugog molara, bilo da se radi o osobama sa normalnim skeletnim odnosom vilica ili skeletno otvorenim zagrižajem [20].

Izuzimajući treći molar, Pucilo je sa saradnicima u sistematskom pregledu zaključio da je distalni koren drugog molara

najbliži mandibularnom kanalu, što se podudara sa rezultatima ove studije [21].

Littner i saradnici su na radiografskim snimcima kadavera izmerili prosečne vrednosti udaljenosti apeksa prvih i drugih molara od kanala, koje su iznosile između 3,50 i 5,40 mm, a prema istraživanju koje su sprovedli Kovisto i saradnici na CBCT snimcima te prosečne vrednosti su iznosile između 1,51 i 3,43 mm [22, 23].

U ovom istraživanju prosečne vrednosti udaljenosti vrhova donjih bočnih zuba od mandibularnog kanala se kreću između 2,76 i 4,88 mm.

Posmatrajući prosečne vertikalne udaljenosti za svaki koren po polu, uočeno je da su sve prosečne vrednosti veće kod osoba muškog pola, što se može dovesti u vezu sa gracilnijom konstitucijom žena i manjim dimenzijama donje vilice. Do sličnog zaključka došli su i drugi istraživači (Aksoy et al. 2017; Simonton et al. 2009), koji su ustanovili da su rastojanja između vrhova donjih premolara, odnosno donjih molara i mandibularnog kanala bila kraća u ženskoj populaciji [18, 24].

Sato i saradnici su vršili istraživanje na kadaverima, te uz pomoć CT snimaka i panoramske radiografije merili udaljenosti od apeksa korena do gornje projekcije mandibularnog kanala. Podaci su grupisani po polu i strani usta. Zabeležili su nešto manje vrednosti udaljenosti prvih i drugih molara od mandibularnog kanala kod žena, u odnosu na vrednosti kod muškaraca [25].

Pokazalo se da postoji četiri puta veća mogućnost nastanka hroničnog bola nakon endodontske terapije ako je pacijent ženska osoba, a takođe je veća i incidenca postoperativnog bola kod žena [26].

Za definitivan zaključak o pouzdanosti ovakvih merenja udaljenosti vrhova zuba od mandibularnog kanala neophodna je provera kod veće grupe zuba nego u ovoj studiji. Odstupanja u merenjima se mogu objasniti činjenicom da su dobijena kroz različite sagitalne preseke CBCT-a, što može uticati na ponovljivost ovih merenja.

ZAKLJUČAK

Merenja u okviru ovog istraživanja i statistički podaci pokazuju da najmanju vertikalnu udaljenost od mandibularnog kanala ima distalni koren mandibularnih drugih molara, pa se preporučuje pažljiva obrada kanala ovog korena i pažljivo planiranje oralnohirurških zahvata u ovoj regiji.

Prilikom intervencija u bočnoj regiji mandibule može doći do oštećenja neurovaskularnog snopa kanala, te pojave neželjenih komplikacija, poput parestezija ili neuropatskih bolova. Zbog toga je važno da se terapeut, uz pridržavanje bioloških principa terapije i adekvatno urađene odontometrije, prethodno informiše o odnosu zuba i mandibularnog kanala.