



Denonvilliers' advancement flap in congenital alar rim defects correction

Denonvilerov *advancement* režanj za korekciju kongenitalnog defekta ruba nosnog krila

Marijan Novaković*, Ivanka Baralić†, Nenad Stepić*,
Milica Rajović*, Vladimir Stojiljković*

Military Medical Academy, *Clinic for Plastic Surgery and Burns, Belgrade, Serbia;
Medical School, †Institute of Forensic Medicine, Belgrade, Serbia

Abstract

Background. Alar rim defects are mostly acquired, resulting from burns, traumas or tumor excision. Sometimes they can accompany craniofacial clefts. However, isolated congenital alar defects are extremely rare. **Case report.** We presented two cases of congenital isolated alar cleft. The defect was closed by the use of an advancement flap, the technique described by Denonvilliers. We achieved both symmetry and appropriate thickness of the nostrils. Skin color and texture of the alar rim were excellent, with scars not excessively visible. **Conclusion.** Denonvilliers' z-plasty technique by using advancement flap provides both functionally and aesthetically satisfying outcome in patients with congenital alar rim defects.

Key words:

nose deformities, acquired; reconstructive surgical procedures; surgical flaps; prognosis.

Apstrakt

Uvod. Defekti ruba nosnog krila većinom su stečeni i najčešće su posledica opekotina, trauma ili resekcije tumora. Ponekada mogu biti udruženi sa kraniofacijalnim rascjepima. Međutim, izolovani kongenitalni defekti nosnog krila predstavljaju ekstremno retku pojavu. **Prikaz slučaja.** U radu su prikazana dva slučaja izolovanih urođenih rascjepa nosnog krila. U pokrivanju defekta korišćen je *advancement* režanj koji je opisao Denonviler. Primenom ove tehnike postignuta je simetrija, kao i odgovarajuća punoća nozdrva. Boja i tekstura kože nosnog krila u potpunosti zadovoljavaju, uz diskretne ožiljke. **Zaključak.** Denovilerova tehnika *advancement* reznja obezbeđuje i funkcionalno i estetski zadovoljavajući ishod hirurške korekcije kongenitalnog defekta ruba nosnog krila.

Ključne reči:

nos, stečene deformacije; hirurgija, rekonstruktivna, procedure; režnjevi, hirurški; prognoza.

Introduction

Due to its specific form and central position, the nose is a dominating structure of the face. That is why even a slightest asymmetry and/or irregularity of the nasal contour are clearly spotted at once.

Alar rim defects are in most cases acquired, as a consequence of burns, traumas and tumor excisions. Congenital nasal deformations sometimes occur within craniofacial clefts. Although the development of the nose is rather complicated, congenital anomalies are rare, the incidence being one in 20 000 to 40 000 live births^{1,2}. Nasal deformations clinically may vary from a tiny vermilion notch on the alar nose rim or eye lids, to big lesions within huge clefts that divide craniofacial structures³.

There are several classification systems of craniofacial clefts⁴⁻⁶. Tessier's classification is mostly used⁷. Craniofacial classification scheme divides facial clefts into types 0, 1,

2 and 3, while types 11, 12, 13 and 14 treat cranial clefts with nose lesions. With a cleft of alar nose rim, usual insufficiencies in soft tissue, cartilage and bone are also diagnosed, and in most cases it is accompanied with other craniofacial anomalies^{8,9}. The majority of nasal clefts are those of Tessier's type 0, while isolated alar cleft lesions are extremely rare. We presented two cases of congenital isolated alar cleft defect (Tessier's type 1), in whom we performed successful reconstructions applying Denonvilliers' procedure.

Case report

Case number one, a 16-year-old male was diagnosed to have an isolated cleft of the right alar rim. Other anomalies were not diagnosed. He was the first born child in his family, delivered in a normal way, weighing 2 890 g at birth. His parents were not blood relatives. There was no previous history of trauma, infection or nose surgery. His mother denied any

illness during her pregnancy; she did not smoke nor take alcohol, nor was she submitted to any therapy. There was no family history of diseases that might indicate heredity.

On physical examination we diagnosed a rupture in the continuity of the right alar rim, in full thickness and of about 2 cm in height, in the one third of the midline of the alar rim (Figure 1). Under the general endotracheal anesthesia the de-

obtain additional tissue needed for lining, a mucoperichondrial flap was detached from the caudal walls. Lining for the secondary defect was obtained by wide undermining of the mucous tissue out of the remaining part of the nasal cavity mucosa. The secondary skin defect on the lateral side of the nose was closed with the local transposition flap out of the nasal dorsum. Here, with the single-stage reconstruction, a

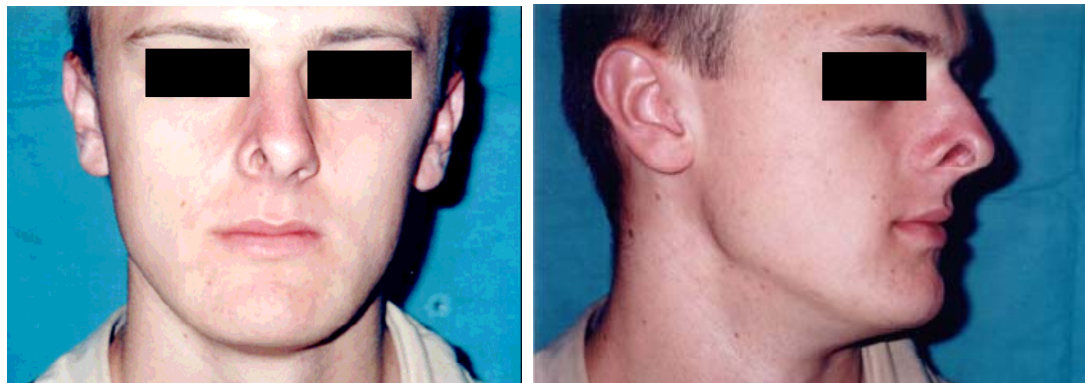

Fig. 1 – Preoperative view of the patient (case 1) – a rupture in continuity of the right alar rim

fect was closed by the method of z-plasty described by Denonvillier as early as in 1877¹⁰ (Figure 2). The incision went through full thickness of the nose cartilage. In order to

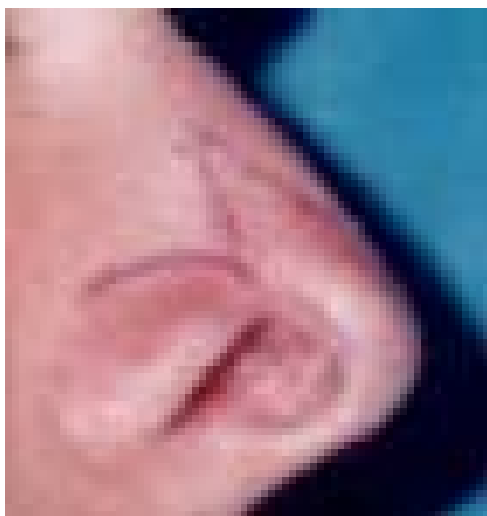


Fig. 2 – Denonvilliers' technique planning

full functional outcome was achieved, together with the very acceptable aesthetic result (Figure 3).

The second case, a female patient, 18-year-old, called in with isolated left alar rim cleft, without any other congenital malformations. She was the first child in the family, born in a normal way, weighing 3 200 grams at birth. Her parents were not blood relatives. The patient denied any previous injuries or infections, nor nose operation. Her mother's pregnancy was regular, there were no illnesses reported during the pregnancy. Her mother was not under any treatment during pregnancy, and she denied having any bad habits (alcohol, cigarettes). There were no diseases in the family that might be of significance.

At physical examination a huge cleft of the left alar rim was diagnosed, an embrasure that captured the complete medial, and the one third of the midline of the alar rim, up to 2 cm in height, accompanied with the unevenness of the alar cartilage on both sides (Figure 4). To close the cleft, we used the same Denonvilliers' z-plasty technique. The outcome was both functionally and aesthetically satisfying (Figure 5).

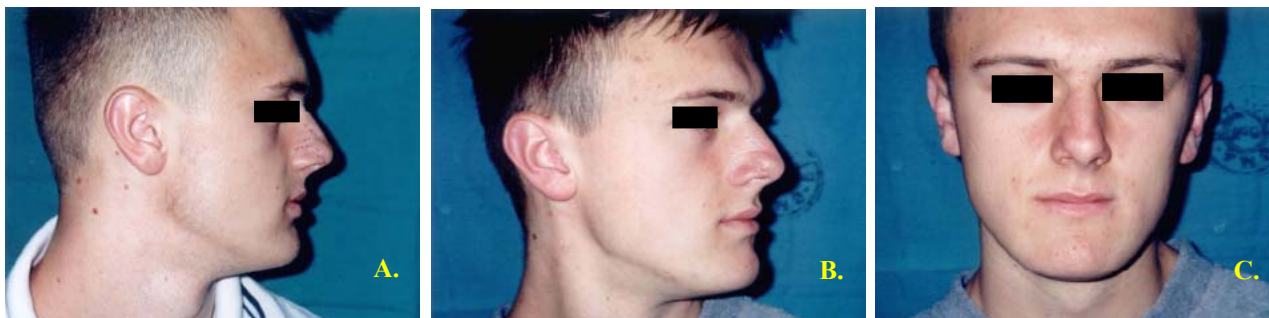
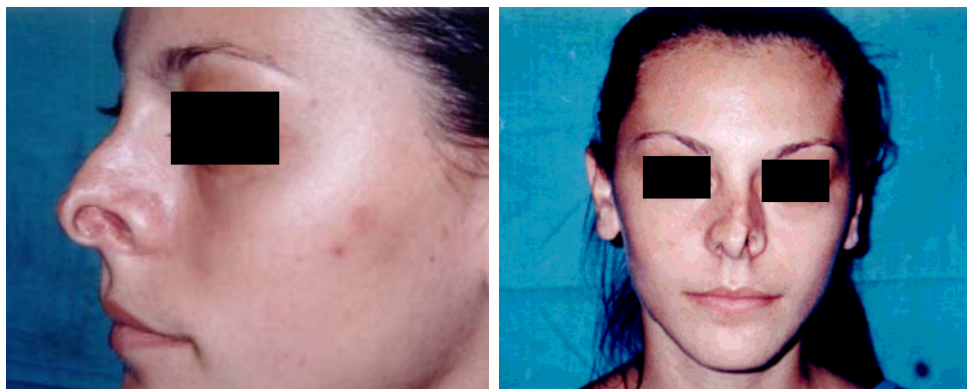
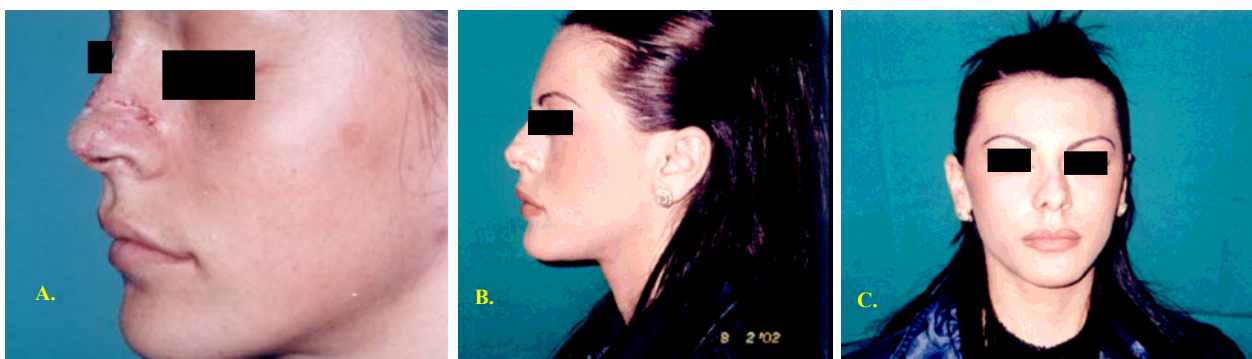Fig. 3 – Postoperative view of the patient (case 1)

A – 7th postoperative day, B and C – postoperative view after 3 months.



**Fig. 4 – Preoperative view of the patient (case 2) – huge cleft of the left alar rim
unevenness of the alar cartilage on both sides**



**Fig. 5 – Postoperative view of the patient (case 2)
A – 7th postoperative day, B and C – postoperative view after the six months.**

Discussion

Isolated congenital alar defects are extremely rare. Newman and Burdi⁸ presented four cases of single-sided alar clefts. It seems hardly possible to determine exactly the incidence of facial clefts. Losee et al.² worked up a classification scheme of congenital nasal anomalies, based upon their series of 261 patients (nasal deformations resulting of lip clefts were excluded), and they reported nasal clefts resulting in 16% of all nasal anomalies. Ortiz-Monasterio et al.³ analyzed a series of 6 500 patients and determined that only 2.2% of all clefts are those of Tessier's types 0, 1, 2 and 3, i.e. nasal clefts. They also report that isolated nasal clefts make only 0.7% of all cranial/facial clefts, and that 40% of nasal clefts belong to Tessier's type 0.

Embryology established that a nose develops from the frontonasal process, during the third to tenth week of the embryonic development. About the end of the fourth week of gestation, nasal placodes begin to develop from the frontonasal process. A fusion of medial nasal placodes causes the forming of nostrils. Medial and lateral nasal processes appear on the edges of those pits. One half of the nasal septum, as well as medial cruses of alar cartilages, develop from medial nasal processes. Nasal bones over the quadrangular cartilage and lateral cruses of alar cartilages appear from the lateral nasal

processes¹⁰⁻¹². There are lots of theories of embryonic development of the face, but the process is not yet fully explained up to the present day. On the other hand, two theories which explain the appearance of facial clefts are accepted. According to the first theory, clefts are the consequence of failed facial processes' fusion. The other theory states that the absence of mesodermal penetration is a key event in the appearance of a cleft¹³. Defects in the development of lateral nasal processes conduct to formation of anomalies of the alar rim¹¹.

Reconstruction of the alar rim is a challenge to every plastic surgeon. The literature abounds with surgical procedures used to resolve the problem. Bipedicule nasal flaps, as well as sliding flap from nasal dorsum may be used for minor alar defects^{14,15}. For minor defects, a composite graft harvested from the outer borders of helix may be used. Nasolabial flaps, as well as flaps from other, distant parts of the face, may be alternatively used, however, considering their disadvantages, like reconstruction in several stages, and/or visible scars^{16,17}.

Conclusion

In the described cases we used the Dennonvillier's technique to achieve both the symmetry and appropriate thickness of the nostrils. Skin color and texture of the nose were excellent, and scars not excessively visible.

R E F E R E N C E S

1. *Bilen BT, Kiliç H.* A congenital isolated alar cleft. *J Craniofac Surg* 2006; 17(3): 602–4.
2. *Losee JE, Kirschner RE, Whitaker LA, Bartlett SP.* Congenital nasal anomalies: a classification scheme. *Plast Reconstr Surg* 2004; 113(2): 676–89.
3. *Ortiz Monasterio F, Fuente del Campo A, Dimopoulos A.* Nasal clefts. *Ann Plast Surg* 1987; 18(5): 377–97.
4. *Harkins CS, Berlin A, Harding RL, Longacre JJ, Snodgrass RM.* A classification of cleft lip and cleft palate. *Plast Reconstr Surg Transplant Bull* 1962; 29: 31–9.
5. *Karfić V.* Oblique Facial Cleft. In: *Transaction International Society of Plastic Surgeons. Fourth Congress 1969.* Excerpta Medica; Amsterdam: 1969. pp. 105.
6. *van der Meulen JC, Mazzola R, Vermey-Keers C, Stricker M, Raphael B.* A morphogenetic classification of craniofacial malformations. *Plast Reconstr Surg* 1983; 71(4): 560–72.
7. *Tessier P.* Anatomical classification facial, cranio-facial and latero-facial clefts. *J Maxillofac Surg* 1976; 4(2): 69–92.
8. *Newman MH, Burdi AR.* Congenital alar field defects: clinical and embryological observations. *Cleft Palate J* 1981; 18(3): 188–92.
9. *Shenmake KB, Kawamoto HK Jr.* Congenital clefts of the nose: principles of surgical management. *Cleft Palate Craniofac J* 1992; 29(6): 531–9.
10. *Converse JM,* ed. *Reconstructive plastic surgery.* Philadelphia: W.B. Saunders Company; 1977.
11. *Saraiya H.* Isolated congenital unilateral alar defect: a rare anomaly. *Plast Reconstr Surg* 1996; 97(1): 246–8.
12. *Arey L,* ed. *Developmental anatomy: a textbook and laboratory manual of embryology.* 7th ed. Philadelphia: W.B. Saunders Company; 1965.
13. *Kawamoto HK Jr.* Rare craniofacial clefts. In: *McCarthy JG,* editor. *Plastic surgery.* Philadelphia: W.B. Saunders Company; 1990.
14. *Kazanjian VH.* Nasal deformities of syphilitic origin. *Plast Reconstr Surg* 1948; 3(5): 517–23.
15. *Denecke HJ, Meyer R,* eds. *Plastic surgery of head and neck.* New York: Springer; 1997.
16. *Koenig FI.* Zur deckung von defektion dur nosenflugel. *Ber Klin Wochenschr* 1902; 39: 137–9.
17. *Jeffrey E,* ed. *Essentials of plastic surgery.* Missouri, St Louis: Quality Medical Publishing; 2007.

The paper received on November 19, 2008.