



Validity of dual tracer ^{99m}Tc -tetrofosmin and ^{99m}Tc -pertechnetate subtraction parathyroid scintigraphy in patients with primary and secondary hyperparathyroidism

Validnost suptrakcione scintigrafije ^{99m}Tc -tetrofosminom i ^{99m}Tc -pertehnetatom kod bolesnika sa primarnim i sekundarnim hiperparatiroidizmom

Sanja Dugonjić*, Boris Ajdinović*, Snežana Cerović†, Zoran Janković*

Military Medical Academy, *Institute of Nuclear Medicine, †Institute of Pathology, Belgrade, Serbia

Abstract

Background/Aim. Primary hyperparathyroidism (pHPT) is an endocrine disease with the third highest incidence of all endocrine disorders after diabetes mellitus and hyperthyroidism. pHPT is typically caused by a solitary parathyroid adenoma, less frequently by multiple parathyroid gland disease (MGD) and rarely by parathyroid carcinoma. Secondary hyperparathyroidism (sHPT) is a common complication in patients with chronic renal failure. The aim of this study was to estimate sensitivity of dual tracer ^{99m}Tc -tetrofosmin and ^{99m}Tc -pertechnetate subtraction scintigraphy in detection of abnormal parathyroid glands in patients with pHPT and sHPT confirmed by histopathology. **Methods.** In 46 patients, (77 abnormal parathyroid glands), 30 with pHPT and 16 with sHPT parathyroid scintigraphy was done preoperatively. All the patients had histopathological confirmation of diagnosis. Abnormal parathyroid glands weighted from 0.1 to 7 g. After *iv* injection dynamic scintigraphy during 25 minutes (one frame-one minute) using 555 MBq of ^{99m}Tc -tetrofosmin, and three hours latter using 111 MBq of ^{99m}Tc /pertechnetate was performed. ^{99m}Tc -tetrofosmin dynamic

study was followed by static scintigraphy of the neck and chest 30 minutes, 1, 2 and 3 hours after *iv* injection. **Results.** An abnormal scintigraphic finding was found in 44 of 46 patients with sensitivity of 96%. In pHPT sensitivity was 93% (28 of 30 patients, and 28 of 30 glands). In sHPT scintigraphy was abnormal in all the patients (sensitivity 100%). In the patients with sHPT scintigraphy detected 30 of 47 abnormal parathyroid glands (sensitivity 64%). An overall sensitivity of scintigraphy per gland, for pHPT and sHPT in detecting 58 of 77 abnormal parathyroid glands was 75%. **Conclusion.** An abnormal scintigraphic result per patient was found in 44 patients (sensitivity 96%) and 58 of 77 abnormal parathyroid glands were detected (sensitivity 75%). A high sensitivity of dual tracer subtraction ^{99m}Tc -tetrofosmin/ ^{99m}Tc -pertechnetate parathyroid scintigraphy in detecting abnormal parathyroid glands in primary and secondary hyperparathyroidism was achieved.

Key words: parathyroid diseases; parathyroid hormones; hyperparathyroidism; radionuclide imaging; organotechnetium compounds; sensitivity and specificity.

Apstrakt

Uvod/Cilj. Primarni hiperparatiroidizam (pHPT) je endokrinološko oboljenje čija je incidencija na trećem mestu posle dijabetesa melitusa. Najčešće nastaje kao posledica solitarnog paratiroidnog adenoma, zatim zbog multiple bolesti paratiroidnih žlezda, a retko zbog paratiroidnog karcinoma. Sekundarni hiperparatiroidizam (sHPT) je česta komplikacija kod bolesnika sa hroničnom renalnom insuficijencijom. Cilj ovog rada bio je da odredi osetljivost suptrakcione scintigrafije paratiroidnih žlezda ^{99m}Tc -tetrofosminom i ^{99m}Tc -pertehnetatom u detekciji patološki izmenjenih paratiroidnih žlezda kod bolesnika sa pHPT i sHPT, dokazanim patohistološki. **Metode.** Scintigrafija paratiroidnih žlezda urađena je preoperativno kod 46 bolesnika, (77 patološki izmenjenih i uvećanih paratiroidnih žlezda), 30 sa primarnim i 16 sa se-

kundarnim hiperparatiroidizmom. Svi bolesnici imali su patohistološku potvrdu dijagnoze. Patološki izmenjene paratiroidne žlezde težile su od 0,1 do 7 g. Posle *iv* injekcije 555MBq ^{99m}Tc -tetrofosmina rađena je dinamska scintigrafija vrata u trajanju od 25 minuta (jedna sličica-jedan minut). Posle dinamske studije ^{99m}Tc -tetrofosminom rađena je statička scintigrafija vrata i grudnog koša 30 minuta, 1, 2 i 3 sata posle *iv* injekcije. Posle *iv* injekcije 111 MBq ^{99m}Tc -pertehnetata rađena je dinamska scintigrafija vrata, najranije tri sata od *iv* injekcije ^{99m}Tc -tetrofosmina. **Rezultati.** Patološki izmenjene paratiroidne žlezde nađene su scintigrafski kod 44 od 46 bolesnika, sa osetljivošću po bolesniku od 96%. Kod bolesnika sa pHPT osetljivost scintigrafije bila je 93% (kod 28 od 30 bolesnika, tj. 28 od 30 žlezda). Kod bolesnika sa sHPT svi bolesnici imali su patološki scintigrafski nalaz (osetljivost 100%). Kod bolesnika sa sHPT scintigra-

fija je otkrila 30 od 47 patološki izmenjenih paratiroidnih žlezda (osetljivost 64%). Ukupna osetljivost, izračunata po žlezdi, za pHPT i sHPT bila je 75% (otkriveno 58 od 77 patološki izmenjenih paratiroidnih žlezda). **Zaključak.** Patološki scintigrafski nalaz nađen je kod 44 od 46 bolesnika (osetljivost 96%). Otkriveno je 58 od 77 patološki izmenjenih paratiroidnih žlezda (osetljivost 75%). Dobijena je visoka osetljivost suptrakcione scintigrafije paratiroidnih žlezda ^{99m}Tc -tetrofosminim i ^{99m}Tc -pertehnetatom u otkrivanju

patološki izmenjenih i uvećanih paratiroidnih žlezda kod bolesnika sa primarnim i sekundarnim hiperparatiroidizmom.

Ključne reči:
paratiroidne žlezde, bolesti; paratiroidni hormoni; hiperparatiroidizam; scintigrafija; organotehnecijumska jedinjenja; osetljivost i specifičnost.

Introduction

Primary hyperparathyroidism (pHPT) is an endocrine disease with the third highest incidence of all endocrine disorders after diabetes mellitus and hyperthyroidism. Primary hyperparathyroidism is caused by secretion of excessive amounts of parathyroid hormone (PTH) by one or more enlarged diseased parathyroid gland(s). Two normal pairs of parathyroid glands are located in the neck posterior to the thyroid gland. pHPT is typically caused by a solitary parathyroid adenoma, less frequently (about 15% of cases) by multiple parathyroid gland disease (MGD) and rarely (about 1% of cases) by parathyroid carcinoma¹⁻³. Patients with MGD have either double adenomas or hyperplasia of three or all four parathyroid glands. Secondary hyperparathyroidism (sHPT) is a common complication in patients with chronic renal failure^{4,5}. Hypocalcemia, accumulation of phosphate and a decrease in the active form of vitamin D lead to increased secretion of PTH. When medical therapy fails, surgery becomes necessary. Successful parathyroidectomy depends on recognition and excision of all hyperfunctional parathyroid glands. Unguided bilateral exploration, dissecting all potential sites in the neck lead to remedy in 90–95% of patients⁶. Two main reasons for surgery failure are ectopic glands (retro-oesophageal, mediastinal, intrathyroid, in the sheath of the carotid artery, or undescended) and undetected MGD. The first neck exploration is optimal to cure hyperparathyroidism^{2,7,8}. Reoperation is associated with the dramatic reduction in the success rate and an increase in surgical complications. Scintigraphic imaging is, therefore, mandatory before reoperation of persistent or recurrent hyperparathyroidism⁷. Because of that, most surgeons would now appreciate having information of localization of abnormal parathyroid tissue. This would minimize the need for reoperation and shorten operation time by avoiding unnecessary surgery. The most common preoperative localization methods for hyperparathyroidism are scintigraphy and ultrasonography⁹⁻²¹. High resolution ultrasound is sensitive enough for localization of abnormal parathyroid glands in the neck, but is unable for mediastinal ectopic enlarged parathyroid masses. Scintigraphy can visualize enlarged parathyroid glands in the neck and parathyroid glands with ectopic localization. The two normal pairs of parathyroid glands are located in the neck posterior to the thyroid gland. They are very small, weighing between 20 and 50 mg. ^{99m}Tc -sestamibi and ^{99m}Tc -tetrofosmin are intracellular tracers, and both go into thyroid and parathyroid tissue allowing visualization of enlarged parathyroid glands. Critical mass of parathyroid tissue for scintigraphic

visualization is about 300 mg². Technetium-99m alone in the form of pertechnetate ($^{99m}\text{TcO}_4^-$) and I-123-sodium iodide are specific tracers for thyroid tissue and they are in use as second tracer for subtraction technique of parathyroid scintigraphy. Ectopic localization of parathyroid glands can be diagnosed by planar scintigraphy^{7,19-22}, SPECT and SPECT-CT scintigraphy techniques, magnetic resonance imaging (MRI) and computerized tomography (CT)^{2,11,18,19,22-25}.

The aim of this study was to estimate sensitivity of dual tracer ^{99m}Tc -tetrofosmin and ^{99m}Tc -pertechnetate subtraction scintigraphy, in detection of abnormal parathyroid glands in patients with primary and secondary hyperparathyroidism confirmed by histopathology.

Methods

Parathyroid scintigraphy was done preoperatively in 46 patients (77 abnormal parathyroid glands). There were 34 female and 12 male patients, 24 to 78 years old, mean age was 54 years. Thirty patients had primary and sixteen secondary hyperparathyroidism. The patients with pHPT had iPTH values from 65 to 837 pg/mL, mean value 253 pg/mL, and plasmatic calcium levels from 2.4 to 3.89 mmol/L, mean value 2.89 mmol/L. Twenty one patient with pHPT had values of serum anorganic phosphates, ranged from 0.35 to 1.1 mmol/L, mean value 0.76 mmol/L. The patients with sPTH had iPTH from 518 to 2500 pg/mL, mean value 1547 pg/mL. Normal iPTH values were in the range from 10.0 to 72.0 pg/mL, for plasmatic calcium from 2.13 to 2.65 mmol/L and for anorganic phosphates from 0.81 to 1.53 mmol/L. All the patients had histopathological confirmation of the diagnosis. Abnormal parathyroid glands weighed from 0.1 to 7 g.

Scintigraphy was done using regular field-of-view gamma camera with a high-sensitivity parallel hole collimator centered at 140 keV with 20% window. After *iv* injection of 555 MBq of ^{99m}Tc -tetrofosmin, with a head of gamma camera under the head, neck and chest of a patient, dynamic scintigraphy during 25 minutes (one frame-one minute) was performed. Late "tetrofosmin" static scintigrams of the neck and chest after 30 minutes, one, two and three hours after *iv* injection of ^{99m}Tc -tetrofosmin were done. When ^{99m}Tc -tetrofosmin was completely washed-out from thyroid gland, dynamic scintigraphy of thyroid gland after *iv* injection of 111 MBq of ^{99m}Tc -pertechnetate, lasting 25 minutes (one frame-one minute) was performed. After normalization and motion correction, subtraction ^{99m}Tc -pertechnetate from ^{99m}Tc -tetrofosmin added dynamic scintigram was done.

Scintigraphic results were graded one to five: grade 1 - normal finding, grade 2 - probably normal finding, grade 3 - suspicious finding, grade 4 - probably abnormal finding and grades 5 - abnormal finding. Scintigraphic findings graded four and five were considered as positive. Sensitivity was calculated using decision matrix formula for sensitivity.

Results

An abnormal scintigraphic finding was found in 44 of 46 patients, with sensitivity per patient of 96%. One patient

with pHPT had scintigraphic finding grade 2 and other one with pHPT scintigraphic finding grade 3. In the patient with scintigraphic finding grade 2, scintigraphic false negative finding was caused by a diffuse enlarged thyroid gland. Scintigraphy was false positive in the patient with scintigraphic finding grade 3, caused by thyroid colloid nodule, on the opposite side from enlarged parathyroid gland. From the remaining 28 patients with pHPT six patients had a scintigraphy finding grade 4, while 22 of them had scintigraphy finding grade 5. Primary hyperparathyroidism showed (Figures 1 and 2) scintigraphic sensitivity per gland of 93% (28

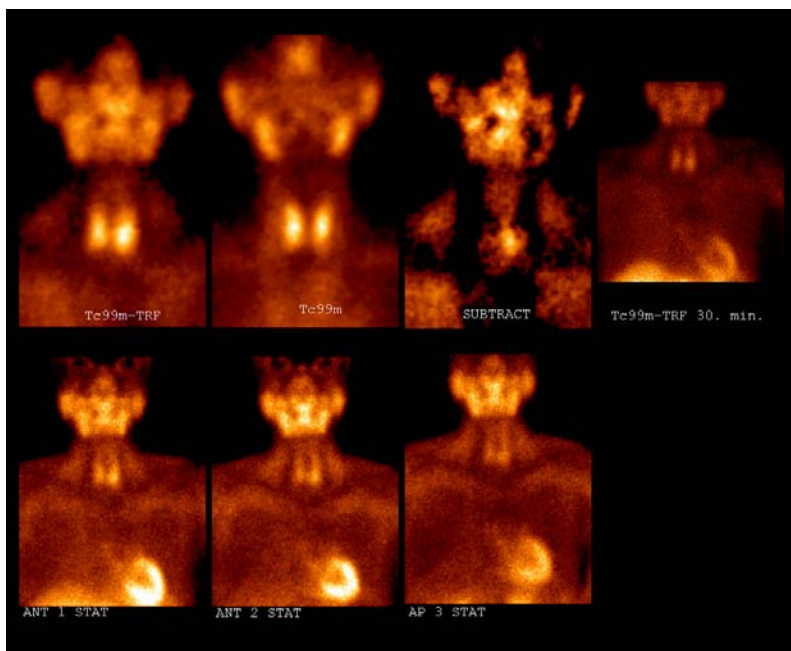


Fig. 1 – Patient S.M, 65 years of age, *Hyperparathyroidismus prim. susp, Osteoporosis sec*, PTH-225 pg/mL, CaU-2.83 mmol/L, P-0,84 mmol/L, ALP-159 U/L, Ca and P in urine b.o. Scintigraphy showed enlarged left inferior parathyroid gland

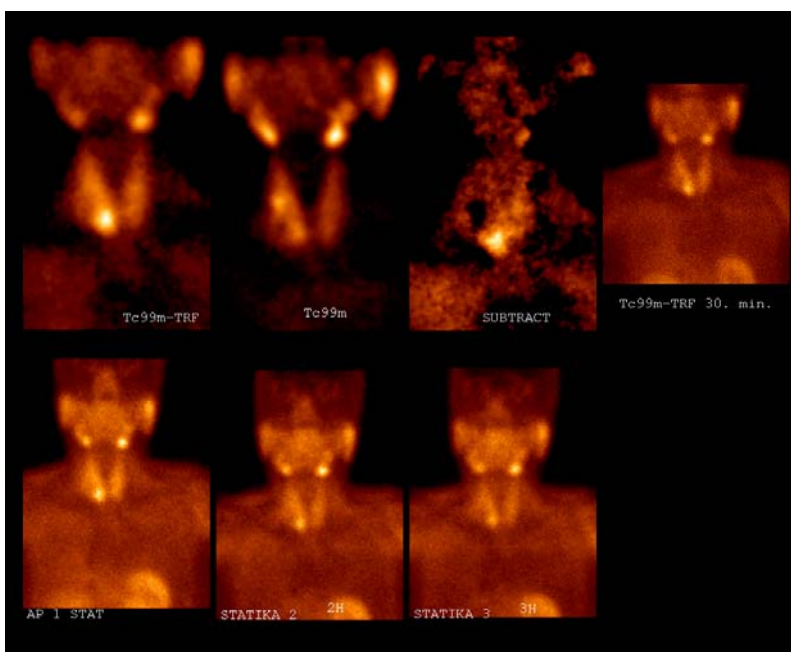


Fig. 2 – Patient M. N, 46 years of age, *Hyperparathyroidismus prim, Calculosis renis bill*, CaU-2.91 mmol/L, P-0.72 mmol/L, PTH-267 pg/mL. US finding was hypoechogenic zone in right inferior pole of thyroid gland 10×7 mm in diameter: enlarged parathyroid gland of thyroid node. Scintigraphy showed enlarged right inferior parathyroid gland

of 30 patients, i.e. 28 of 30 glands). All patients with the secondary hyperparathyroidism (Figure 3) had abnormal scintigraphic finding with sensitivity per patient of 100%, but sensitivity per gland, detecting 30 of 47 abnormal glands, was 64%. An overall sensitivity of scintigraphy for primary and secondary hyperparathyroidism per gland (detecting 58 of 77 abnormal parathyroid glands) was 75%.

pHPT, and 100% sensitivity per patient for sHPT. Causes of false negative findings are small weight, localization and kinetics of radionuclid uptake (cellularity and perfusion) of abnormal parathyroid glands, and large thyroid gland (mass > 35 g). Most frequent cause of false negative results is small gland weight. Enlarged hyperplastic parathyroid glands in sHPT have diffuse or nodular hyperplasia, and reach different weight and size in




Fig. 3 – Patient P. J, 44 years of age, *Insuff. Ren. Chr, Haemodialysis 6 years, PTH-1230 pg/mL*. Scintigraphy showed Tc99m-TRF activity in projection of left upper half of thyroid gland and smaller amount of TRF activity below left inferior pole of thyroid gland, suggesting enlarged left superior and inferior parathyroid gland

Discussion

In the last decade improvements in sensitivity and specificity of diagnostic techniques for identifying parathyroid pathology in patients with primary and secondary hyperparathyroidism were made. This has increased the need for preoperative parathyroid imaging, because exact localization of abnormal parathyroid glands shortened operation time and allow minimally invasive parathyroid surgery^{22, 26, 27}.

More than twenty years ago Ferlin et al.^{19, 20, 23} introduced double tracer thallium-201/technetium-99m (²⁰¹Tl/^{99m}Tc) subtraction scintigraphy as a very sensitive method for localizing abnormal or aberrantly located parathyroid tissue. Since then parathyroid scintigraphy has been used for localizing enlarged parathyroid glands both in primary and secondary hyperparathyroidism. ^{99m}Tc-sestamibi and ^{99m}Tc-tetrofosmin were promoted as new radiopharmaceuticals first for myocardial perfusion imaging, about ten years later^{13, 14}. Because of their high and uniform sensitivity, sestamibi and tetrofosmin are the radionuclides of choice for parathyroid imaging. Earlier papers reported wide range of sensitivity (26–94%) but uniform specificity, more than 95% of ²⁰¹Tl/^{99m}Tc dual tracer subtraction scintigraphy^{7, 13, 14}. Scintigraphy with ^{99m}Tc-sestamibi and ^{99m}Tc-tetrofosmin reaches sensitivity of 97%^{24, 25}. Our results are similar reaching as high sensitivity as 96% per patient and 93% per gland, for

the same patient⁴. This is the most probable reason for lower sensitivity of parathyroid scintigraphy estimated for sHPT per gland, as in our study (64%). About 10% are false positive findings caused by diffuse or multinodular goitre or solitary adenoma of thyroid gland. False positive findings can cause sarcoid or metastatic lymph nodes in the neck. Later studies discussed cellular predominance, PEG expression and cellular metabolic activity as reasons for lesser or greater uptake of sestamibi and tetrofosmin^{5, 28–30}.

Most of enlarged abnormal parathyroid glands have slower metabolism and wash-out of ^{99m}Tc-tetrofosmin and ^{99m}Tc-MIBI than thyroid gland, so they can be visualized in late “tetrofosmin/MIBI” scintigrams, without subtraction technique. Some abnormal parathyroid glands have a very high metabolism and fast wash-out of ^{99m}Tc-tetrofosmin from the gland, so they cannot be visualized on late scintigrams^{10, 12}. In such cases and in cases of intrathyroid localization of parathyroid glands subtraction technique clearly delineate abnormal parathyroid gland. Further sensitivity can be achieved by using SPECT or SPECT-CT scintigraphic technique^{11, 24, 25}. Using a probe perioperatively can be further extended for localization during operative procedures, leading to more accurate surgical results^{26, 27}. In this group of patients double tracer subtraction technique and dual-phase technique were combined to obtain higher sensitivity of parathyroid scintigraphy.

Conclusion

An abnormal scintigraphic result per patient was found in 44 patients (sensitivity 96%) with 58 abnormal glands detected

(sensitivity 75%). In this study a high sensitivity of dual tracer subtraction ^{99m}Tc -tetrofosmin/ ^{99m}Tc -pertechnetat parathyroid scintigraphy in detecting abnormal parathyroid glands in primary and secondary hyperparathyroidism was achieved.

R E F E R E N C E S

- Gbandur-Mnaymeh L, Kimura N. The parathyroid adenoma. A histopathologic definition with a study of 172 cases of primary hyperparathyroidism. *Am J Pathol* 1984; 115(1): 70–83.
- Parathyroid adenoma. Disease Topic 4778 [created: 2003 May 01, modified: 2003 May 02]. Available from: <https://rad.usuhs.edu/medpix/index.html>
- Silverberg SJ, Bilezikian JP. Asymptomatic primary hyperparathyroidism: a medical perspective. *Surg Clin North Am* 2004; 84(3): 787–801.
- Gasparri G, Camandona M, Abbona GC, Papotti M, Jeantet A, Radice E, et al. Secondary and tertiary hyperparathyroidism: causes of recurrent disease after 446 parathyroidectomies. *Ann Surg* 2001; 233(1): 65–9.
- Grzeła T, Chudziński W, Łazarczyk M, Niderla J, Dziunycz P, Milewski L, et al. Persisted/recurrent hyperparathyroidism associated with development of multi-drug resistance phenotype and proliferation of parathyroid transplants. *Int J Mol Med* 2004; 14(4): 595–9.
- Fine J. Eugene. Parathyroid Imaging: Its current Status and Future Role. *Semin Nucl Med* 1987; 27 (4): 350–9.
- Rodriguez JM, Tezleman S, Siperstein AE, Dub QY, Higgins C, Morita E, et al. Localization procedures in patients with persistent or recurrent hyperparathyroidism. *Arch Surg* 1994; 129(8): 870–5.
- Mack LA, Pasieka JL. Asymptomatic primary hyperparathyroidism: a surgical perspective. *Surg Clin North Am* 2004; 84(3): 803–16.
- Barczyński M, Golkowski F, Konturek A, Buzjak-Bereza M, Cichon S, Hubalewska-Dydejczyk A, et al. Technetium-99m-sestamibi subtraction scintigraphy vs. ultrasonography combined with a rapid parathyroid hormone assay in parathyroid aspirates in preoperative localization of parathyroid adenomas and in directing surgical approach. *Clin Endocrinol (Oxf)* 2006; 65(1): 106–13.
- Siegel A, Mancuso M, Seltzer M. The spectrum of positive scan patterns in parathyroid scintigraphy. *Clin Nucl Med* 2007; 32(10): 770–4.
- Gayed IW, Kim EE, Broussard WF, Evans D, Lee J, Broemeling LD, et al. The value of ^{99m}Tc -sestamibi SPECT/CT over conventional SPECT in the evaluation of parathyroid adenomas or hyperplasia. *J Nucl Med* 2005; 46(2): 248–52.
- Bénard F, Lefebvre B, Beuon F, Langlois MF, Bisson G. Rapid washout of technetium-99m-MIBI from a large parathyroid adenoma. *J Nucl Med* 1995; 36(2): 241–3.
- Thompson GB, Mullan BP, Grant CS, Gorman CA, van Heerden JA, O'Connor MK, et al. Parathyroid imaging with technetium-99m-sestamibi: an initial institutional experience. *Surgery* 1994; 116(6): 966–72.
- Arslan N, İlğan S, Urhan M, Karacaoglu AÖ, Arslan İ, Öztürk E, et al. The role of technetium-99m-sestamibi parathyroid scintigraphy in the detection and localization of parathyroid adenomas in patients with hyperparathyroidism: comparison with technetium-thallium subtraction scan and ultrasonography. *Turk J Endocrinol Metabol* 1999; 3(2): 47–52.
- Dolezal J, Horáček J, Ceeová V, Vízďal J. Disagreement between findings of ^{99m}Tc -MIBI and ^{99m}Tc -pertechnetate scintigraphy scans in patients with primary hyperparathyroidism. *Vnitř Lek* 2004; 50(1): 72–5. (Czech)
- Aigner RM, Fueger GF, Nicoletti R. Parathyroid scintigraphy: comparison of technetium-99m methoxyisobutylisonitrile and technetium-99m tetrofosmin studies. *Eur J Nucl Med* 1996; 23(6): 693–6.
- Fröberg AC, Valkema R, Bonjer HJ, Krenning EP. ^{99m}Tc -tetrofosmin or ^{99m}Tc -sestamibi for double-phase parathyroid scintigraphy? *Eur J Nucl Med Mol Imaging* 2003; 30(2): 193–6.
- Isibashi M, Nishida H, Hiromatsu Y, Kojima K, Uchida M, Hayabuchi N. Localization of ectopic parathyroid glands using technetium-99m sestamibi imaging: comparison with magnetic resonance and computed tomographic imaging. *Eur J Nucl Med* 1997; 24(2): 197–201.
- Adams BK, Devi RT, Al-Haider ZY. Tc-99m sestamibi localization of an ectopic mediastinal parathyroid tumor in a patient with primary hyperparathyroidism. *Clin Nucl Med* 2004; 29(6): 388–9.
- Prasad B, Fleming RM. Intrathyroidal parathyroid adenoma. *Clin Nucl Med* 2005; 30(7): 467–9.
- Rubello D, Grass MD, Mariani G, AL-Nabhas A. Scintigraphic techniques in primary hyperparathyroidism: from pre-operative localization to intra-operative imaging. *Eur J Nucl Med Mol Imaging* 2007; 34(6): 926–33.
- Rubello D, Casara D, Pagetta C, Piotta A, Pelizzolo MR, Shapiro B. Determinant role of Tc-99m MIBI SPECT in the localization of a retrotracheal parathyroid adenoma successfully treated by radioguided surgery. *Clin Nucl Med* 2002; 27(10): 711–5.
- Quiros RM, Warren W, Prinz RA. Excision of a mediastinal parathyroid gland with use of video-assisted thoracoscopy, intraoperative ^{99m}Tc -sestamibi scanning, and intraoperative monitoring of intact parathyroid hormone. *Endocr Pract* 2004; 10(1): 45–8.
- Eslamy HK, Ziessman HA. Parathyroid scintigraphy in patients with primary hyperparathyroidism: ^{99m}Tc sestamibi SPECT and SPECT/CT. *Radiographics* 2008; 28(5): 1461–76.
- Nichols KJ, Tomas MB, Tronco GC, Rini JN, Kunjummen BD, Heller KS, et al. Preoperative parathyroid scintigraphic lesion localization: accuracy of various types of readings. *Radiology* 2008; 248(1): 221–32.
- Chen H, Mack E, Starling JR. A comprehensive evaluation of perioperative adjuncts during minimally invasive parathyroidectomy: which is most reliable? *Ann Surg* 2005; 242(3): 375–80.
- Kitagawa W, Shimizu K, Akasu H. Radioguided parathyroidectomy for primary hyperparathyroidism using the solid-state, multi-crystal gamma camera. *Med Sci Monit* 2003; 9(6): CS53–6.
- Yamaguchi S, Yachiku S, Hashimoto H, Kaneko S, Nishihara M, Niibori D, et al. Relation between technetium 99m-methoxyisobutylisonitrile accumulation and multidrug resistance protein in the parathyroid glands. *World J Surg* 2002; 26(1): 29–34.
- Rao VV, Chiu ML, Kronauge JF, Pinnica-Worms D. Expression of recombinant human multidrug resistance P-glycoprotein in insect cells confers decreased accumulation of technetium-99m-sestamibi. *J Nucl Med* 1994; 35(3): 510–5.
- Sun SS, Shiao YC, Lin CC, Kao A, Lee CC. Correlation between P-glycoprotein (P-gp) expression in parathyroid and Tc-99m MIBI parathyroid image findings. *Nucl Med Biol* 2001; 28(8): 929–33.

The paper received on March 18, 2009.