



## Two male patients with incontinentia pigmenti

### Dva bolesnika muškog pola sa inkontinencijom pigmenti

Snežana Minić\*, Gerd EK Novotny†, Ljiljana Medenica\*, Miljana Obradović‡, Bratislav Stefanović‡, Dušan Trpinac‡

\*Clinical Center of Serbia, Institute of Dermatology, Belgrade, Serbia; †University of Düsseldorf, Medizinische Einrichtungen, Institute of Anatomy I, Düsseldorf, Germany; ‡University of Belgrade, School of Medicine, Institute of Histology and Embryology, Belgrade, Serbia

#### Abstract

**Background.** Incontinentia pigmenti (IP) is a rare, complex, X-linked genodermatosis in which skin changes are combined with defects of other organs. It appears almost exclusively in females and is usually lethal in men. It is estimated that according to the available reported cases, there have been approximately 900–1 200 affected individuals, out of which 60 males. The aim of the study was to report two additional individual male cases with IP. **Case reports.** We discovered two male patients with IP according to standard IP diagnostic criteria. The diagnosis was made by a dermatologist and confirmed by cutaneous histopathology and ultrastructural analysis. The pedigrees, karyotype analyses and routine laboratory findings were made. Two male probands were the only ones with IP in their families, with no history of miscarriages. Both probands had normal karyotype. In one proband, acrocentric chromosomes of the group D had tendency of forming associations. Histopathological and ultrastructural skin analyses revealed findings typical for IP. **Conclusion.** The detection of each male case is very valuable because of their rarity. Application of the standard diagnostic criteria is necessary for comparison and epidemiological analysis. Monitoring such probands allows a better determination of how genetic transmission occurs, and is important because of the different degrees of severity of IP.

#### Key words:

incontinentia pigmenti; male; diagnosis.

#### Apstrakt

**Uvod.** Inkontinencija pigmenti (IP) je retka, složena, X-zavisna genodermatoza kod koje su promene na koži udružene sa poremećajima drugih organa. Javlja se gotovo isključivo kod osoba ženskog pola i obično je letalna za muške fetuse. Na osnovu objavljenih slučajeva procenjuje se da postoji približno 900–1 200 obolelih osoba, od čega su 60 muškarci. Naš cilj bio je da predstavimo još dva slučaja obolelih muškaraca sa IP. **Prikaz bolesnika.** Otkrili smo dva bolesnika muškog pola sa IP prema standardnim dijagnostičkim kriterijumima za IP. Dijagnozu IP postavio je dermatolog, a potvrđena je patohistološkim i ultrastrukturnim analizama kože. Za oba bolesnika urađeni su rodoslovi, analize kariotipa i rutinske laboratorijske analize. Dva probanda muškog pola prikazana u ovom radu u svojim porodicama jedini su imali IP. U njihovim porodicama nije bilo pobačaja. Oba probanda imala su normalan kariotip. Kod jednog probanda akrocentrični hromozomi grupe D imali su tendenciju da formiraju asocijacije. Patohistološke i ultrastrukturne analize kože pokazale su tipične nalaze za IP. **Zaključak.** Prikaz svakog bolesnika muškog pola sa IP je dragocen zbog izuzetno malog broja takvih registrovanih slučajeva. Korišćenje standardnih dijagnostičkih kriterijuma važno je zbog poređenja i epidemiološke analize. Praćenje probanada i njihovih porodica važno je zbog praćenja načina genetskog prenošenja oboljenja i zbog različitog stepena izraženosti IP.

#### Ključne reči:

inkontinencija pigmenti; muškarci; dijagnoza.

#### Introduction

Incontinentia pigmenti (IP) is a rare, X-linked genodermatosis in which a gene localized on the chromosome Xq28 is responsible for IP<sup>1</sup>. The NEMO (IKBK) signaling pathway is a multi-component pathway that regulates the expression of hundreds of genes that are involved in diverse

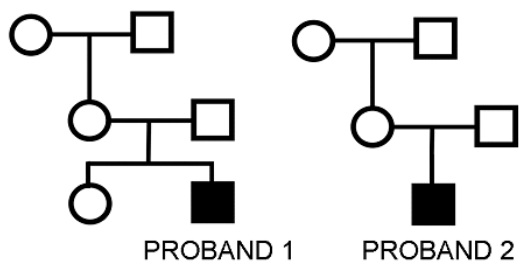
and key cellular processes, such as cell proliferation, cell survival, immunity, and inflammation. Its mis-regulation is involved in many diseases<sup>2,3</sup>. However, failure to identify NEMO (IKBK) mutation does not rule out the diagnosis of IP<sup>4</sup>. Affected females survive because of X-chromosome dizygosity and negative selection of cells carrying the mutant X-chromosome<sup>5</sup>.

It appears almost exclusively in females and is usually lethal in men<sup>6</sup>. Survival in males is explained through the following mechanisms: 47, XXY karyotype, somatic mosaicism and/or mutations that produce a milder form of IP<sup>4</sup>.

According to the available reported cases, it is estimated that there have been approximately 900–1 200 affected individuals, out of which 60 males<sup>4</sup>. In this paper, we reported two additional single male cases with IP, hereditary X linked disease usually lethal in males.

**Case report**

From 1989 until 2005 we discovered 9 families with IP. There were only two male patients in this group. Selection of patients was carried out according to the Landy and Donnai criteria<sup>7</sup>. The study protocol was approved by the Clinical Center of Serbia (CCS) Ethics Committee. Our cases were diagnosed clinically by a dermatologist and confirmed by cutaneous histopathology and ultrastructural analyses. The pedigrees (Figure 1), karyotype analyses and routine laboratory findings were done for all examinees.



**Fig. 1 – Pedigrees of the 2 investigated families with individual male cases of incontinentia pigmenti (affected probands denoted by blackened symbols)**

The basic data on the two unrelated male patients and key clinical and laboratory findings are given in Table 1. None of the male probands' relatives had any signs or symptoms of IP. There were no miscarriages in either of the families of both male IP patients.

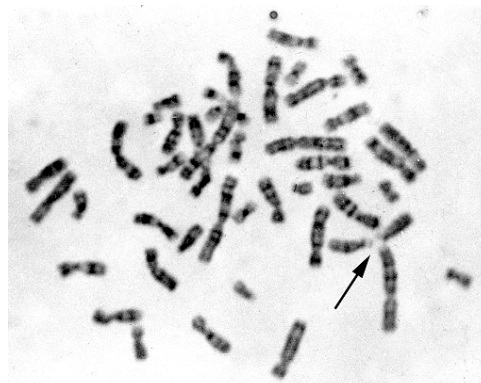
**Table 1  
Basic subjects data and key clinical and laboratory findings**

Patient's data and findings	Family-proband	
	1	2
Age when examined (years)	9	7
Skin	+	+
CNS*	-	-
Ocular	-	-
Dental and/or oral	+	+
Eosinophilia	+	-
Nails	+	-
Other findings	-	Asthma

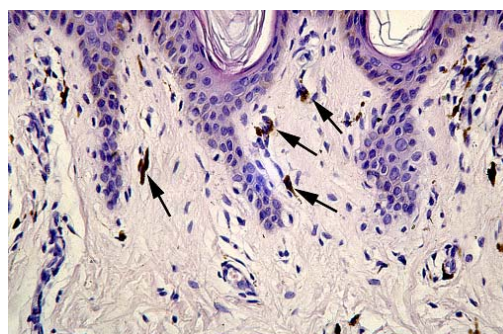
\*Central nervous system

A proband 1 was a 9-year old boy. He was examined at the Outpatient Unit of the Institute of Dermatovenerology, CCS. He was the second child from the second pregnancy. The first child was a healthy boy. First skin changes appeared when he was 3 days old as vesiculobullous lesions on the face, trunk, and upper extremities. He had lentiginosis on


his face, lips and hands. Linear hypo- and hyperpigmentations were present on his trunk, following Blaschko lines. The skin changes on his trunk had band-like and whirl-like shapes. Discrete atrophic maculas were present on his lower legs. His skin was dry and he had diminished sweating. He had brittle nails. His karyotype was normal, 46,XY. His acrocentric chromosomes of the group D were forming associations (Figure 2). Histopathological (Figure 3) and ultrastructural skin analyses (Figure 4) revealed typical findings for IP including free melanosome clusters in the dermis.



**Fig. 2 – Proband 1 karyotype with acrocentric chromosomes forming associations (arrow)**



**Fig. 3 – Histopathological findings in proband 2. Pigment in dermal cells (arrows) (Haematoxyline & Eosine, magnification 160x)**



**Fig. 4 – Ultrastructural findings in proband 1. Free melanosome clusters (mc) in dermis (D) rich in collagen fibers (kv) (TEM, bar 2 μm)**

A proband 2 was a 7-year old boy. He was born after a normal, uneventful pregnancy. Shortly after the birth, vesiculobulous lesions, mainly on the trunk, appeared in several eruptions. These changes resolved leaving hyper- and hypopigmented maculas. When examined for the first time at our institute, he was 2.5 years old. He had hyperpigmented whirl like maculas on his trunk and the right arm and hypopigmented maculas on his right hand (Figure 5). At the age of 7, the presence of verrucoid papulas over the hyperpigmented surface, in the inguinal region were detected. Karyotype was normal, 46,XY.

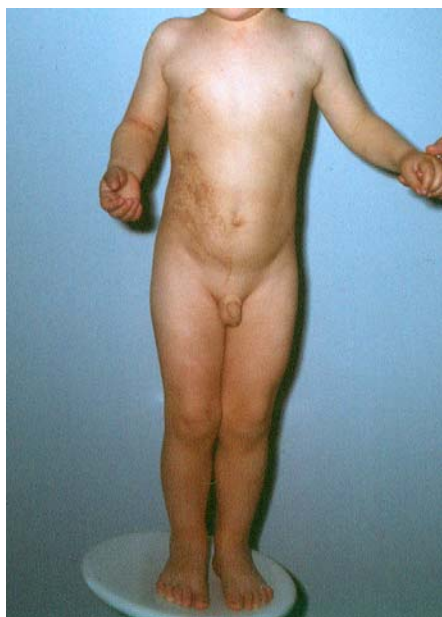


Fig. 5 – Skin changes in proband 2

## Discussion

IP is more common in females. The most common mutation in IP is a genomic rearrangement resulting in the deletion of a part of the *IKBKG* gene. These genetic abnormalities are responsible for extreme susceptibility to apoptosis, thus explaining the usual embryonic death in males and the extremely skewed X-chromosome inactivation in females with IP<sup>1</sup>.

Diagnostic selection of IP patients was made according to the Landy and Donnai criteria<sup>7</sup>. These criteria are divided in major and minor. The clinical diagnosis of IP can be made in the presence of at least one of the major criteria<sup>7</sup>. Major

criteria consist of skin lesions that occur from infancy to adulthood. Skin lesions usually start with erythema followed by blisters (vesicles) anywhere on the body, except the face, typically in linear distribution. Hyperpigmented streaks and whirls that respect Blaschko lines appear mainly on the trunk and fade in adolescence. Pale, hairless, atrophic linear streaks or patches may be present from adolescence through adulthood. Minor criteria are presented with anomalies of: teeth (hypodontia, anodontia, abnormally shaped, cariotic), hair (alopecia, wooly hair), nails (ridging or pitting), retina (revascularization, etc)<sup>7</sup>. The presence of minor criteria (dental, eye, hair, and nail anomalies) supports the clinical diagnosis. A complete absence of minor criteria should raise doubt about the diagnosis. Besides major and minor criteria patients should be tested for eosinophilia in the early stages of IP.

We have revealed two male probands who were the one and only affected members in their families with no miscarriages in their family histories. Both cases had the normal karyotype. In one patient, acrocentric chromosomes of the group D had a tendency to forming associations. This may be present in unstable karyotypes<sup>8</sup>. The diagnosis of IP was confirmed by histopathological and ultrastructural analysis. We hypothesized, as our probands had the normal karyotype, that they had either somatic mosaicism or mutations that produce a milder form of IP. Incontinentia pigmenti is usually first diagnosed by a dermatologist because skin changes are the most obvious ones.

The disease severity is extremely variable: none of the methods available, however, would allow one to predict the severity of the disease in the affected fetus<sup>9</sup>. According to the reported male cases in the world literature<sup>10</sup>, it would be expected that male patients are more severely affected than female, but this was not so for the two males that we reported.

## Conclusion

The application of the same diagnostic criteria is important for the comparison and epidemiological analysis of such a rare disease. The detection of each male IP case is very valuable since the extremely small number of them has been discovered. The monitoring of these probands and their families is important in order to better determine how genetic transmission occurs. Genetic counseling should be made available to all patients and their families.

## REFERENCES

1. Smahi A, Courtois G, Vabres P, Yamaoka S, Heuertz S, Munnich A, et al. Genomic rearrangement in NEMO impairs NF- $\kappa$ B activation and is a cause of incontinentia pigmenti. The International Incontinentia Pigmenti (IP) Consortium. *Nature* 2000; 405(6785): 466–72.
2. Courtois G, Gilmore TD. Mutations in the NF- $\kappa$ B signaling pathway: implications for human disease. *Oncogene* 2006; 25(51): 6831–43.
3. Orange JS, Levy O, Geba RS. Human disease resulting from gene mutations that interfere with appropriate nuclear factor- $\kappa$ B activation. *Immunol Rev* 2005; 203: 21–37.
4. Scheuerle A, Nelson D. Incontinentia pigmenti (Bloch-Sulzberger syndrome). University of Washington; Seattle (WA): GeneReviews 2008 Feb [cited 2008 Jan 28]. 24 p. Available from: [http://www.ncbi.nlm.nih.gov/books/bv.fcgi?rid=gene.chapter\\_i-p](http://www.ncbi.nlm.nih.gov/books/bv.fcgi?rid=gene.chapter_i-p)

5. *Martinez-Pomar N, Munoz-Saa I, Heine-Suner D, Martin A, Smabi A, Matamoros N.* A new mutation in exon 7 of NEMO gene: late skewed X-chromosome inactivation in an incontinentia pigmenti female patient with immunodeficiency. *Hum Genet* 2005; 118: 458–65.
6. *Berlin A, Paller AS, Chan LS.* Incontinentia pigmenti: a review and update on the molecular basis of pathophysiology. *J Am Acad Dermatol* 2002; 47: 169–87.
7. *Landy SJ, Donnai D.* Incontinentia pigmenti (Bloch-Sulzberger syndrome). *J Med Genet* 1993; 30(1): 53–9.
8. *Galperin-Lemaître H, Hens L, Sele B.* Comparison of acrocentric associations in male and female cells. Relationship to the active nucleolar organizers. *Hum Genet* 1980; 54(3): 349–53.
9. *Basarab T, Dunnill MGS, Munn SE, Russell-Jones R.* Incontinentia pigmenti: variable disease expression within an affected family. *J Eur Acad Dermatol Venerol* 1998; 11(2): 173–6.
10. *Scheuerle AE.* Male cases of incontinentia pigmenti: case report and review. *Am J Med Genet* 1998; 77(3): 201–18.

The paper received on February 2, 2009.

Revised on July 22, 2009.

Accepted on September 15, 2009.