



## Early reconstruction of bone defect created after initial surgery of a large keratocystic odontogenic tumor: A case report

### Rana rekonstrukcija defekta vilice nastalog posle prve operacije velikog keratocističnog odontogenog tumora

Stevo Matijević\*†, Zoran Damjanović‡, Snežana Cerović\*§

\*Department of Oral Surgery, †Clinic for Dentistry, ‡Clinic for Maxillofacial Surgery, §Department of Pathology, Military Medical Academy, Belgrade, Serbia; †Faculty of Medicine of the Military Medical Academy, University of Defence, Belgrade, Serbia

#### Abstract

**Introduction.** Keratocystic odontogenic tumor (KCOT) is defined as a benign cystic neoplasm of the jaws of odontogenic origin with a high rate of recurrence. The most lesions occur in the posterior part of the mandible. Treatment of KCOT remains controversial, but the goals of treatment should involve eliminating the potential for recurrence while minimizing surgical morbidity. However, another significant therapeutic problem related to the management of KCOT is an adequate and early reconstruction of the existing jaw defect, as well as appropriate aesthetic and functional rehabilitation of a patient, especially in cases of a very large destruction of the jaws bone. **Case report.** We presented a 65-year-old female patient with very large KCOT of the mandible. Orthopantomographic radiography showed a very large elliptical multilocular radiolucency, located on the right side of the mandible body and the ascending ramus of the mandible, with radiographic evidence of cortical perforation at the anterior border of the mandibular ramus and the superior border of the alveolar part of the mandible. The surgical treatment included two phases. In the first phase, the tumor was removed by enucleation and additional use of Carnoy solution, performing peripheral osteotomy and excision of the affected overlying mucosa, while in the second phase, restorative surgery of the existing mandibular defect was performed 6 months later. Postoperatively, we did not register any of postoperative complications, nor recurrence within 2 years of the follow-up. **Conclusion.** Adequate and early reconstruction of the existing jaw defect and appropriate aesthetic and functional rehabilitation of the patient should be the primary goal in the treatment of KCOT, having in mind the need for a long-term post-surgical follow-up.

#### Key words:

odontogenic cysts; oral surgical procedures; recurrence; reconstructive surgical procedures; mandible; treatment outcome.

#### Apstrakt

**Uvod.** Keratocistični odontogeni tumor (KCOT) definisan je kao benigna cistična neoplazma viličnih kostiju odontogenog porekla, sa visokom stopom recidiva. Najveći broj lezija obuhvata bočne delove mandibule. Lečenje KCOT je kontroverzno, ali ciljevi lečenja treba da obuhvate eliminisanje potencijala za pojavu recidiva, kao i smanjenje pojave hirurških komplikacija. Međutim, drugi značajan terapijski problem u lečenju KCOT jeste adekvatna i što ranija rekonstrukcija postojećeg viličnog defekta, kao i odgovarajuća estetska i funkcionalna rehabilitacija ovih bolesnika, naročito u slučajevima velikih destrukcija viličnih kostiju. **Prikaz bolesnika.** U radu je prikazana 65-godišnja žena sa veoma velikim KCOT mandibule. Na ortopantomografskoj radiografiji uočeno je elipsasto multilokularno rasvetljenje lokalizovano na desnoj strani tela mandibule i susednog dela ramusa donje vilice sa radiografski evidentnim postojanjem kortikalne perforacije prednje ivice ramusa i gornje ivice alveolarnog dela mandibule. Operativni zahvat izveden je u dve faze. U prvoj fazi, tumor je uklonjen enukleacijom uz upotrebu Karnojevog rastvora i perifernom osteotomijom, sa ekscizijom okolno zahvaćene sluzokože. U drugoj fazi, šest meseci kasnije, rekonstruiran je postojeći defekt donje vilice. Postoperativno, nije registrovana nikakva komplikacija niti pojava recidiva dve godine nakon intervencije. **Zaključak.** Adekvatna i rana rekonstrukcija postojećeg viličnog defekta i odgovarajuća estetska i funkcionalna rehabilitacija ovih bolesnika treba da bude primaran cilj lečenja KCOT. Takođe, potrebno je sistematsko i dugotrajno postoperativno praćenje bolesnika.

#### Ključne reči:

ciste, odontogene; hirurgija, oralna, procedure; recidiv; hirurgija, rekonstruktivna, procedure; mandibula; lečenje, ishod.

## Introduction

Keratocystic odontogenic tumor (KCOT) is defined as a benign cystic neoplasm of the jaws of odontogenic origin<sup>1</sup>. Histological features are characterized by the presence of a thin band-like parakeratinized stratified squamous epithelium<sup>2,3</sup>. The most lesions occur in the posterior part of the mandible<sup>4</sup>.

Clinically, KCOT is one of the most aggressive behavior lesions, with the potential of rapid growth, and tendency for local intraosseal destruction, penetration to adjacent soft tissue and with a high rate of recurrence<sup>5</sup>. Treatment of KCOT remains controversial, but the goals of treatment should involve eliminating the potential for recurrence while also minimizing the surgical morbidity<sup>6</sup>.

Certainly, the most important therapeutic problem in dealing with KCOT is the risk of its recurrence, as well as the choice and radicalism of surgical procedure to minimize possibility of recurrence<sup>7-9</sup>.

However, treatment of these lesions has another major therapeutic problem, which is the choice of adequate reconstruction of the existing jaw defect after initial surgical treatment, and appropriate aesthetic and functional rehabilitation of the patient, especially in cases of a very large destruction of the jaws, with the aim that patients early regain functioning.

The purpose of this report was to present a patient with a very large KCOT of the mandible, which was removed by enucleation with the additional use of Carnoy solution, as well as peripheral ostectomy and excision of the affected overlying mucosa in the first phase, and restorative surgery of the mandibular defect in the second phase, followed-up postoperatively for 2 years.

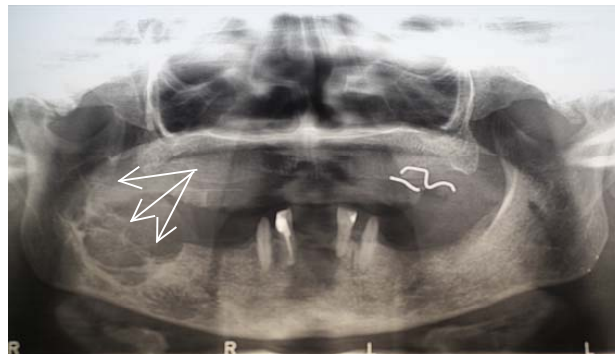
## Case report

A 65 year-old female patient was admitted to the Department of Oral Surgery, Military Medical Academy (MMA), Belgrade, because of expansion of the buccal cortex of the mandible body on the right side, as well as a large perimandibular soft tissue swelling. The patient had no other clinical symptoms. Orthopantomographic radiography showed a large elliptical multilocular radiolucency, located in the right side of the mandible body and the ascending ramus. Radiographic evidence of cortical perforation at the anterior border of the mandibular ramus and the superior border of the alveolar part of the mandible was also noted (Figure 1).

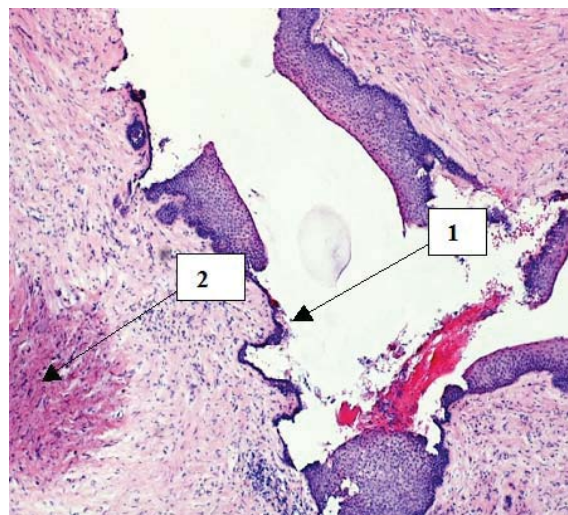
The patient was advised for surgical treatment after biopsy, because it is the adopted protocol for cases of the suspected KCOT or similar lesion. Due to the existing infection at the time of examination, antibiotic therapy was started (amoxicilin/clavulanic acid and metronidazole, orally). Ten days later, the patient underwent an incisional biopsy of the lesion under local anesthesia (4% Articain chloride<sup>TM</sup>, 3M ESPE).

The histopathologic finding was odontogenic cyst – keratocystic odontogenic tumor, indicating that tumor was

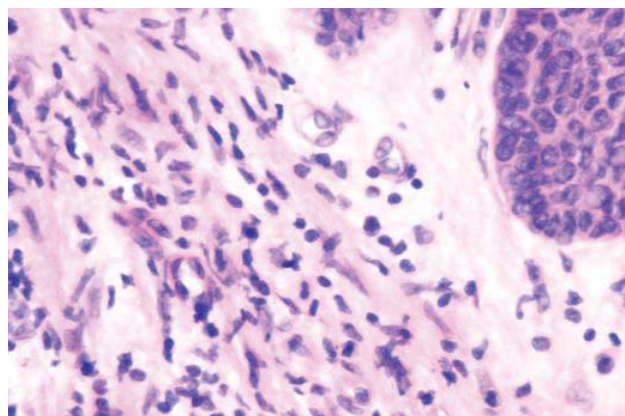
completely lined with squamous epithelium of parakeratotic type, without atypia. Secondary acute inflammation in the lumen of the lesion and partially in the epithelium was present (Figures 2–4).



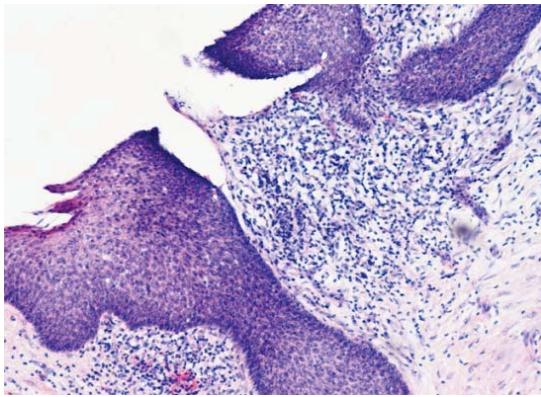
**Fig. 1 – Orthopantomographic radiography at the time of examination: a large elliptical multilocular radiolucency, located on the right side of the mandible, with radiographic evidence of cortical perforation (arrows).**



**Fig. 2 – Cystic squamous epithelium, showing atrophy and parakeratotic invaginations into the lumen (arrow 1): focal hemorrhage and fibroblast proliferation in the wall of the lesion (arrow 2) (H&E, 40×).**



**Fig. 3 – Inflammatory components in the wall of KCOT, mainly consisting of plasmocytes, with granulocytes to a lesser degree (H&E, 75×).**



**Fig. 4 – Separating granulation tissue between deep epithelial rete pegs at the site of ulceration (H&E, 40×).**

#### *The first surgery*

Upon receipt of the histopathological findings, the patient was advised to have the operation under general anesthesia on the in-patient basis. At the Clinic for Maxillofacial, Oral Surgery and Implantology of the MMA all the necessary laboratory analysis for surgery under general anesthesia were made, and at the Institute of Pharmacy of the MMA, Carnoy solution was prepared according to the following prescription: absolute alcohol – 6 mL, chloroform – 3 mL, glacial acetic acid – 1 mL and ferric chloride – 1 g.

Surgical procedure started with incision along the anterior border of the right mandibular ramus, then over the alveolar crest to the gingival margin till the right first premolar, including vertical relaxing incision down to the fornix in this region. After mucoperiosteal flap uplifting and separating the masseter and medial pterygoid muscle attachments, the defect of the anterior border of the ramus and the superior border of the alveolar part of the mandible, about 60 mm long, was seen. The defect was slightly widened caudally at its lateral aspect in order to approach the lesion and the intralésional septae were eliminated before enucleation of the tumor and application of Carnoy's solution. Then, the lesion was completely enucleated, a defect rinsed with saline, and a sterile gauze swab pre-soaked with Carnoy solution was placed in the lumen of the defect, for 3 minutes, then rinsed with saline to be able to see dark brown colored and fixated cystic wall remnants, and easily and completely remove them. After that, a peripheral os-

tectomy in the caudal and cranial direction was performed and the overlying attached mucosa was excised. After repeated rinsing with saline the wound was sutured, primarily. Postoperatively, the patient was prescribed intravenous antibiotics: ceftriaxon 2 g × 1 daily, aminoglicoside 1 g × 1 daily and metronidazole 0.5 g × 3 daily, for the following seven days. The sutures were removed after 7 days. No neurosensory deficit in the innervation area of the inferior alveolar nerve was present, as well as, any other postoperative complications.

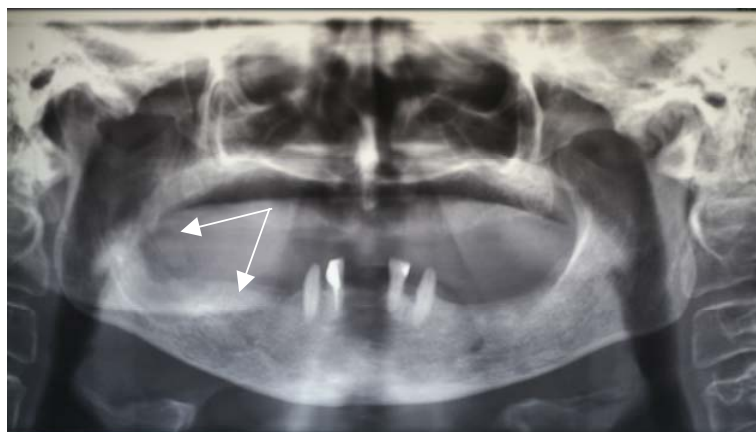
#### *The second (restorative) surgery*

The restorative surgery was performed about 6 months after the enucleation and peripheral ostectomy procedure, and included intraoral reconstruction of the existing mandibular defect.

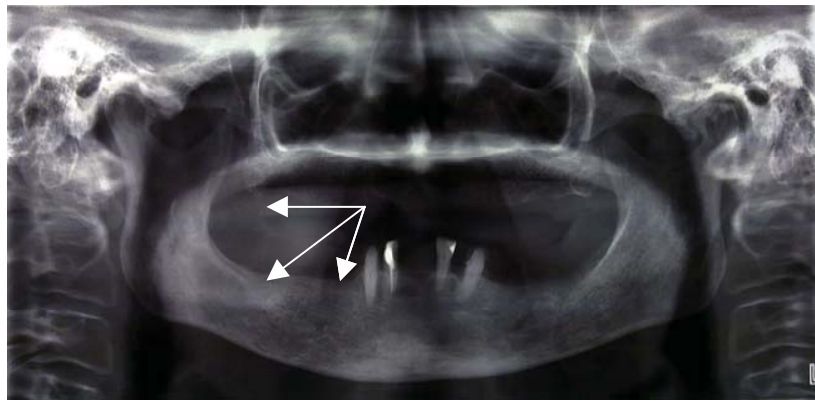
The second surgery was also performed on the inpatient basis under general anesthesia. Surgical procedure started with the same incision as in the first surgery. The mandibular defect was debrided of the fibrous tissue, which was taken for histological examination, and *ex tempore* histological report on the fibrous tissue removed from the mandibular defect and the soft tissue removed from the surrounding mucosa before graft placement was negative to KCOT. A heterogenous bone block (Osteovit®, B. Braun Melsungen AG.) was placed into the mandibular defect thereafter, and a spongy bone substitute (Bio-Oss®, Geistlich Pharma AG, Switzerland) was added around the bone block to fill the gaps. The intraoral wound was closed with 4-0 silk sutures, primarily. Postoperatively, the patient was prescribed antibiotics intravenously (ceftriaxon 2 g, once daily and metronidazole 0.5 g, 3 times daily) for the following 7 days. The sutures were removed after 7 days, and the patient was discharged without any postoperative complications.

Functional rehabilitation of the patient was completed with a pair of classic dentures six months after the second surgery, because the patient refused our suggestion for dental implantation and construction of dental implants-supported dentures.

The patient was followed up regularly, radiographically and clinically. After a 2-year period, orthopantomographic radiography confirmed a successful and complete bone healing of the previous mandibular defect on the right side of mandible, without recurrence of the lesion (Figures 5 and 6).



**Fig. 5 – The orthopantomographic radiography six months after the second surgery (arrows).**



**Fig. 6 – The orthopantomographic radiography, 2 years after second surgery, showing a complete and successful bone healing on the right side of the mandible (arrows).**

### Discussion

KCOT is one of the most commonly encountered odontogenic entities, thus requiring special consideration<sup>5</sup>. Renewed classification of odontogenic keratocysts to the KCOT by the World Health Organization (WHO) was based on the well-known aggressive behavior of this lesion, its histology and new information regarding its genetics<sup>4</sup>. Clinical evidence of its aggressive behavior is supported by reported cases penetrating the cortical bone and involving adjacent soft tissues<sup>5</sup>.

Generally, treatments of these lesions are classified as conservative or radical (aggressive), but there are several dilemmas and different opinions concerning the appropriate surgical approach<sup>10</sup>. Kolokythas et al.<sup>5</sup> suggested that the treatment modality should be chosen on the basis of clinical or radiographic evidence of cortical perforation and subsequent soft tissue involvement, and possible history of previous recurrences of the same lesion. The crucial problem is to determine when, and whether aggressive and radical therapy is necessary in treatments of these lesions.

It seems that there are 4 different, but very important and intriguing facts related to treatment of KCOT: firstly, a high rate of recurrence, as many authors reported frequency of recurrences up to 60%, especially within the first 5 to 7 years after initial surgery<sup>11–14</sup>; secondly, there are different surgical options, and the main goal would be to eliminate the potential for recurrence and minimize surgical morbidity; thirdly, there is a need, very often, for early reconstruction of bone defect and an adequate aesthetic and functional rehabilitation of the patient; and fourthly, there is a chance, although rarely, of malignant transformation<sup>15</sup>. Certainly, the first and second therapeutic problems are the most significant because recurrences may have serious consequences<sup>16</sup>.

In the literature review, the majority of studies reported relationship between the incidences of the recurrences and the choice of the surgical approach. A choice of applying completely conservative method in the treatment of KCOT may be justified if there is a risk of injury to the surrounding anatomic structures<sup>17–21</sup>, especially in children, where the use of aggressive surgical techniques can cause disturbances in the growth and development of jaws and teeth<sup>18</sup>. How-

ever, completely conservative methods (marsupialisation, decompression) have many disadvantages, primarily due to the fact that they imply incomplete removal of the lesion. After decompression and marsupialisation, some authors reported a considerable reduction of the cystic volume and levels of IL1- $\alpha$  and cytokeratin-10, which are related to the cystic expansion and metaplasia of the epithelial lining, meaning conversion to a less aggressive form<sup>11, 20–22</sup>. However, malignant alteration is still possible<sup>23, 24</sup>, and a very high rate of recurrence still exists<sup>5, 21, 22, 25</sup>. Finally, after completely conservative approaches, early reconstruction of the jaws defect is not possible.

On the contrary, jaw resection, as the most radical and aggressive therapeutic option, regardless the lowest rate of recurrence, should be used only in cases of frequent recurrences (more than three) and in patients where KCOT is associated with nevoid basal cell carcinoma syndrome<sup>5, 6, 8, 9, 14</sup>. Kolokythas et al.<sup>5</sup> and Tolstunov and Treasure<sup>9</sup> consider jaw resection as the initial surgical treatment in cases of KCOT showing more aggressive behavior (large and/or multilocular tumor). However, jaw resection produces a significant morbidity, the loss of the jaw continuity and facial disfigurement<sup>8</sup>. Although this surgical method offers the possibility of immediate reconstruction of the bone defect with iliac crest bone graft and the early return to function<sup>26</sup>, esthetic and functional rehabilitation of the patient might be inappropriate.

### Conclusion

We operated on the presented patient successfully for a large, multilocular KCOT by a less aggressive surgical approach (enucleation with the use of Carnoy's solution, peripheral ostectomy and excision of the affected overlying mucosa) without the loss of the jaw continuity. This surgical approach provided a significant possibility for adequate and early reconstruction of the jaw defect, resulting in better quality of life of the presented patient.

### Acknowledgements

The authors are grateful to Prof. Ljubomir Todorović for his encouragement to present this case report and for his valuable help in preparing the manuscript.

## R E F E R E N C E S

1. *Philipsen HP*. Keratocystic odontogenic tumour. In: *Barnes L, Eveson JW, Reichart P, Sidransky D*, editors. World Health Organization classification of tumours. Pathology and genetics of head and neck tumours. Lyon: IARC Press; 2005. p. 306–7.
2. *Brannon RB*. The odontogenic keratocyst. A clinicopathological study of 312 cases. Part II. Histologic features. *Oral Surg Oral Med Oral Pathol* 1977; 43(2): 233–55.
3. *Crowley TE, Kangars GE, Gunsolley JC*. Odontogenic keratocysts: a clinical and histologic comparison of the parakeratin and orthokeratin variants. *J Oral Maxillofac Surg* 1992; 50(1): 22–6.
4. *Madras J, Lapointe H*. Keratocystic odontogenic tumour: reclassification of the odontogenic keratocyst from cyst to tumour. *Tex Dent J* 2008; 125(5): 446–54.
5. *Kolokythas A, Fernandes RP, Pazoki A, Ord RA*. Odontogenic keratocyst: to decompress or not to decompress? A comparative study of decompression and enucleation versus resection/peripheral osteotomy. *J Oral Maxillofac Surg* 2007; 65(4): 640–4.
6. *Morgan TA, Burton CC, Qian F*. A retrospective review of treatment of the odontogenic keratocyst. *J Oral Maxillofac Surg* 2005; 63(5): 635–9.
7. *Pitak-Arnnon P*. Enucleation of keratocystic odontogenic tumours: study interpretation, technical refinement and future research. *Clin Oral Investig* 2010; 14(6): 719–21.
8. *Pitak-Arnnon P, Chainé A, Opresan N, Dhanuthai K, Bertrand JC, Bertolus C*. Management of odontogenic keratocysts of the jaws: a ten-year experience with 120 consecutive lesions. *J Craniomaxillofac Surg* 2010; 38(5): 358–64.
9. *Tolstanov L, Treasure T*. Surgical treatment algorithm for odontogenic keratocyst: combined treatment of odontogenic keratocyst and mandibular defect with marsupialization, enucleation, iliac crest bone graft, and dental implants. *J Oral Maxillofac Surg* 2008; 66(5): 1025–36.
10. *Stoeltinga PJ*. The treatment of odontogenic keratocysts by excision of the overlying, attached mucosa, enucleation, and treatment of the bony defect with Carnoy solution. *J Oral Maxillofac Surg* 2005; 63(11): 1662–6.
11. *Blanas N, Freund B, Schwartz M, Furst M*. Systematic review of the treatment and prognosis of the odontogenic keratocyst. *Oral Surg Oral Med Oral Pathol Oral Radiol Endod*. 2000; 90(5): 553–8.
12. *Boyne PJ, Hou D, Moretta C, Pritchard T*. The multifocal nature of odontogenic keratocysts. *J Calif Dent Assoc* 2005; 33(12): 961–5.
13. *Chebli H, Dhoubi M, Karray F, Abdelmoula M*. Risk factors for recurrence of maxillary odontogenic keratocysts. *Rev Stomatol Chir Maxillofac* 2010; 111(4): 189–92.
14. *Stoeltinga JW*. Long-term follow-up on keratocysts treated according to a defined protocol. *Int J Oral Max Fac Surg* 2001; 30(1): 14–25.
15. *Swinson DB, Jerjes W, Thomas JG*. Squamous Cell Carcinoma Arising in a Residual Odontogenic Cyst: Case Report. *J Oral Maxillofac Surg* 2005; 63(8): 1231–3.
16. *Matijević S, Damjanović Z, Lazjić Z, Gardašević M, Radenović-Durić D*. Peripheral osteotomy with the use of Carnoy's solution as a rational surgical approach to odontogenic keratocyst: a case report with 5-year follow-up. *Vojnosanit Pregl* 2012; 69(12): 1101–5.
17. *Zhao YF, Liu B, Jiang ZQ*. Marsupialization or decompression of the cystic lesions of the jaws. *Shanghai Kou Qiang Yi Xue* 2005; 14(4): 325–9. (Chinese)
18. *Hyun HK, Hong SD, Kim JW*. Recurrent keratocystic odontogenic tumor in the mandible: a case report and literature review. *Oral Surg Oral Med Oral Pathol Oral Radiol Endod* 2009; 108(2): e7–10.
19. *Nakamura N, Mitsuyasu T, Mitsuyasu Y, Taketomi T, Higuchi Y, Ohishi M*. Marsupialization for odontogenic keratocysts: Long-term follow-up analysis of the effects and changes in growth characteristics. *Oral Surg Oral Med Oral Pathol Oral Radiol Endod* 2002; 94(5): 543–53.
20. *Pogrel MA*. Treatment of keratocysts: the case for decompression and marsupialization. *J Oral Maxillofac Surg* 2005; 63(11): 1667–73.
21. *Giuliani M, Grossi GB, Lajolo C, Biscaglia M, Herb KE*. Conservative management of a large odontogenic keratocyst: report of a case and review of the literature. *J Oral Maxillofac Surg* 2006; 64(2): 308–16.
22. *Zhao YF, Wei JX, Wang SP*. Treatment of odontogenic keratocysts: a follow-up of 255 Chinese patients. *Oral Surg Oral Med Oral Pathol Oral Radiol Endod* 2002; 94(2): 151–6.
23. *Chaisuparat R, Coletti D, Kolokythas A, Ord RA, Nikitakis NG*. Primary intraosseous odontogenic carcinoma arising in an odontogenic cyst or de novo: a clinicopathologic study of six new cases. *Oral Surg Oral Med Oral Pathol Oral Radiol Endod* 2006; 101(2): 194–200.
24. *Leitner C, Hoffmann J, Kröber S, Reinert S*. Low-grade malignant fibrosarcoma of the dental follicle of an unerupted third molar without clinical evidence of any follicular lesion. *J Craniomaxillofac Surg* 2007; 35(1): 48–51.
25. *Gosau M, Draenert FG, Müller S, Frerich B, Bürgers R, Reichert TE, Driemel O*. Two modifications in the treatment of keratocystic odontogenic tumors (KCOI) and the use of Carnoy's solution (CS)—a retrospective study lasting between 2 and 10 years. *Clin Oral Investig* 2010; 14(1): 27–34.
26. *Barry CP, Kearns GJ*. Case report-odontogenic keratocysts: enucleation, bone grafting and implant placement: an early return to function. *J Ir Dent Assoc* 2003; 49(3): 83–8.

Received on March 10, 2012.

Accepted on June 11, 2012.