



## Tolosa-Hunt syndrome: is it really necessary to show granuloma? – The report on eight cases

### Tolosa-Hunt sindrom: da li je neophodno prikazati granulom?

Ana Podgorac\*<sup>†</sup>, Jasna Zidverc-Trajković\*\*<sup>‡</sup>, Zagorka Jovanović\*\*<sup>‡</sup>,  
Aleksandar Ristić\*\*<sup>‡</sup>, Aleksandra Radojičić\*\*<sup>‡</sup>, Aleksandra Pavlović\*\*<sup>‡</sup>,  
Milija Mijajlović\*\*<sup>‡</sup>, Tamara Švabić-Medjedović<sup>‡</sup>, Nadežda Čovičković Šternić\*\*<sup>‡</sup>

\*Faculty of Medicine, University of Belgrade, Belgrade, Serbia; <sup>†</sup>Neurology Clinic,  
Clinical Center of Serbia, Belgrade, Serbia; <sup>‡</sup>Institute of Mental Health,  
Belgrade, Serbia

#### Abstract

**Introduction.** Tolosa–Hunt syndrome (THS) is a rare entity, characterized by unilateral orbital pain associated with paresis of one or more of the oculomotor cranial nerves and caused by a granulomatous inflammation in the cavernous sinus, superior orbital fissure or orbit. The low prevalence of THS with a broad spectrum of other disorders that could cause painful ophthalmoplegia resulted in a stricter diagnostic criteria of THS in the latest edition of the International Classification of Headache Disorders. Current criteria require demonstration of granuloma by magnetic resonance imaging or biopsy. The diagnosis could be difficult and the initiation of treatment delayed due to a high variability of clinical presentation of THS. Reducing the number of patients that, based on clinical presentation, could be classified as having THS, but do not fulfill all diagnostic criteria further complicates establishing of correct diagnosis. **Case report.** Hereby we presented eight patients diagnosed with and treated for THS. In spite the exclusion of other causes of painful ophthalmoplegia, granuloma could not be demonstrated in a half of patients. Clinical presentation of THS in patients with and without shown granuloma, did not significantly differ concerning headache characteristics (localization, intensity, quality, duration preceding cranial nerve palsy, response to steroids), the affected cranial nerve, disease course and response to the treatment, as well as types of diagnostic procedures that were performed in ruling out other diseases from the extensive differential diagnosis of painful ophthalmoplegia. **Conclusion.** There is no significant difference between the THS patients with and without demonstrated granuloma.

#### Key words:

tolosa-hunt syndrome; brain; diagnosis; diagnosis, differential; magnetic resonance imaging.

#### Apstrakt

**Uvod.** Sindrom Tolosa–Hunt (THS) je redak entitet koji se odlikuje jednostranim orbitalnim bolom udruženim sa parezom jednog ili više okulomotornih nerava, uzrokovanim granulomatoznim zapaljenjem kavernoznog sinusa, gornje orbitalne fisure ili orbite. Niska prevalencija ovog sindroma, kao i široki spektar drugih oboljenja koja bi mogla uzrokovati bolnu oftalmoplegiju, doprineli su pooštavanju dijagnostičkih kriterijuma za THS u poslednjem izdanju Međunarodne klasifikacije glavobolja. Važećim kriterijumima zahleba se dokazivanje prisustva granuloma magnetnom rezonancom ili biopsijom. Visoka varijabilnost kliničke prezentacije THS može biti uzrok otežanog postavljanja dijagnoze, uz odlaganje početka lečenja. Smanjenje broja bolesnika koji bi na osnovu kliničke slike mogli imati THS, ali ne ispunjavaju sve dijagnostičke kriterijume, dalje komplikuje i odlaže pravovremeno postavljanje tačne dijagnoze. **Prikaz bolesnika.** Prikazali smo osam bolesnika lečenih pod dijagnozom THS. I pored isključenja drugih uzroka bolne oftalmoplegije, granulom nije bilo moguće prikazati kod četiri bolesnika. Klinička prezentacija THS kod bolesnika sa i bez dokazanog prisustva granuloma, nije se razlikovala značajno kada su u pitanju osobine glavobolje (lokalizacija, intenzitet, kvalitet, trajanje pre razvoja slabosti okulomotora, odgovor na kortikosteroidnu terapiju), zahvaćenost kranijalnih nerava, trajanje bolesti i odgovor na terapiju, kao ni dijagnostički postupak sproveden sa ciljem isključivanja drugih bolesti koje bi mogle biti uzrok bolne oftalmoplegije. **Zaključak.** Ne postoji značajna razlika između bolesnika sa THS bez obzira na to da li je granulom dokazan ili ne.

#### Ključne reči:

tolosa-huntov sindrom; mozak; dijagnoza; dijagnoza, diferencijalna; magnetna rezonanca, snimanje.

## Introduction

Tolosa–Hunt syndrome (THS)<sup>1,2</sup> is a rare entity, described in the latest, 3rd, beta version of The International Classification of Headache Disorders (ICHD), as unilateral orbital pain associated with paresis of one or more of the III, IV and/or VI cranial nerves caused by a granulomatous inflammation in the cavernous sinus, superior orbital fissure or orbit<sup>3</sup>.

The low prevalence of THS with broad spectrum of other disorders that could cause painful ophthalmoplegia resulted in stricter diagnostic criteria of THS in ICHD-III.

Current criteria require demonstration of granuloma by magnetic resonance imaging (MRI) or biopsy, while the prompt positive response on steroid treatment, as not specific treatment only of THS, had been excluded from diagnostic criteria.

In clinical practice, THS is highly variable in its presentation<sup>4</sup>, thus, reducing the number of patients that, based on clinical presentation could be with THS, but do not fulfill all diagnostic criteria, complicates establishing of the correct diagnosis on time to start treatment.

Hereby we present eight patients diagnosed with and treated as THS in our Headache Center during the period of 13 years, picked up from over 5,800 examined patients. In further reading it will be shown that granuloma could not have been demonstrated by MRI examination in a half of the patients meeting clinical criteria for THS.

## Case reports

### Case 1

During the period of six years, from her 48 to 54 years of life, this woman suffered from five episodes of right-sided headache separated by headache free periods lasted from 1 to 4 years. All episodes had similar presentation consisting of constant pain localized on the right side of the forehead and in the right orbital region, that was sharp and of moderate intensity, irresponsive to analgesics. The headache used to last for ten days and then inability to make complete abduction of the right eye with double vision occurred. Additionally, during the second episode, besides the six cranial nerve palsy, the ptosis of the right palpebra, inability to adduct the right eye, or move it in vertical direction, was noticed, pointing to the affection of the 3rd cranial nerve, too. On neurological examination, there was no other abnormalities. In the personal history, mild hypertension and chronic gastritis, without permanent therapy, were recorded.

Extensive diagnostic procedures had been performed and repeated during multiple hospitalizations. Blood examination, considering biochemical parameters, blood cells, coagulation, immunology and thyroid hormones levels, were completely normal. The biochemical examination and cytological examination of cerebrospinal fluid (CSF) were completely normal, as well. Oligoclonal bands were not detected. Echsonography of orbits and MRI of the brain, particularly cavernous sinus regions (1.5T, 3 mm thickness) were normal. Control MRI of the brain, performed during every single relaps showed normal findings.

The patient was treated with steroids, in some episodes orally with 60–80 mg of prednisolone *per os* daily, while in others intravenously with methylprednisolone, 120 mg to 1,000 mg daily for 7–14 days followed by oral steroid therapy for several months. The response to steroid treatment, concerning headache, was prompt, resolving pain in 72 hours. Still, the recovery was incomplete concerning bulbo-motor paresis, with diplopia lasting for several months.

### Case 2

During the period of seven years, from her 60 to 67 years of life, this woman suffered from six episodes of left-sided constant intensive orbital pain, being after ten days associated with ptosis of the left palpebra and paralysis of the left bulb. Hypoesthesia in the distribution of V1 and V2 branches of the trigeminal nerve were present, as well. In personal history, mild hypertension and dyslipidemia were recorded. Bilateral mild hearing impairment was present too, for several years.

Blood examination, considering biochemical parameters, blood cells, coagulation, immunology and thyroid hormones levels, were completely normal. Biochemical and cytology examinations of CSF were completely normal, as well. Repeated MRI of the brain, with the special sections through the *ala minor* (1.5T, 3 mm thickness), showed multiple ischemic lacunar lesions, localized in paraventricular regions, bilaterally, without any other abnormality, particularly in cavernous sinus regions. The result of digital subtraction angiography (DSA) was normal. MRI of orbits, MRI angiography and phlebography were normal, as well.

In each episode, the patient was treated with oral steroid therapy, prednisolone 60 mg *per os* daily, which set her pain free with remaining hypoesthesia in the distribution of V1 branch on the left. The steroid dose was tapered to 10 mg daily, which became permanent because of symptoms relapses on every attempt of steroid withdrawal. After several years, the patient developed diabetes mellitus.

### Case 3

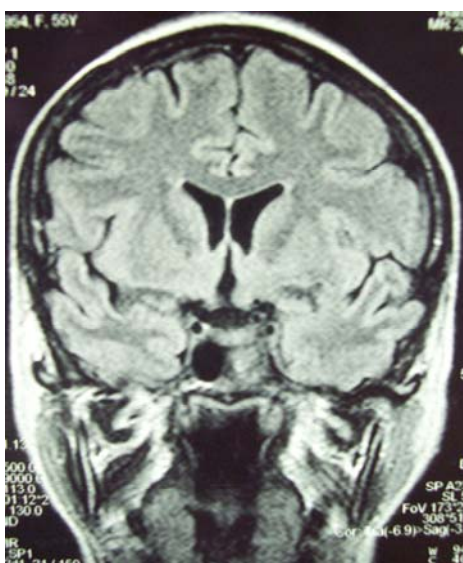
A 56-years-old women was examined because of onset of intense, throbbing-like headache located at the base of the nose on the left side. The pain was irradiating to the left supraorbital and frontotemporal region. During the next month the patient experienced everyday, mostly bilateral facial pain treated unsuccessfully with antibiotics and analgesics. More than 5 weeks after the first symptoms, the patient noticed weakness of her left upper eyelid palpebra. Over the next 2 weeks this was accompanied by decreased mobility of the left eye bulb. Neurologic examination revealed ptosis of the left palpebra, plegia of the left bulb with the possibility of only mild abduction and hypoesthesia in the area of V2 nerve distribution. The rest of examination was unremarkable.

MRI examination (1.5T, 3 mm thickness) showed a mass in the left cavernous sinus without propagation to the near structures and without contrast enhancement (Figure 1).

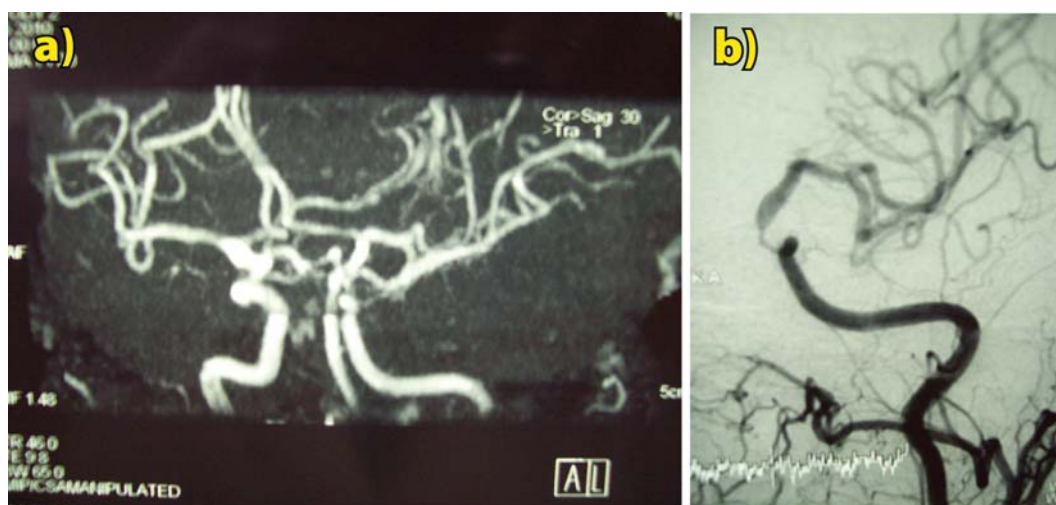
Radiologic appearance was mostly consistent with inflammatory/granulomatous infiltration. Subocclusion, due to external compression, of the intracavernous segment of the left internal carotid artery was visualized on cerebral panangiography (Figures 2 a and b). Biochemistry panel tests, full blood count, coagulation screening tests and urine analysis were within reference ranges. Additional testing included immunoserology (circulating immunocomplexes, antinuclear, antinucleocytoplasmatic and anticardiolipine antibodies), thyroid function tests, 24 h calciuria, serum angiotensin-converting enzyme (ACE) level and chest computed tomography – all normal. Lumbar puncture was performed, with protein levels 0.51 g/L, 3.5 mmol/L of glucose and 1 lymphocyte. CSF was analyzed for syphilis *Treponema pallidum* haemagglutination (TPHA), *Borrelia burgdorferi* (ELISA), tuberculosis (acidoresistant staining, culture), *Cryptococcus* (direct staining) and common parasitic patho-

gens (*Cysticercus*, *Toxoplasma*, *Echinococcus*), with negative results. CSF sediment was without pathologic elements.

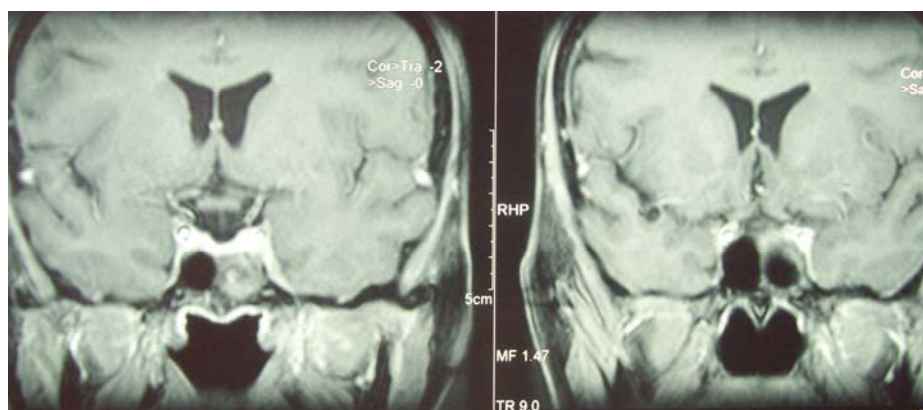
High-dose pulse corticosteroid therapy (methylprednisolone 1 g, *iv* during 7 days) was initiated. Orbital pain responded dramatically after 24 h and resolved completely after < 36 h of steroid introduction. Very discrete, but progressive ocular motility was observed during the next 7 days and after that the patient was followed as outpatient. The therapy switched to oral prednisolone (80 mg daily) and tapered down in one month intervals to the maintenance dose of 20 mg, every second day. Full ocular motility was established 3 weeks after the initial steroid dose, but mild ptosis of the left palpebra and hypoesthesia in V1 distribution were still present three months after. Control MRI showed infiltration of the left cavernous sinus, without progression or regression in comparison to the former imaging (Figure 3).



**Fig. 1 – Magnetic resonance imaging (MRI) focused on sellar and parasellar region – infiltration of the left cavernous sinus.**



**Fig. 2 – a) Magnetic resonance angiography (MRA) shows subocclusion of the cavernous portion of the left internal carotid artery; b) Digital subtraction angiography (DSA) finding of subocclusion of the left internal carotid artery.**



**Fig. 3 – Control magnetic resonance imaging (MRI) focussed on sellar and parasellar region – no progression, no regression [in comparison with the previous finding (Fig. 1)]**

#### Case 4

A 53-years-old man was admitted two days after experiencing left gaze diplopia and dull, constant left-sided retroorbital headache. During the first week of hospitalization his status progressed with the development of left-sided ptosis, mydriasis and complete left external ophthalmoplegia. Neurological examination revealed complete paralysis of the oculomotor, trochlear and abducens nerves with the involvement of the first two trigeminal nerve branches. There were no other pathological signs in neurological examination.

MRI of the brain showed infiltration of the left cavernous sinus, most consistent with granulomatous infiltration. Computed tomography (CT) angiography of the brain was normal. Laboratory analyses included general biochemistry panel, complete blood count, urinalysis, immunoserology panel (antinuclear, antinucleocytoplasmatic and anticardiolipin autoantibody titers), ACE, chitotriosidase levels and thyroid hormone levels, all showing normal results. Cerebrospinal fluid biochemistry, cytology, polymerase chain reaction (PCR) for *Mycobacterium tuberculosis*, bacteriological cultures, analysis for *Cryptococcus neoformans*, TPHA, ELISA for *Borrelia burgdorferi* and ACE were all also normal or within the reference range.

The patient was treated with high-pulse corticosteroid therapy (methylprednisolone, 1gr iv for 7 days) with resolution of pain (within 72 h) and progressive recovery of affected cranial nerve function. Three weeks after the therapy was started, the patient was pain free with discrete mydriasis of the left pupil and minimal diplopia in extreme lateral gaze. Therapy was continued with oral prednisolone (60 mg), the patient was discharged and followed as an outpatient. In the next two years, the patient was asymptomatic.

#### Case 5

A 38-year old women experienced abrupt onset of left gaze diplopiae and intense, permanent left hemicrania, with a gradual localization of pain in the left orbital region. Neurologic examination revealed impaired function of the left lateral rectus muscle. In the past medical history, the patient had partial thyroidectomy one month prior to the actual symptom onset which revealed a solitary colloid cyst.

MRI of the brain was notable for asymmetry in the cavernous sinus regions, with diffuse enlargement of the left cavernous sinus without post-contrast enhancement. CT angiography disclosed patent intracranial vessels. Laboratory analyses included general biochemistry panel, complete blood count, urinalysis, basic immunologic screening which all yielded normal results. Cytology, biochemistry, mycobacterial cultures, staining for *Cryptococcus neoformans*, TPHA and ELISA detecting *Borrelia*, as well as ACE retrieved the results within the reference range in CSF. We, however, noted slightly increased levels of chitotriosidase in CSF, but complementary tests aimed at detecting sarcoidosis were normal.

After introduction of pulse corticosteroid therapy (methylprednisolone, 1g for 7 days) a substantial, but not complete, improvement of left eye bulb motility was noted. Pain intensity was reduced but did not extinct. Two months later and after corticosteroid dose had been tapered to 10 mg of prednisolone on the second day, the patient condition got worse with the same symptoms and signs as at disease onset, which required additional methylprednisolone pulse to control the symptoms. Follow-up examination, performed two months after the relapse, revealed a complete recovery maintained for the next 18 months, till the last check-up. The latest, control MRI of the brain was normal.

#### Case 6

A 68-years old woman, examined because of headache that occurred suddenly, presented with pain in the left eye bulb and forehead, lasting for days, followed by left palpebra ptosis and diplopia. Neurological examination revealed paralysis of the left oculomotor, ophthalmic and abducens nerves.

Blood examination, considering biochemical parameters, blood cells, coagulation, immunology and thyroid hormones levels, tumor markers, was completely normal. The biochemical and cytology examination of CSF was completely normal, as well. MRI of the brain showed minimal infiltration of the apical region of the left orbit and the left cavernous sinus with post-contrast enhancement in signal intensity, dominantly on T1W FS MR tomograms. MRI angiography did not show abnormalities in blood vessels of the brain.

The high pulse corticosteroid therapy (methylprednisolone 1 g, given intravenously for 7 days) led to incomplete recovery with still present impaired function of the left abducens, in one week. The therapy was continued with oral prednisolone (80 mg daily), gradually tapered and switched of in one month.

Six months later, paresis of the left abducens was still present, the patient went through symptoms of impairment of the left ophthalmic nerve again.

Control MRI of the brain did not show infiltration of the apical region of the left orbit and the left cavernous sinus that had been previously shown. The patient was advised to continue with oral prednisolone (20 mg daily) for the next four weeks, recovered completely, and on the last check-up, six months later, was without pathological symptoms and signs.

#### Case 7

A 69-years old woman, was examined because of intensive, throbbing headache localized in the right eye bulb, constant and lasting for 20 days, followed by right palpebra ptosis and diplopia. Neurological examination revealed paralysis of right oculomotor and trochlear nerves.

Blood examination, considering biochemical parameters, blood cells, coagulation, immunology and thyroid hormones levels, tumor markers, was completely normal. Biochemical and cytology examination of CSF was completely normal, as well. MRI of the brain, particularly cavernous sinus regions (1.5T, 3 mm thickness) was normal. MRI angiography did not show abnormalities in blood vessels of the brain.

The high pulse corticosteroid therapy (methylprednisolone 1g, given intravenously, for 7 days) in 48 hours brought pain relief and improvement of motility of the right bulb, with still present semiptosis and incomplete adduction. The therapy was continued with oral prednisolone (60 mg daily), gradually tapered and switched of in six months.

Six months later, after steroids withdrawal, the patient went through pain of the same characteristics as she did before, still without symptoms of impairment of cranial nerves.

Control MRI of the brain did not show any pathological finding. The patient was advised to continue with oral prednisolone (20 mg daily). In ten days, the patient was pain-free, continuing with this therapy for the next six weeks. On the

last check-up, two months later, the patient was without pathological symptoms and signs.

#### Case 8

A 53-year-old man was examined due to moderate pain in the right orbit, abrupt in its onset, followed by diplopia and ptosis of the right palpebra. Neurological examination revealed dysfunction of the 3rd and 4th cranial nerves. Extensive blood and CSF examination showed all results normal. MRI of the brain showed granulomatous infiltration of the right cavernous sinus. Introduction of pulse corticosteroid therapy (methylprednisolone, 1 g for 7 days) set him pain-free in 3 days, with residual semiptosis and incomplete adduction. Corticosteroid therapy was continued orally with 40 mg of prednisolone daily until check-up scheduled in 6 weeks. Control MRI of the brain was scheduled in 3 months.

Summary of clinical presentations of THS, meaning characteristics of headache and cranial nerves paresis, in our patients, are given in Tables 1 and 2. MRI findings are given in Table 3.

#### Discussion

According to the ICHD-III criteria for THS, to establish THS diagnosis patients should have unilateral headache localized around the brow and the eye that precedes in the period up to two weeks ipsilateral paresis of oculomotor nerve(s) and confirmed granulomatous inflammation of the cavernous sinus, superior orbital fissure or orbit, by MRI or biopsy<sup>3</sup>.

The presented patients completely satisfied clinical criteria for THS diagnosis. In all the patients, the same panel of diagnostic procedures was performed in order to rule out other pathological disorders involving cavernous sinus and orbit. Nowadays, biopsy is rarely performed in order to confirm the diagnosis of THS, so that the diagnosis relies on MRI finding. The four of eight presented patients lack MRI confirmation; otherwise, their clinical presentation was similar to the presentation of patients with the confirmed cavernous sinus granuloma.

ICHD-3 do not give specified features for headache in THS, besides the unilateral pain localized around the brow and

Table 1

Headache features in the presented Tolosa-Hunt syndrome patients

Patient	Localization	Intensity of pain	Quality of pain	Time gap between the headache onset and cranial nerve(s) paresis (days)	Disappearance of pain after initiation of steroids (days)
1	R forehead and orbit	moderate	sharp	10	3
2	L orbit	intensive	sharp	10	3
3	L forehead, orbit and temple	intensive	throbbing	35	2
4	L retro-orbital	moderate	dull	immediately	3
5	L orbit	intensive	sharp	immediately	7
6	L forehead and orbit	intensive	sharp	10	7
7	R orbit	intensive	throbbing	20	2
8	R orbit	moderate	dull	5	3

R – right; L – left.

Table 2

Cranial nerves palsy in the presented Tolosa-Hunt syndrome patients					
Patient	Affected cranial nerve(s)	Disappearance of paresis after initiation of steroids period	Residual deficit	Number of relapses	Monitoring time duration
1	III, VI	> 3 months	VI	4	6 years
2	III, V <sub>1</sub> , V <sub>2</sub> , VI	> 3 months	V <sub>1</sub>	5	7 years
3	III, IV, V <sub>1</sub> , V <sub>2</sub> , VI	3 weeks	III, V <sub>1</sub>	0	2 months
4	III, IV, V <sub>1</sub> , V <sub>2</sub> , VI	3 weeks	no	0	2 years
5	VI	> 3 months	no	1	18 months
6	III, V <sub>1</sub> , VI	> 3 months	no	1	6 months
7	III, IV	> 3 months	no	1	6 months
8	III, IV	3 weeks	III	0	3 months

Table 3

Magnetic resonance imaging (MRI*) findings in the presented Tolosa-Hunt syndrome patients		
Patient	The first MRI	Control MRI
1	Normal	Normal
2	Normal	Normal
3	Granulomatous infiltration in the left cavernous sinus	Unchanged
4	Granulomatous infiltration of the left cavernous sinus	Not performed
5	Diffuse enlargement of the left cavernous sinus	Normal
6	Infiltration of the apical region of the left orbit and the left cavernous sinus	Normal
7	Normal	Normal
8	Granulomatous infiltration of the right cavernous sinus	Not performed

\*Examinations performed with 3 mm thickness coronal and axial T1-SE and T2-SE sequences and with T1 FS weighted images after gadolinium administration at the level of the orbit and cavernous sinus.

eye. Analyses of headache features, summarized in Table 1, revealed that pain was always localized in the orbit, and in more than half of the patients, in the ipsilateral part of the forehead. Pain was mostly intensive, rarely moderate, mainly sharp and throbbing, exceptionally dull. According to the literature<sup>4,5</sup>, in THS pain is typically periorbital, or in some cases retroorbital, frontal or temporal. It is described as intense, sometimes as “boiling” or “stabbing.” In our group of THS patients, headache was immediately, or within 10 days, followed by paresis of the cranial nerves, with the exception of one patient who had headache lasting for 5 weeks before cranial nerves paresis occurred. The time gap exceeding two weeks was reported in 11% of patients in large THS cohort, reported by Zhang et al.<sup>6</sup>.

Concerning pain, all the patients had good response to corticosteroids, becoming pain-free within 2 to 7 days after the initiation of the therapy. Colnaghi et al.<sup>7</sup> reported pain resolution within 72 hours after initiation of corticosteroids in 78% of 38 cases of THS, picked-up from 536 articles published between 1999 and 2007.

The most commonly affected cranial nerve was the 3rd cranial nerve being affected in all but one patients (Table 2). The 6th cranial nerve was affected in six cases, the first or the second division of the trigeminal nerve in four cases and the 4th cranial nerve in four patients. Zhang et al.<sup>6</sup> reported that the 3rd cranial nerve was affected in three quarters of THS patients, being the most commonly affected of all, as well. Four out of eight patients reported sensory disturbances in distribution of ophthalmic branch of trigeminal nerve and additionally, of maxillary branch in three of them. In our patients, the involvement of the V2 occurred only in patients with the simultaneous involvement of other nerves of cavernous sinus. Looking

the cavernous sinus anatomy, the position of the V2 is in the lowest portion of the sinus, exiting outside the orbital apex<sup>8</sup>. Clinical presentation with V2 involvement could point to the more extensive pathological process visible by MRI. Still, MRI lesion was found in the Case No 2.

Concerning paresis of the cranial nerves, in all the patients, response to corticosteroids was delayed comparing to headache resolution, which is in accordance with findings of other studies<sup>9</sup>. Recovery was incomplete in a half of our patients (Table 2).

The most prominent observation in these patients is that the lack of granuloma verified by MRI was noticed in two patients with multiple relapses (Table 3).

So, in those patients the diagnosis of recurrent painful ophthalmoplegic neuropathy, coded with 13.9 in ICHD-3, could not be excluded. Namely, for establishing this diagnosis, at least two attacks of unilateral headache, accompanied by ipsilateral paresis of ocular motor nerves, are required, with the exclusion of intracranial lesions. The time gap between headache and nerve palsy should not exceed two weeks, just like in THS. Moreover, recent data demonstrate gadolinium enhancement or nerve thickening by MRI in these patients<sup>10,11</sup>, still that type of MRI changes is not shown in any of our patients.

Corticosteroid treatment is beneficial in some patients, just like in THS. So, it seems that the term “recurrent painful ophthalmoplegic neuropathy”, coined in order to reject an old and inappropriate term of ophthalmoplegic migraine, now overlaps with THS, at least in some patients.

Three out of eight patients had negative findings on MRI, and two of them had clinical course with multiple relapses. Although it has been suggested that a normal MRI

study should exclude the diagnosis of THS<sup>3, 12</sup>, in the lack of more suitable diagnosis, the authors considered those patients as patients with Tolosa-Hunt syndrome. In accordance with the opinion of some authors<sup>13, 14</sup>, our opinion is that the diagnosis of THS is clinical and finding of granuloma using MRI or biopsy should not be obligatory.

## Conclusion

There is no significant difference in clinical presentation of THS in patients with and without demonstrated granuloma.

The diagnosis of THS is clinical and finding of granuloma using MRI or biopsy should not be obligatory.

## R E F E R E N C E S

1. *Hunt WE*. Tolosa-Hunt syndrome: One cause of painful ophthalmoplegia. *J Neurosurg* 1976; 44(5): 544–9.
2. *Tolosa E*. Periarteritic lesions of the carotid siphon with the clinical features of a carotid infraclinoidal aneurysm. *J Neurol Neurosurg Psychiatr* 1954; 17(4): 300–2.
3. Headache Classification Committee of the International Headache Society (IHS). The International Classification of Headache Disorders (beta version). *Cephalalgia* 2013; 33(9): 629–808.
4. *La Mantia L, Curone M, Rapoport A, Bussone G*. Tolosa-Hunt syndrome: Critical literature review based on IHS 2004 criteria. *Cephalalgia* 2006; 26(7): 772–81.
5. *Kline LB, Hoyt WF*. The Tolosa-Hunt syndrome. *Neurol Neurosurg Psychiatry* 2001; 71:577–82.
6. *Zhang X, Zhou Z, Steiner TJ, Zhang W, Liu R, Dong Z, et al*. Validation of ICHD-3 beta diagnostic criteria for 13.7 Tolosa-Hunt syndrome: Analysis of 77 cases of painful ophthalmoplegia. *Cephalalgia* 2014; 34(8): 624–32.
7. *Colnaghi S, Versino M, Marchioni E, Pichiecchio A, Bastianello S, Cosi V, et al*. ICHD-II diagnostic criteria for Tolosa-Hunt syndrome in idiopathic inflammatory syndromes of the orbit and/or the cavernous sinus. *Cephalalgia* 2008; 28(6): 577–84.
8. *Lee JH, Lee HK, Park JK, Choi CG, Sub DC*. Cavernous sinus syndrome: Clinical features and differential diagnosis with MR imaging. *AJR Am J Roentgenol* 2003; 181(2): 583–90.
9. *Cakirer S*. MRI findings in Tolosa-Hunt syndrome before and after systemic corticosteroid therapy. *Eur J Radiol* 2003; 45(2): 83–90.
10. *Bharucha DX, Campbell TB, Valencia I, Hardison HH, Kothare SV*. MRI findings in pediatric ophthalmoplegic migraine: a case report and literature review. *Pediatr Neurol* 2007; 37(1): 59–63.
11. *Gelfand AA, Gelfand JM, Prabakar P, Goadsby PJ*. Ophthalmoplegic "migraine" or recurrent ophthalmoplegic cranial neuropathy: new cases and a systematic review. *J Child Neurol* 2012; 27(6): 759–66.
12. *Jain R, Sambney S, Koul RL, Chand P*. Tolosa-Hunt syndrome: MRI appearances. *J Med Imaging Radiat Oncol* 2008; 52(5): 447–51.
13. *Abdelghany M, Orozco D, Fink W, Begley C*. Probable Tolosa-Hunt syndrome with a normal MRI. *Cephalalgia* 2015; 35(5): 449–52.
14. *Hao R, He Y, Zhang H, Zhang W, Li X, Ke Y*. The evaluation of ICHD-3 beta diagnostic criteria for Tolosa-Hunt syndrome: A study of 22 cases of Tolosa-Hunt syndrome. *Neurol Sci* 2015; 36(6): 899–905.

Received on July 3, 2015.

Revised on August 5, 2015.

Accepted on October 21, 2015.

Online First July, 2016.