



Autoimmune pancreatitis type 1 and type 2: A report on two cases

Autoimunski pankreatitis tipa 1 i 2

Irina Brčerević*†, Radoje Doder*†, Nenad Perišić*, Stanko Petrović*,
Jasna Jović*†, Dejan Hristović‡, Zoran Djordjević§, Olga Tasić Radić||

*Clinic for Gastroenterology and Hepatology, †Clinic for Infectious and Tropical Diseases, §Institute of Radiology, ||Institute of Pathology, Military Medical Academy, Belgrade, Serbia; ‡Faculty of Medicine of the Military Medical Academy, University of Defence, Belgrade, Serbia

Abstract

Introduction. Autoimmune pancreatitis is a disease associated with autoimmune mechanisms, clinically manifested mostly as obstructive icterus with or without partial enlargement of the pancreas, histological lymphoplasmacytic infiltration, fibrosis or granulocytic epithelial lesions with a favourable therapeutic response to the application of corticosteroids. Type 1 autoimmune pancreatitis is a systemic disease befalling the group of IgG4-related diseases in contrast to type 2 which is specific for pancreas disease. **Case report.** We presented two cases. The first one was a 64-year-old male patient with autoimmune pancreatitis complaining of abdominal pain, weight loss, weakness and exhaustion. Clinical examination showed a rare IgG4 autoimmune pancreatitis. The second one was a 37-year-old male patient complaining of abdominal pain with diarrhea. The diagnosis made revealed the presence of type 2 autoimmune pancreatitis. Following the diagnosis, immunosuppressive therapy was administered to both patients leading to the improvement of their general condition. **Conclusion.** Autoimmune pancreatitis is a rare disease, sometimes not easy to differ from pancreatic tumor or bile duct tumor with poor prognosis. Thus, early recognition of the disease is very important, since adequate treatment significantly increases the course and the outcomes of the disease.

Key words:

pancreatitis; autoimmune diseases; diagnostic techniques and procedures; diagnosis, differential; drug therapy.

Apstrakt

Uvod. Autoimunski pankreatitis (AP) je oboljenje čiji nastanak se povezuje sa autoimunskim mehanizmima i klinički se najčešće manifestuje opstruktivnim ikterusom sa ili bez uvećanja čitavog ili dela pankreasa, histološki limfoplazmocitnom infiltracijom, fibrozom ili granulocitno-epitelnim lezijama uz povoljan terapijski odgovor na primenu kortikosteroida. AP tipa 1 je sistemsko oboljenje koje pripada grupi IgG4 udruženih bolesti. **Prikaz bolesnika.** Prikazali smo dva bolesnika. Prvi bolesnik, star 64 godine, sa AP tipa 1, žalio se na bolove u trbuhu, gubitak telesne mase, slabost i malaksalost. Kliničko ispitivanje pokazalo je da se radi o retkom IgG4 AP. Drugi bolesnik, star 37 godina, na prijemu imao je stomadne bolove u predelu pojasa i tečne stolice. Postavljena dijagnoza otkrila je prisustvo autoimunskog pankreatitisa tipa 2. Oba bolesnika lečena su imunosupresivnom terapijom koja je popravila njihovo opšte stanje. **Zaključak.** AP predstavlja retko oboljenje koje je nekada teško razlikovati od tumora pankreasa ili bilijarnog trakta koji ima lošu prognozu. Stoga, veoma je važna rana dijagnoza pošto adekvatno lečenje značajno poboljšava tok i ishod bolesti.

Ključne reči:

pankreatitis; autoimunske bolesti; dijagnostičke tehnike i procedure; dijagnoza, diferencijalna; lečenje lekovima.

Introduction

Autoimmune pancreatitis (AIP) is a chronic fibro-inflammatory autoimmune disease of the pancreas that still has the cause not known completely¹. The disease was firstly described by Sarles et al.² in 1961 when they noticed the presence

of pancreatitis followed by hypergammaglobulinemia and sclerosis. It is supposed today that its prevalence in patients with chronic pancreatitis is 5.3% in Japan, and 11% in the USA³. Also, 2–3% of pancreatoduodenectomies are performed in patients with AIP due to the wrong diagnosis of pancreatic carcinoma⁴. There are two types of the disease. Type 1 AIP, a prototype

of IgG4-related systemic diseases, is a multiple-organ disease associated with the increase of IgG4 in serum and IgG4 positive plasma cells in pancreatic biopsies (more than 10 cells in the field of view) with obliterative phlebitis and storiform fibrosis. The disease could be related to IgG4 sclerosing cholangitis, sialo- and dacryoadenitis, retroperitoneal fibrosis, tubulointerstitial nephritis, chronic sclerosing aortitis and periaortitis, and Riedel's thyroiditis⁵. There is almost no organ that could not be affected by this disease. Type 2 AIP with granulocytic epithelial lesions (idiopathic duct-centric pancreatitis) has a few or no IgG4 positive plasma cells with the presence of neutrophil infiltration. Type 2 AIP appears more often in Europe and the USA, mainly not associated with affecting the other organs, except for a little bit higher frequency of inflammatory bowel disease (IBD) in these patients. This type of the disease usually does not relapse.

Clinically, AIP could be asymptomatic, but it could be manifested as acute pancreatitis, sometimes followed by the other organs damage⁶⁻¹¹. It is characterized by diffuse or focal enlargement of the pancreas that sometimes is not easy to differ from pancreatic cancer⁷. The international criteria for AIP used today, established back in 2011, significantly help in recognizing and starting adequate treatment of this disease. During the past decades various diagnostic criteria for AIP were suggested on many occasions¹². The International Consensus Diagnostic Criteria (ICDC) for AIP, and its Japanese Amendment developed by the Japanese Pancreas Society (JPS 2011) in 2011 are used today¹³. The major difference between the ICDC and JPS 2011 is in that the Japanese criteria are more focused on type 1 AIP and require the application of endoscopic retrograde pancreatocolangiography (ERCP) when imaging methods for the diagnosis are not defined¹⁴. The diagnosis of type 1 AIP can be definitive and probable, and is made on the basis of radiological and ERCP findings, serology, pathohistological finding of pancreatic biopsy tissue, other organs affected, and positive response to corticosteroid therapy¹⁵. It is also possible to diagnose it in 70% of cases with no invasive method¹⁶. The diagnosis of type 2 AIP no matter it is definite or probable was made on histopathology¹⁷.

The aim of this report was to present two patients with type 1 and type 2 AIP never registered before in our institution.

Case report

Case 1

A 64-year old patient presented to the Clinic for Gastroenterology and Hepatology, Military Medical Academy, Belgrade, Serbia, due to weakness, exhaustion, weight loss of 16 kg, occasional abdominal pain. Otherwise, the patient suffered from insulin-dependent diabetes mellitus. Physical examination revealed a painful sensitivity of epigastrium. The values of laboratory parameters [sedimentation (SE), C-reactive protein (CRP), blood analysis, electrolytes, urea, creatinine, total proteins, albumin, total bilirubin, aspartate aminotransferase (AST), alanine aminotransferase (ALT), gamma-glutamyl transferase (GGT), alkaline phosphatase (ALP), amylase, lipase, protein electrophoresis] were normal except for glycemic values (5.3–10.4 mmol/L). Colonoscopy and esophagogastroduodenoscopy were normal. Abdominal ultrasound discovered a diffusely enlarged hypoechoic pancreas (Figure 1). It was confirmed with endoscopic ultrasonography (EUS) (Figure 2).

The patient was then submitted to multislice computer tomography (MSCT) of the abdomen that showed the enlarged, hypodense pancreas bordered by a thin capsule ("sausage-like pancreas") with the presence of *ductus pancreaticus* penetration through the tissue of the organ (Figure 3).

The increase of IgG was confirmed in serum, while IgG4 subclass analysis suggested the increased value of IgG4 of 9.8 g/L. Ultrasound-guided biopsy of the pancreas was performed (Figure 4). The pathohistological finding indicated severe intracinous fibrosis of focal storiform pattern and multiplied connective fibers next to the periductal lymphoplasmacytic infiltration. The immunohistochemical finding confirmed the presence of more than 10 IgG4 positive plasma cells under high magnification microscope.

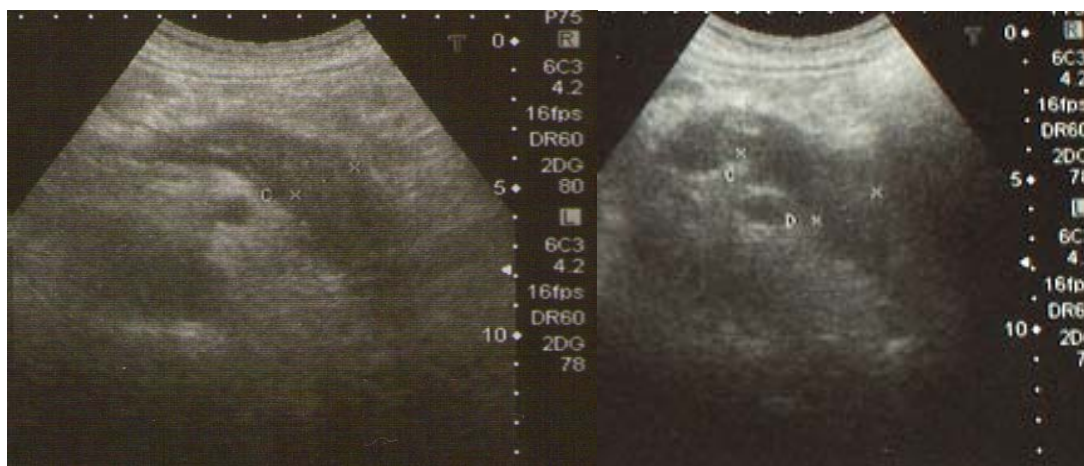


Fig. 1 – Ultrasound of the abdomen showing the voluminous hypoechoic pancreas.

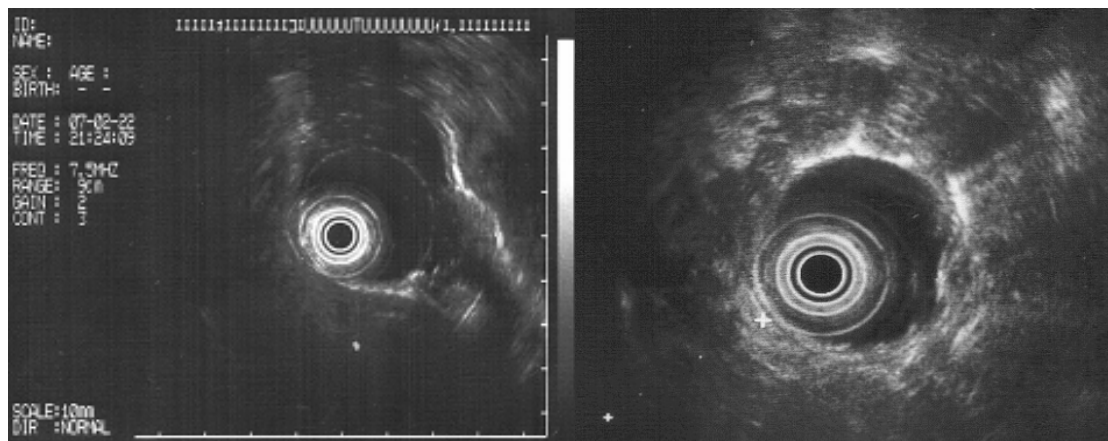


Fig. 2 – Endoscopic ultrasonography shows the enlarged hypoechoic pancreas with no focal changes.

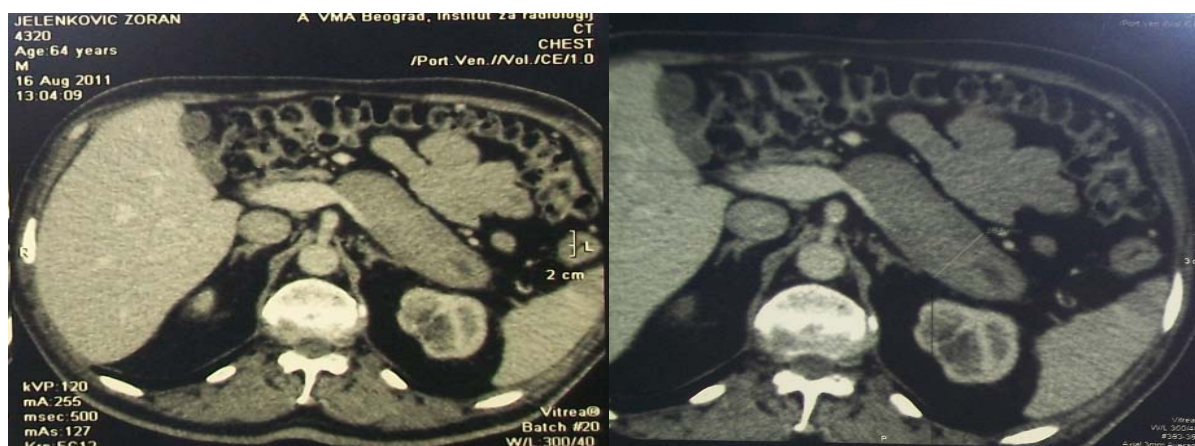


Fig. 3 – Multislice computed tomography of the pancreas with type 1 autoimmune pancreatitis.

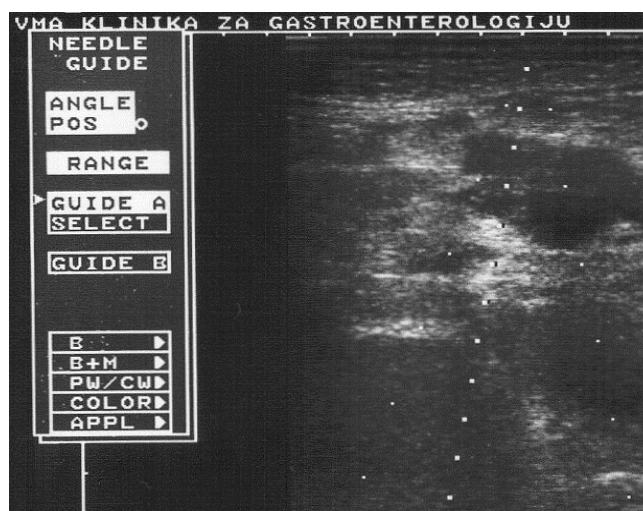


Fig. 4 – Ultrasound image of guided biopsy of the pancreas.

Following confirmation of type 1 AIP in the patient, corticosteroid therapy was administered. The patient was given prednisone 40 mg/daily within the first month. On the day 3, abdominal pain vanished, so the dose was reducing *per* 5 mg to 2 weeks upto the dose of 10 mg/daily to maintain. The control values of IgG4 were within the referent ranges (0.801 g/L). Ultrasound examination of the abdomen was normal. Two months following the beginning of the

therapy, control MSCT of the abdomen was made showing the normal size of the pancreas. However, in spite of the therapy correction with insulin (the patient had type 1 diabetes mellitus) within a year there was no acceptable regulation of glycemia, thus prednisone was replaced with azathioprine 100 mg/day (recommended 1–2 mg/kg/day). The therapy caused no recurrence, so it was stopped after two years. Three years later there was no recurrence of the disease.

Case 2

A 37-year-old patient presented to the Clinic for Infectious and Tropical Diseases, Military Medical Academy, Belgrade, Serbia due to weakness, diarrhea, abdominal pain, and fever up to 38.5°C. Laboratory findings showed increased factors of inflammation [SE 138, CRP 212.33 mg/L, leucocytes (Le) 11.47×10^9], hyposideremic anemia (iron 3.6 $\mu\text{mol/L}$; normal range 8.9–26.8 $\mu\text{mol/L}$), normal values of biochemical parameters and serum enzymes (urea, creatinine, protein, albumin, total bilirubin, electrolytes, cholesterol, triglycerides, transaminases, GGT, ALP, amylase and lipase), immunoglobulin, chromogranin A and thyroid hormones. There was a rise in serum glucose (glucose 9.9 mg/dL) and amylase in urine (2,195 IU/h). Esophagogastroduodenoscopy was normal. Colonoscopy showed easily narrowed Bouchins valves with patchy mucosal petechiae of the right colon, but pathohistological findings confirmed no presence of inflammatory bowel disease (Figure 5). Abdominal ultrasound revealed a diffusely enlarged hypoechoogenic pancreas of lobular structure, with a smaller amount of ascites (Figure 6). That was confirmed by endoscopic ultrasound and MSCT examination of the abdomen. Biopsy was also per-

formed. Hystopathological findings confirmed the presence of advanced autoimmune pancreatitis type 2 – sclerosing lymphoplasmacytic infiltration as a sign of chronicity and characteristic ductocentric inflammation with focal granulocyte epithelial lesions (GEL).

The patient was initially treated with antibiotics (ciprofloxacin, metronidazole), proton pump inhibitor (pantoprazole 40 mg) and *per os* pancreatic enzymes (Kreon). Subjectively, the patient felt better, and laboratory tests showed a decrease in parameters of inflammation. After receiving pathohistological findings, the patient was submitted to the treatment with prednisone 40 mg/day within the first 14 days, while gradually reducing the dose of 5 mg for 7 days up to a maintenance dose of 10 mg/day. Laboratory control of inflammation factors, blood count and biochemistry of the enzymes revealed normal values. Two months following the start of the therapy, the patient underwent abdominal ultrasound – the pancreas was of normal size, lobular, with more hyperechogenic material, and the results regarding other parenchymatous organs were normal (Figure 7). The patient had no new attack of the disease the previous year.

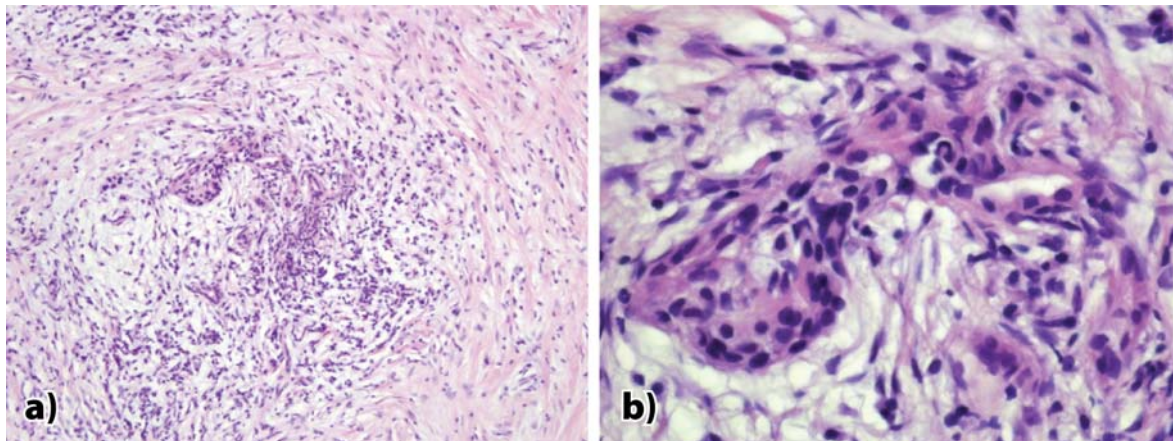


Fig. 5 – Histopathological finding of biopsy done on the pancreatic tissue. (Immunohistochemistry IgG4: a) $\times 100$; b) $\times 200$).

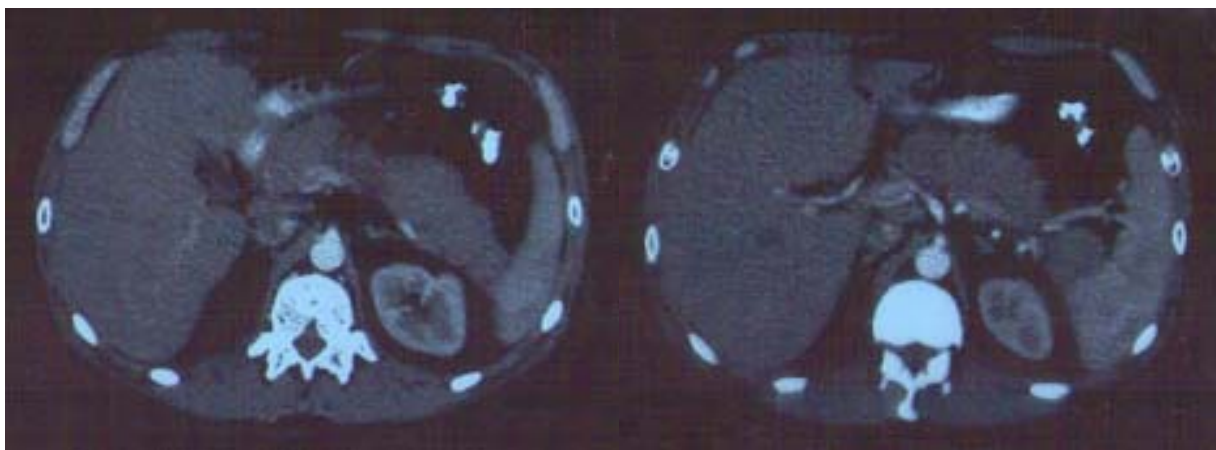


Fig. 6 – Type 2 autoimmune pancreas: multislice computed tomography (enlarged, hypodense pancreas bordered by a thin capsule, "sausage-like pancreas" and a smaller amount of ascites).

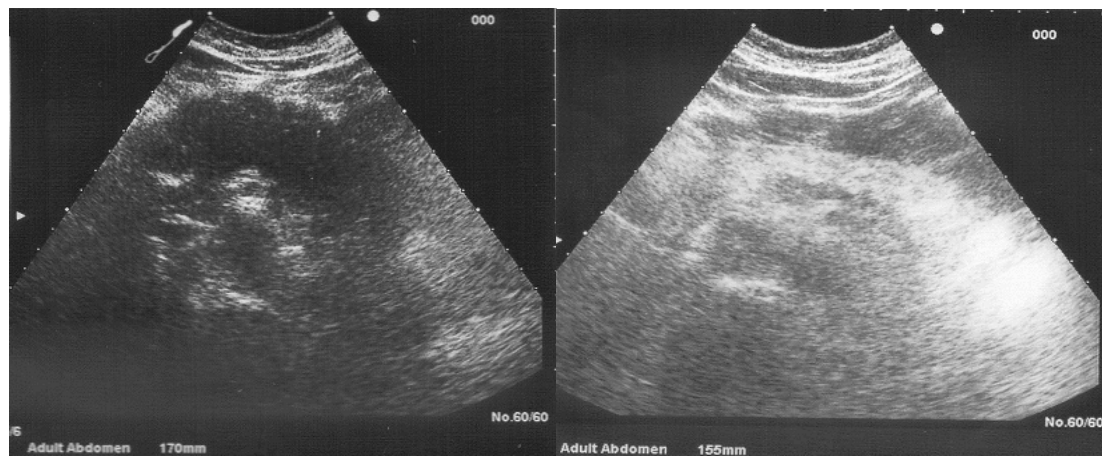


Fig. 7 – Ultrasound of the pancreas before (left) and after the therapy with corticosteroids (right).

Discussion

Autoimmune pancreatitis is a relatively new entity, the name of which was published for the first time in 1995 by the Joshida et al.⁸. Type 1 AIP (IgG4 AIP) is the best example for IgG4-associated diseases. It is featured by lymphoplasmacytic infiltration with IgG4 positive plasma cells, increase of IgG4 in serum, and good therapy response to the applied corticosteroids. Type 2 AIP is not a systemic disease, and usually occurs in younger patients. The most common radiographic presentation includes a focal change in the pancreas. Histopathologically, granulocyte-epithelial lesions were observed in intraluminal and intraepithelial neutrophil infiltration. IgG4 positive plasma cells were either not present, or present in a very small numbers⁹. AIP clinical picture includes obstructive icterus (35–75%), abdominal and back pain (32–70%), weight loss (15%), weakness, exhaustion (9%), diabetes mellitus (43–83%), other disorders (dry mouth, etc), while 15% of patients remain with no complaint¹⁰. It usually occurs in 70s, presented with focal (60%), and diffuse (40%) pancreatic enlargement. The image of acute pancreatitis appears in 15% of patients only¹¹.

The therapy for AIP includes corticosteroids (prednisone 30–40 mg/day) gradually reduced up to a maintenance dose of the drug¹⁷. Therapy stoppage is applied depending on the disease activity within 3 years of its beginning. Complete remission implies symptoms disappearance, as well as the loss of radiological and serological characteristics of the disease¹⁸. Spontaneous remission with no use of corticosteroids has also been reported in the literature. Indications for corticosteroid therapy include icterus appearance, pain or extrapancreatic AIP manifestation. Relapse commonly appears within the first 3 years of the disease (relapse within the maintenance therapy appears in 26% of cases, with no therapy in 54% of cases)¹⁹. Re-acutezation of the disease is more often occurred if initial enlargement is more than 1/3 of the

pancreas and in the presence of icterus, in comorbidity with extrapancreatic lesions (IgG4 sclerosing pancreatitis associated with AIP, proximal extra- and intrahepatic structures), incomplete remissions, as well as in the presence of genetic factors (haplotype HLA DQb1 57)²⁰. Disease relapse requires application of corticosteroids, azathioprine, mycophenolate mofetil, methotrexate or 6-mercaptopurine, and currently anti-CD20 antibodies (rituximab). Immunoregulatory therapy is used in frequent relapses, in cases of resistance or pronounced adverse effects of corticosteroids²¹.

Our patients were treated according to the protocol for the treatment of autoimmune pancreatitis. They did not have a relapse of the underlying disease, even after discontinuation of the therapy

It is sometimes hard to distinguish the focal form of AIP from pancreatic cancer in spite of clear criteria, since inflammatory cells could be found around cancer tissue in biopsy material, as well as IgG4 positive plasma cells, and, as we know, corticosteroids could be applied only when malignancy is excluded²². It is known, also, that chronic pancreatitis and older age are risk factors for pancreatic cancer development. Prolonged use of corticosteroids leads to immunosuppression and could contribute to tumor appearance. So, it is necessary to control patients with AIP at regular intervals as well as to determine their tumor marker Ca 19.9. There are articles showing frequent appearance of pancreatic cancer many years after disease beginning, sometimes even at the same time with AIP^{23,24}.

Conclusion

Autoimmune pancreatitis is a relatively new disease that is recognized more and more frequently today. The long-term prognosis is uncertain. The course of the disease could be affected by frequent relapses, exocrine and endocrine dysfunction of the pancreas, condition of the other affected organs, and comorbidity with the malignancy.

R E F E R E N C E S

1. Divatia M, Kim SA, Ro JY. IgG4-related sclerosing disease, an emerging entity: A review of a multi-system disease. *Yonsei Med J* 2012; 53(1): 15–34.
2. Sarles H, Sarles J, Muratore R, Guen C. Chronic inflammatory sclerosis of the pancreas—An autonomous pancreatic disease. *Am J Dig Dis* 1961; 6(7): 688–98.
3. Chari ST, Smyrk TC, Levy MJ, Topazian MD, Takahashi N, Zhang L, et al. Diagnosis of autoimmune pancreatitis: The Mayo Clinic experience. *Clin Gastroenterol Hepatol* 2006; 4(8): 1010–6; quiz 934.
4. Kamisawa T. Diagnostic criteria for autoimmune pancreatitis. *J Clin Gastroenterol* 2008; 42(4): 404–7.
5. Chari ST, Kloppel G, Zhang L, Notohara K, Lerch M, Shimosegawa T. Histopathologic and clinical subtypes of autoimmune pancreatitis. *Pancreas* 2010; 39(5): 549–54.
6. Cheuk W, Chan JK. IgG4-related sclerosing disease: A critical appraisal of an evolving clinicopathologic entity. *Adv Anat Pathol* 2010; 17(5): 303–32.
7. Hayashi M, Arisaka Y, Takeshita A, Tominaga Y, Ki T, Masuda D, et al. Differential diagnosis of pancreatobiliary carcinoma from autoimmune pancreatitis-related diseases: A report of three cases. *J Gastrointest Cancer* 2011; 42(4): 241–51.
8. Yoshida K, Toki F, Takeuchi T, Watanabe S, Shiratori K, Hayashi N. Chronic pancreatitis caused by an autoimmune abnormality. Proposal of the concept of autoimmune pancreatitis. *Dig Dis Sci* 1995; 40(7): 1561–8.
9. Zen Y, Bogdanos DP, Kawa S. Type 1 autoimmune pancreatitis. *Orphanet J Rare Dis* 2011; 6: 82.
10. Hirano K, Isogawa A, Tada M, Isayama H, Takahara N, Miyabayashi K, et al. Long-term prognosis of autoimmune pancreatitis in terms of glucose tolerance. *Pancreas* 2012; 41(5): 691–5.
11. Okazaki K, Kawa S, Kamisawa T, Ito T, Inui K, Irie H, et al. Amendment of the Japanese consensus guidelines for management of autoimmune pancreatitis 2013. I. Concept and diagnosis of autoimmune pancreatitis. *J Gastroenterol* 2014; 49(4): 567–88.
12. Fantini L, Zanini N, Fisaletti M, Calculli L, Casadei R, Campana D, et al. Autoimmune pancreatitis: The classification puzzle. *Adv Med Sci* 2007; 52: 71–5.
13. Kawa S, Okazaki K, Kamisawa T, Shimosegawa T, Tanaka M. Japanese consensus guidelines for management of autoimmune pancreatitis: II. Extrapancreatic lesions, differential diagnosis. *J Gastroenterol* 2010; 45(4): 355–69.
14. Maruyama M, Watanabe T, Kanai K, Oguchi T, Muraki T, Hamano H, et al. International consensus diagnostic criteria for autoimmune pancreatitis and its Japanese amendment have improved diagnostic ability over existing criteria. *Gastroenterol Res Pract* 2013; 2013: 456965.
15. Shimosegawa T, Chari ST, Frulloni L, Kamisawa T, Kawa S, Mino-Kenduson M, et al. International consensus diagnostic criteria for autoimmune pancreatitis. *Pancreas* 2011; 40(3): 352–8.
16. Sab RP, Chari ST. Autoimmune pancreatitis: An update on classification, diagnosis, natural history and management. *Curr Gastroenterol Rep* 2012; 14(2): 95–105.
17. Pappa K, Angst E, Seidel S, Flury-Frei R, Hetzer FH. The diagnostic challenges of autoimmune pancreatitis. *Case Rep Gastroenterol* 2015; 9(1): 56–61.
18. Pezzilli R, Imbrogno A, Fabbri D. Autoimmune pancreatitis management: Reflections on the past decade and the decade to come. *Expert Rev Clin Immunol* 2012; 8(2): 115–7.
19. Kim HM, Chung MJ, Chung JB. Remission and relapse of autoimmune pancreatitis: Focusing on corticosteroid treatment. *Pancreas* 2010; 39(5): 555–60.
20. Kamisawa T, Okazaki K, Shigeyuki K, Shimosegawa T, Tanaka M. Japanese consensus guidelines for management of autoimmune pancreatitis: III. Treatment and prognosis of AIP. *J Gastroenterol* 2010; 45(5): 471–7.
21. Kubota K, Watanabe S, Uchiyama T, Kato S, Sekino Y, Suzuki K, et al. Factors predictive of relapse and spontaneous remission of autoimmune pancreatitis patients treated/not treated with corticosteroids. *J Gastroenterol* 2011; 46(6): 834–42.
22. Kalaitzakis E, Webster GJ. Review article: autoimmune pancreatitis: Management of an emerging disease. *Aliment Pharmacol Ther* 2011; 33(3): 291–303.
23. Takuma K, Kamisawa T, Gopalakrishna R, Hara S, Tabata T, Inaba Y, et al. Strategy to differentiate autoimmune pancreatitis from pancreas cancer. *World J Gastroenterol* 2012; 18(10): 1015–20.
24. Kim JH, Kim MH, Byun JH, Lee SS, Lee SJ, Park SH, et al. Diagnostic Strategy for Differentiating Autoimmune Pancreatitis From Pancreatic Cancer: Is an Endoscopic Retrograde Pancreatography Essential. *Pancreas* 2012; 41(4): 639–47.

Received on October 07, 2015.

Accepted on November 09, 2015.

Online First September, 2016