



Biometric features of the eyes of preterm born babies

Biometrijske karakteristike očiju prevremeno rođenih beba

Zorka Grgić*, Ana Oros*, Jelena Karadžić †, Vladimir Čanadanović*,
Sandra Jovanović*, Sofija Bolinovska*

Clinical Center of Vojvodina, *Clinic for Eye Diseases, Novi Sad, Serbia; Clinical
Center of Serbia, †Clinic for Eye Diseases, Belgrade, Serbia

Abstract

Background/Aim. Preterm birth and retinopathy of prematurity (ROP) could affect optical and biometric features of eyes and cause refractive errors. The aim of this study was to compare the ocular axial length, anterior chamber depth and lens thickness changes during the first year in preterm born babies with and without ROP. **Methods.** This prospective longitudinal study included 87 preterm born babies. The examinations were performed at 3 and 12 months after birth and included fundus examination and measurements of the ocular axial length, anterior chamber depth and lens thickness. Based on the results of fundus examination at 3 months, the subjects were divided into two groups and the measurements of those with and without ROP were compared. **Results.** At 3 months 60.92% of infants had ROP. The mean values in the ROP group were: axial length 16.56 mm and 16.53 mm, chamber depth 2.34 mm and 2.38 mm and lens thickness 4.04 mm and 3.96 mm, in the right and the left eye, respectively. In the no ROP group these values were: axial length 17.06 mm and 17.08 mm, chamber depth 2.31 mm and 2.39 mm and lens thickness 4.16 mm and 4.14 mm in the right and the left eye, respectively. At 12 months 28.74% of the children had a change in the ocular fundus as a result of the ROP therapy. In the ROP group the axial length was 19.94 mm in both eyes, chamber depth 3.01 mm and 2.99 mm and lens thickness 4.28 mm and 4.29 mm, in the right and the left eye, respectively. In the no ROP group the axial length was 20.64 mm and 20.29 mm, lens thickness 4.37 mm and 4.36 mm, in the right and the left eye, respectively and chamber depth 3.10 mm in both eyes. **Conclusion.** In the group of children with ROP axial length of the eye at 3 and 12 months was statistically significantly smaller in comparison to the group without ROP. Statistically significant difference was not found between these groups in the anterior chamber depth and lens thickness.

Key words:

infant, premature; retinopathy of prematurity; biometry; refraction, ocular; eye.

Apstrakt

Uvod/Cilj. Prevremeno rođenje i prematurna retinopatija (ROP) mogu dovesti do nastanka refraktivnih mana, uticajem na optičke i biometrijske karakteristike oka. Cilj ovog rada bio je da se uporede promene u aksijalnoj dužini oka, dubini prednje očne komore i debljini sočiva prematurusa sa i bez ROP tokom prve godine života. **Metode.** Ispitivanje je sprovedeno kao prospektivna longitudinalna studija, koja je obuhvatila 87 prevremeno rođenih beba. U uzrastu od 3 i 12 meseci urađen je pregled očnog dna i merenje aksijalne dužine oka, dubine prednje očne komore i debljine očnog sočiva. Prema nalazu na očnom dnu 3 meseca posle rođenja bebe su podeljene u dve grupe, sa i bez ROP i izmerene vrednosti praćenih parametara su upoređene. **Rezultati.** Prilikom pregleda beba sa 3 meseca kod 60,92% njih je ustanovljen ROP. Prosečne vrednosti merenih parametara na desnom i levom oku u grupi sa ROP bile su: aksijalna dužina 16,56 mm i 16,53 mm, dubina prednje očne komore 2,34 mm i 2,38 mm i debljina sočiva 4,04 mm i 3,96 mm na desnom, odnosno levom oku. U grupi bez ROP ove vrednosti na desnom i levom oku bile su: aksijalna dužina 17,06 mm i 17,08 mm, dubina prednje komore 2,31 mm i 2,39 mm i debljina sočiva 4,16 mm i 4,14 mm. Sa 12 meseci 28,74% dece je imalo promene na retini kao posledice tretmana ROP. U grupi sa ROP pri prvom pregledu, aksijalne dužine bile su 19,94 mm na oba oka, dubine prednje komore 3,01 mm i 2,99 mm, a debljine sočiva 4,28 mm i 4,29 mm na desnom, odnosno levom oku. U grupi bez ROP aksijalne dužine desnog, odnosno levog oka bile su 20,64 mm i 20,29 mm, dubine komore 3,10 mm na oba oka, a debljine sočiva 4,37 mm i 4,36 mm, desno i levo. **Zaključak.** U grupi dece sa ROP aksijalna dužina oka sa 3 i 12 meseci bila je statistički značajno manja u odnosu na grupu bez promena na retini. Statistički značajna razlika nije nađena između grupe sa i bez ROP poređenjem parametara očne komore i sočiva.

Ključne reči:

nedonošče; retinopatija kod prematurusa; biometrija; oko, refrakcija; oko.

Introduction

The number of infants born prematurely (that is before 37 weeks of gestation), which survive the neonatal and perinatal period is currently increasing. The focus of medical care is therefore shifted to long-term functional results of all organ systems¹. Vision is a complex and highly functional set of processes at the levels of the retina and nervous system². The impressions that an infant receives through the sense of sight are highly important for its normal psychological and cognitive development³. Potential consequences of premature delivery for visual, motor and cognitive functions are numerous³. There are many causes for visual impairment, but they mainly occur as a consequence of the immaturity of the central nervous system and not of localized damage to the eye or cerebral cortex¹. Retinopathy of prematurity (ROP) is a vasoproliferative disorder of the retina in prematurely born infants⁴, which is the most common cause of preventable blindness in children. Preterm birth is also characterized by a higher incidence of strabismus, refractive disorders, nystagmus, glaucoma, optic nerve hypoplasia, eye movement disorders and reading disorders¹.

ROP develops in two distinct phases^{2,5,6} and according to the International Classification, the severity of the disease is described in five stages, the localization of the process with three zones and the circumferential extent of the disease is based on the clock hours (from 1 to 12), where the extent of five hours is regarded as the critical value⁷. Generally, stage 1 is defined by the presence of the so-called demarcation line, stage 2 by the presence of the so-called ridge, stage 3 by extraretinal fibrovascular proliferation. Stages 4 and 5 are severe conditions, the former of which is characterized by sub-total retinal detachment and the latter by total retinal detachment⁷. The zones are defined according to the posterior position of the process, so that the severity of the disease decreases from zone I to zone III^{5,7}.

Screening of prematurely born infants is performed in order to identify cases with a high risk of permanent visual loss due to ROP, which in turn could be decreased by adequate and timely intervention^{8,9}. The criteria for screening infants in our country, following the recommendation of the American Academy of Pediatrics, are the birth weight 2,000 grams or less and gestational age 36 weeks or less, with the postnatal application of oxygen. The presence of additional risk factors during the development of the child points to the need of screening regardless of the criteria mentioned^{5,7}. The first examination should be performed 4 to 6 weeks after birth^{5,8} or between gestational weeks 31 and 33^{8,10}. After that, the second examination is performed after a week or two, depending on the local findings⁸. The screening takes place until blood vessels reach zone III in infants without ROP in the zones I and II^{8,11,12}, or to the completed vascularization of the ora serrata after intravitreal application of anti-vascular endothelial growth factor or until week 50 postmenstrually for children with prior milder ROP forms or until ROP recedes¹². A repeated ophthalmological examination of prematurely born babies at 12 months is of

crucial importance, regardless of the presence of ROP, in order to identify amblyogenic factors such as strabismus or refractive disorders^{11,13}.

Premature birth, i.e. gestational age, birth weight, retinopathy and the development of refractive disorders are closely related¹⁴. These characteristics indirectly affect refraction, by influencing the optical characteristics of the eye¹⁵. Refractive disorders occur when the ocular axial length does not correspond to the focal plane, created by the cornea, lens and anterior chamber¹⁶. The process of balancing out the strength of the refractive power of the optical system and the ocular axial length is called emmetropization¹⁷ and it generally occurs between month 3 and 12 after birth. This process is different in full-term and preterm infants and the differences are noticeable depending on the presence of the retina disorder¹⁵. The changes in the refractive power of the cornea and lens show a negative correlation with the axial growth of the eye¹⁸. At the age of one, 6.66% of prematurely born children with ROP at the earliest age and 3.75% of those without ROP have a refractive error¹⁹. The main causes of the high incidence of myopia, in general, are the greater axial length^{20,21}, shallower anterior chamber and the greater thickness of the ocular lens²¹. However, prematurity, lower gestational age and birth weight are characterized by a more convex cornea, shallower anterior chamber, thicker lens, but also, a smaller axial length, compared to the values which might be expected from the dioptric value of the eye^{14,19,22,23}. The early effect of growth restriction within retinopathy is later followed by irregularities in the growth of the eye posterior segment²³, so that in preterm infants there is no direct correlation between the ocular axial length and its refractive status. Proportions of the eye are not later fully compensated for by the growth of the eye and visual experience^{14,22}.

In this study is shown how the ocular axial length, anterior chamber depth and lens thickness were changing during the first year of life in preterm born babies with and without ROP.

Methods

The research was conducted as a prospective, longitudinal study at the Clinic for Eye Diseases of the Clinical Center of Vojvodina during the period of 5 years, from 2005 till 2010. The study was approved by the Clinical Centre of Vojvodina Ethics Committee. The parents of the participating babies provided their informed consent, after being provided written and verbal information about the study. The study enrolled 87 preterm infants (174 eyes), divided into the two groups according to the presence of ROP. Two examinations were performed, at 3 and 12 months of age.

The study included preterm born babies whose birth weight was 2000 grams or lower and gestational age 36 weeks or lower, who received oxygen, as well as infants satisfying these criteria, but with other risk factors that might affect the development of the retinal vasculature, such as: diseases of the respiratory tract, brain hemorrhage, sepsis, anaemia, enterocolitis, blood transfusion, non-physiological values of partial pressure of oxygen and carbon dioxide, acidosis, phototherapy and multiple pregnancies. The preterm in-

fants with risks were selected by neonatologists. Infants that developed severe forms of retinopathy (stages IV and V) were excluded from the study, since the biometrical data and the refractive status that would have been acquired in those cases would bear no relevance for this research.

For the collection of necessary data, an original questionnaire was used. The research was conducted according to the preset methodological plan with precisely defined criteria. It included: the scrutiny of medical documentation, i.e. the discharge note from the Institute for Child and Youth Health Care of Vojvodina, biometric measurements, including the measurements of the ocular axial length, anterior chamber depth and lens thickness of both eyes, as well as the bilateral fundus examination in mydriasis and with indentation at the two respective ages. The values were taken for each eye separately in order to record differences in values for each eye, taking into account the higher incidence of anisometropia in preterm population.

Medical records provided the basic personal data, the data on the values of birth weight, gestation age and the presence of risk factors.

Biometric measurements were performed after the application of the local anesthetic Tetracaine hydrochloride® 0.5% eye drops, three times at 5 minutes intervals. The ocular axial length, anterior chamber depth and the thickness of the lens were measured by the ultrasonographic A-method using the Sonomed Inc, USA, A-2500 ultrasound machine, with the transducer frequency of 10 MHz. The values were taken three times for all the parameters and the mean value was calculated. The measurements were expressed in millimeters.

The examination of the ocular fundus was performed through dilated pupils. The maximal mydriasis was provided by the application of Phenylephrine hydrochloride® 2.5% eye drops or Cyclopentolate® 0.5% eye drops, twice at 10-minute intervals one hour before the examination. The examination was performed by indirect binocular ophthalmoscope, Indirekte Ophthalmoskop Omega 180, Heine Optotechnik, Hersching, Germany and a 20 D lens. For a more detailed view of the peripheral segments of the retina scleral indentation was used. Eyelid separation was obtained by using blepharostat. The results were expressed in accordance with the International Classification of Retinopathy of Prematurity.

Statistical analysis of the data was performed using the Statistical Package for Social Sciences software - SPSS 21. The numerical values were expressed as mean values and variability measurements (range, standard deviation) and the attributive features by frequencies and percentages. The comparison of the numerical values between the groups was done using *t*-test and the differences between the frequencies of attributive features by χ^2 test. The correlation between two features was determined by Pearson's correlation coefficient. Statistical significance was set at level $p < 0.05$.

The results are presented as tables and figures.

Results

The research included 87 preterm born babies (174 eyes): 43 (49.43%) boys and 44 (50.57%) girls. The mean

gestational age at birth was 31.45 weeks, ranging from 24 to 36 weeks. Birth weight ranged from 1,190 grams to 3,620 grams, with the mean value 1,643.51 grams.

The results at 3 months

The incidence of ROP at 3 months was present in 60.92% of the infants and was identical in both eyes. In the right eye 41.5% infants with ROP had ROP 1, 9.4% ROP 2, 43.4% ROP 3, 1.9% ROP 4 and 3.8% ROP 5. In the left eye, the occurrence of specific ROP stages was: 41.5% with ROP 1, 9.4% with ROP 2, 45.3% with ROP 3, ROP 4 was found in none of the infants and ROP 5 was found in 3.8% babies (Table 1).

Table 1

The incidence of specific retinopathy of prematurity (ROP) stages in eyes of premature born infant at the age of 3 months

ROP stages	Right eye, n (%)	Left eye, n (%)
1	22 (41,5)	22 (41.5)
2	5 (9,4)	5 (9.4)
3	23 (43,4)	24 (45.3)
4	1 (1,9)	
5	2 (3,8)	2 (3.8)
Total	53 (100)	53 (100)
Mean	2,17	
Median	2,00	
Mode	3	

The mean values of the axial length in patients with ROP were 16.56 mm (15.02 to 17.78 mm; standard deviation (SD) = 0.72 mm) in the right and 16.53 mm (15.10 to 17.78 mm; (SD) = 0.68 mm) in the left eye. Axial length values in the group of infants without ROP were 17.06 mm (15.97 to 18.27 mm; (SD) = 0.55 mm) in the right and 17.08 mm (15.66 mm to 18.27 mm; (SD) = 0.54) in the left eye. The standard deviation was higher in the group of patients with ROP in both eyes, which points to the higher heterogeneity of this group. The results of the differences in the axial values between the two groups were statistically highly significant both in the right ($t = 3,451, p = 0,001$) and in the left eye ($t = 3,996, p = 0,000$) (Figure 1).

The analysis of the values of the anterior chamber depth of the right ($t = 0,420, p = 0,676$) and the left eye ($t = 0,149, p = 0,882$) revealed no statistical difference between the groups with and without ROP, while the values of standard deviation, similarly to the values of axial length, were higher in the group of infants with ROP. The mean of the anterior chamber depth was 2.31mm (1.92 to 2.90 mm; SD = 0.24 mm) in the right and 2.39 mm (2.11 to 3.36 mm; SD = 0.27 mm) in the left eye in the group without ROP, while in the group with ROP it was 2.34 mm (1.92 to 4.34 mm; SD = 0.38 mm) in the right and 2.38mm (1.85 to 4.27 mm; SD = 0.36 mm) in the left eye (Figure 2).

The mean values of the lens thickness in infants without ROP were 4.16 mm (3.40 to 4.90 mm; SD = 0.30 mm) and 4.14 mm (2.75 to 4.79 mm; SD = 0.37 mm) and in babies with ROP they were 4.04 mm (2.10 to 4.70 mm; SD = 0.49 mm) and 3.96 mm (2.26 to 4.75 mm; SD = 0.47 mm) in the right and the left eye respectively. The differences obtained

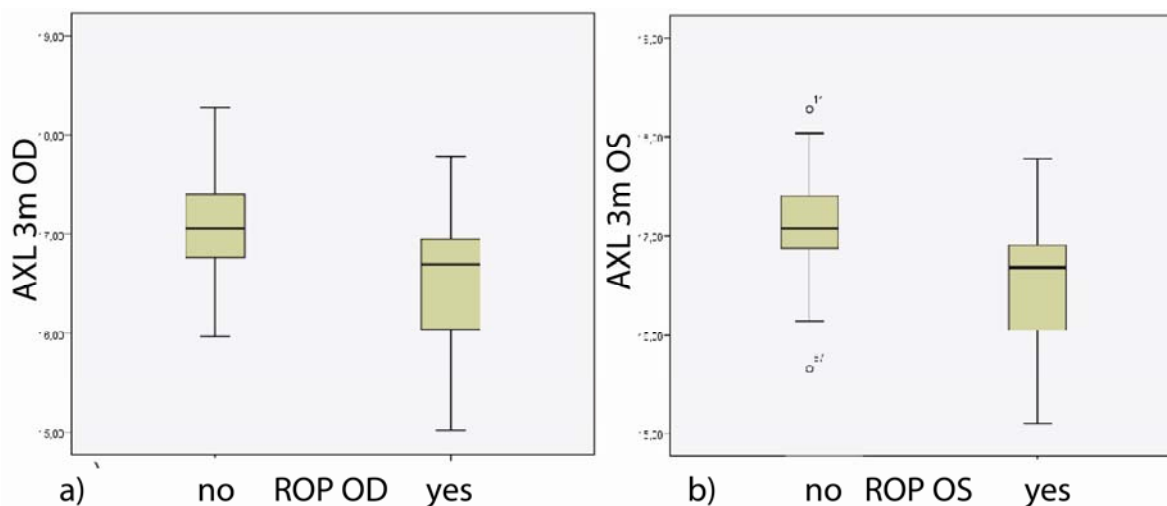


Fig. 1 – Axial length of eyes in premature born infants with and without retinopathy of prematurity (ROP) at the age of 3 months: a) right eye; b) left eye.

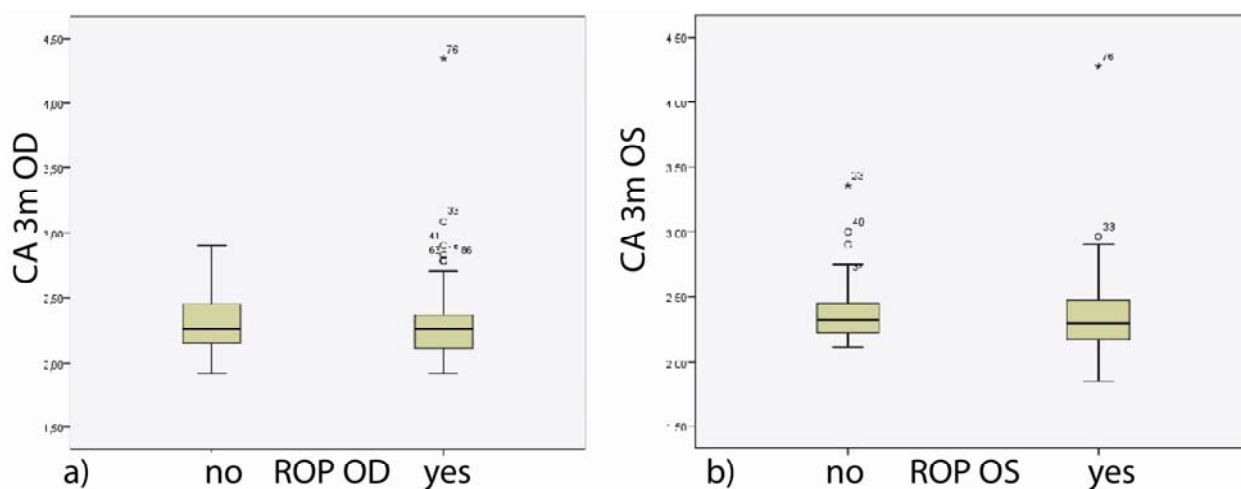


Fig. 2 – Anterior chamber depth of eyes at the age of 3 months in premature born infants with and without retinopathy of prematurity (ROP) at the age of 3 months: a) right eye; b) left eye.

were not statistically significant in either the right ($t = 1.360$, $p = 0.177$) or the left eye ($t = 1.852$, $p = 0.067$) and the values of higher standard deviation point to the greater heterogeneity of the group with ROP (Figure 3).

The results at 12 months

At 12 months of age 62 (71.26%) babies had a normally developed blood network of the retina. The remaining 25 (28.74%) had a change in the ocular fundus as a result of cryopexy or retinal laser therapy due to ROP. The results were almost identical in both eyes. The axial length of the right ($t = 2.329$, $p = 0.022$) and the left eye ($t = 2.087$, $p = 0.040$) in the no ROP group was statistically significantly greater than in the group with ROP. The values of standard deviation of this parameter in both eyes were approximately the same in the group with ROP, while the standard deviation in the right eye in the other group was significantly higher, since the values of one child deviated considerably from the others, whose results were homogeneous. In the group

without ROP the mean value of the axial length of the right eye was 20.64 mm (19.0 to 30.4 mm; SD = 1.89 mm) and of the left one 20.29 mm (19.0 to 22.0 mm; SD = 0.65 mm). In the group with ROP, these values of the right eye ranged from 17.4 to 22.1 mm (SD = 0.87 mm) and of the left eye from 16.7 to 21.8 mm (SD = 0.84 mm). The mean value of both eyes was 19.94 mm (Figure 4).

The difference in the mean values of the anterior chamber depth was not statistically significant neither in the right ($t = 1.048$, $p = 0.268$), nor in the left eye ($t = 1.408$, $p = 0.163$) in both groups, with or without ROP. In the group without ROP the mean value of both eyes was 3.10 mm (right eye: 2.14 to 3.58 mm; SD = 0.34 mm; left eye: 2.26 to 3.81 mm; SD = 0.37 mm) and in the group with ROP the mean values were 3.01 mm (2.15 to 3.77 mm; SD = 0.41 mm) and 2.99 mm (2.40 to 3.57 mm; SD = 0.34 mm) in the right and left eye, respectively. The differences in standard deviations were not statistically significant which pointed to close homogeneity of both groups regarding this parameter (Figure 5).

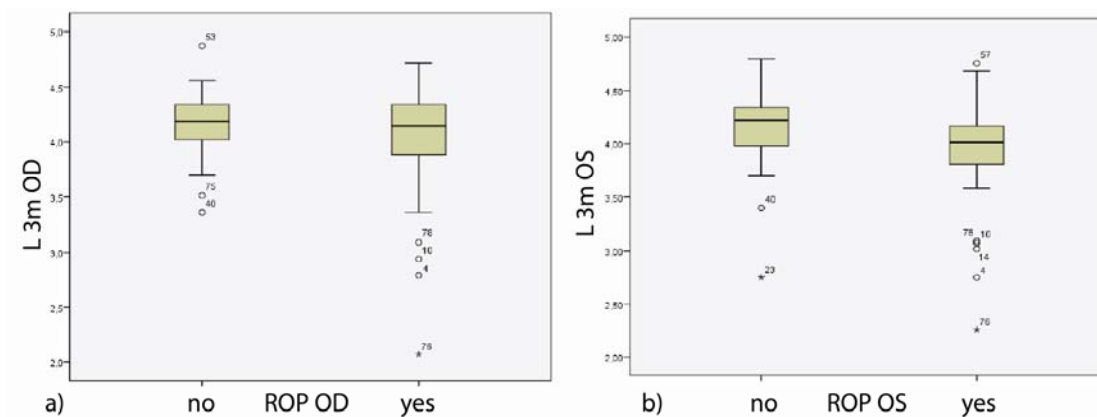


Fig. 3 – Lens thickness of eyes in preterm born infants with and without retinopathy of prematurity (ROP) at the age of 3 months: a) right eye; b) left eye.

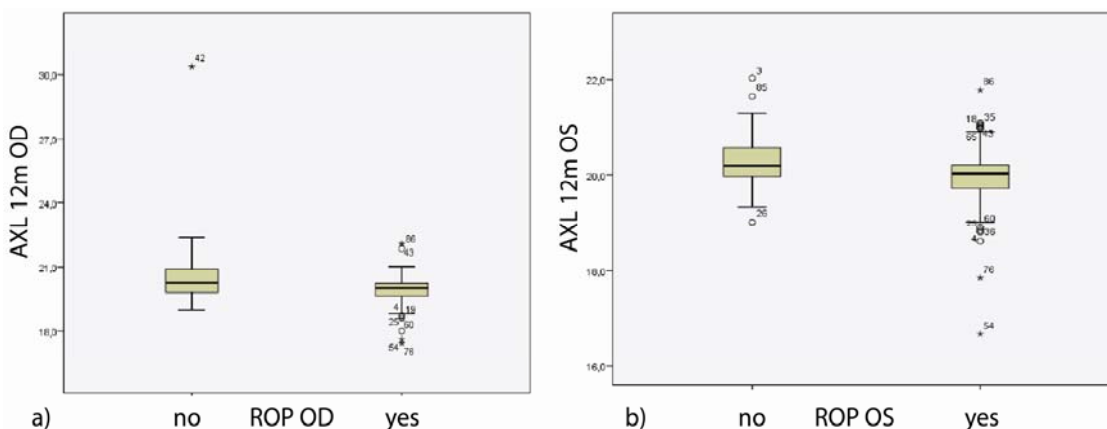


Fig. 4 – Axial length of the eyes in preterm born infants with and without retinopathy of prematurity (ROP) at the age of 12 months: a) right eye; b) left eye.

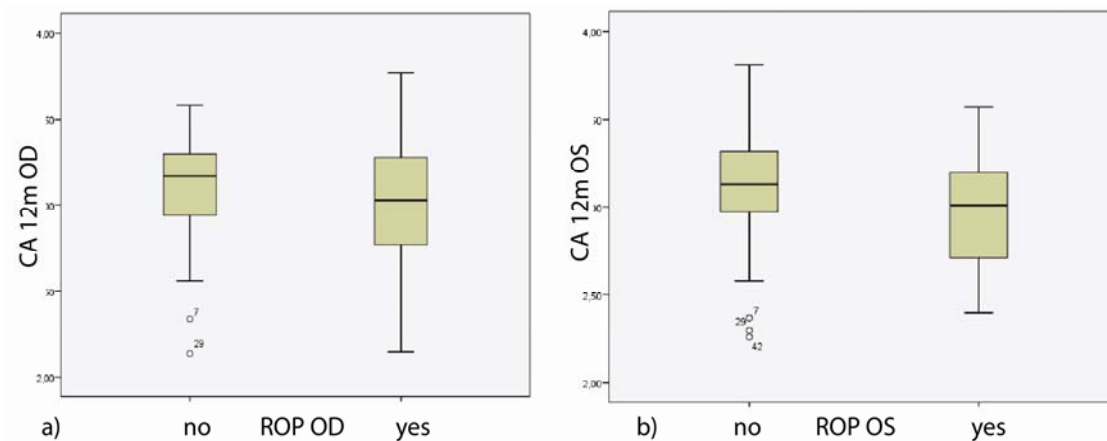


Fig. 5 – Anterior chamber depth of eyes in preterm born infants with and without retinopathy of prematurity (ROP) at the age of 12 months: a) right eye; b) left eye.

No statistical significance was found in the mean values of the lens thickness of both eyes in patients with and without ROP (right: $t = 1.357, p = 0.178$; left: $t = 1.092, p = 0.278$). Standard deviations of the values obtained in the two groups point to their relative homogeneity, although the ROP group was even somewhat more homogeneous. In the group without ROP the values were 4.37 mm (3.77 to 4.92 mm; SD = 0.30 mm) in the right and 4.36 mm (3.02 to 4.90 mm; SD = 0.36 mm) in the left eye, whereas in the group with ROP

they were 4.28 mm (3.69 to 5.13 mm; SD = 0.28 mm) in the right and 4.29 mm (3.81 to 4.96 mm; SD = 0.26 mm) in the left eye (Figure 6).

Discussion

The objective of this study was to examine the effect of retinopathy of prematurity on the growth and development of the eye.

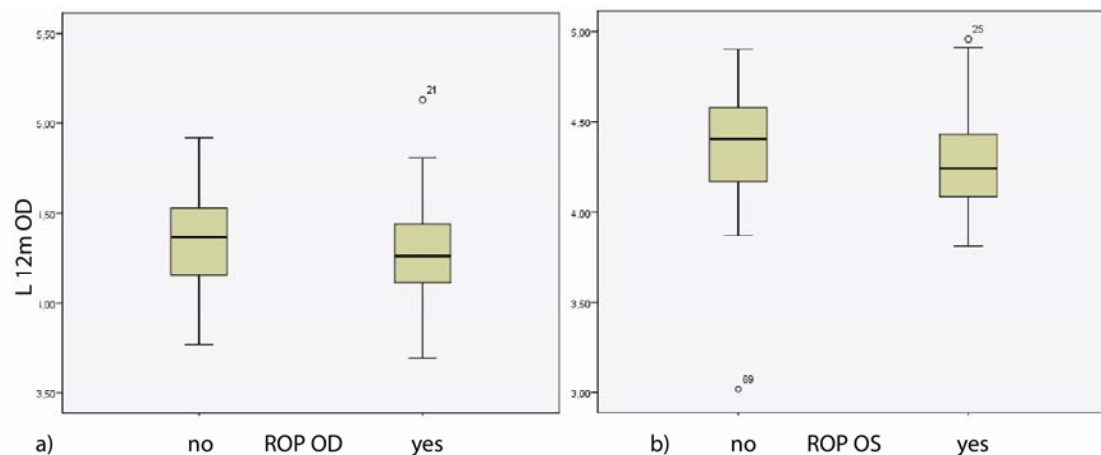


Fig. 6 – Lens thickness of the eyes in preterm born infants with and without retinopathy of prematurity (ROP) at the age of 12 months: a) right eye; b) left eye.

The study enrolled a similar number of boys and girls and therefore, the difference between the genders in the groups was of no statistical significance. The findings reported in the literature regarding the influence of gender on the biometric characteristics of the eye have been inconsistent thus far. Siegwart and Norton¹⁶ claim that gender does affect the development of the eye. According to O'Brien and Clark²⁴, and Laws et al.²⁵ the mean axial length of the eye and the rate of its growth are greater in male infants notwithstanding the correction of the birth weight, gestational age and head dimensions. On the other hand, Mutti et al.¹⁸ reported that gender is not a factor affecting the development and change in refraction and eye growth. Similar results were obtained by Chen et al.²², who also consider the characteristics of the anterior segment of the eye in preterm infants to be independent of the gender.

Gestational age and birth weight are highly important parameters of the development and progression of ROP^{23, 26}. Various screening criteria are found in the literature, but they are primarily related to these two characteristics. The differences between the criteria are also conditioned by the differences in the economic prosperity and investments into medical care, including neonatal, one as well as differences in the incidence of more severe forms of ROP^{4, 8, 9, 11, 27–29}. The mean gestational age of our subjects was 31.45 weeks, while the mean birth weight was 1,643.51 grams.

The overall incidence of ROP in this sample was 60.92%, which is higher than the data reported in the literature. The incidence of ROP among preterm infants reported in the studies by Chen et al.²² was 44%. The need for more frequent and long-term follow-up examinations due to the disorders of the retina may explain the obtained differences in incidence. Namely, the infants with normal findings in the first or second examination were not taken to the follow-up examination at 1 year of age, so they were not included in this study. The greatest majority of infants had ROP 1 (41.5% in both the right and the left eye) and ROP 3 (43.4% in the right and 45.3% in the left eye), while the incidence of ROP 2 was lower than ten percent in both eyes (9.4%). ROP 4 was only found in the right eye, in 1.9% cases and the incidence of ROP 5 was the

same in both eyes (3.8%). Chen et al.²² also report the incidence of specific stages of ROP in preterm infants, ROP 1 and 3 being of the highest incidence, then ROP 2 and the lowest incidence is found with ROP 4 and 5.

The mean axial length of the right and the left eye in infants without retinopathy (17.06 mm and 17.08 mm) was statistically significantly higher in comparison to these values in infants with retinopathy (16.56 mm and 16.53 mm). The values of the axial length of the eye in preterm children at birth³⁰, as well as at 3 months, are lower compared to full-term babies and this difference is particularly marked in the presence of ROP²³. Fledelius and Fledelius³⁰ report about the values of this parameter in full-term infants at birth and preterm newborns at the full-term gestational age, pointing that they are similar in the two groups. They also state that visual and biometric parameters in preterm infants with milder forms of ROP and spontaneous regression are similar to those of preterm infants without ROP³⁰. Full-term newborns have the mean axial length ranging from 16.6 mm to 17.6 mm, while the mean value in the preterm infants at 40 gestational weeks ranges from 16.6 mm to 17.16 mm³⁰. According to the data reported by Pennie et al.³¹, at 3 months of age, the axial length in full-term infants is 17.99±0.67 mm, whereas Mutti et al.¹⁸ report the mean value of 19.03±0.58 mm. Cook et al.²³ report the data on the values of the eye axial length of preterm infants at 3 months, giving a comparison to the findings of the fundus. Thus at 3 months infants without ROP have the approximate mean axial diameter of 18.6 mm and with ROP 18.5 mm. After this period the axial length of the eye increases, so that in full-term children at 9 months it is approximately 20.23±0.64 mm¹⁸ but at 12 months approximately 19.71±0.87 mm³¹. However, very few studies report on the axial length values of prematurely born children at 1 year of age. Our study found a statistically significant difference in axial length values of both eyes in the groups of infants with and without ROP, such that in the case of normal development of retinal blood vessels the axial length of the eye was greater compared to the group of infants who had ROP at 3 months of age. In addition to this, the group without ROP was significantly more homogeneo-

us. The mean value of the axial length of the right eye in the group of infants with ROP at 12 months was 19.94 mm and without ROP it was 20.64 mm. The corresponding values of the left eye for the two respective groups were 19.94 mm and 20.29 mm.

Since at both ages investigated the axial length in both eyes was statistically significantly smaller in infants with ROP, but also in preterm infants compared to full-term infants, it can be concluded that prematurity, as well as retina disorders related to premature birth, both affect the growth of the eye in total from birth to one year of age. Future research and analyses of older children are also necessary in order to determine the alteration of these values at later ages.

In our population studied, there was no statistically significant difference at 3 months of age between the anterior chamber depth in infants with and without ROP in the right (2.34 mm vs. 2.31 mm) or left eye (2.38 mm vs. 2.39 mm). However, the standard deviation of this parameter points to differences in the homogeneity between the two groups, which disappear at a later age. The depth of the anterior chamber in full-term children is approximately 2.38 mm to 2.90 mm, while in preterm infants at the time of full-term gestation this value ranges from approximately 2.25 mm to 2.44 mm, as reported by Fledelius and Fledelius³⁰. The depth of the anterior chamber in full-term infants at 3 months is 2.76±0.27 mm¹⁸. Other authors also report lower values (2.24±0.31D) (31). As reported in the studies by Anna Cook et al.²³ at 3 months of age the depth of the anterior chamber in preterm infants is smaller than in full-term infants, especially in the case of ROP. Its mean value in preterm infants without ROP is 2.8 mm and with ROP 2.7 mm at that age.

The mean value of the depth of the anterior chamber of both eyes was somewhat lower in children with ROP at 12 months but without any statistical significance in comparison to children without ROP. The depth of the anterior chamber was 3.01 mm in the right and 2.99 mm in the left eye in the group with ROP and 3.10 mm in both eyes in the group of children without ROP. The depth of the anterior chamber increases gradually in the first months after birth and its value in full-term children reaches 3.03±0.35 mm at 9 months¹⁸, but at 12 months of age the anterior chamber depth of full-term children is around 2.8±0.26 mm³¹.

The mean lens thickness at the first examination of infants with ROP in our study was 4.04 mm and 3.96 mm and in infants without ROP it was 4.16 mm and 4.14 mm. This difference had no statistical significance and in addition, there was no statistical difference between the values of the right and the left eye. The homogeneity of the two groups studied increased between 3 and 12 months, especially in the group with ROP. The thickness of the lens of full-term infants at birth ranges from 3.40 mm to 3.96 mm, while in preterm infants this value ranges from 3.89 mm to 4.04 mm³⁰. However, in contrast to the axial length and depth of the anterior chamber, the thickness of the lens in full-term children decreases¹⁸. At 3 months of age the reported thickness of the lens in full-term children is 3.92±0.17 mm¹⁸ or 3.65±0.25 mm³¹, at 9 months it is 3.86±0.18 mm (19) and at 12 months approximately 3.65±0.14 mm³¹. As for preterm infants, Cook et al.²³ report that the mean value of lens thickness of premature infants without ROP is 4.0 mm and with ROP 3.96 mm at 3 months, which corresponds to the results of our study.

The mean values of the lens thickness of the right and the left eye in the group of children without ROP at 12 months were 4.37 mm and 4.36 mm and with ROP 4.28 mm and 4.29 mm. The values obtained bear no statistically significant difference between the patients with and without ROP. It is important to notice that, in contrast to full-term children, in preterm infants the thickness of the ocular lens increases during emmetropization, which also corresponds to the data reported in the literature^{15, 22, 30, 32}.

Conclusion

At 3 and 12 months of age, the axial length of both eyes is significantly smaller in preterm infants who develop retinopathy of prematurity at the earliest age, than in those infants who do not. However, the depth of the anterior chamber and the lens thickness of both eyes are not statistically significantly different in the two groups of preterm born infants. We can conclude that during the first year of life retinopathy of prematurity significantly affects the growth of the eye on the whole, but not the growth of the components of its anterior segment compared to the other premature population.

R E F E R E N C E S

1. *Birch EE, O'Connor AR.* Preterm birth and visual development. *Semin Neonatol* 2001; 6(6): 487–97.
2. *Oros A.* Modern approach to the development of the retina in premature infants. In: *Dedović Bjelajac B, Kostić Todorović M, Marković M, Mileusnić Milenović R, Mušić Trninić N, Oros A,* et al, editors. *Clinical seminars.* Belgrade: Institute for neonatology; 2013. p. 119–27. (Serbian)
3. *Madan A, Jan JE, Good WV.* Visual development in preterm infants. *Dev Med Child Neurol* 2005; 47(4): 276–80.
4. *van Sorge AJ, Schalijs-Delfos NE, Kerkehoff FT, van Rijn LJ, van Hillegersberg JL, van Liempt IL,* et al. Reduction in screening for retinopathy of prematurity through risk factor adjusted inclusion criteria. *Br J Ophthalmol* 2013; 97(9): 1143–7.
5. *Oros A.* Detection, treatment and prevention of the development of retinopathy of prematurity [thesis]. Novi Sad: Faculty of Medicine University of Novi Sad; 2002. (Serbian)
6. *Budd SJ, Hartnet ME.* Increased angiogenic factors associated with peripheral avascular retina and intravitreal neovascularization: a model of retinopathy of prematurity. *Arch Ophthalmol* 2010; 128(5): 589–95.
7. *Oros A.* Etiology and pathogenesis of retinopathy of prematurity. In: *Oros A,* editor. *Retinopathy of prematurity.* Belgrade: Zadužbina Andrejević; 2003. p. 22–54. (Serbian)
8. *Fiedler AR, Reynolds JD.* Retinopathy of prematurity: clinical aspects. *Semin Neonatol* 2001; 6(6): 461–75.

9. *Pierce LM, Raab EL, Holzman IR, Ginsburg RN, Brodie SE, Stroustrup A.* Importance of birth weight as a risk factor for severe retinopathy of prematurity when gestational age is 30 or more weeks. *Am J Ophthalmol* 2014; 157(6): 1227–30.e2.
10. *Fierson WM.* *American Academy of Pediatrics Section on Ophthalmology; American Academy of Ophthalmology; American Association for Pediatric Ophthalmology and Strabismus; American Association of Certified Orthoptists.* Screening examination of premature infants for retinopathy of prematurity. *Pediatrics* 2013; 131(1): 189–95.
11. *Felder AR, Levene MI.* Screening for retinopathy of prematurity. *Arch Dis Child* 1992; 67 (7 Spec No): 860–7.
12. *Kennedy KA, Wrage LA, Higgins RD, Finer NN, Carlo WA, Walsh MC, et al.* Evaluating etinopathy of prematurity screening guidelines for 24–27 week gestational age infants. *J Perinatol* 2014; 34(4): 311–8.
13. *Demorest BH.* Retinopathy of prematurity requires diligent follow-up care. *Surv Ophthalmol* 1996; 41(2): 175–8.
14. *Saunders KJ, McCulloch DL, Shepherd AJ, Wilkinson AG.* Emmetropisation following preterm birth. *Br J Ophthalmol* 2002; 86(9): 1035–40.
15. *Hsieh CJ, Liu JW, Huang JS, Lin KC.* Refractive outcome of premature infants with or without retinopathy of prematurity at 2 years of age: A prospective controlled cohort study. *Koahsinung J Med Sci* 2012; 28(4): 204–11.
16. *Siegrwart JT Jr, Norton TT.* Perspective: how might emmetropization and genetic factors produce myopia in normal eyes? *Optom Vis Sci* 2011; 88(3): E365–72.
17. *Troilo D, Wallman J.* The regulation of eye growth and refractive state: an experimental study of emmetropization. *Vision Res* 1991; 31(7–8): 1237–50.
18. *Mutti DO, Mitchell GL, Jones LA, Friedman NE, Frane SL, Lin WK, et al.* Axial growth and changes in lenticular and corneal power during emmetropization in infants. *Invest Ophthalmol Vis Sci* 2005; 46(9): 3074–80.
19. *Cosgrave E, Scott C, Goble R.* Ocular findings in low birthweight and premature babies in the first year: Do we need to screen? *Eur J Ophthalmol* 2008; 18(1): 104–11.
20. *Mutti DO, Hayes JR, Mitchell GL, Jones LA, Moeschberger ML, Cotter SA, et al.* Refractive error, axial length, and relative peripheral refractive error before and after the onset of myopia. *Invest Ophthalmol Vis Sci* 2007; 48: 2510–9.
21. *Choi MY, Park IK, Yu YS.* Long term refractive outcome in eyes of preterm infants with and without retinopathy of prematurity: comparison of keratometric value, axial length, anterior chamber depth, and lens thickness. *Br J Ophthalmol* 2000; 84(2): 138–43.
22. *Chen TC, Tsai TH, Shib YF, Yeh PT, Yang CH, Hu FC, et al.* Long-term Evaluation of Refractive Status and Optical Components in Eyes of Children Born Prematurely. *Invest Ophthalmol Vis Sci* 2010; 51(12): 6140–8.
23. *Cook A, White S, Batterbury M, Clark D.* Ocular growth and refractive error development in premature infants with or without retinopathy of prematurity. *Invest Ophthalmol Vis Sci* 2008; 49(12): 5199–207.
24. *O'Brien C, Clark D.* Ocular biometry in pre-term infants without retinopathy of prematurity. *Eye (Lond)* 1994; 8(Pt 6): 662–5.
25. *Lans DE, Haslett R, Ashby D, O'Brien C, Clark D.* Axial length biometry in infants with retinopathy of prematurity. *Eye (Lond)* 1994; 8(Pt 4): 427–30.
26. *McColm JR, Fleck BW.* Retinopathy of prematurity: causation. *Semin Neonatol* 2001; 6(6): 453–60.
27. *Ho SF, Mathew MR, Wykes W, Lavy T, Marshall T.* Retinopathy of prematurity: an optimum screening strategy. *J AAPOS* 2005; 9(6): 584–8.
28. *Mathew MR, Fern AI, Hill R.* Retinopathy of prematurity: are we screening too many babies? *Eye (Lond)* 2002;16(5): 538–42.
29. *Shah PK, Ramakrishnan M, Sadat B, Bachu S, Narendran V, Kalpana N.* Long term refractive and structural outcome following laser treatment for zone 1 aggressive posterior retinopathy of prematurity. *Oman J Ophthalmol* 2014; 7(3): 116–9
30. *Fledelius HC, Fledelius C.* Eye Size in Threshold Retinopathy of Prematurity, Based on a Danish Preterm Infant Series: Early Axial Eye Growth, Pre- and Postnatal Aspects. *Invest Ophthalmol Vis Sci* 2012; 53(7): 4177–84.
31. *Pennie FC, Wood IC, Olsen C, White S, Charman WN.* A longitudinal study of the biometric and refractive changes in full-term infants during the first year of life. *Vision Res* 2001; 41(21): 2799–810.
32. *Wang J, Ren X, Shen L, Yanni SE, Leffler JN, Birch EE.* Development of Refractive Error in Individual Children With Regressed Retinopathy of Prematurity. *Invest Ophthalmol Vis Sci* 2013; 54(9): 6018–24.

Received on October 19, 2015.

Revised on January 23, 2016.

Accepted on February 4, 2016.

Online First October, 2016.