



## The influence of the position of the medial portal and of lower leg flexion on the length of the femoral tunnel in anatomic anterior cruciate ligament reconstruction – A cadaveric study

Uticaj pozicije medijalnog portala i stepena fleksije u zglobu kolena na dužinu femoralnog tunela prilikom anatomske rekonstrukcije prednje ukrštene veze – kadaverska studija

Ninoslav Begović\*, Marko Kadija†, Gordana Santrač Stijak‡, Mihajlo Ille†, Miloš Mališ§, Ana Starčević§, Berislav Vekić||, Lazar Stijak§

Mother and Child Health Institute, \*Department of Pediatric Orthopedic Surgery, Belgrade, Serbia; Clinical Center of Serbia, †Clinic for Orthopedic Surgery and Traumatology, Belgrade, Serbia; ‡Health Center "Novi Beograd", Belgrade, Serbia; University of Belgrade, Faculty of Medicine, §Department of Anatomy, Belgrade, Serbia; Clinical Centre "Dr Dragiša Mišović", ||Department of Surgery, Belgrade, Serbia

### Abstract

**Background/Aim.** The key to successful anterior cruciate ligament reconstruction lies in the proper positioning of the femoral tunnel within the anatomical footprint and in providing for an adequate length of this tunnel without perforation to the lateral cortex. The aim of this study was to determine the change in the length of the femoral tunnel drilled during anatomic anterior cruciate ligament (ACL) reconstruction, depending on: the position of the limb being operated on, the degree of knee flexion, as well as the angle between the drill and the medial aspect of the lateral condyle. **Methods.** This study was performed on 16 cadaveric knees (6 male and 10 female) of the average age of 83. After the subcutaneous tissue was dissected, the femoral insertion of the ACL was identified. Then, 18 tunnels were drilled through the center of the femoral insertion with the help of 2 mm thick Kirschner wires. This was performed in two stages. In the first phase the leg was positioned on an arthroscopic leg holder, while in the second phase the leg was positioned on the table. In each phase the knee was placed in three different flexion positions (110°, 120° and 130°) and for each position three tunnels were drilled (70°, 60° and 50°) in relation to the medial aspect of the lateral condyle. **Results.** The average length of the femoral tunnel

drilled with the leg positioned on the operating table ( $36.6 \pm 4.7$  mm) was highly statistically significantly greater ( $p = 0.000$ ) in comparison with the length of the femoral tunnel obtained by positioning the leg on a fixed arthroscopic leg holder ( $35.4 \pm 4.3$  mm). The greatest lengths of the femoral tunnel were obtained with the leg flexed at 130° and the reamer positioned at 50° angle in relation to the medial aspect of the lateral condyle (43 mm on the operating table and 41 mm on a fixed leg holder), while the shortest tunnel (33 mm on the operating table and 31 mm on a fixed leg holder) was obtained with the lower leg flexed at 110° and the reamer positioned at a 70° angle. **Conclusion.** The optimal position of the leg on a fixed leg holder for obtaining a femoral tunnel of sufficient length requires lower leg flexion of 120° and the position of the medial portal which enables the positioning of the reamer at a 60° angle in relation to the medial aspect of the lateral condyle. With the leg positioned on the operating table, it becomes unnecessary to push the leg into flexion greater than 110°; rather a longer femoral tunnel is achieved by lateralization of the medial portal.

**Key words:** anterior cruciate ligament reconstruction; cadaver; anatomy, regional.

### Apstrakt

**Uvod/Cilj.** Ključ uspešne rekonstrukcije prednje ukrštene veze nealazi se u pravilnom pozicioniranju femoralnog tunela unutar anatomske otiske i obezbeđivanju adekvatne dužine ovog tunela bez perforacije prema bočnom korteksu.

Cilj ove studije bio je utvrđivanje promene u dužini femoralnog tunela bušenog tokom anatomske rekonstrukcije prednje ukrštene veze (ACL). **Metode.** Studija je rađena na 16 kadaverskih kolena (6 muških i 10 ženskih) prosečne starosti 83 godine. Nakon disekcije potkožnog tkiva i zglobne kapsule, odstranjena je prednja ukrštena veza, a po-

tom je identifikovan femoralni pripoj prednje ukrštene veze. Potom je uz pomoć Kiršenovih igala, kroz centar femoralnog pripoja prednje ukrštene veze, bušeno 18 tunela u dve faze. U prvoj fazi noga je pozicionirana na artroskopskom držaču, dok je u drugoj fazi noga pozicionirana na operacionom stolu. U svakoj fazi koleno je postavljano u tri stepena fleksije (110°, 120° i 130°), pri čemu su u svakom stepenu fleksije bušena po tri tunela koja su sa unutrašnjom stranom spoljašnjeg kondila zaklapala uglove od 70°, 60° i 50°. **Rezultati.** Prosečna dužina femoralnog tunela, izbušenog dok je noga bila postavljena na operacionom stolu ( $36.6 \pm 4.7$  mm), bio je statistički značajno veća ( $p = 0.000$ ) od dužine femoralnog tunela dobijene postavljanjem noge na fiksni držač noge ( $35.4 \pm 4.3$  mm). Najveće dužine femoralnog tunela dobiju one sa fleksijom noge od 130° i postavljanjem burgije pod

uglom od 50° u odnosu na unutrašnju stranu spoljašnjeg kondila (43 mm na operacionom stolu i 41 mm na fiksnom držaču noge). **Zaključak.** Optimalan položaj noge na fiksnom držaču noge za dobijanje dovoljno dugačkog femoralnog tunela podrazumeva fleksiju potkolenice od 120° i poziciju medijalnog portala koja omogućava postavljanje ramera pod 60° u odnosu na unutrašnju stranu spoljašnjeg kondila. Postavljanjem noge na operacioni sto nepotrebno je prilikom bušenja tunela gurati nogu u fleksiju veću od 110°, već se dobijanje veće dužine femoralnog tunela može obezbediti lateralizacijom medijalnog portala.

#### **Ključne reči:**

**ligament prednji, ukršteni, rekonstrukcija; leš; anatomija, regionalna.**

## **Introduction**

The key to successful anterior cruciate ligament (ACL) reconstruction lies in the proper positioning of the femoral tunnel within the anatomical footprint and in providing for an adequate length of this tunnel without perforation to the lateral cortex. Surgically speaking, it is necessary to choose the place of anatomic insertion on the medial aspect of the lateral condyle, and then it is necessary to drill a tunnel of adequate length across that spot without compromising the integrity of the posterior femoral cortex<sup>1</sup>. By decreasing the angle between the reamer and the medial aspect of the lateral condyle the length of the tunnel is increased, but the position of the tunnel is brought closer to the posterior cortex. The application of the suspensory device for fixation on the femur where the tunnel is shorter than 25 mm cannot provide adequate incorporation of the graft into the bone<sup>2,3</sup>, while perforation of the posterior femoral cortex during tunnel drilling, not only increases the duration of the procedure, but also prevents fixation and leads to a new, most frequently non-anatomical position of the femoral graft fixation.

Anatomically speaking, the ideal site of femoral insertion in single-bundle reconstruction would be the place where the superior and the middle third of the bifurcation ridge meet on the medial aspect of the lateral femoral condyle, described in detail by Ferretti et al.<sup>4</sup>. In order to locate this marker, as the place where two angulated surfaces meet, in addition to the surgeon's experience, i.e. his/her "skilled eye", an appropriate position of the lower limb is also necessary, providing for a sufficient level of flexion, so that the entire surface of the medial aspect of the lateral condyle is completely visible.

Although the site of femoral anatomic ACL insertion has been the topic of many studies<sup>4-9</sup>, which have, in various ways, visually described the precise insertion site of the ACL and its bundles, this theoretical knowledge meets with numerous obstacles in practice, when a surgeon needs to choose, in the very confined space of the intercondylar notch, with 30° or 70° optics, the center of graft insertion on the medial aspect of the lateral femoral condyle. This segment of a seemingly simple task decides the fate of the reconstruction

and makes the difference between successful and poorly performed reconstructions. Many colleagues believe that they are indeed performing an anatomic reconstruction of the ACL, but the position of the femoral insertion does not speak to that effect.

The purpose of this study was to determine the extent to which the position of the reamer, which is primarily dependent on the position of the medial portal, and the flexion of the lower leg influence the length of the femoral tunnel in anatomic ACL reconstruction.

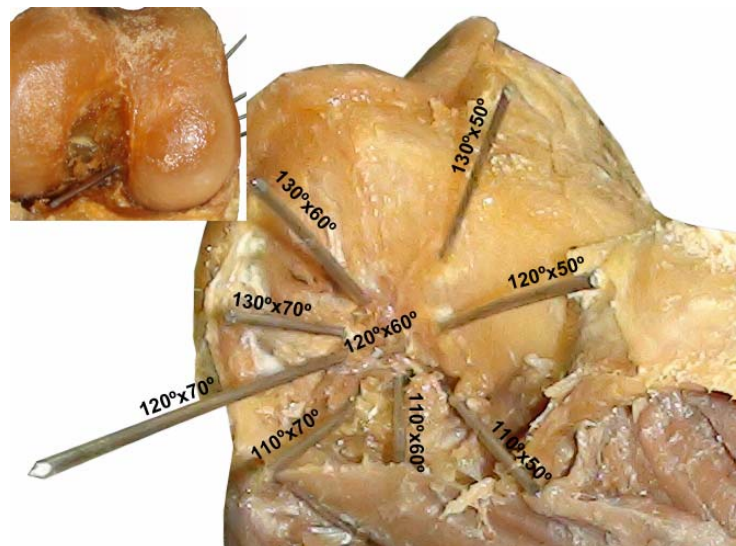
## **Methods**

This study was performed on 16 cadaveric knees (6 male and 10 female, 8 left and 8 right) of the average age of  $83 \pm 6$  years. These knees displayed neither advanced degenerative changes nor bone damage.

Following precise dissection of the soft tissue structures, with preservation of the ligaments of the knee (with the exception of the ACL) the site of anatomical ACL insertion was identified on the medial aspect of the lateral femoral condyle. Then, 18 tunnels were drilled (into two phases) through the center of the femoral insertion with the help of 2 mm thick Kirschner wires.

In the first phase the leg was positioned on an arthroscopic leg holder while in the other phase the leg was positioned on the table. In each phase the knee was placed in three different flexion positions (110°, 120° and 130°) and for each position three tunnels were drilled (70°, 60° and 50°) in relation to the medial aspect of the lateral condyle (Figure 1). Lower leg flexion of 130° approximately matched maximal possible flexion on a fixed leg holder, while the angle between the reamer and the medial aspect of the lateral condyle of 70° coincided with the position of the reamer leaning against the medial femoral condyle.

The three flexion positions of the knee reflected the change stemming from the flexion of the lower leg during surgery (position of the tunnel in the sagittal plane). In the process of drilling each tunnel, the Kirschner wire, i.e. reamer, rested against the anterior margin of the proximal end of the tibia, i.e. against the anterior horn of the medial meni-



**Fig. 1 – Point of exit of nine femoral tunnels. The first number represents the angle of knee flexion, while the second number represents the angle between the reamer and the internal surfaces of the lateral femoral condyle. The picture at the top left corner shows the entrance of the tunnel.**

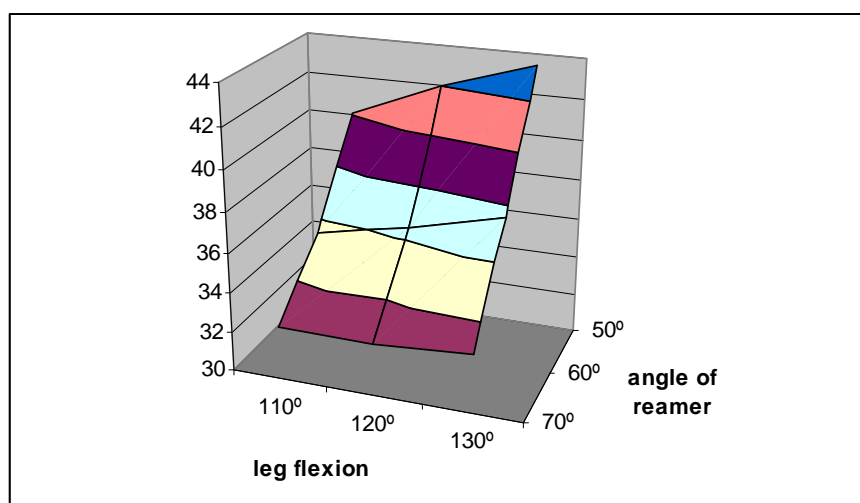
scus, so that lower leg flexion directly influenced the direction of the femoral tunnel. The three different angles formed by the reamer and the medial aspect of the lateral condyle reflected the position of the medial portal through which the reamer was inserted (position of the tunnel in the frontal plane). A wider angle denoted the medial position of the reamer, whereas a more acute angle indicated lateralization of the medial portal.

After drilling, each tunnel was dilated with a 5 mm reamer. The length of each tunnel was measured with the aid of a Kirschner wire and a caliper with the accuracy of 1 mm. The integrity of the posterior femoral cortex was checked for each tunnel.

All data were processed with the aid of the SPSS 11.0 program. The differences between the groups were tested with the Student's *t*-test for linked pairs. The statistical significance was set at  $\leq 0.05$ .

## Results

There was not a single case of posterior femoral cortex perforation in any of the 288 drilled tunnels. By positioning a leg on the operating table, the greatest femoral tunnel length (43.4 mm) was obtained with the leg flexion of 130° and the reamer positioned at an angle of 50° in relation to the medial aspect of the lateral condyle, while the shortest tunnel length (32.6 mm) was achieved when the lower leg was flexed at 110° angle, with the reamer positioned at an angle of 70° (Figure 2). This difference was highly statistically significant. A statistically significant difference was not found in the femoral tunnel length related to the degree of the lower leg flexion between any two neighboring lower leg flexion positions, within any of the three set reamer positions ( $p > 0.05$  in all cases). These values were somewhat greater for greater degrees of flexion, however the noted differences did not prove



**Fig. 2 – The dependence of the tunnel length (mm) on the degree of the lower leg flexion and the angle of the reamer when the leg is positioned on the operating table.**

to be statistically significant. On the other hand, for the same degree of lower leg flexion, the decrease in the angle between the reamer and the medial aspect of the lateral condyle lead to a highly statistically significant increase in the length of the femoral tunnel ( $p < 0.01$  in all of the cases). In other words, when the angle of the reamer was unchanged, the increase of lower leg flexion by  $10^\circ$  lead to an increase of the femoral tunnel length of less than 1 mm, while, when the flexion of the lower leg remained unchanged, the decrease in the angle of the reamer by  $10^\circ$  lead to an increase in the length of the femoral tunnel of more than 4 mm on average.

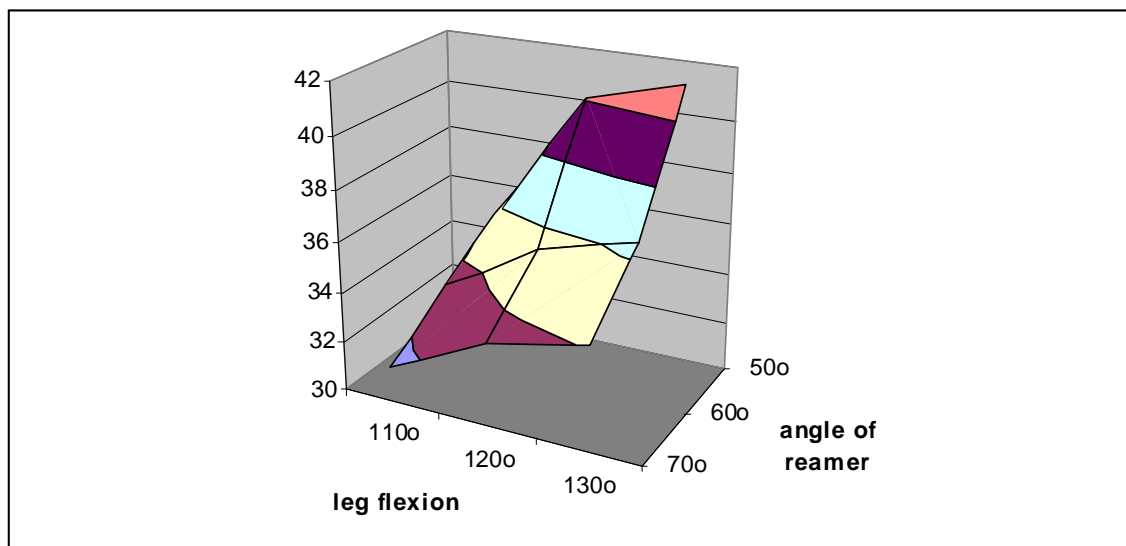
When the operated leg was positioned on a fixed leg holder, the greatest femoral tunnel length (41 mm) was achieved with the leg flexed at  $130^\circ$  angle and the reamer positioned at  $50^\circ$  angle in relation to the medial aspect of the lateral condyle, while the shortest tunnel (31 mm) was obtained when the lower leg was flexed at  $110^\circ$  angle with the reamer positioned at an angle of  $70^\circ$  (Figure 3). This difference is highly statistically significant ( $p = 0.001$ ). The increase in the lower leg flexion from an angle of  $110^\circ$  to an angle of  $120^\circ$  lead to a statistically significant increase in the length of

length by less than 1 mm. When the degree of flexion of the lower leg remained unchanged, the decrease in the reamer angle from  $70^\circ$  to  $60^\circ$  lead to the increase of femoral tunnel length of 2 mm on average, while the decrease in the angle of the reamer from  $60^\circ$  to  $50^\circ$  lead to the increase in femoral tunnel length of up to 5 mm (for the position of lower leg flexion of  $120^\circ$  and  $130^\circ$ ).

The average femoral tunnel length drilled with the leg positioned on the operating table ( $36.6 \pm 4.7$  mm) was highly statistically significant ( $p = 0.000$ ) than the femoral tunnel length achieved with the leg positioned on the fixed leg holder ( $35.4 \pm 4.3$  mm).

### Discussion

The most important finding of the present study is that femoral tunnels drilled on the operating table are significantly longer than the femoral tunnels drilled on a fixed leg holder. Furthermore, the length of the femoral tunnels drilled with a leg positioned on the operating table is minimally dependent on the degree of the lower leg flexion,



**Fig. 3 – The dependence of the tunnel length on the degree of the lower leg flexion and the angle of the reamer when the leg is positioned on a fixed leg holder.**

the femoral tunnel ( $p = 0.001$ ) in all three set reamer positions, while an increase in the lower leg flexion from an angle of  $120^\circ$  to an angle of  $130^\circ$  did not lead to a statistically significant increase in the tunnel length in any of the cases ( $p > 0.05$ ). On the other hand, for the same degree of lower leg flexion, the decrease in the angle between the reamer and the medial aspect of the lateral condyle lead to a highly statistically significant increase in the length of the femoral tunnel ( $p < 0.01$  in all cases), with the exception of the position of the reamer at  $50^\circ$  angle with the lower leg flexed at  $110^\circ$ . When the leg was positioned on a fixed leg holder, if the angle of the reamer remained unchanged, the increase of the lower leg flexion from  $110^\circ$  angle to an angle of  $120^\circ$  lead to the increase of the femoral tunnel by more than 2 mm, while the increase in lower leg flexion from an angle of  $120^\circ$  to an angle of  $130^\circ$  lead to the increase of femoral tunnel

regardless of whether the lower leg is flexed at an angle of  $110^\circ$ ,  $120^\circ$  or  $130^\circ$ . On the other hand, the decrease of the angle of the reamer by  $10^\circ$  results in a significant lengthening of the femoral tunnel. Although the position of the reamer set at an angle of  $50^\circ$  provides for the greatest length of the femoral tunnel (40 mm), the authors of the present study consider that the optimal position of the reamer angle is  $60^\circ$ , as none of the tunnels drilled at this angle was shorter than 31 mm regardless of the degree of flexion of the lower leg. Also, with the decrease of the angle of the reamer from  $70^\circ$  to  $60^\circ$ , the reamer is brought away from the cartilage of the medial condyle, which is often damaged during manipulation when the tunnel is dilated.

When the fixed leg holder is employed it is necessary to provide for lower leg flexion at an angle of  $120^\circ$ , since with lower leg flexion of  $110^\circ$  the frequency of the femoral tunnel

length of 30 mm or less is 25–55% (depending on the angle of the reamer). Further pushing of the lower leg into flexion greater than 120° does not result in a significant increase of the femoral tunnel length.

The breadth of the lateral femoral condyle at the level of the popliteal notch amounts to 27 mm, and at the level of the lateral epicondyle to 33.5 mm<sup>10</sup>. These results, obtained by a direct measurement on macerated thigh bones speak in favor of the fact that, by drilling the femoral tunnel perpendicularly to the medial aspect of the lateral condyle, a length of the tunnel which is rather greater than the breadth of the condyle at the level of the popliteal notch, can be achieved. Flexion of the lower leg at an angle of 120° enables the reamer to be positioned in the direction of the lateral epicondyle and, in that way, the tunnels can be made a little longer. Also, the positioning of the medial portal more laterally, i.e. a reduction of an angle between the reamer and the medial aspect of the lateral condyle provides for a longer femoral tunnel, primarily because the proximal opening of the femoral tunnel surpasses the domain of the epicondyle and in that way extends to the distal portion of the femoral diaphysis.

A part of the results of the present study completely support the results published by Steiner and Sencert<sup>11</sup>. Their femoral tunnel drilled with rigid reamers (32.5) with the lower leg flexed at 110° are in accordance with the results of the present study (32.6 mm) obtained by drilling the femoral tunnel with the leg positioned on a fixed leg holder, with an identical degree of the lower leg flexion and maximal medialization of the medial portal (angle of reamer amounting to 70°). In their study on 106 patients, whose femoral tunnels were drilled with rigid reamers through the anteromedial portal, Tompkins et al.<sup>12</sup> noted the length of the femoral tunnel of 37 mm, with the knee flexed at 134°. For the approximately same lower leg flexion position (130°) on a fixed leg holder, the authors of the present study obtained an approximately equivalent femoral tunnel length (36.4 mm), with the reamer positioned at 60° angle in relation to the medial aspect of the lateral condyle. This identical tunnel length (36.4 mm) was noted by Dong et al.<sup>13</sup> who also measured femoral tunnel lengths obtained with lower leg flexion of 130°–135° on cadaveric knees. Other authors who drilled the femoral tunnel with rigid reamers through the anteromedial portal also noted tunnel lengths supporting the lengths obtained in the present study by using the same means for drilling the tunnels<sup>14</sup>.

In their study, which was a comparison of the length of the femoral tunnel drilled by the application of two different techniques (transportal and outside-in), Kim et al.<sup>15</sup> reported somewhat greater tunnel lengths achieved by the application of the outside-in technique, both for the anteromedial tunnel (38.9 : 34.8 mm) and for the posterolateral tunnel (39.3 : 32 mm). The results of the transportal technique speak in favor of the results of the present study obtained with the lower leg flexed at 110° and a reamer angle of 70°.

In their study, 20 out of 47 subjects, who had undergone anatomic ACL reconstruction, Hensler et al.<sup>16</sup> noted an approximately equal femoral tunnel length (31 ± 6 mm) to

the ones achieved in the present study when the leg was positioned on the leg holder and the lower leg was flexed at 110° angle (reamer angle of 70°). However, the authors did not elaborate on the precise method of femoral tunnel drilling.

By using the anteromedial portal and flexing the lower leg at an angle of 120°, Lee et al.<sup>17</sup> measured an average femoral tunnel length of 34.4 mm on 52 subjects. However they did not specify the angle between the reamer and the medial aspect of the lateral condyle. This tunnel length is somewhat greater than the length achieved in the present study with identical lower leg flexion, but with the reamer angle set at 70°, and it is equally smaller than the tunnel length obtained with the reamer angle set at 60°.

It can be noted that many studies do not specify the angle between the reamer and the medial aspect of the lateral condyle. The authors of the present study believe that this is the result of the operating technique itself, which entails maximal medialization of the medial portal with the reamer leaning against the medial condyle during the tunnel drilling. In such a position, the reamer forms 70° angle with the medial aspect of the lateral condyle, preventing in this way some possible perforation of the posterior femoral cortex. When the medial portal is moved laterally, the angle between the reamer and the medial aspect of the lateral condyle is decreased to 60° or 50°, while the tunnel itself increases in length, ending above the lateral epicondyle in the region of the distal portion of the femoral diaphysis. At the same time, flexion of the lower leg of 110° or more, moves the proximal end of the femoral tunnel forward and prevents the perforation of the posterior cortex.

#### *Clinical relevance*

The use of the operating table, rather than the fixed leg holder, provides for a longer femoral tunnel, independently of the degree of lower leg flexion or the position of the reamer. When the medial portal is moved closer to the ligament of the patella, a more acute angle is achieved between the reamer and the medial aspect of the lateral condyle, which in turn provides for a longer femoral tunnel.

#### *Study limitations*

This study has two significant limitations. Although none of the knees displayed any degenerative changes, the average age of the subjects (83 years) is far above the average age of the patients who normally undergo ACL reconstruction. The other limitation relates to the diameter of the tunnel. Although the authors of this study have noted that no perforation of the posterior femoral cortex was registered in any of the cases, the fact that the tunnel was dilated only to the diameter of 5 mm must be taken into consideration.

#### **Conclusion**

The optimal position of the leg for obtaining a sufficiently long femoral tunnel, when placed on a fixed leg holder, requires a lower leg flexion of 120° and the position

of the medial portal which enables the positioning of the reamer at 60° angle in relation to the medial aspect of the lateral condyle. When the leg is positioned on the operating table

it is unnecessary to push the leg into flexion greater than 110° when drilling the tunnel; a longer femoral tunnel can be achieved by lateralization of the medial portal.

#### R E F E R E N C E S

1. *Kadija M, Bumbaširević M, Blagojević Z, Dubljanin-Raspopović E.* Posterior femoral cortex perforation unrecognised during arthroscopic LCA reconstructive surgery. *Acta Chi Jugosl* 2006; 53(4): 73–8. (Serbian)
2. *Bedi A, Raphael B, Maderazo A, Pavlov H, Williams RJ.* Transtibial versus anteromedial portal drilling for anterior cruciate ligament reconstruction: A cadaveric study of femoral tunnel length and obliquity. *Arthroscopy* 2010; 26(3): 342–50.
3. *Golish SR, Baumfeld JA, Schoderbek RJ, Miller MD.* The effect of femoral tunnel starting position on tunnel length in anterior cruciate ligament reconstruction: A cadaveric study. *Arthroscopy* 2007; 23(11): 1187–92.
4. *Ferretti M, Doca D, Ingham SM, Cohen M, Fu FH.* Bony and soft tissue landmarks of the ACL tibial insertion site: An anatomical study. *Knee Surg Sports Traumatol Arthrosc* 2012; 20(1): 62–8.
5. *Bernard M, Hertel P, Hornung H, Cierpinski T.* Femoral insertion of the ACL. Radiographic quadrant method. *Am J Knee Surg* 1997; 10(1): 14–21.
6. *Moon DK, Yoon CH, Park JS, Kang BJ, Cho SH, Jo HS, et al.* Effect of anteromedial portal entrance drilling angle during anterior cruciate ligament reconstruction: A three-dimensional computer simulation. *Yonsei Med J* 2014; 55(6): 1584–91.
7. *Takabashi M, Matsubara T, Doi M, Suzuki D, Nagano A.* Anatomical study of the femoral and tibial insertions of the anterolateral and posteromedial bundles of human posterior cruciate ligament. *Knee Surg Sports Traumatol Arthrosc* 2006; 14(11): 1055–9.
8. *Tsukada H, Ishibashi Y, Tsuda E, Fukuda A, Tob S.* Anatomical analysis of the anterior cruciate ligament femoral and tibial footprints. *J Orthop Sci* 2008; 13(2): 122–9.
9. *Zauleck MK, Gabriel S, Fischmeister MF, Hirtler L.* Origin of the anterior cruciate ligament and the surrounding osseous landmarks of the femur. *Clin Anat* 2014; 27(7): 1103–10.
10. *Stijak L, Radonjić V, Aksić M, Filipović B, Sladojević M, Santrač SG.* Correlation between femur's length and morphometric parameters of distal femur important in rupture anterior cruciate ligament. *Acta Chir Jugosl* 2009; 56(2): 61–6.
11. *Steiner ME, Smart LR.* Flexible instruments outperform rigid instruments to place anatomic anterior cruciate ligament femoral tunnels without hyperflexion. *Arthroscopy* 2012; 28(6): 835–43.
12. *Tompkins M, Milewski MD, Carson EW, Brockmeier SF, Hamann JC, Hart JM, et al.* Femoral tunnel length in primary anterior cruciate ligament reconstruction using an accessory medial portal. *Arthroscopy* 2013; 29(2): 238–43.
13. *Dong YL, Cai CY, Jiang WH, Jiang GY, Qian YN, Zhao ZW, et al.* Anatomical study on the femoral tunnel anatomy reconstruction of anterior cruciate ligament. *Zhongguo Gu Shang* 2013; 26(9): 757–9.
14. *Ilabi OA, Ventura NJ, Qadeer AA.* Femoral tunnel length: Accessory anteromedial portal drilling versus transtibial drilling. *Arthroscopy* 2012; 28(4): 486–91.
15. *Kim JG, Wang JH, Ahn JH, Kim HJ, Lim HC.* Comparison of femoral tunnel length between transportal and retrograde reaming outside-in techniques in anterior cruciate ligament reconstruction. *Knee Surg Sports Traumatol Arthrosc* 2013; 21(4): 830–8.
16. *Hensler D, Working ZM, Illingworth KD, Tashman S, Fu FH.* Correlation between femoral tunnel length and tunnel position in ACL reconstruction. *J Bone Joint Surg Am* 2013; 95(22): 2029–34.
17. *Lee JK, Lee S, Seong SC, Lee MC.* Anatomic single-bundle ACL reconstruction is possible with use of the modified transtibial technique: A comparison with the anteromedial transportal technique. *J Bone Joint Surg Am* 2014; 96(8): 664–72.

Received on October 11, 2015.

Revised on May 27, 2016.

Accepted on June 17, 2016.

Online First July, 2016.