



## Successful implementation of rituximab in patients with severe refractory forms of granulomatosis with polyangiitis

Uspešna primena rituksimaba kod bolesnika sa teškom refraktarnom formom granulomatoze sa poliangiitismom

Jasna Bolpačić\*<sup>†</sup>, Nevena Savić\*, Snežana Arandjelović\*<sup>†</sup>,  
Vesna Tomić-Spirić\*<sup>†</sup>, Sanvila Rašković\*<sup>†</sup>, Aleksandra Perić-Popadić\*<sup>†</sup>

University of Belgrade, \*Faculty of Medicine, Belgrade, Serbia; Clinical Center of Serbia, <sup>†</sup>Clinic of Allergology and Immunology, Belgrade, Serbia

### Abstract

**Introduction.** Wegener's granulomatosis is a disease characterized by granulomatous inflammation of the upper and/or lower respiratory tract, glomerulonephritis with varying degrees of small vessel vasculitis and classic anti-neutrophil cytoplasmic antibodies (c-ANCA) findings. The treatment uses different modalities of immunosuppressive therapy which does not always lead to remission. We presented the efficacy of biological therapy in a patient with refractory form of the Wegener's granulomatosis. **Case report.** A 23-years-old patient, was treated in August, 2011 at the Clinic of Otorhinolaryngology and Maxillofacial Surgery of the Clinical Center of Serbia because of suppurative otitis media, resulting twice in mastoidectomy. On the day 7 after the surgery, hemoptysis and fever occurred. Considering lung x-ray that showed presence of the round soft-tissue changes on both sides, nonspecific inflammatory syndrome in laboratory analysis and positive c-ANCA (1 : 160) with high titers the antibodies to the proteinase 3 (anti-PR 3), Wegener's granulomatosis was diagnosed. Due to the fact that administration of glucocorticoids, cyclophosphamide and immunomodulatory dose of immunoglobulin did not lead to clinical remission, it was decided to apply rituximab. After its application clinical remission occurred and it lasted fifteen months. **Conclusion.** Application of biologic therapy might be successful in the treatment of patients with severe form of refractory granulomatosis with polyangiitis.

### Key words:

granulomatosis with polyangiitis; therapeutics;  
biological therapy; rituximab; treatment outcome.

### Apstrakt

**Uvod.** Wegener-ova granulomatoza je oboljenje koje karakteriše granulomatозна inflamacija gornjih i/ili donjih disajnih puteva, glomerulonefritis, uz različit stepen vaskulitisa malih krvnih sudova i nalaz c antineutrofilnih citoplazmatskih antitela (ANCA). U lečenju se koriste različiti modaliteti imunosupresivne terapije koji ne dovode uvek do remisije. Prikazana je efikasnost biološke terapije kod bolesnika sa refraktarnom formom Wegener-ove granulomatoze. **Prikaz bolesnika.** Bolesnik, star 23 godine, lečen je avgusta 2011. godine na Klinici za otorinolaringologiju i maksilofacijalnu hiruriju Kliničkog Centra Srbije zbog gnojne upale srednjeg uva. U dva navrata je rađena masteidektomija, a sedmog dana nakon operacije došlo do pojave hemoptizije i febrilnosti. S ozirom na rendgenski snimak pluća na kome su viđene okrugle mekotkivne promene obostrano, laboratorijske analize koje su ukazale na nespecifični zapaljenski sindrom i pozitivne c ANCA (1 : 160) uz povišen titar antitela protiv proteinaze 3 (anti-PR3 antitela), postavljena je dijagnoza Wegener-ova granulomatoze. S obzirom na to da primena glikokortikoida, ciklofosfamida, imunomodulatorne doze imunoglobulina nisu doveli do kliničke remisije, odlučeno je da se primeni rituksimab. Nakon njegove primene uspostavljena je klinička remisija koja je trajala petnaest meseci. **Zaključak.** Primena biološke terapije može biti uspešna u lečenju bolesnika sa teškom refraktarnom formom granulomatoze sa poliangiitismom.

### Ključne reči:

vegenerova granulomatoza; lečenje; biološka terapija;  
rituksimab; lečenje, ishod.

## Introduction

Granulomatosis with polyangiitis is a systemic autoimmune disease which affects upper airways, lungs, kidneys, but any organ could be affected<sup>1</sup>. Diagnosis is based on clinical manifestation of systemic vasculitis and histologically proven necrotizing vasculitis of the blood vessels or granulomatous inflammation<sup>2</sup>. A specific laboratory parameter is the emergence of classic anti-neutrophil cytoplasmic antibodies (c-ANCA) in almost 90% of patients. These are the antibodies to the proteinase 3 (anti-PR 3) which is found in the granules of neutrophils. Height of the c-ANCA titer can be an indicator of disease activity<sup>1</sup>. The clinical picture is severe, remissions are followed by higher percentage of relapses and it is a potentially life-threatening systemic autoimmune disease. The use of aggressive initial immunosuppressive therapy [glucocorticoids and cyclophosphamide (CYC)] is justified because of the high rate of the mortality. Half of the untreated patients died within 6 months while 90% of patients died during 2 years, mainly because of respiratory or renal insufficiency<sup>3</sup>.

We presented a patient with refractory form of granulomatosis with polyangiitis (Wegener's granulomatosis) successfully treated with biological therapy.

## Case report

Male patient, born in 1988, from Belgrade, was treated in August, 2011 at the Clinic of Otorhinolaryngology and Maxillofacial Surgery Clinical Centre of Serbia, due to purulent otitis on the right ear. Mastoidectomy with radical trepanation in the process at the top of the pyramid to the right was done. Since inflammatory syndrome maintained after intensive use of antibiotics, reintervention was done. Seven days after reintervention, due to the poor clinical course, despite the antibiotic therapy (clindamycin, ciprofloxacin) – maintenance of febrile status and elevated inflammatory factors were registered. Bloody sputum occurred. Radiographic findings, and, then, the thoracic computed tomography (CT) showed presence of the round soft-tissue changes on both sides in the lung parenchyma with suspected white shadows. The largest one was localized left, paracardially and was later confirmed by multi-slice (MSCT). Therefore, in September 2011, the patient was transferred to the Clinic of Pulmonology, Clinical Centre of Serbia. Laboratory results showed inflammatory syndrome while all other findings were within normal values including the urine sediment. Immediately on admission, combined antibiotic therapy was administered: clindamycin, cefuroxime, metronidazole, in the further course vancomycin 2 × 1 g, imipenem 3 × 1 g, sulfamethoxazole and trimethoprim, 2 × 2 amp, and at all times patients was febrile. During this hospitalization, pathogenic bacterial flora was not isolated on the bacteriological examination of sputum and by direct microscopy of sputum acid resistant bacilli (ARBs) were not observed (3 ×). Also, there were negative Löw culture, and blood negative on ARBs (3 ×). Tumor markers had normal values.

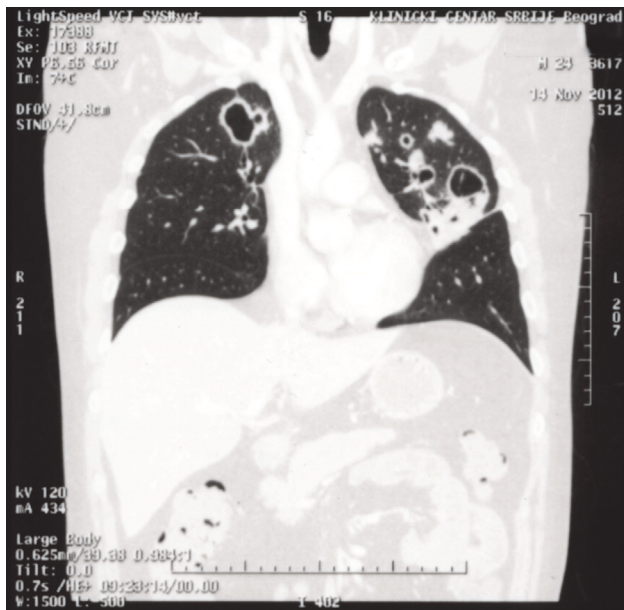
Skin tests and sputum for aspergillus bronchoalveolar lavage (BAL) as antibodies to the antigen aspergillus were negative.

Preserved renal function involved proteinuria and creatinine clearance normal within 24 hours. Bronchial endoscopy indicated signs of inflammation, fiber aspirate was negative on ARBs, and PH bronchoscopy findings revealed chronic bronchitis. After the results of immunoassays: cANCA 1 : 160, anti-PR3 42.3 relative units (RU)/mL, polyangiitis with granulomatosis was diagnosed and patient was transferred to the Clinic of Allergology and Immunology at the Clinical Center of Serbia. Methylprednisolone 3 × 80 mg, was introduced into the therapy. One day after the introduction of the corticosteroid, the patient become afebrile.

During hospitalization, patient received high doses of glucocorticoids (1 mg/kg) followed by gastroprotective therapy and also sulfamethoxazole and trimethoprim. Pulse therapy with CYC at the dose of 1,000 mg, was started and the patient continued to receive it at monthly intervals for the next 5 months, with good clinical and laboratory effects: reduction of the sedimentation (SE) from 90 g/L to 6 g/L, fibrinogen from 6.2 g/L to 2.2 g/L (normal range 2–4 g/L) C-reactive protein (CRP) from 75 mg/dL (normal range 0–10 mg/dL) to 0.2 mg/dL c ANC 1:160 to 1:20, anti-PR3 from 42.3 to 29.9.

In March 2012 the patient was admitted with clinical deterioration: febrile, body temperature up to 39°C, with epistaxis, followed by cough and expectoration of bloody and mucus sputum. Physical findings showed both-sided late-inspiration breaks, more on the left side. Laboratory results showed inflammatory syndrome: SE 90 g/L, fibrinogen 9.9 g/L, CRP 28 mg/dL, leukocytes (Le)  $22 \times 10^9/L$  (normal range  $4.5\text{--}11 \times 10^9/L$ ), trombocytes (Tr)  $609 \times 10^9/L$  (normal range  $150\text{--}400 \times 10^9/L$ ), c-ANCA 1 : 80 and anti-PR3 96.8 RU/mL. Lung and heart X-ray showed one nodose shadow in the mid-lung in midclavicular line on the right and a large nodose shadow in the mediastinum. In the mid-lung on the left, closer to the mid-shadow, a rounded shadow was visible as well as a nodose shadow, closer to the thoracic wall, which corresponded to the primary disease confirmed by the MSCT (Figure 1). The patient was treated with antibiotics, ceftriaxone and ciprofloxacin, with higher doses of glucocorticoids, including pulse doses of methylprednisolone 1,000 mg daily and 6 pulses of CYC at a dose of 1,000 mg, but with incomplete therapeutic effect of the applied therapy. He was discharged with a dose of 40 mg of prednisolone and from May, a therapy with CYC orally at a dose of 150 mg per day was applied. The clinical course of the disease did not improve. Besides activities and primary disease complications, especially colliquation of nodular and necrotic changes, clinical picture was complicated by superimposed respiratory infections and adverse effects of applied glucocorticoid therapy (signs of Cushing's syndrome). In October 2012, patient was again admitted in deterioration, febrile 38.5°C, with cough and expectoration of yellow-green sputum, chest pain, more pronounced in the inspiratory phase, with abundant physical findings in the lungs with low pitch wheezes and rales present in inspiration and expiration. Labo-

ratory results showed inflammatory syndrome, cANCA 1 : 160, anti-PR 3 131 RU/mL. Sputum on bacillus Koch (BK), [mycobacteria growth indicator tube (MGIT) test] was negative. In sputum, *pseudomonas aeruginosa* was isolated. In the lungs, parenchyma round shadows on both sides and nodular shadows in the upper lung field were found as well as abscess mass paracardially on the left with pulmonary condensation zone, indicating poliangiitis with granulomatosis. The patient was treated with a long-term combined antibiotic therapy (piperacillin, imipenem, amikacin) according to the sputum antibiogram in which repeatedly *Pseudomonas aeruginosa* was isolated and with intravenous (*iv*) application of immunoglobulin at a dose of 400 mg/kg for 5 days.

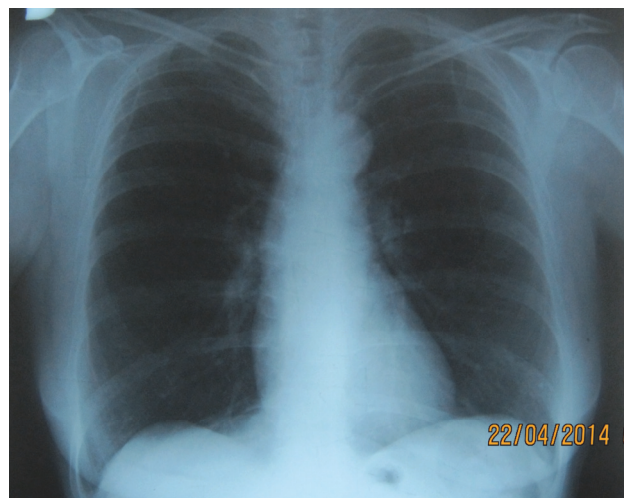

**Fig. 1 – Multislice computed tomography (MSCT) before application of rituximab reveals rounded shadow in mid-lung and large nodose shadow in the mediastinum.**

All modalities of standard immunosuppressive and immunomodulatory therapy (CYC, glucocorticoids, immunoglobulins) were used, but the disease still had a progressive course which was further complicated by the formation of numerous cavities with colliquative necrosis and superimposed infection. For all these reasons, a consultative decision on the application of rituximab (RTX) was made. It was implemented as an induction dose of 375 mg/m<sup>2</sup>, once a week, for 4 weeks, with appropriate premedication, which was approved by the Ethics Committee of the Clinical Center of Serbia. During January and February 2013, an induction of RTX was conducted, at a dose of 375 mg/m<sup>2</sup>, once a week, during 4 weeks with premedication (paracetamol at a dose of 1,000 mg *iv*, methylprednisolone 80 mg *iv*, desloratadin 1 × 1 tbl, ranitidin amp in a small infusion). The patient was in good health condition during the treatment. During that hospitalization, the patient was firstly treated with imipenem at a dose of 1.5 g (according to the sputum antibiogram done due to isolated *Pseudomonas aeruginosa*), after which the results were normal in repeated samples. Afterwards, the patient had

ambulatory follow-ups and was in remission for 15 months. Lung and heart X-ray showed a stationary findings in terms of morphological changes in the lungs. Immunological findings were as follows: cANCA 0 and anti-PR3 19 RU/mL. During periods of remission, B-cell depletion in the sample was verified and it was detected a scarce population of B Ly CD19.8/μL (the reference range 80–490/μL) with elevated absolute lymphocytes count, elevated absolute T-lymphocytes count, elevated absolute CD4+ T cells and, CD8+ T cells (CD3, 3,386/μL; CD3/CD4 1,759/μL and CD3/CD8/1,693 μL). Bacterial smear of specimens from throat, nose, ear and sputum were negative.

Considering that RTX in our country is not registered for use in Wegener's granulomatosis, we were not able to apply any protocol except the "watch and wait" principle of treating. The following relapse occurred in May 2015. Clinical picture included weight loss, cough and hemoptysis with inflammatory syndrome, reactive thrombocytosis, reconstitution of B-cells [immunophenotyping results showed that B lymphocytes population was in relative and absolute values within the reference range, while the absolute values of the total T lymphocytes, subpopulation CD4+ T lymphocytes and natural killer (NK) lymphocytes were significantly reduced], and positivisation of c-ANCA 1:80 and anti-PR3 150 RU/mL. The patient was hospitalized and reapproval of the Ethics Committee for the application of RTX was requested. In the meantime, the patient received high doses of immunoglobulins (human immunoglobulin during 5 days at a dose of 30 g) with combined antibiotic and antimycotic therapy. In June 2014, RTX was repeated during 4 weeks at a dose 4 × 375 mg/kg. During that therapy, the patient received imipenem and fluconazole with probiotics and was re-introduced in a stable clinical remission with complete calming of the inflammatory syndrome and ANCAs negativisation. Lung X-ray finding after the application of rituximab is shown in Figure 2. Since then, the patient has been on regular therapy with prednisone at a dose of 20 mg and methotrexate at a dose of 15 mg per week along with other symptomatic therapy.



**Fig. 2 – Lung X-ray after application of rituximab.**

## Discussion

European League Against Rheumatism (EULAR) published valid recommendations for the treatment of Wegener's granulomatosis in Europe. For induction of remission in generalized forms of the disease it is recommended to apply CYC orally during 3–6 months, or, 6–9 cycles *iv* with application of corticosteroids or, application of RTX at a dose of 375 mg/m<sup>2</sup> in 4 cycles. As therapeutic option for life-threatening vasculitis, especially in rapidly progressive glomerulonephritis and pulmonary hemorrhage plasmapheresis is recommended<sup>4,5</sup>. Maintenance regimen with azathioprine has been replaced by methotrexate, leflunomide and mycophenolate mofetil<sup>4,6,7</sup>.

Refractory disease is defined as a disease in which the maximum tolerated dose of CYC did not have a therapeutic effect, or, CYC could not be applied because of some adverse toxic effects (leukopenia, hemorrhagic cystitis) or contraindications such as the existence of malignancy<sup>8</sup>. For refractory disease or relapse, intravenous application of immunoglobulins for 5 days is recommended, or, application of RTX at a dose of 375 mg/m<sup>2</sup> in 4 cycles. As an option, infliximab or mycophenolate mofetil are proposed<sup>1</sup>.

The presence of B-lymphocytes is essential for the regulation of the immune response and production of antibodies. Also, they have multiple roles such as expression of co-stimulating molecules, production of cytokines, the role of antigen presenting cells, regulation of the activation and differentiation of T-lymphocytes and dendritic cells<sup>9</sup>. They are also responsible for the production of ANCAs that have multiple proinflammatory effects leading to damage of various tissues, organs, and vasculitis<sup>9-11</sup>.

RTX is a chimeric monoclonal antibody against the CD20 antigen, which is superficial cell antigen located on pre-B and mature B lymphocytes, but not on the pro B- cells or plasma cells and blasts. RTX allows cell-mediated cytotoxicity, complement-mediated cytotoxicity and inhibits the early B-cell activation and differentiation resulting in rapid and prolonged depletion of B lymphocytes<sup>12</sup>.

Two randomized controlled trials, RAVE (RTX in ANCA associated vasculitis) and RITUXIVAS (RTX vs CYC in ANCA associated vasculitis), have shown that RTX is effective as CYC for induction of remission in newly diagnosed patients with severe ANCA associated vasculitis and even superior in severe relapses, resistant cases and also, in such cases when it would be desirable to avoid the side-effects of CYC<sup>10,13,14</sup>. Most published reports speak in favor of the extraordinary therapeutic response to the application

of RTX with a minimum of side effects and rare relapses. Despite the fact that the B-cells level reduction after RTX administration was not observed, increased incidence rate of serious infections in these patients was noticed<sup>13</sup>.

The standard protocols of RTX application have not yet been determined. Studies should demonstrate whether it is more efficient principle of RTX administration cycles at certain fixed intervals, or „watch and wait“ approach when a decision about re-application of RTX, in case of relapse, is made based on monitoring of biomarkers and/or the clinical picture. Advised protocols of maintenance therapy are repeated dose of RTX, at a dose of 1 g, in 4-month intervals or 2 per year<sup>4</sup>.

Specks et al.<sup>15</sup> showed that neither the number of B-cells or ANCA titer were predictors of relapse, but as long as both the B-cells and ANCA antibodies were not detectable, a risk of relapse was very low<sup>15</sup>. Expected reconstitution of peripheral B-cells was up to 18 months<sup>2</sup>. Cartin-Ceba R et al.<sup>14</sup> study followed a group of 53 patients with a diagnosis of granulomatous polyangiitis who received at least 2 cycles of RTX on average. They all had depletion of B lymphocytes, all relapses were followed by the B-cells reconstitution and an increase of the c-ANCA level, except in the case of one negative ANCA patient. The average time of reconstitution was 8.5 months. In the case of our patients, remission followed by depletion of B lymphocytes lasted 15 months after the first administration of RTX. Monitoring of the ANCA titer i.e. their positivity, and CD19+ B lymphocytes number, i.e. the reconstitution of their number, were reliable markers of relapse, together with inflammatory syndrome and the clinical picture. In periods of remission, there was a negatiation of ANCA titer antibodies and depletion of B19+ B lymphocytes number.

## Conclusion

The application of standard immunosuppressive therapy does not always result in remission of the Wegener's granulomatosis. Therefore, it is necessary to think about new treatment modalities. Previous worldwide experience in the treatment of this disease, as well as our case reported in which RTX was applied for the first time in Serbia, confirms the importance and effectiveness of biologic therapy. RTX is a promising alternative therapy to the previous immunosuppressive therapy. Also, repeated RTX treatment can be individualized by monitoring laboratory parameters such as CD19+ B lymphocyte numbers and c-ANCA level based on a "watch and wait" principle.

## R E F E R E N C E S

1. *Ebrahim AK, Looek JW.* Case of acute, resistant fulminant Wegener's granulomatosis successfully treated by rituximab. *J Laryngol Otol* 2013; 127(4): 411–4.
2. *Lutalo PM, D'Cruz DP.* Diagnosis and classification of granulomatosis with polyangiitis (aka Wegener's granulomatosis). *J Autoimmun* 2014; 48–49: 94–8.
3. *Hogan SL, Falk RJ, Chin H, Cai J, Jennette CE, Jennette JC,* et al. Predictors of relapse and treatment resistance in anti-neutrophil cytoplasmic antibody-associated small-vessel vasculitis. *Ann Intern Med* 2005; 143(9): 621–31.
4. *Adler S, Villiger PM.* B cell strategy to maintain remission in ANCA-associated vasculitides? *J Rheumatol* 2012; 39(1): 4–5.

5. Jayne DR, Gaskin G, Rasmussen N, Abramowicz D, Ferrario F, Guillevin L, et al. Randomized trial of plasma exchange or high-dosage methylprednisolone as adjunctive therapy for severe renal vasculitis. *J Am Soc Nephrol* 2007; 18(7): 2180–8.
6. Pagnoux C, Mahr A, Hamidou MA, Boffa JJ, Ruyvart M, Ducroix JP, et al. Azathioprine or methotrexate maintenance for ANCA-associated vasculitis. *N Engl J Med* 2008; 359(26): 2790–803.
7. Bosch X, Guillevin L, Espinosa G, Mirapeix E. Treatment of antineutrophil cytoplasmic antibody associated vasculitis: a systematic review. *JAMA* 2007; 298(6): 655–69.
8. Specks U. Biologic agents in the treatment of granulomatosis with polyangiitis. *Cleve Clin J Med* 2012; 79 Suppl 3: S50–3.
9. Keogh KA, Ytterberg SR, Fervenza FC, Carlson KA, Schroeder DR, Specks U. Rituximab for refractory Wegener's granulomatosis: report of a prospective, open-label pilot trial. *Am J Respir Crit Care Med* 2006; 173(2): 180–7.
10. Stone JH, Merkel PA, Spiera R, Seo P, Langford CA, Hoffman GS, et al. Rituximab versus cyclophosphamide for ANCA-associated vasculitis. *N Engl J Med* 2010; 363(3): 221–32.
11. De Groot K, Rasmussen N, Bacon PA, Tervaert JW, Feighery C, Gregorini G, et al. Randomized trial of cyclophosphamide versus methotrexate for induction of remission in early systemic antineutrophil cytoplasmic antibody-associated vasculitis. *Arthritis Rheum* 2005; 52(8): 2461–9.
12. Pescovitz MD. Rituximab, an anti-cd20 monoclonal antibody: history and mechanism of action. *Am J Transplant* 2006; 6(5 Pt 1): 859–66.
13. Jones RB, Tervaert JW, Hauser T, Luqmani R, Morgan MD, Peh CA, et al. Rituximab versus cyclophosphamide in ANCA-associated renal vasculitis. *N Engl J Med* 2010; 363(3): 211–20.
14. Cartin-Ceba R, Golbin JM, Keogh KA, Peikert T, Sánchez-Menéndez M, Ytterberg SR, et al. Rituximab for remission induction and maintenance in refractory granulomatosis with polyangiitis (Wegener's): ten-year experience at a single center. *Arthritis Rheum* 2012; 64(11): 3770–8.
15. Specks U, Merkel PA, Seo P, Spiera R, Langford CA, Hoffman GS, et al. Efficacy of remission-induction regimens for ANCA-associated vasculitis. *N Engl J Med* 2013; 369(5): 417–27.

Received on December 24, 2015.

Revised on March 24, 2017.

Accepted on March 27, 2017.

Online First April, 2017.