



Bilateral ovarian metastases of gallbladder carcinoma – A case report

Obostrane ovarijalne metastaze karcinoma žučne kese

Saša Ljuština*, Svetlana Milenković†, Ružica Maksimović*§, Saša Kadija*§,
Radmila Sparić*§

Clinical Center of Serbia, *Clinic for Gynecology and Obstetrics, †Pathology
Department, ‡Center for Radiology and Magnetic Resonance Imaging, Belgrade, Serbia;
University of Belgrade, §Faculty of Medicine, Belgrade, Serbia

Abstract

Introduction. Gallbladder carcinoma is a rare malignancy with a poor prognosis because it is diagnosed late. There are only a few cases of ovarian metastasis from gallbladder carcinoma described in the literature. We presented a rare case of ovarian metastasis of gallbladder carcinoma and highlight the importance of differentiation between primary and metastatic ovarian tumors. **Case report.** A 55-year old women had cholecystectomy for suspected cholecystitis. However, histological findings showed invasive adenocarcinoma of her gallbladder. The patient refused further proposed treatment. Three months later, the same patient presented with abdominal pain and discomfort. Imaging diagnostic methods (magnetic resonance scan) showed no local tumour mass at the site of cholecystectomy, but large, bilateral, multilocular ovarian tumor of mixed consistency. During surgery, ovarian tumours and infiltration of omentum was found. A total abdominal hysterectomy with bilateral salpingo-oophorectomy and omentectomy was performed. Histological findings indicated adenocarcinoma but could not distinguish between a primary ovarian carcinoma and gallbladder metastatic tumor. An immunohistochemical examination clarified that the findings corresponded to metastatic ovarian adenocarcinoma from the gastrointestinal tract, i.e., adenocarcinoma originating from the gallbladder. Unfortunately, the patient did not successfully recover and died three months later. **Conclusion.** The presence of ovarian masses of unknown origin and a diagnostic dilemma between primary and metastatic tumor require careful clinical, radiological, intraoperative, and histological examination for the purpose of establishing a definitive diagnosis and providing optimal treatment.

Key words:

gallbladder neoplasms; neoplasm metastasis; ovary; diagnosis, differential; immunohistochemistry; treatment outcome.

Apstrakt

Uvod. Karcinom žučne kese je redak malignitet koji zbog kasnog dijagnostikovanja ima lošu prognozu. U literaturi je opisano samo nekoliko slučajeva ovarijalnih metastaza karcinoma žučne kese. Prikazan je redak slučaj bolesnice sa ovarijalnim metastazama karcinoma žučne kese sa akcentom na značaju diferencijalne dijagnoze između primarnih i metastatskih tumora jajnika. **Prikaz bolesnika.** Bolesnica starosti 55 godina zbog sumnje na zapaljenje žučne kese urađena je holecistektomija. Međutim, histološkom analizom utvrđeno je da se radilo o karcinomu žučne kese. Bolesnica je odbila predloženo dalje lečenje. Posle tri meseca javila se u ambulantu zbog bolova u trbuhu. Imidžing dijagnostikom (magnetna rezonanca) isključeno je prisustvo lokalnih tumorskih masa na mestu holecistektomije, ali su vizualizovani veliki obostrani tumori jajnika mešovite konzistencije. Intraoperativno, nađeni su tumori jajnika i infiltracija omentuma. Urađena je totalna histerektomija sa obostranom adneksektomijom i totalna suprakolična omentektomija. Histologijom je utvrđeno da se radilo o adenokarcinomu, ali je ostalo nejasno da li se radilo o primarnom adenokarcinomu jajnika ili metastazama karcinoma žučne kese. Tek imunohistochemijskom analizom utvrđeno je da se radilo o metastatskom karcinomu jajnika porekla gastrointestinalnog trakta, najverovatnije žučne kese. Nažalost, bolesnica nije uspela da se oporavi i preminula je nakon tri meseca. **Zaključak.** Prisustvo ovarijalnih tumora nepoznatog porekla i dijagnostička dilema između primarnog i metastatskih tumora zahtevaju pažljivo kliničko, radiološko, intraoperativno i histološko ispitivanje, sa ciljem postavljanja definitivne dijagnoze i pružanja optimalnog lečenja bolesnika.

Ključne reči:

žučna kesa, neoplazme; neoplazme, metastaze; jajnik; dijagnoza, diferencijalna; imunohistochemija; lečenje, ishod.

Introduction

Gallbladder carcinoma is a rare malignancy with a poor prognosis due to the fact that it is almost always diagnosed at a late stage of the disease^{1,2}. There are no differences in the clinical presentations of benign biliary disease and gallbladder carcinoma, which is why gallbladder carcinoma must always be kept in mind². The tumour spreads most commonly by direct extension and may involve adjacent organs (liver, bile duct, duodenum, colon), while vascular invasion can cause distant metastasis into the liver, lungs, and other organs.

Approximately 5% to 15% of malignant ovarian tumors are metastases from other sites (genital or non-genital tract tumours)³. Making an accurate distinction between primary and metastatic ovarian tumors is of a great importance since mistakes in interpretation can lead to inadequate treatment and suboptimal outcomes. The origin of ovarian metastasis is usually the gastrointestinal tract with the best known metastasis being the Krukenberg tumor arising in 73% from gastric cancer⁴. Moreover, some researchers showed that the most common non-genital malignant tumors presenting with ovarian metastasis are colon cancer, followed by appendix and breast⁵. On the other hand, there are only a few cases of ovarian metastasis from gallbladder carcinoma described in literature⁶⁻⁹.

Case report

A 55-year-old woman underwent a classic cholecystectomy for suspected cholecystitis. As the histologic exami-

nation of the gallbladder showed invasive adenocarcinoma, the Clinic Cancer Board indicated an exploratory laparotomy for radical resection, but the patient refused the proposed reoperation and any further treatment. Three months later, the same patient presented to a gynaecological outpatient clinic with lower abdominal pain and discomfort. A mass arising from her pelvis and extending to the umbilical level of the abdomen was palpated on a bimanual examination and presented as solid. The patient's blood count and liver function tests were within normal limits. A serum level of Ca-125 was 80.6 U/mL (reference range 0–21 U/mL). Pelvic ultrasonography showed large, bilateral, multiseptated ovarian tumors with solid components and the presence of a large amount of ascites in the abdomen. A magnetic resonance (MR) scan of her pelvis and abdomen was performed (Figure 1).

A chest radiograph revealed left-sided pleural effusion. After a preoperative evaluation, an exploratory laparotomy was performed. Intraoperative findings revealed about five litres of ascites and bilateral adnexal tumors. The left adnexal tumor was 20 × 15 cm in diameter, and the right one was 15 × 10 cm. Both tumors were of semisolid consistency and smooth greyish surface, and identification of the ovarian or tubal tissues was impossible. Tumor infiltration of the bladder wall and omentum was identified as well as massive adhesions. A total abdominal hysterectomy with bilateral salpingo-oophorectomy and resection of the visualized tumor masses and omentectomy were performed.

The postoperative course was uneventful, and the patient was discharged from hospital on the eighth postoperative day.

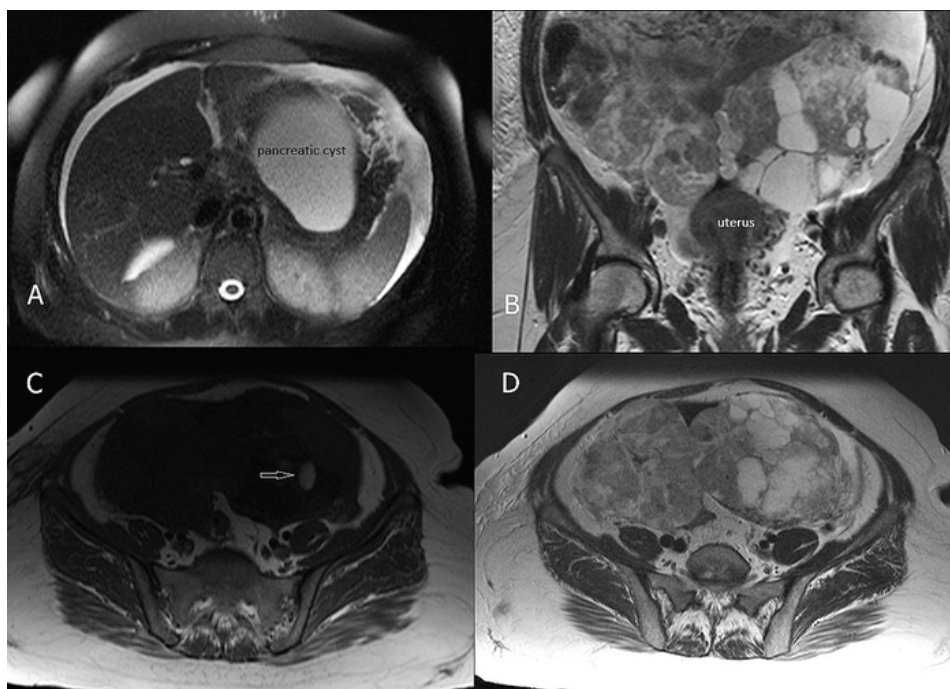


Fig. 1 – Magnetic resonance imaging findings: A) The local tumor mass was not seen at the site of the cholecystectomy. The T2w FS image reveals ascites as well as the presence of a big, encapsulated, well-defined, cystic mass in the pancreatic tail; B) Bilateral ovarian tumor masses, multilocular and with thick septa, of inhomogeneous signal intensity are seen in a coronal T2w image. Both tumor masses are well delineated without infiltration of adjacent structures; C) An axial T1w FS image showed the presence of small areas of haemorrhage in the tumor mass (indicated by an arrow); D) No enlarged parailiac lymph nodes are noted on the axial T2w image.

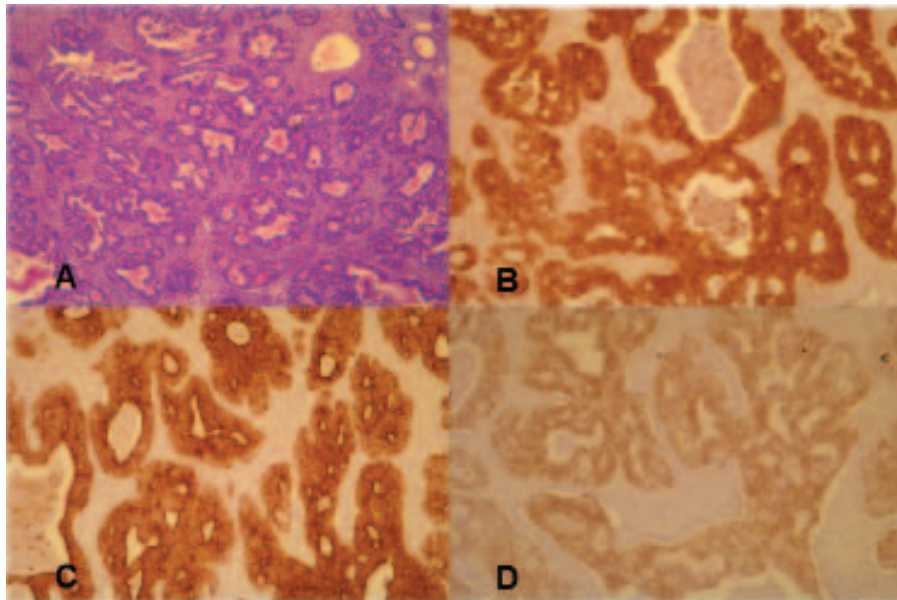


Fig. 2 –A) Small gland adenocarcinoma in a prominent desmoplastic stroma (hematoxylin and eosin, $\times 5$); B) The tumor cells are diffusely and strongly positive for β -catenin ($\times 10$); C) CK7 ($\times 10$), and D) CDX-2 ($\times 10$).

Histological findings were, on the basis of morphology, unable to determine whether the patient was a case of primary ovarian carcinoma or gallbladder metastatic tumor. The histologic specimen was routinely processed and embedded in paraffin, and sections were stained with hematoxylin-eosin for light microscopic examination (Figure 2A). The well-differentiated adenocarcinoma was formed of small tubular and rare microcystic glands surrounded by desmoplastic, or more often, oedematous stroma. The glands and microcysts had attenuated lining cells. Haemorrhage and necrosis were spread in the tumor, and residual ovarian structures were not presented. A review of the histological findings indicated adenocarcinoma, which had the same morphological characteristics as the gallbladder adenocarcinoma of the patient, and concluded that a definitive diagnosis required immunohistochemical examinations of specimens of both the gallbladder and the ovaries.

Immunohistochemistry was performed on paraffin sections with a broad spectrum of immunohistochemical stains (Figures 2B, 2C, 2D). The tumor cells showed diffuse strong labelling for CK7, CDX-2, and β -catenin, but only focal CK-20. Expression of ER, PR, WT-1, and Ca-125 was absent. Based on light microscopy appearance along with the immunohistochemistry staining, the final diagnosis of ovarian metastasis of primary gallbladder adenocarcinoma was made.

The definitive decision made by the Clinic Cancer Board after the surgical treatment was that specific oncological treatment was not indicated considering the disease severity and the overall condition of the patient, but that symptomatic and supportive therapy was indicated.

Unfortunately, the patient died three months after the gynaecological surgery due to an advanced stage of malignancy. The patient's family refused to give consent for the autopsy.

Discussion

The clinical presentation of gallbladder carcinoma mimics benign conditions, which is why gallbladder carcinoma is often diagnosed at an advanced stage and therefore has a poor prognosis. The patient we are reporting on was also misdiagnosed due to confusing symptomatology. Overall mean survival is a mere six months, while the five-year survival rate is only 5%¹⁰. The most common metastatic lesions are in the liver, pancreas, and common biliary duct¹¹.

Most metastatic ovarian tumors originate from the gastrointestinal tract, breast, and gynaecologic organs. Unlike colon or appendix carcinoma, or primary tumors of the upper gastrointestinal tract, which usually produce metastatic transformations of the ovary, ovarian biliary metastases are rare¹. In general, patients with metastatic ovarian cancer are younger than patients with primary epithelial ovarian tumors, which proved to be true for our patient as well. The reported median age is between 35.7 and 55 years⁴.

It is very important to distinguish metastatic ovarian tumours from primary ovarian cancer; otherwise, the patient may get insufficient treatment since imaging findings cannot make accurate distinctions. Available literature data suggest that bilaterality and semisolid, semicystic consistency point to metastatic ovarian tumors³. In 66% of cases, metastatic ovarian cancers are bilateral tumours that symmetrically enlarge the ovaries, retaining the overall ovarian outline⁴, features which were present in our case as well.

Misinterpretation of metastatic ovarian tumors as primary ovarian neoplasms occurs more often when ovarian lesions are the first manifestation of the disease. In the presented case, the data on the previous surgery, histological diagnosis of the gallbladder adenocarcinoma, and

current local findings of the bilateral adnexal masses and their macroscopic appearance could have led to a reasonable conclusion of metastatic ovarian tumor. Nonetheless, the fact that there were neither local metastases nor recidivism of the primary carcinoma was misleading. Moreover, the presentation of unusually advanced ovarian vascular deposits, rather than local metastases of the gallbladder carcinoma, makes this case distinctive. Finally, only an immunohistochemical analysis was able to clarify any doubts and disregard the possibility of primary ovarian adenocarcinoma.

Conclusion

The presence of ovarian masses of unknown origin and the diagnostic dilemma between primary and metastatic tumors require careful clinical, radiological, intraoperative, and histological examination for the purpose of establishing a definitive diagnosis. Whenever adnexal masses are detected, it is necessary to conduct an evaluation of the patient's gastrointestinal tract.

R E F E R E N C E S

1. Goetze TO. Gallbladder carcinoma: Prognostic factors and therapeutic options. *World J Gastroenterol* 2015; 21(43): 12211–7.
2. Butte JM, Matsuo K, Gönen M, D'Angelica MI, Waugh E, Allen PJ, et al. Gallbladder cancer: differences in presentation, surgical treatment, and survival in patients treated at centers in three countries. *J Am Coll Surg* 2011; 212(1): 50–61.
3. Brown DL, Zou KH, Tempany CM, Frates MC, Silverman SG, McNeil BJ, et al. Primary versus secondary ovarian malignancy: imaging findings of adnexal masses in the Radiology Diagnostic Oncology Group Study. *Radiology* 2001; 219(1): 213–8.
4. Kesic V, Stojanovic N, Sparic R. Surgery of Ovarian Metastases: special considerations. *CME J Gynecol Oncol* 2006; 11: 93–100.
5. Moore RG, Chung M, Granai CO, Gajewski W, Steinhoff MM. Incidence of metastasis to the ovaries from nongenital tract primary tumors. *Gynecol Oncol* 2004; 93(1): 87–91.
6. Carlomagno C, Insabato L, Bifulco G, De Placido S, Lauria R. Ovarian metastasis following gallbladder carcinoma: a case report. *Eur J Gynaecol Oncol* 2010; 31(2): 219–21.
7. Kumar Y, Chahal A, Garg M, Bbutani A. Occult gallbladder carcinoma presenting as a primary ovarian tumor in two women: two case reports and a review of the literature. *J Med Case Rep* 2010; 4: 202.
8. Sun HD, Tsai CC, Hsiao SM, Wei MC, Wang KC, Wang PH. Primary gallbladder carcinoma presenting as advanced-stage ovarian cancer. *Taiwan J Obstet Gynecol* 2012; 51(3): 443–5.
9. Singh S, Gupta P, Khanna R, Khanna AK. Simultaneous breast and ovarian metastasis from gallbladder carcinoma. *Hepatobiliary Pancreat Dis Int* 2010; 9(5): 553–4.
10. Hundal R, Shaffer EA. Gallbladder cancer: epidemiology and outcome. *Clin Epidemiol* 2014; 6: 99–109.
11. Gourgiotis S, Kocher HM, Solaini L, Yarollahi A, Tsiambas E, Salemis NS. Gallbladder cancer. *Am J Surg* 2008; 196(2): 252–64.

Received on October 15, 2016.

Revised on March 3, 2017.

Accepted on March 6, 2017.

Online First March, 2017.