



The role of a captopril renal scintigraphy in examination of children with hypertension – A case report

Uloga kaptoprilske scintigrafije u ispitivanju dece sa hipertenzijom

Biljana Milošević*†, Radmila Žeravica†‡, Slobodan Grebeldinger†§,
Marija Vukmirović Papuga‡, Dalibor Ilić^{||}

Institute of Children and Youth Health Care, *Department of Nephrology,

§Clinic of Pediatric Surgery, Novi Sad, Serbia; University of Novi Sad,

†Faculty of Medicine, Novi Sad, Serbia; Clinical Center of Vojvodine,

‡Department of Nuclear Medicine, ||Center of Radiology, Novi Sad, Serbia

Abstract

Introduction. Secondary hypertension is a relatively common form of hypertension in childhood with renovascular hypertension being responsible for 5%–10% of all arterial hypertension in children. An early diagnosis of renovascular hypertension is important when considering an appropriate treatment of hypertension that may prevent or slow further progression of kidney damage. To validate the usefulness of a captopril renal scintigraphy in hypertensive children, we report a case of a 16-year-old female patient with a history of hypertension as a result of fibromuscular dysplasia. **Case report.** The patient was asymptomatic with elevated blood pressure revealed by a routine physical examination. Laboratory tests showed the increased levels of plasma renin activity with the normal levels of aldosteron. The renal ultrasound was normal. The Doppler of the renal arteries showed no significant differences of resistive index. A renal captopril scintigraphy was performed, including two day study protocol, the baseline study followed by another captopril study several days later. The scintigraphy showed the abnormal baseline and captopril renogram curve of the right kidney with significant cortical retention of radiotracer after angiotensin-converting enzyme inhibition. Following the captopril scintigraphy a renovasography was obtained confirming the presence of a 2 mm long circular narrowing of the right renal artery. It was immediately treated resulting in a significant expansion of the lumen. **Conclusion.** The captopril renal scintigraphy allows non-invasive functional testing in a selected group of hypertensive children, which can either confirm or rule out the existence of hemodynamically significant renal artery stenosis.

Key words:

hypertension, renovascular; child; diagnostic techniques and procedures; radionuclide imaging; captopril; renal circulation.

Apstrakt

Uvod. Sekundarna hipertenzija je najčešći oblik hipertenzije kod dece i renovaskularna hipertenzija je odgovorna za 5%–10% svih hipertenzija. Pravovremeno otkrivanje renovaskularne hipertenzije je važno jer omogućuje specifičan tretman koji vodi do odgovarajućeg lečenja hipertenzije, čime se utiče na prevenciju nastanka i dalje progresije parenhimskog oštećenja bubrega. U cilju potvrde korisnosti kaptoprilske scintigrafije bubrega u skriningu hipertenzivne dece prikazujemo slučaj šesnaestogodišnje devojčice sa istorijom hipertenzije uzrokovane fibromuskularnom displazijom. **Prikaz slučaja.** Bolesnica je bila bez simptoma. Povišen krvni pritisak je otkriven prilikom rutinskog sistematskog pregleda. Laboratorijske analize su otkrile povišene vrednosti reninske aktivnosti plazme uz vrednosti aldosterona koje su bile u granicama referentnih vrednosti. Ultrasonografski nalaz bubrega bio je uredan. Dopler krvnih sudova bubrega nije ukazivao na prisustvo signifikantne razlike u vrednostima indeksa otpora. Urađena je kaptoprilska scintigrafija bubrega, koja uključuje bazalnu studiju dinamske scintigrafije bubrega, a potom ponovljenu dinamsku scintigrafiju bubrega sa premedikacijom kaptoprilom. Kaptoprilska scintigrafija ukazala je na patološki nalaz bazalne i kaptoprilske renografske krivulje desnog bubrega sa značajnom kortikalnom retencijom radioobeleživača nakon inhibicije angiotenzin konvertujućeg enzima. Nakon kaptoprilske scintigrafije, renovazografija je potvrdila prisustvo cirkularnog suženja desne renalne arterije u dužini od 2 mm. Neposredno nakon potvrde stenozе desne bubrežne renalne arterije urađena je balon dilatacija i postignuto je značajno proširenje lumena. **Zaključak.** Kaptoprilska scintigrafija bubrega omogućava neinvazivno funkcionalno ispitivanje u selektovanoj grupi hipertenzivne dece koja može potvrditi ili isključiti postojanje hemodinamski značajne stenozе renalne arterije.

Ključne reči:

hipertenzija, renovaskularna; deca; dijagnostičke tehnike i procedure; scintigrafija; kaptopril; bubreg, cirkulacija krvi.

Introduction

According to several epidemiological studies, the prevalence of hypertension in children is approximately 1%–3%, increasing with obesity in older children¹. Secondary hypertension is a relatively common form of hypertension in childhood and renovascular hypertension (RVH) is responsible for 5%–10% of all arterial hypertension in children². RVH is defined as hypertension caused by renal hypoperfusion, usually due to anatomic renal artery stenosis (RAS) and the activation of the renin-angiotensin aldosterone system (RAAS). The critical degree of stenosis leads to a reduction in renal perfusion pressure below the range of autoregulation while the experimental hemodynamic studies indicate that measurable changes in perfusion pressure do not develop until the stenotic lesion cross section area is reduced by at least 70%–75%. The most common causes of RAS are fibromuscular dysplasia (FMD) in younger population and atherosclerosis in elderly population²⁻³.

A captopril renal scintigraphy (CRS) represents a non-invasive functional test aiming to demonstrate both the RAAS activation and the lateralization of renin secretion by the kidney affected by a “hemodynamically significant” RAS. The captopril scintigraphy is based on the fact that the reduced renal perfusion pressure, due to renal artery stenosis, results in an angiotensin II-mediated efferent arteriolar vasoconstriction, as described by Gates⁴. The following rise of the transglomerular pressure gradient allows the kidney to maintain the glomerular filtration rate (GFR) even in the condition of the reduced perfusion pressure to the glomerulus. Premedication with an angiotensin-converting enzyme (ACE) inhibitor interrupts the renin-angiotensin system reducing the compensatory vasoconstriction of the efferent arteriole. The consequent dilatation lowers the glomerular transcapillary pressure, leading to a decrease in GFR. The decrease of the individual kidney GFR, induced by inhibition of ACE, can be evaluated by the captopril scintigraphy with the use of tubular agents, such as technetium-99m mercaptoacetyl triglycine (MAG3) or technetium-99m ethylenedicysteine (EC) or by glomerular agent, such as technetium-99m diethylene triamine penta-acetic acid (DTPA)⁵.

Diagnosis of RVH is important since it enables a specific treatment leading to the cure of arterial hypertension that may prevent or slow progression of kidney damage. Nowadays, many tests are available for the evaluation of RVH⁶. The conventional angiography represents the gold standard used to diagnose renal artery stenosis mainly in adults. However, this is an invasive test with potential risks, usually requiring hospitalization and general anesthesia, principally in pediatric population. For these reasons, it is not universally performed for the evaluation of pediatric hypertension. Several non-invasive methods have been recommended for evaluation of RVH in children, but their specificity and sensitivity varies widely⁷⁻⁹.

To validate the usefulness of the captopril renal scintigraphy in hypertensive children, we report a case of a 16-year-old female patient with a history of hypertension as a result of FMD.

Case report

A 16-year-old female with a history of high blood pressure (BP) was referred to our department by a pediatric nephrologist, for the renal captopril scintigraphy. The patient was asymptomatic with elevated blood pressure revealed by a routine physical examination. The family history of hypertension was positive (father suffering from hypertension and receiving antihypertensive therapy). Her physical examination revealed a blood pressure of 170/95 mmHg (multiple readings taken from both arms).

During hospitalisation at the Pediatric Nephrology Department, a high BP was confirmed, with the value of 145/95 mmHg (which is more than 95% for her age, gender and height). Body mass index (BMI) was recorded to be 20.2 kg/m². Laboratory tests showed the increased levels of plasma renin activity with the normal levels of aldosterone. The blood urea nitrogen, creatinine and uric acid values were within the normal limits.

Urin analysis reported the elevated albumin/creatinin ratio and the patient tested positive for proteinuria and microalbuminuria (24 hour urine collection). The renal ultrasound was normal. The doppler of the renal arteries showed no significant differences in resistive index (RI on *aa.arcuata* left was 0.6 and RI on right *aa. arcuata* was 0.56). Evidence of *retinopathia hypertensiva* gradus I–II was discovered during a fundus examination. There was no carotid, abdominal or femoral arterial bruits. The electrocardiography (ECG) was normal but the echocardiography showed left ventricular hypertrophy. The suggested therapy for her hypertension was a calcium channel blocker.

A two-day study protocol was performed including a baseline scintigraphic study followed by another dynamic scintigraphy several days later, the latter with the captopril premedication (25 mg of captopril) one hour before the test. The patient was hydrated with 10 mL of water per kg of body weight half an hour before both studies. The blood pressure (BP) was measured prior to the captopril intake and after 60 minutes of rest.

The study protocol for the basal and captopril scintigraphy implies the patient being in the supine position with the gamma camera facing the lower back of the patient, with the kidneys, heart and bladder in the field of view. Starting immediately after the intravenous injection of 99mTc-MAG3 (Mallinckrodt Ltd.) at a dose according to an international scale, serial 10-second/frame images were obtained for 30 min. A single-headed large field of view gamma camera (Symbia, Siemens) equipped with a general-purpose parallel-hole collimator was used. The analyses were made using the software for renal scintigraphy. Regions of interest (ROI) were manually drawn around the whole kidney and perirenal background as well. The renographic curves of the right and left kidneys were analysed separately and the relative function of each kidney (in percentage) was calculated as well as the functional renal indices¹⁰.

The CRS showed the abnormal baseline and captopril renogram curve of the right kidney with significant cortical retention of radiotracer after the ACE inhibition. During the

baseline study, the functional renal indices of the right kidney (Tmax and the 20 min/peak min count ratio) had pathological values, showing significant deterioration after the ACE inhibition (Figures 1 and 2). The relative kidney func-

tion of the right kidney was 45%. According to the diagnostic criteria based on the consensus report, these findings were indicative of a high probability of renal vascular hypertension¹¹.

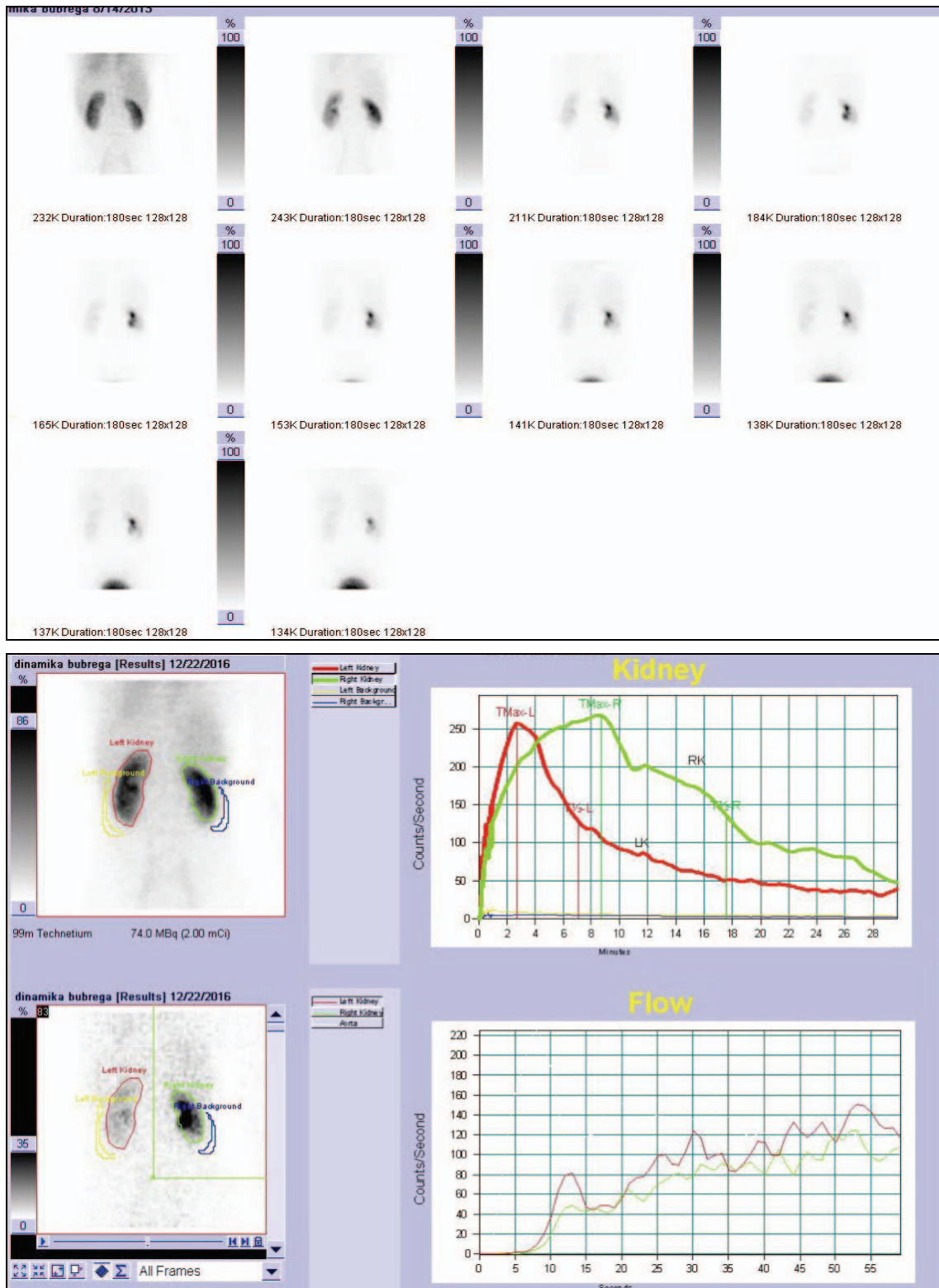


Fig. 1 – Baseline study – unilateral retention of radiotracer in the right kidney with the abnormal baseline renogram curve. The time to maximum counts of the right kidney was 8.6 minutes and to the left kidney was 2.6 minutes. A 20 min/peak min count ratio of the right kidney was 0.39 – prolonged transit time. A 20 min/peak min count ratio of the left kidney was 0.15 – normal transit time.

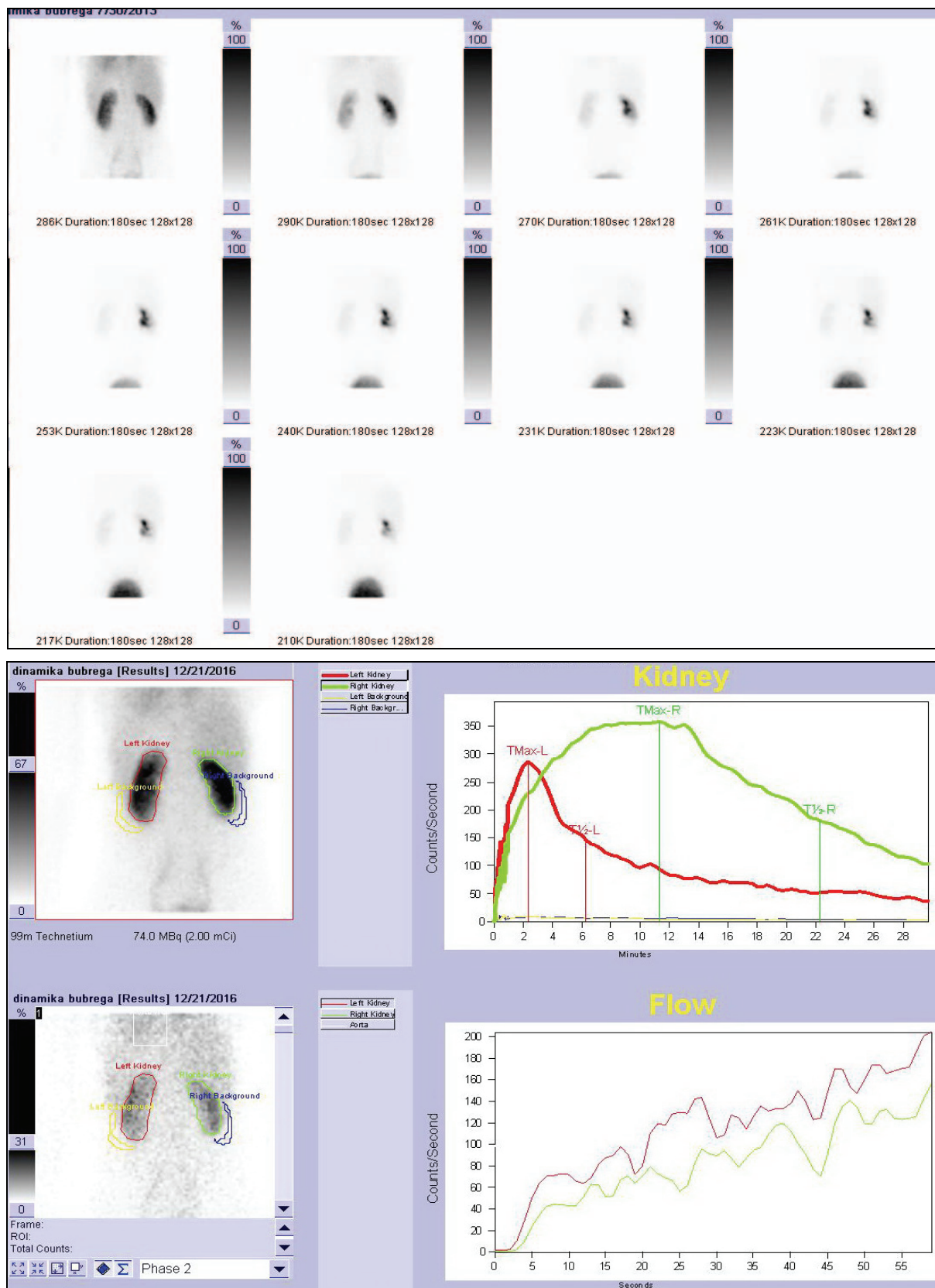


Fig. 2 – Captopril study – marked parenchymal retention after angiotensin-converting enzyme (ACE) inhibition of radiotracer and the abnormal renogram curve of the right kidney. Time to maximum counts of the right kidney after ACE inhibition was 11.6 minutes and 20 min/peak min count ratio of the right kidney was 0.65 – a significant increase in T max and prolongation of transit time from the baseline study.

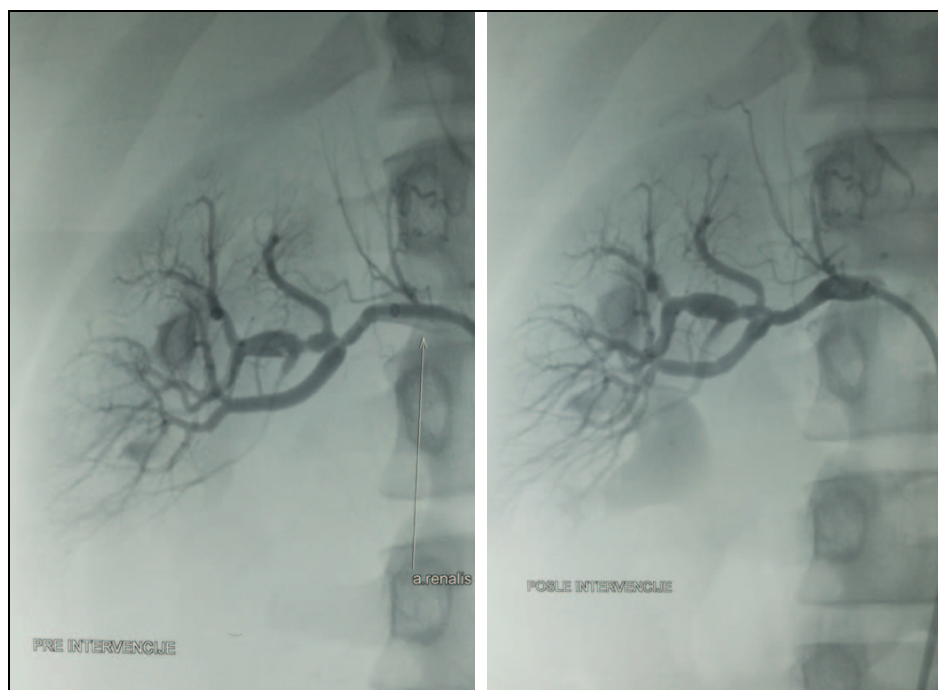

Fig. 3 – The renal angiography: Before the procedure, the presence of a circular narrowing of the right renal artery; After a percutaneous balloon dilatation, a significant expansion of the lumen was achieved.

Following the captopril scintigraphy a renovasography was performed, confirming the presence of a 2 mm long circular narrowing of the right renal artery. It was immediately treated by a percutaneous balloon dilatation of the stenosis on the bifurcation of the renal artery and two segmental branches resulting in a significant expansion of the lumen (Figure 3).

The follow-up captopril renal scintigraphy showed significantly improved parenchymal indicators of the right kidney without any signs of cortical retention of radiotracer (Figure 4). The repeated renin activity plasma test was within the normal limits. The patient's blood pressure normalized over a period of several months resulting in the discontinuation of antihypertensive therapy. The patient's BP is currently within the normal limits and she actively plays sports.

Discussion

Arterial hypertension poses a significant risk factor for cardiovascular, renal and cerebrovascular diseases. In childhood, arterial hypertension is usually of the secondary origin, mainly due to a renal disease. Since RVH is potentially treatable, it is essential to identify these patients.

As discussed above, conventional angiography is considered the gold standard in diagnosis, but it is invasive, relatively expensive and exposes the kidney to a contrast load. Therefore, it is less useful as a screening test. A number of screening tests have been developed. Being less invasive and carrying the least possible radiation burden, the captopril renal scintigraphy and Doppler ultrasonography are suggested to be the initial tests in the evaluation of RVH in younger population¹². It is also suggested that several factors need to be considered when choosing an appropriate diagnostic test;

in the first place, the clinical index of suspicion, then the presumed etiology of RVH, the presence or absence of renal insufficiency, the risk of complications from conventional contrast angiography and the use of antihypertensive medications that affect the RAS. Taking all these factors into account, the captopril scintigraphy is considered to be the primary non-invasive test in patients with a moderate clinical suspicion of FMD (or suspected uncomplicated atheromatous disease) with a normal renal function as presented in our case¹³.

A number of studies, mainly referring to adult population, have shown different sensitivity and specificity of the captopril scintigraphy in the detection of renovascular disease¹⁴. The research results in the adult population as well as in the pediatric ones were quite inconsistent. The sensitivity and specificity of the captopril scintigraphy greatly depended on the selected group of subjects. In the group of subjects with the preserved renal function, the sensitivity and specificity were approximately 90%, while in the group of patients with the impaired renal function the tests showed lower specificity^{11, 14, 15}. In addition, some case studies point out the potential role of the captopril scintigraphy in the evaluation of the effects of percutaneous transluminal dilatation of renal artery stenosis in hypertension¹⁶. In the presented case, the captopril scintigraphy, performed immediately after the endovascular procedure, indicated significantly improved parenchymal indicators of the right kidney which corresponded to a complete normalization of the patient's blood pressure occurring several months after the scintigraphy. This may indicate not only the importance of the captopril scintigraphy in RVH screening but also its potential role in further monitoring of patients following endovascular procedures and its prognostic significance.

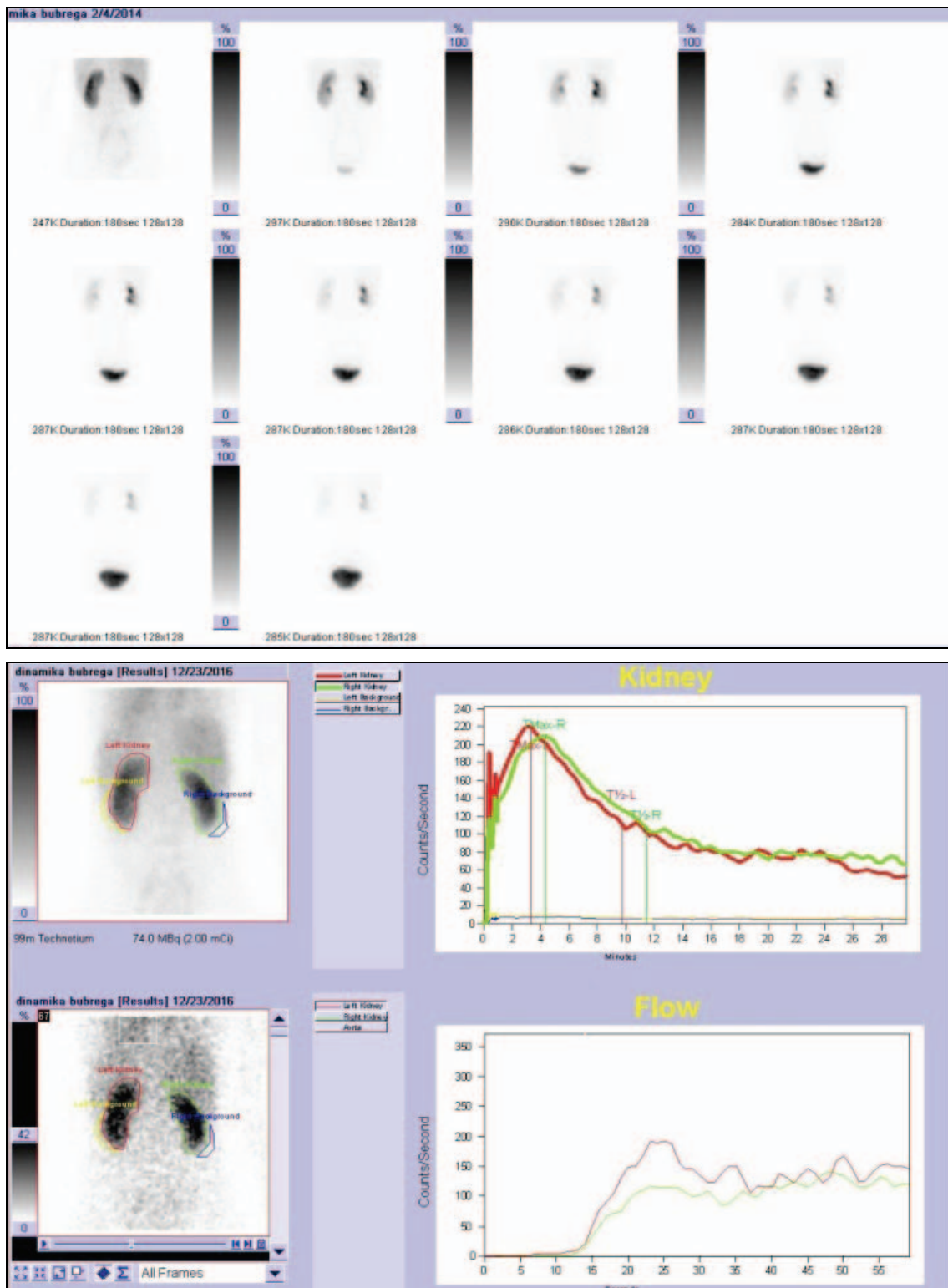


Fig. 4 – The captopril renal scintigraphy after the procedure – a significant improvement of the renogram curve of the right kidney. The time to maximum counts of the right kidney was 4.3 minutes and 20 min/peak min count ratio of the right kidney was 0.33.

Conclusion

It could be said that the captopril renal scintigraphy allows non-invasive functional testing in a selected group of

hypertensive children which can either confirm or rule out the existence of hemodynamically significant renal artery stenosis.

R E F E R E N C E S

1. *Falkner B.* Hypertension in children and adolescents: Epidemiology and natural history. *Pediatr Nephrol* 2010; 25(7): 1219–24.
2. *Radanović B, Cacić Z, Perković D, Smiljanić R, Corić SR, Ilaković K.* Endovascular therapy of renovascular hypertension in children: Single center analysis. *Eur J Pediatr Surg* 2009; 19(3): 135–40.
3. National High Blood Pressure Education Program Working Group on High Blood Pressure in Children and Adolescents. The fourth report on the diagnosis, evaluation, and treatment of high blood pressure in children and adolescents. *Pediatrics* 2004; 114 (2 Suppl 4th Report): 555–76.
4. *Gates GF.* Glomerular filtration rate: Estimation from fractional renal accumulation of ^{99m}Tc -DTPA (stannous). *AJR Am J Roentgenol* 1982; 138(3): 565–70.
5. *Reusz GS, Kis E, Cséprekál O, Szabó AJ, Kis E.* Captopril-enhanced renal scintigraphy in the diagnosis of pediatric hypertension. *Pediatr Nephrol* 2010; 25(2): 185–9.
6. *Estépa R, Gallego N, Orte L, Puras E, Aracil E, Ortuño J.* Renovascular hypertension in children. *Scand J Urol Nephrol* 2001; 35(5): 388–92.
7. *Humbert J, Roussey-Kesler G, Guerin P, LeFrançois T, Connault J, Chenouard A,* et al. Diagnostic and medical strategy for renovascular hypertension: report from a monocentric pediatric cohort. *Eur J Pediatr* 2015; 174(1): 23–32.
8. *Marks SD, Tullus K.* Update on imaging for suspected renovascular hypertension in children and adolescents. *Curr Hypertens Rep* 2012; 14(6): 591–5.
9. *Tullus K, Roebuck DJ, McLaren CA, Marks SD.* Imaging in the evaluation of renovascular disease. *Pediatr Nephrol* 2010; 25(6): 1049–56.
10. *Ajdinović B, Janković L, Peco-Antić A, Dugonjić S.* Renal scintigraphy in infants with antenatally diagnosed renal pelvis dilatation. *Vojnosanit Pregl* 2008; 65(4): 299–302.
11. *Taylor A, Blaufox M, Joseph V, Nally J, Dubovsky E, Fine E,* et al. Society of nuclear medicine procedure guideline for diagnosis of renovascular hypertension. *Soc Nuc Med* 2003; 20: 97–103.
12. *Johansson M, Jensen G, Aurell M, Friberg P, Herlitz H, Klingenshierna H,* et al. Evaluation of duplex ultrasound and captopril renography for detection of renovascular hypertension. *Kidney Int* 2000; 58(2): 774–82.
13. *Lagomarsino E, Orellana P, Muñoz J, Velásquez C, Cavagnaro F, Valdés F.* Captopril scintigraphy in the study of arterial hypertension in pediatrics. *Pediatr Nephrol* 2004; 19(1): 66–70.
14. *Abdulamea S, Anderson P, Biassoni L, Brennan E, McLaren CA, Marks SD,* et al. Pre- and postcaptopril renal scintigraphy as a screening test for renovascular hypertension in children. *Pediatr Nephrol* 2010; 25(2): 317–22.
15. *Bloch MJ, Basile J.* Diagnosis and Management of Renovascular Disease and Renovascular Hypertension. *J Clin Hypertens (Greenwich)* 2007; 9(5): 381–9.
16. *Anfelter P, Granerus G, Stenström H, Eriksson P, Nyström FH.* The effect of percutaneous dilatation of renal arterial stenosis on captopril renography in hypertension. *Blood Press* 2005; 14(6): 359–65.

Received on November 24, 2016.

Revised on December 25, 2016.

Accepted on January 09, 2017.

Online First January, 2017.