



Unrecognized urinoma caused by infiltrative bladder cancer

Neprepoznati urinom izazvan infiltrativnim karcinomom mokraćne bešike

Dragan Grbić*, Dimitrije P. Jeremić*[†], Saša Vojinović*[†], Ivan Levakov*[†],
Alexander B. Cantrell[‡], Goran Marušić*[†]

Clinical Center of Vojvodina, *Department of Urology, Novi Sad, Serbia;
University of Novi Sad, [†]Faculty of Medicine, Novi Sad, Serbia; University of California,
[‡]Department of Urology, Davis, United States

Abstract

Introduction. Urinoma develops after disruption of collecting system of urinary tract and urine leak in surrounding tissue. Most common causes of urinoma are blunt or penetrating trauma. Less common causes are iatrogenic injuries or urinary tract obstruction. In this article we presented a rare case of the urinoma caused by infiltrative bladder cancer. **Case report.** Acutely ill, a septic patient with ileus and profound azoemia was admitted to medical intensive care unit. Native computed tomography revealed moderate ileus, right kidney hydronephrosis, extensive retroperitoneal urinoma and vesical thickening with excluded infiltration of ureteral orifices. Computed tomography guided percutaneous drainage was done. Upon stabilization, patient underwent transurethral bladder tumor electroresection (histopathology report was: infiltrative transitional cell tumor of urinary bladder). Radical cystectomy was done. The patient's recovery was uneventful. **Conclusion.** Urinoma formed due to spontaneous rupture of collecting system based on ureteral obstruction caused by urinary bladder tumor is very rare clinical case scenario. In case of urinoma of unclear etiology invasive bladder cancer should be excluded.

Key words:

urinoma; diagnosis; tomography, x-ray computed; histological techniques; urinary bladder, neoplasms.

Apstrakt

Uvod. Urinom se javlja kao posledica disrupcije kolektorskog sistema urinarnog trakta i curenja urina u okolno tkivo. Najčešći uzroci razvoja urinoma su tupa ili penetrantna trauma. Ređi uzroci pojave urinoma su jatrogene lezije ili opstrukcija urinarnog trakta. Prikazan je redak klinički slučaj urinoma izazvanog infiltrativnim karcinomom mokraćne bešike. **Prikaz bolesnika.** Bolesnik u akutnom stanju, sa znacima sepse, ileusom i izraženom azotemijom, primljen je u jedinicu internističke intenzivne nege. Nativni kompjuterizovani tomografski pregled ukazao je na postojanje srednje izraženog ileusa, hidronefroze sa desne strane, ekstenzivnog retroperitonealnog urinoma i zadebljanja zida mokraćne bešike uz infiltraciju orificijuma uretera. Urađena je perkutana drenaža urinoma vođena kompjuterizovanom tomografijom. Posle poboljšanja opšteg stanja urađena je transuretralna elektroresekcija tumora mokraćne bešike (Patohistološki nalaz glasio je: infiltrativni karcinom prelaznog epitela mokraćne bešike). U daljem postupku lečenja urađena je radikalna cistektomija; postoperativni tok je protekao bez komplikacija. **Zaključak.** Razvoj urinoma usled spontane rupture kolektorskog sistema uzrokovane opstrukcijom uretera infiltrativnim tumorom mokraćne bešike je vrlo retka klinička prezentacija. U slučaju urinoma nejasne etiologije trebalo bi isključiti postojanje infiltrativnog tumora mokraćne bešike.

Ključne reči:

urinom; dijagnoza; tomografija, kompjuterizovana, rendgenska; histološke tehnike; mokraćna bešika, neoplazme.

Introduction

Urinoma develops after disruption of collecting system of urinary tract and urine leak in surrounding tissue. Most common causes of urinoma are blunt or penetrating trauma.

Posttraumatic urinomas are well-described complications associated with the nonoperative management of major blunt renal injuries¹. Less common causes are iatrogenic injuries of urinary tract obstruction. We presented a rare case of the urinoma caused by infiltrative bladder cancer.

Case report

Urology consulting was called for a patient with ileus and hydronephrosis who was admitted to medical intensive care unit. The patient was a 83-year-old male in acute distress, with clinical signs of moderate ileus (Figure 1).

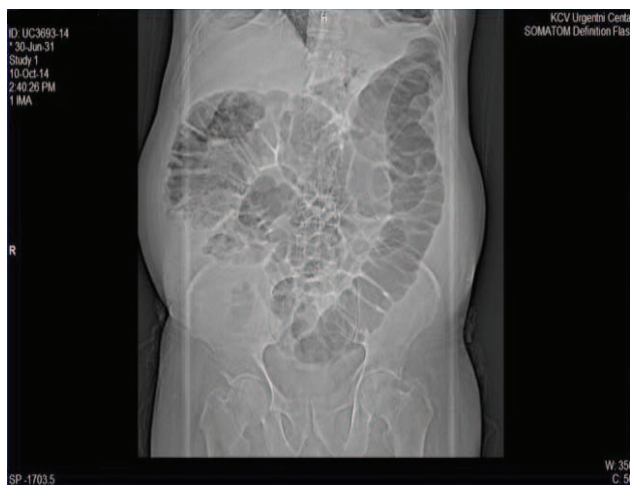

Fig. 1 – A native radiograph of the abdomen shows distended bowels – moderate degree of ileus.

Laboratory findings revealed severe azoemia [creatinine level of 800 $\mu\text{mol/L}$ [normal range (nr) (60–110 $\mu\text{mol/L}$)], moderate acidosis [pH of 7.2 (nr 7.35–7.45)], white blood cells (WBC) of 19×10^9 (nr $3.5\text{--}10.5 \times 10^9$), findings met criteria for sepsis. Computed tomography (CT) scan findings were consistent with hydronephrosis grade 2 on the right and minimal hydronephrosis on the left side – urine was leaking out through the tear in the left kidney pelvicalyceal (PC) system (Figure 2).

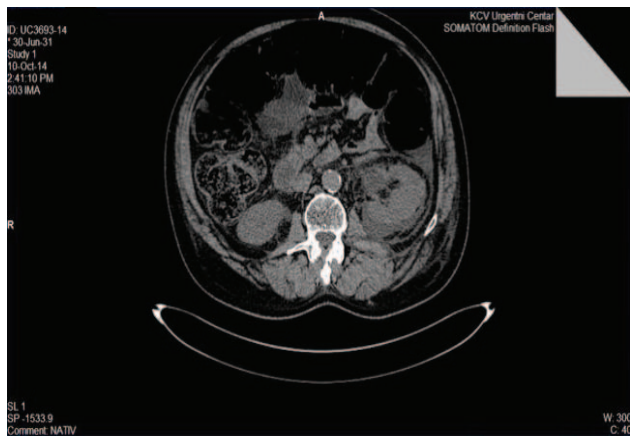

Fig. 2 – Computed tomography (CT) scan finding reveals hydronephrosis grade 2 on the right and minimal hydronephrosis on the left side.

There was obvious retroperitoneal urinoma – predominantly on the left side (Figure 2 and 3).

CT scan of the urinary bladder showed irregularly thickened wall at the trigonal part of the bladder, more prominent on the left side (Figure 4).

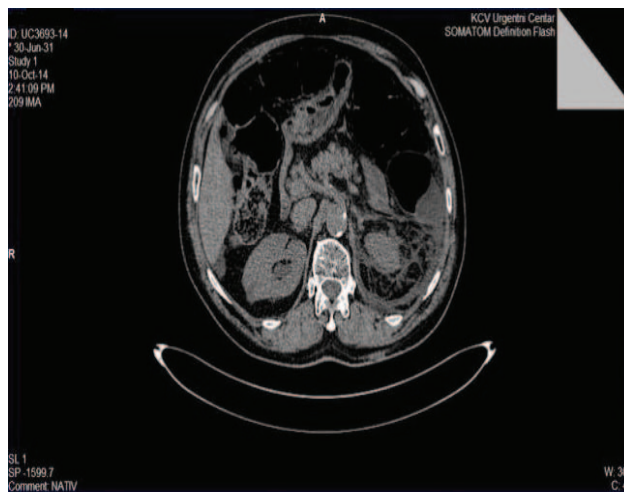


Fig. 3 – Computed tomography (CT) scan finding of retroperitoneal urinoma predominantly of the left side.

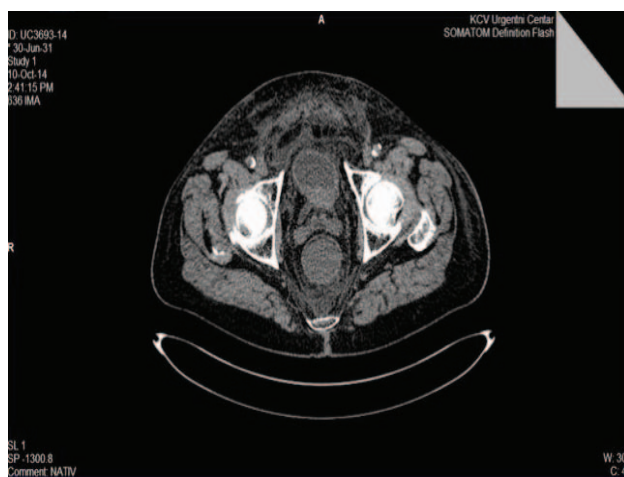

Fig. 4 – Computed tomography (CT) scan of the urinary bladder reveals irregularly thickened wall at the trigonal part of the bladder, more prominent of the left side.

Patient underwent urgent CT guided percutaneous drainage procedure, with drain placement in the left retroperitoneum. Drained fluid was tested and it was confirmed to be urine. Soon after the procedure, the patient felt much better, ileus resolved and laboratory findings slowly normalized. Patient was scheduled for transurethral electroresection (TUR) of suspected urinary bladder tumor. During the TUR procedure tumorous obstruction of both ureteral orifices were seen. Histopathology report confirmed infiltrative transitional cell cancer (TCC) of the urinary bladder. After TUR of bladder tumor, follow-up ultrasonography (US) was done and it showed hydronephrosis stage one on the right side (partially unblocked right ureteral orifice by previous TUR bladder tumor), no hydronephrosis of the left kidney and small amount of perirenal fluid on the left side. The patient was scheduled for radical cystectomy. During the surgery, no obvious tear of the left pylon or ureter were found, both ureters were stented with J-J stents and Bricker's urinary derivation was done. On postoperative day 3, output at previously installed percutaneous drainage dramatically decreased and therefore drain was removed. Postoperative recovery was otherwise unremarkable.

Discussion

By definition, urinoma is a mass of extravasated urine delineated by perirenal fascia within reactively formed fibrous capsule. Urinoma might also manifest as a free fluid². There are three factors necessary for urinoma (caused by urinary tract obstruction) to be developed: a tear in PC system, functional kidney and distal obstruction³.

Most often, urinoma is caused by a trauma, less common causes are distal ureteral obstruction by calculus, pelvic masses or iatrogenic injuries. The PC system injury and urinary leakage through the tear is not so rare, but in most of these cases urine leaks undergo spontaneous resolution and formed urinoma develops only in few instances⁴.

Usual clinical presentation of urinoma includes: mild to moderate flank fullness/pressure/pain, atypical abdominal pain, poor appetite, weakness, weight loss. It takes time for urinoma to develop. Urinoma presentation depends on causes, extent, urinoma localization and time window between time of injury of the PC system and time until diagnosis was established. Rarely, if not recognized or left untreated, urinoma may present as an ileus, peritonitis and abscesses and

sepsis. In our case delayed establishing of correct diagnosis was crucial for severe clinical presentation.

Method of choice for urinoma diagnosis is CT with radio contrast agents. In some cases, like in this one, where an use of contrast is contraindicated, native (non-contrast) CT should be performed. In addition, an image guided percutaneous needle aspiration drainage (which is both diagnostic and therapeutic) might be done⁵.

In most cases, small urinoma would reabsorb spontaneously, and drainage would not be necessary⁶. In some cases of large or persistent urinoma, or in a case of moderate to severe illness (fever, sepsis), first step should be CT or US guided drainage⁷. Further treatment depends on a cause of the urinary obstruction and should be aimed accordingly.

Conclusion

Urinoma formation due to collecting system rupture because of ureteral obstruction caused by urinary bladder tumor is very rare clinical case scenario. In case of urinoma of unclear etiology invasive bladder cancer should be excluded.

R E F E R E N C E S

1. *Philpott JM, Nance ML, Carr MC, Canning DA, Stafford PW.* Ureteral stenting in the management of urinoma after severe blunt renal trauma in children. *J Pediatr Surg* 2003; 38(7): 1096–8.
2. *Gayer G, Zissin R, Apter S, Garniek A, Ramon J, Kots E, et al.* Urinomas caused by ureteral injuries: CT appearance. *Abdom Imaging* 2002; 27(1): 88–92.
3. *Morano JU, Burkhalter JL.* Percutaneous catheter drainage of post-traumatic urinoma. *J Urol* 1985; 134(2): 319–21.
4. *Srinath N, Sood R, Rana KV, Madhusoodhanan P.* Urinoma following blunt renal trauma. *MJAFI* 2000; 56: 3446.
5. *Rizvi S, Ibne A, Siddiqui MA, Syed M.* A case report: urinoma as initial presenting sign of bladder malignancy. *Indian J Cancer* 2011; 48(4): 516–7.
6. *Lang EK, Glorioso L 3rd.* Management of urinomas by percutaneous drainage procedures. *Radiol Clin North Am* 1986; 24(4): 551–9.
7. *Titton RL, Gervais DA, Boland GW, Mueller PR.* Renal trauma: radiologic evaluation and percutaneous treatment of nonvascular injuries. *AJR Am J Roentgenol* 2002; 178(6): 1507–11.

Received on December 30, 2016.

Accepted on February 27, 2017.

Online First March, 2017.