



## Evaluation of odontometric methods in immature permanent teeth: research for a better practice

Evaluacija odontometrijskih metoda kod stalnih zuba nedovršenog razvoja: istraživanje u cilju bolje prakse

Kristina Vicko, Jelena Nikolić Ivošević, Bojan Petrović

University of Novi Sad, Faculty of Medicine, Novi Sad, Serbia

### Abstract

**Background/Aim.** Determination of correct working length is one of the keys to success in root canal treatment. It provides efficient canal cleaning and shaping, a three-dimensional hermetic obturation and an optimal healing process following root apex formation. The aim of this work was to evaluate and compare the accuracy and applicability of working lengths determined in permanent immature teeth *in vivo* using different clinical methods. **Methods.** The research was conducted at the Dental Clinic of Vojvodina in Novi Sad, the Department of Pediatric and Preventive Dentistry. A sample of 30 canals of young permanent teeth were selected for the research. Inclusion criteria were: a need for endodontic treatment, young permanent teeth, teeth with incomplete apex formation according to Demirijans stages F and G determined on radiography. Exclusion criteria: more than 3 years from eruption, pathological and iatrogenic resorption of the apex. The canal length was measured first on the initial radiograph used later as the parameter for comparison with various clinical methods. **Results.** The greatest average difference of measured working lengths was found by using electroodontometry and the paper point method afterwards. Regarding individual measurements, the most unprecise reading was with electroodontometry and tactile method up to 5 mm difference, and 4.6 mm was the maximal deviation for radiographic method. A deviation was defined by matching the measurements with a canal length measured on the initial radiograph. Our results showed that there was a difference between observed methods, although there was no statistical significance. **Conclusion.** The radiographic method and tactile method stand out as dominant methods for odontometry in permanent immature teeth, thanks to highly accurate readings, while the electroodontometry is considered the most unreliable method for determining working length in immature permanent teeth.

### Key words:

endodontics; root canal preparation; odontometry.

### Apstrakt

**Uvod/Cilj.** Određivanje tačnih radnih dužina je ključno u lečenju kanala korena zuba. Preciznim određivanjem radnih dužina korena se omogućuje efikasno čišćenje i oblikovanje, kao i trodimenzionalno hermetičko zatvaranje uz optimizaciju procesa lečenja. Cilj ove studije je evaluacija i upoređivanje primenivosti i tačnosti određenih radnih dužina kod stalnih zuba nezavršenog razvoja korena dobijenih *in vivo* različitim kliničkim metodama. **Metode.** Istraživanje je sprovedeno na Klinici za stomatologiju Vojvodine, na odeljenju Dečje i preventivne stomatologije. Uzorak je činilo 30 kanala mladih stalnih zuba. Kriterijumi za uključivanje u istraživanje bili su: potreba za endodontskim tretmanom, mladi stalni zubi sa nezavršenim razvojem korena, F i G stadijum, po Demirijanu određeno na radiogramu. Kriterijumi za isključivanje bili su: ako je prošlo više od tri godine nakon nicanja zuba, patološka ili jatrogena resorpcija vrha korena. Dužina kanala je najpre izmerena na inicijalnom radiogramu, a zatim je ova vrednost uzeta kao parametar za upoređivanje radnih dužina dobijenih različitim kliničkim metodama. **Rezultati.** Najveće prosečno odstupanje određenih radnih dužina dobijeno je elektroodontometrijskom metodom, zatim papirnim poenom. Najmanje precizno individualno merenje dobijeno je elektroodontometrijom i taktilnom metodom sa zabeleženim odstupanjem i do 5 mm, dok je maksimalna devijacija za radiografsku metodu bila 4.6 mm. Devijacija je određivana merenjem poklapanja sa dužinom određenom na inicijalnoj radiografiji. Rezultati pokazuju da postoje razlike u merenjima pomoću ispitivanih metoda, ali bez statistički značajnih razlika. **Zaključak.** Zahvaljujući vrlo preciznim merenjima, radiografska i taktilna metoda izdvajaju se kao dominantne metode za odontometriju kod mladih stalnih zuba, dok je elektroodontometrija najmanje pouzdana za određivanje radne dužine kod zuba sa nezavršenim rastom korena.

### Ključne reči:

endodoncija; zub, lečenje korenskog kanala; odontometrija.

## Introduction

Determination of correct working length is one of the keys to success in root canal treatment. It provides efficient canal cleaning and shaping, a three-dimensional hermetic obturation and an optimal healing process following root apex formation. In clinical practice the presence of a wide apex may provide challenges in endodontic treatment. A routine root canal procedure cannot be performed in these cases and the success of the treatment is unpredictable<sup>1</sup>.

Immature permanent teeth have open or wide apices at the time of their eruption as a physiologic phase during root development. Apical closure occurs approximately 3 years after eruption<sup>1</sup>. Open apices can also be present as a consequence of trauma, caries, or pathological resorption. They can also be iatrogenic as a result of overinstrumentation or root resection<sup>2</sup>. An open apex may develop in a previously mature apex owing to extensive resorption after orthodontic treatment or severe periapical inflammation<sup>1</sup>. An open apex and thin dentinal walls make the endodontic treatment difficult and there is a higher risk of post-treatment root fracture under occlusal or traumatic forces<sup>1,3,4</sup>. The walls of the apex may diverge, converge, or be parallel depending on the stage of root development<sup>5</sup>.

The aim of determining the working length is to enable the root canal to be prepared as close to the apical constriction as possible. There is a general agreement that the apical constriction is appropriate for termination of canal preparation and obturation<sup>6</sup>. The location of the apical constriction normally varies between 0.5 and 2 mm from the radiographic apex in fully developed permanent teeth<sup>6</sup>. However, in cases of wide apices, the apical constriction is not formed and, consequently, this guideline cannot be followed. A lack of research in this field and no defined protocol nor golden standard test for working length determination in immature teeth has led to variable methods and rendered the question of working length determination a controversy.

Long-term medication with calcium hydroxide is widely used to induce the apexification of immature teeth with pulpal necrosis before a definitive obturation<sup>7</sup>. The success rate of apexification with calcium hydroxide is about 95%. With Mineral Trioxide Aggregate (MTA), the success rate of apexification is comparable or higher<sup>3</sup>. The advantages of MTA are fewer visits and faster development of a calcific barrier, even though the long-term success rate of the MTA apexification is yet to be determined<sup>8</sup>. Calcium hydroxide and also MTA should be placed in the soft tissue region at the apex in order to promote apexification<sup>3</sup>. In contrast to using calcium hydroxide or MTA, relevant literature highlights the benefits and a better long-term prognosis with regenerative endodontic therapy, even though there are no standardized protocols for its application as well.

Given the lack of clinical research in the field of odontology in immature permanent teeth and precise clinical protocols for determining working length, the study aimed to evaluate and compare the accuracy and applicability of working lengths determined in permanent immature teeth *in vivo* using different clinical methods: electroodontometry, radiographic method, tactile method and paper point method.

## Methods

The research was conducted at the Dental Clinic of Vojvodina in Novi Sad, the Department of Pediatric and Preventive Dentistry. The study protocol was approved by the local Ethics Committee, and patients/parents gave their informed consent. The selection of patients was made by two experienced clinicians, one pedodontist and one general dentist with 15 years of experience. The endodontic procedures and measurements were performed after the dentists were calibrated, with a kappa intra-examiner concordance index score of 0.84. Inclusion criteria were: a need for endodontic treatment, young permanent teeth and teeth with incomplete apex formation according to Demirijian's stages F and G determined with radiography<sup>5</sup>. Exclusion criteria were: more than 3 years from eruption, and pathological and iatrogenic resorption of the apex. All patients had endodontic treatments throughout multiple visits. The treatments were done with calcium hydroxide or MTA. For the purpose of this research paper, the clinical protocol remained unchanged and additional diagnostic procedures were not included.

The clinical examination began with thorough history of subjective symptoms, following the diagnostic tests and the radiographic examination. The diagnosis of pulpal status was irreversible pulpitis or pulpal necrosis. The canal length was measured firstly on the initial radiograph, which was later used as the parameter for comparison between various clinical methods. The retroalveolar radiograph was made with a digital X ray (SironaHeliodentVario, Sirona Dental Systems GmbH) using bisecting angle method. The length was measured on the X ray between a reference point on a cusp or incisal edge 1 mm shorter than the visible edge of the tooth on the radiograph. The estimated canal length was measured with a mm ruler and 2x magnification with two clicks (1 click at the reference point and the second click 1 mm shorter than the apex).

Local anaesthesia was used if pain was expected regarding the diagnosis, or if a patient requested it and patients/parental consent was gained. If not approved, anaesthesia was not given. After isolating the tooth with a rubber dam, an access cavity was prepared to allow removal of all inflamed or necrotic pulp tissue. Next, a nerve file was inserted. At this point some of the pulp tissue was removed by rotating and withdrawing a nerve file. Irrigation was done with NaOCl 0.5%.

The tactile measurements were completed firstly, using a suitable file. Local anaesthesia was not used when these measurements were performed. The tip of the file was placed against a dentinal wall in the root canal and displaced apically until it reached the edge of dentinal wall at the apex and provoked sensitivity or haemorrhage. The length was adjusted and measured. This procedure was repeated to circumferentially probe all dentinal walls; if a shorter length was determined, the ring on the file was readjusted, thus representing the tactile working length.

Electronic measurements were done after that, by using the Raypex 5 electronic apex locator (VDWGmbH, Munich, Germany), the fourth generation apex locator. After a copi-

ous irrigation with NaOCl 0.5%, a file was chosen; it was four degrees smaller than the file which was earlier defined as suitable for the tactile method. After slightly drying the canals, the chosen file was introduced until a constant beep (around 5 seconds) was evoked. This was repeated and the correct length noted.

The next step was to record radiographic measurements with a file placed in the canal, in length which corresponds to the length on the initial radiograph. The steps of radiographic imaging were standardized. If the obtained results differed more than 3 mm, the X ray was repeated. If the difference was less than 3 mm, the length of the instrument was measured again and the working length was corrected adding or subtracting for adequate length. The measuring was done with a mm ruler and x2 magnification with 2 clicks (1 click at the reference point and the second click at the file tip).

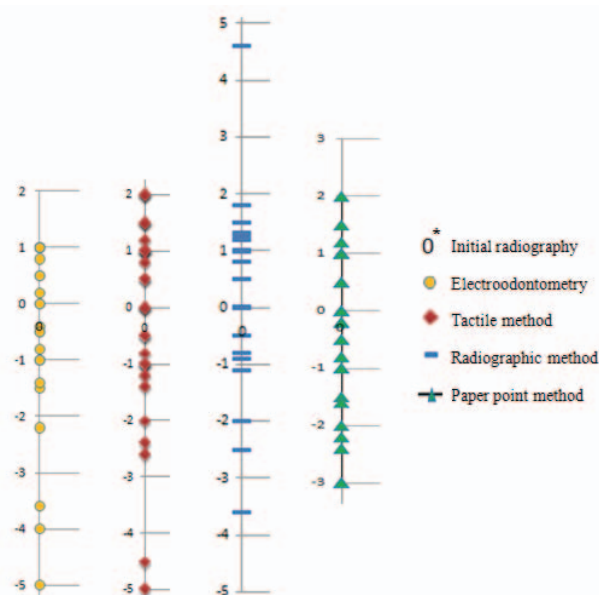
Odontometry using paper points was done next. An initial paper point was placed 0.5 mm short of the indicated length determined by the tactile method done earlier. The point advanced apically until some fluid was noticed on the tip. Another paper point was used just short of this point. The working length was then determined as the maximum length that a paper point could be placed into the canal and remained dry after brief contact<sup>9</sup>.

The working length measured by apex locator, tactile method, paper point and radiographic method was compared to the canal length measured on the initial radiograph. Data was collected and statistical analysis was carried out with the use of Statistical Package for the Social Sciences (SPSS) Windows version 12.0. Statistical analysis included standard descriptive statistical analysis; the differences between investigated groups were compared using one-way analysis of variance (ANOVA) test [absolute values and standard deviation (SD) in mm were compared for all determined working lengths] with the level of significance set at  $p < 0.05$ . Average differences, maximal and minimal deviations and SD were determined for each individual measurement method. The deviations from the average values (both positive and negative) were calculated for all measurements as well as the correlation coefficient between employed clinical methods.

## Results

The sample consisted of 21 patients (9 females, 12 males), mean age  $8.3 \pm 1.7$  years. The sample of 22 immature permanent teeth including 13 upper central incisors, 2 upper lateral incisors, 2 upper premolars and 2 upper and 3

lower molars with a total of 30 canals were selected for the research. The results of this study are shown in Table 1. The greatest average difference of measured working lengths was found using electroodontometry, then the paper point method. Regarding individual measurements, the most unprecise reading was with electroodontometry and tactile method with 5 mm difference while 4.6 mm was the maximal deviation for radiographic method. The minimal deviation meant that the single measurements corresponded to the parameter measured on the initial radiograph. Our results showed that there was a difference among observed methods, although there was no statistical significance. In two cases, there was a problem in defining the correct canal length with paper point method, when repeatedly a dry canal could not be obtained while some uncertainties were present in one case when using the tactile method, where the mean value of four measurements was applied. In Figure 1, each method and all measurements of working lengths are shown. The correlation between the deviations in all clinical methods was 0.79.



**Fig. 1 – Differences between working lengths measured (mm) on the initial radiograph and by various clinical odontometric methods.**

\*lengths measured on the initial radiograph were taken as zero in order to display differences among various methods. Note: the negative values were shorter and positive values were longer working lengths obtained.

**Table 1**

**Statistical analysis of measured working lengths using different clinical methods**

Parameters	Electroodontometry	Tactile method	Radiographic method	Paper point method
Average difference	0.597	0.213	0.16	0.373
Maximal deviation	5	5	4.6	3
Minimal deviation	0	0	0	0
Standard deviation	1.689	1.793	1.5	1.434

$p = 0.322$

## Discussion

To the best of the authors' knowledge, no prospective clinical studies of working length determination in immature teeth have been published. By its design, this was prevalently *in vivo* study aimed to clarify the dilemma of odontometry in teeth with the incomplete root formation.

There are many experimental *in vitro* studies about working length determination in immature teeth. The time taken to process an *in vitro* research and its conclusions versus an *in vivo*, clinical research is significantly shorter. The results from *in vitro* studies should be interpreted with caution; as in clinical situations, there is often a lack of ideal circumstances and controlled environment for precise measurement<sup>10-12</sup>. Nevertheless, for a comprehensive understanding of this matter, knowledge of odontometry about permanent immature teeth should be validated through both *in vitro* and *in vivo* studies.

Apex locators have been shown to be highly accurate in locating the apical foramen and constriction in fully developed teeth<sup>8</sup>. Their performance can be influenced by several factors: the diameter of apical foramen, the size of file in use, electrolytes, pulp tissue and blood. The third and later generation apex locators were constructed to overcome some of these limitations<sup>1</sup>. Even though, various authors determined that as the diameter of the apical foramen increased, the measured lengths with apex locators became shorter than the actual canal length<sup>13</sup>. A laboratory study showed that file size was irrelevant for apical size of 60, whereas, better fitting files were recommended to use for apical sizes over 70<sup>1</sup>. It has been found that apex locators had an accuracy rate of only 62.7% in cases of teeth with wide apices, often showing shorter working length as incorrect measurements<sup>9</sup>. Our results mainly correspond to these findings meaning that electroodontometry can be surprisingly unprecise in immature teeth with a tendency to record shorter working lengths. Various studies indicated that a difference of  $\pm 0.5$  mm in electroodontometry measurements was clinically acceptable<sup>13-15</sup>. In our research, the average difference of working lengths determined with electroodontometry was within this range, even though it varied mostly in the initial working length in comparison to other methods.

In the teeth with open apices, the radiographic interpretation of canal length can be difficult due to a different apical structure and the missing periodontal ligament space at the root apex<sup>16</sup>. Although the radiography is the main method of determining working length during endodontic treatment of immature permanent teeth, variations are frequent among the imaging techniques used<sup>1</sup>. With a correct imaging technique magnification and image distortion can be minimized, but a certain amount of these phenomena is unavoidable<sup>17</sup>. The radiographic methods may lead to overinstrumentation due to showing a longer canal length<sup>14</sup>. The main reason is the fact that the apical foramen is frequently (92%) located short of the apex and the length of the measuring file appears radiographically shorter than its actual length<sup>15</sup>. In our study measurements with the radiographic method were the most precise. This can be due to the fact

that the parameter for defining the deviations was the canal length measured on the initial radiograph. In the literature there are statements that the success rate of the endodontic treatment using the Raypex5 electronic apex locator and radiographic measurement are quite similar<sup>1</sup>. The benefits of electroodontometry, in addition to eliminating radiation exposure, is that apex locators are superior in reducing overestimation during odontometry compared to radiographic canal length determination<sup>18</sup>. In our study, we concluded that, when comparing single measurements, the radiographic odontometric method was more precise, but there was no statistically significant difference comparing all the results gained from applying electroodontometry and radiographic methods.

The accuracy of the Tactile Method, measured in the teeth with open apices was found to be high (over 97%)<sup>13, 14, 16</sup>. ElAyouti et al.<sup>19</sup> described a tactile method using a size 25 file with a bent tip. Their results showed that this method may offer an alternative to other methods, as 97.7% of measurements were in the range of  $\pm 0.5$  mm to actual canal length. Our results are in accordance with these findings since the average difference for tactile method was 0.213 mm, also within the clinically acceptable range. During measuring by the tactile method, there were some uncertainties in one case with 5 mm deviations observed in multiple working length determination attempts.

While using paper point method, there were some issues with defining the correct length in two first molars, when repeatedly a dry canal could not be obtained. The control of moisture is difficult because the contact area to the periapical tissues is wide, especially in cases with periapical inflammation when an excess moisture is inevitable<sup>19, 20</sup>. Also, to determine precise measurements, the periapical tissue must be located at the same level of the apical foramen, a requirement which may not be present in immature permanent teeth since periapical tissues can extend in the canal up to 3 mm<sup>21</sup>.

Our results are in line with earlier published statements by ElAyouti et al.<sup>19</sup> and Gurtu et al.<sup>22</sup> who noted difficulties in the usage of tactile and paper point method in curved and narrow canals, contrary to expected success in anterior teeth with wide canals with obtained moisture control.

The study limitations include the possible risk of error in reproducibility during measuring and relatively small sample sizes. The study also reflects a single center experience. In two cases, there was a problem in defining the correct length with paper point method, when repeatedly a dry canal could not be obtained. With the tactile method there were some uncertainties in one case when the examiner decided to use the mean value of four measurements.

## Conclusion

Thanks to highly accurate readings, the radiographic method and tactile method stand out as dominant methods for odontometry in permanent immature teeth. On the other hand, electroodontometry is the most unreliable method for determining working length in immature permanent teeth.

Defining a precise protocol and golden standard method for working length determination in permanent immature teeth remains necessary to be an objective in the field of endodontics.

### Conflict of interest

All authors declare that they have no conflict of interest.

### R E F E R E N C E S

1. Kim YJ, Chandler NP. Determination of working length for teeth with wide or immature apices: a review. *Int Endod J* 2013; 46(6): 483–91.
2. Gutmann JL, Heaton JF. Management of the open (immature) apex. 2. Non-vital teeth. *Int Endod J* 1981; 14(3): 173–8.
3. Bogen G, Kuttler S. Mineral trioxide aggregate obturation: a review and case series. *J Endod* 2009; 35(6): 777–90.
4. Flanagan TA. What can cause the pulps of immature, permanent teeth with open apices to become necrotic and what treatment options are available for these teeth. *Aust Endod J* 2014; 40(3): 95–100.
5. Mohammed RB, Koganti R, Kalyan SV, Tirucoveluri S, Singh JR, Srinivasulu E. Digital radiographic evaluation of mandibular third molar for age estimation in young adults and adolescents of South Indian population using modified Demirjian's method. *J Forensic Dent Sci* 2014; 6(3): 191–6.
6. *European Society of Endodontology*. Quality guidelines for endodontic treatment: consensus report of the European Society of Endodontology. *Int Endod J* 2006; 39(12): 921–30.
7. Rosenberg DB. The paper point technique. Part I. *Dent Today* 2003; 22(2): 80–6.
8. Frank AL. Therapy for the divergent pulpless tooth by continued apical formation. *J Am Dent Assoc* 1966; 72(1): 87–93.
9. Webber RT. Apexogenesis versus apexification. *Dent Clin North Am* 1984; 28(4): 669–97.
10. Beltrame AP, Triches TC, Sartori N, Bolan M. Electronic determination of root canal working length in primary molar teeth: An in vivo and ex vivo study. *Int End J* 2011; 4(5): 402–6.
11. Goldberg F, De Silvio AC, Manfré S, Nastri N. In vitro measurement accuracy of an electronic apex locator in teeth with simulated apical root resorption. *J Endod* 2002; 28(6): 461–3.
12. Williams CB, Joyce AP, Roberts S. A comparison between in vivo radiographic working length determination and measurement after extraction. *J Endod* 2006; 32(7): 624–7.
13. Herrera M, Ábalos C, Lucena C, Jiménez-Planas A, Llamas R. Critical diameter of apical foramen and of file size using the Root ZX apex locator: an in vitro study. *J Endod* 2011; 37(9): 1306–9.
14. Fouad AF, Rivera EM, Krell KV. Accuracy of the Endex with variations in canal irrigants and foramen size. *J Endod* 1993; 19(2): 63–7.
15. Briseño BM, Sonnabend E. The influence of different root canal instruments on root canal preparation: An in vitro study. *Int Endod J* 1991; 24(1): 15–23.
16. Haffner C, Folwaczny M, Galler K, Hickel R. Accuracy of electronic apex locators in comparison to actual length-an in vivo study. *J Dent* 2005; 33(8): 619–25.
17. Mentis A, Gencoglu N. Canal length evaluation of curved canals by direct digital or conventional radiography. *Oral Surg Oral Med Oral Pathol Oral Radiol Endod* 2002; 93(1): 88–91.
18. Ravanshad S, Adl A, Anvar J. Effect of working length measurement by electronic apex locator or radiography on the adequacy of final working length: a randomized clinical trial. *J Endod* 2010; 36(11): 1753–6.
19. ELAyouti A, Dima E, Löst C. A tactile method for canal length determination in teeth with open apices. *Int Endod J* 2009; 42(12): 1090–5.
20. Economides N, Vouzara T. Non-surgical endodontic retreatment after unsuccessful apicectomy: a case report. *Balk J Stom* 2011; 15(3): 166–70.
21. Baggett FJ, Mackie IC, Worthington HV. An investigation into the measurement of the working length of immature incisor teeth requiring endodontic treatment in children. *Br Dent J* 1996; 181(3): 96–8.
22. Gurtu A, Singhal A, Singhal P. A tactile method for canal length determination in teeth with open apices – A case report. *Ann Essences Dent* 2010; 2: 36.

Received on May 26, 2016.  
Revised on March 30, 2017.  
Accepted on April 19, 2017.  
Online First April, 2017.