



Surgical treatment of unstable pelvic ring fractures

Hirurško liječenje nestabilnih preloma karličnog prstena

Miroslav Kezunović, Nikola Bulatović

The Clinical Centre of Montenegro, The Orthopaedics and Traumatology Clinic,
Podgorica, Montenegro

Abstract

Background/Aim. Pelvic ring fractures are complex injuries and are often associated with internal organs injuries. These injuries require rapid and accurate diagnosis and in some cases one or more surgical interventions. The aim of this retrospective study is to describe the indications and outcomes of surgical treatment of pelvic ring injuries with the emphasis on anatomical reconstruction and stable osteosynthesis as a prerequisite for early mobilization and more favorable functional outcomes. **Methods.** In the period from 2006 to 2012, fifty-five patients with pelvic ring injuries with or without acetabular fractures were analyzed. The average age of all patients was 36 years. Forty-one patients were treated with operational open reduction and internal fixation (ORIF) while nine of them were treated nonoperatively (bed rest, skeletal traction and external fixation). **Results.** All operated patients were treated within 3–24 days with ORIF, stable osteosynthesis and early mobilization which resulted in avascular necrosis (AVN) of the femoral head in two cases. AVN of the femoral head was noted in five cases in combined and isolated pelvic ring injuries and ace-

tabulum which were treated with skeletal traction. Neurological deficit was recorded in three patients treated with conservative methods while two patients underwent ORIF. Deep vein thrombosis (DVT) was noted in two patients and pulmonary thromboembolism appeared in one patient 23 days after surgical intervention. Two infections occurred around Steinman pins in the patients who had the definitive treatment performed with external fixator. In one patient treated with ORIF a superficial infection occurred and was treated with antibiotics. The functional results were evaluated based on Merle d'Aubigné score. The results of the radiography treatment were analyzed according to Slatis. **Conclusion.** Strict application of rational criteria and surgical technique with stable internal fixation with early mobilization provide significantly better outcomes of these injuries in relation to non surgical treatment or treatment with definitive external fixation.

Key words:

pelvic bones; fractures, bone; orthopedic procedures; open fracture reduction; fracture fixation, internal; treatment outcome.

Apstrakt

Uvod/Cilj. Povrede karličnog prstena su kompleksne povrede udružena sa povredama unutrašnjih organa. Ove povrede zahtevaju brzu i tačnu dijagnozu i u nekim slučajevima jednu ili više hirurških intervencija. Cilj ove retrospektivne studije je bio da opiše indikacije i ishode hirurškog lečenja povreda karličnog prstena sa akcentom na anatomsku rekonstrukciju i stabilnu osteosintezu, kao preduslov za ranu mobilizaciju i povoljniji funkcionalni rezultat. **Metode.** U periodu od 2006. do 2012. god. analizirano je 55 bolesnika sa povredom karličnog prstena, sa i bez preloma acetabuluma. Prosečna starost svih bolesnika je bila 36 godina. Operativno otvorenom repozicijom i internom fiksacijom (ORIF) lečen je 41 bolesnik, a devetoro njih neoperativno (lečeni su mirovanjem, skeletnom ekstenzijom i spoljašnjom fiksacijom). **Rezultati.** Svi operisani bolesnici tretirani su unutar 3–24 dana ORIF stabilnom osteosintezom i ranom mobilizacijom. Kao posledica, pojavila se avaskularna nekroza (AVN) glave femura kod dva slučaja. AVN glave femura je zabeležena kod pet slučajeva kod kombinovanih i izolovanih

povreda karličnog prstena i acetabuluma, koji su lečeni skeletnom ekstenzijom. Neurološki deficit je zabeležen kod trojice lečenih konzervativnim metodama i kod dvojice operisanih ORIF. Duboka venska tromboza (DVT) je konstatovana kod dva bolesnika, a plućna tromboembolija kod jednog operisanog i to 23 dana posle hirurške intervencije. Desile su se dve infekcije oko Stajmanovih klinova kod bolesnika kod kojih je definitivno lečenje provedeno spoljašnjim fiksatorom. Kod jednog bolesnika tretiranog ORIF nađena je površna infekcija koja je sanirana primenom antibiotika. Funkcionalni rezultati su procenjeni na osnovu M. d'Aubigné skora. Rezultati lečenja putem radiografije analizirani su prema Slatis-u. **Zaključak.** Striktna primena racionalnih kriterijuma i hirurška tehnika sa stabilnim internim fiksacijama uz ranu mobilizaciju daju značajno bolje ishode ovih povreda u odnosu na neoperativni tretman ili tretman sa definitivnom spoljašnjom fiksacijom.

Ključne reči:

karlica; prelomi; ortopedске procedure; prelom, otvorena redukcija; osteosinteza; lečenje, ishod.

Introduction

Pelvic ring fractures are complex injuries and are often associated with internal organs injuries. These fractures are among the most severe injuries which often happen in traffic accidents, sometimes with significant consequences. These injuries require rapid and accurate diagnosis, and in some cases, one or more surgical interventions¹.

Good estimate of general life threat and classification of injury is very important in these patients as well as the acute treatment of injuries. At this stage of treatment, the first priority is to save the life of a patient by applying appropriate reanimation procedures with a temporary stabilization of the pelvic ring (external fixator, C - ram, etc.), and appropriate surgical interventions of other system, if necessary (head, abdomen, chest, etc.). After stabilizing the general and hemodynamic status, it is necessary to pass on to the definitive treatment of these injuries in the period up to 4 weeks².

Stability of all articulations is given through three factors: bone stability, stability of capsular ligaments soft tissue and dynamic stability of muscle structures (minimum contribution). The sacrum is the "cornerstone" for bone stability of the pelvic ring when the ligament apparatus is intact. Sacroiliac ligaments are the most important for the stability of the posterior segment. There are various opinions (classifications) on defining zones of pelvic ring instability. Some are focused on the instability and some on the cause of injury: classifications by Tile³ and March et al.⁴.

The decision on operative treatment is made only after quality and adequate diagnosis. When admitting a patient to the emergency services, it is important to determine the mechanism and severity of the injury. That primarily refers to the assessment of pelvic ring deformity, length and rotation of extremities as well as the assessment of soft tissue condition when physical examination of the patient is performed. Radiographic examination includes standard imaging of the pelvic ring (antero-posterior – AP profile, inlet and outlet), and in the case when acetabulum injury is suspected, two semi-angled images are also made⁵.

For preoperative planning, timing is very important. Due to associated injuries, a good coordination of more specialties is necessary: the extremities, neurosurgical, abdominal, urological, etc. For stabilization of hemodynamic instability a C-clamp/ external fixator, sheet or pelvic binder must be applied, and must be removed for definitive treatment, usually within a period of 5-7 days after the injury^{5,6}.

The choice of surgical approach also includes an adequate selection of the position of a patient, a repositioning technique and fixation of fractures in accordance with all biomechanics osteosynthesis principles. For reduction and fixation of fractures of the pelvic ring, the specific instrumentation and the appropriate set of osteosynthetic material is necessary (osteosynthetic material adequate for the injury – reconstruction plates and titanium material are used; they provide firmness to external and internal forces of rotation and movement)⁷.

Pelvic ring injuries with dislocations and signs of instability are treated surgically since conservative treatment

gives poor results in these cases. Surgery can be performed openly, percutaneously or can be combined. Open techniques provide better visualization and easier fixation, but their disadvantages are the risk of infection, blood loss, possible surgical soft tissue injuries and large scars⁷. Percutaneous techniques are increasingly applied due to less surgical traumatization of tissue and blood loss, having as a disadvantage the increasing radiation exposure to both patients and health care personnel. The combination of the open and percutaneous approach is a good choice, especially if a stabilization of the pelvic ring in more places is needed^{8,9}.

In preventing complications, it is most important to recognize soft tissue injuries, to avoid incisions through compromised tissue, to use the appropriate osteosynthetic material and be careful when placing implants^{10,11}.

In the end, the outcome of the treatment will be significantly more favorable.

Methods

In the period from 2006 to 2012, fifty-five patients with pelvic ring injuries with or without acetabular fractures were analyzed. The average age of all patients was 36 years. Forty-one (74.5%) patients were operationally treated and fourteen (25.5%) non-operatively. Forty-one patients who underwent open reduction and internal fixation (ORIF), stable osteosynthesis and early mobilization constituted the first group (Figure 1), and fourteen patients who were only treated with bed rest, skeletal traction and external fixation are classified in the second group (Group II).

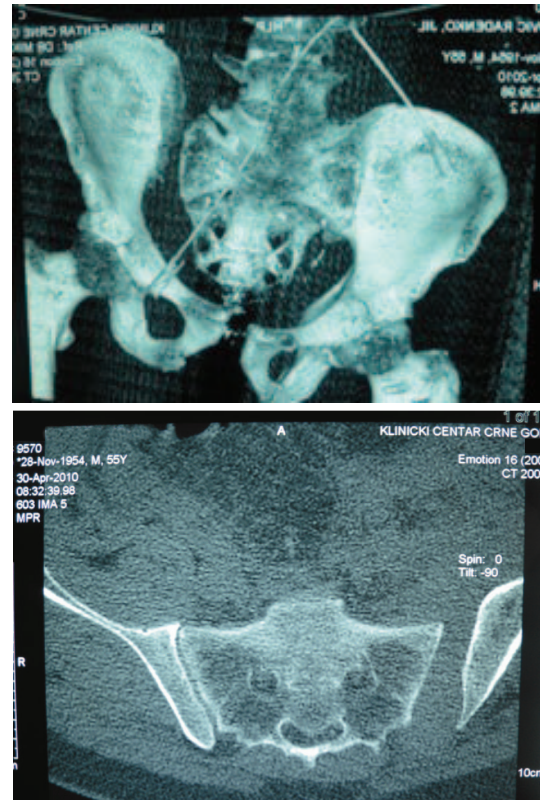


Fig.1 – Vertical and rotational instability of the pelvic ring [computed tomography (CT)].

In all cases computed tomography 3D (CT 3D) reconstruction was performed which significantly helped us in defining the instability of the pelvic ring. The indication for surgery was given based on the degree of pelvic ring instability determined according to Marvin Tile classification³. According to this classification, the representation of patients was: type A – 26%, type B – 44% and type C – 30%.

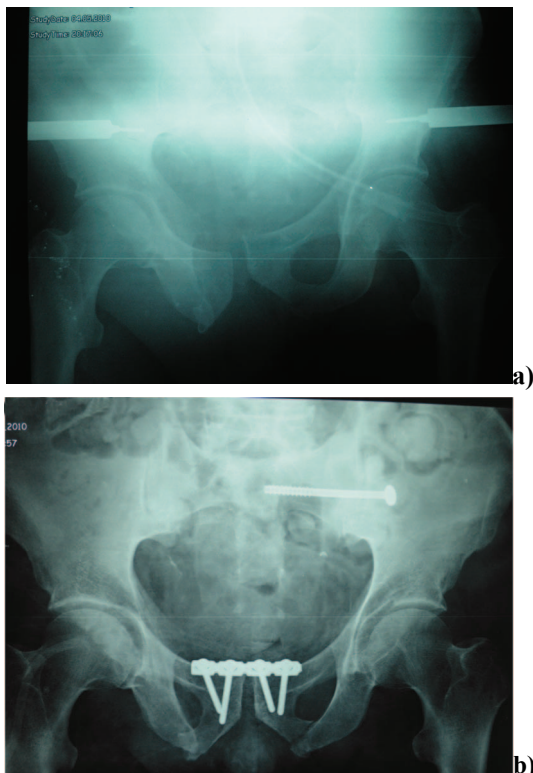
Regarding a form of associated injuries with other systems, it could be seen that there were 19.2% head injuries, 14.8 % abdominal injuries, 11.4% thorax injuries, 5.6% spine injuries and 49.0% extremity injuries.

Preoperatively, all patients were given a low dose anti-coagulant therapy to prevent blood clotting. Sometimes, magnetic resonance venography (MRV) was performed in order to determine the existence of a possible blood clot in the veins of the injured pelvic ring or extremities.

Stabilization of the pelvic ring with a C-clamp or external fixator must be performed before eventual laparotomy, or other surgical procedures of any region. After stabilizing the hemodynamic status in the period of up to 4 weeks, we made a decision on definitive open reduction and internal fixation of the injured pelvic ring.

There were 27 (49.1%) isolated pelvic ring injuries. According to the gender structure, 19 were in men and 8 in women of the average age of 35 years. The average number of operations per patient was 1.3.

According to the definitive treatment method, ORIF with one or more plates was performed in twenty-one patients, stabilization was definitely completed by external fixator in four patients and two patients were definitely treated with skeletal traction (Case 1: Figures 1 and 2).



**Fig. 2 – a) Primarily fixed C – clamp;
b) Definitive osteosynthesis.**

There were 28 (50.9%) combined pelvic ring and acetabulum injuries of which 19 in the male patients, 9 in the female patients of the average age of 37 years. The average number of surgeries in this group of patients was 1.8. According to the method of treatment, three patients were definitely treated with skeletal traction, only two with bed rest, while twenty-three patients were definitely internally stabilized with one or more plates and free screws. The patients who were not treated surgically had comorbidities or refused surgery (Case 2: Figures 3 and 4), (Case 3: Figures 5–8).

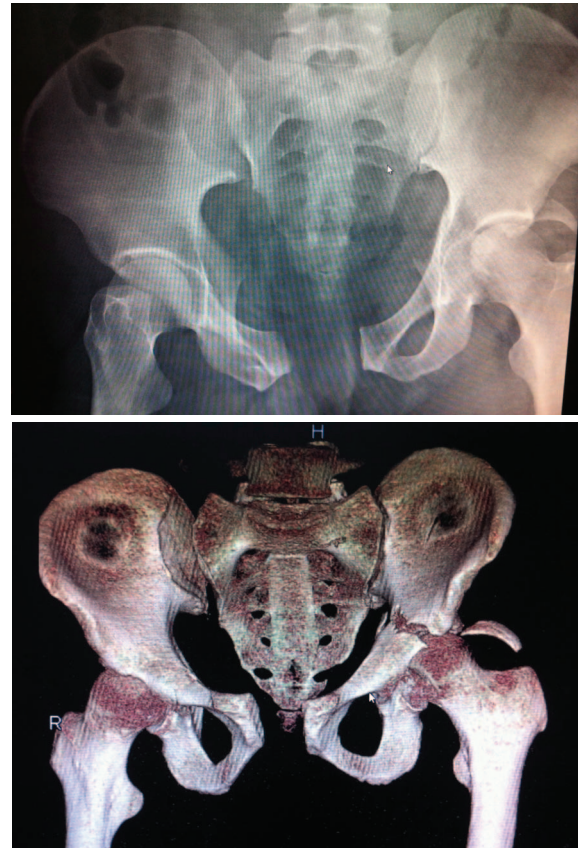

Fig. 3 – The instability of the anterior and posterior segment of the pelvic ring associated with an acetabular fracture and the lower part of the femoral head (Pipkin fracture – Type IV).

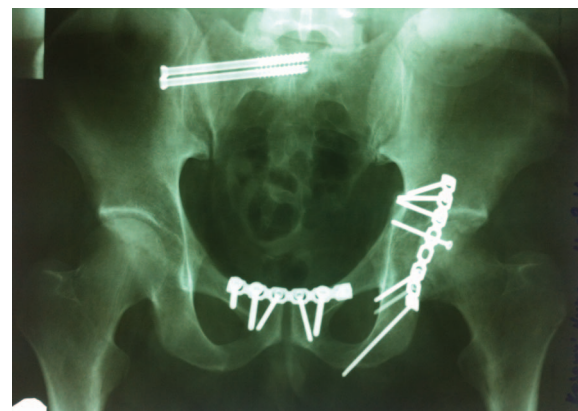

Fig. 4 – Definitive osteosynthesis open reduction and internal fixation (ORIF) combined with the percutaneous technique.

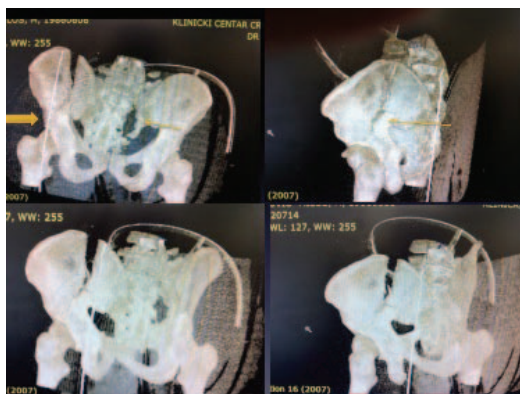


Fig. 5 – Posterior pelvic ring segment instability [computed tomography-3D (CT – 3D)].

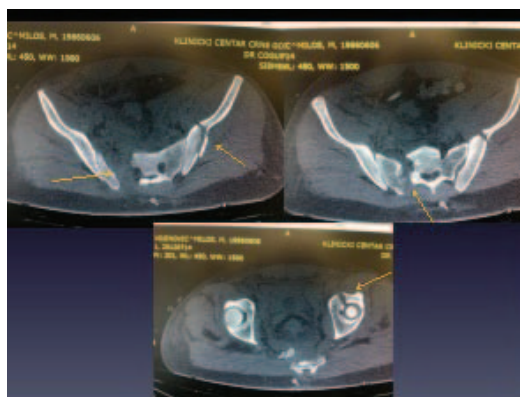


Fig. 6 – Denis II sacral fracture with acetabular fracture.

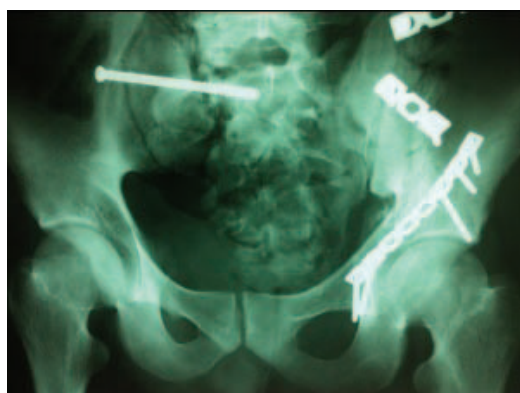


Fig. 7 – Definitive osteosynthesis.



Fig. 8 – Functional outcomes 8 months after injury.

Postoperatively, all patients received anticoagulation therapy for the period of up to 6 weeks. In the beginning, pain management includes analgesics. In severe cases, the patient-controlled analgesia (PCA) pump was used, and therefore there was no danger that the patient receives too much pain medication. The average period of postoperative follow-up in the patients was 16 months (range of 6–36 months). For more objective assessment of functional clinical results of our patients, the following scoring was used: pain, daily life activities, a range of motion, power (PARP) – according to the Modified Merle d'Aubigné and Postel scoring system. The outcomes of treating the patients by using radiography were analyzed according to Slatis^{6,12}.

Results

Analyzing the outcomes of isolated pelvic ring fractures, treatment in those who, in our series of patients, besides the unstable pelvic fracture had an acetabular injury, the assessment of the clinical functional status was made by using the Merle d'Aubigne and Postel scoring system (Table 1)⁶. According to the methods of medical treatment, the patients were divided into two groups: the first group comprised the patients treated by stable osteosynthesis with 1, 2 or more reconstruction plates and free screws. The second group comprised the patients treated by bed rest, skeletal traction or external fixator (Tables 2 and 3).

Table 1

Numerical strength of isolated pelvic ring injuries and combined acetabulum and pelvic ring injuries

Injuries	Group I (n)	Group II (n)	Total (n)
Pelvis	18	9	27
Pelvis/acetabulum	23	5	28
Total	41	14	55

Group I – patients treated by stable osteosynthesis
Group II – patients treated by bed rest, skeletal fraction or external fixator.

Table 2

Analysis of the functional status outcomes

Outcomes	Group I (%)	Group II (%)
Pain	19	55
Activities	87	40
ROM	63	33
Power	94	61

ROM – range of motion.
For explanation see under Table 1.

Our results in the Table 3 showed that the radiological outcomes were better in the group I ($p < 0.03$). The analysis of radiological outcomes was evaluated based on distance between fragments at an anterior or a posterior pelvic ring segment as follows: excellent from 0–5 mm, good 6–8 mm, satisfactory 9–11 mm and and poor from 12 mm and above.

Table 3

Group*	Radiologic outcomes			
	Excellent	Good	Satisfactory	Poor
Group I, n (%)	20 (48.8)	12 (29.3)	6 (14.6)	3 (7.7)
Group II, n (%)	2 (13.3)	1 (6.7)	3 (20.0)	9 (60.0)

$p < 0.03$

The outcome of radiography treatment – Slatiš.
For explanation see under Table 1.

Three patients who were treated with external fixation or traction had a neurological deficit at the L4, L5 and S1 levels, while three of them recovered during the follow-up within the average period of 16–36 months. The sensory deficit in levels S1-S2 roots was isolated in two patients treated by stable osteosynthesis, one at multifragmental sacral fracture, type Denis zone 2 fracture. Two patients treated conventionally and with traction and only one treated with stable osteosynthesis had a deep vein thrombosis (DVT). Poor consolidation and re-dislocation of the fracture was observed in five cases where the treatment included external fixation or skeletal traction. Avascular necrosis (AVN) of the femoral head occurred in two patients with unstable osteosynthesis treated with screw and traction, and in only one treated with stable fixation. Sexual dysfunction was not recorded in any group of the patients. Three patients from the Group I and one from the Group II had ectopic ossification (Table 4).

Table 4

Numerical strength of complications in both groups

Complications	*Group I (n)	*Group II (n)
DVT	1	2
Pulmonar thromboemboli	1	0
AVN	2	5
Infection	0	2
Ectopic ossification	1	3
Sexual dysfunction	0	0
Neurological deficit	2	3
Nonunion	0	1
Malposition	0	3
Symphyseal fusion	1	0
Pelvic obliquity	0	2

AVN – avascular necrosis; DVT – deep vein thrombosis.
***For explanation see under Table 1.**

Discussion

Unstable pelvis and acetabulum fractures require definitive stabilization since the injury itself and the type of surgical procedure directly affect the subsequent quality of patients' lives. Two-thirds of these injuries were from road traffic accidents, primarily involving motorcyclists and pedestrians, and only then involving the other traffic participants. One third was caused by a fall from height, most often to construction workers^{2, 13}.

Pelvic fractures are the result of the force of high intensity and if associated with the injuries of extremities, head, abdomen, chest - within polytrauma, mortality rate is very

high (60% –80%), and if the injury is isolated, the rate amounts to 10%^{13, 14}. Four deaths in emergency patients with unstable pelvic ring fractures in polytrauma were not considered in this paper since no temporary pelvic stabilization was performed during reanimation measures (sheet, pelvic binder, external fixation, C-clamp). The reason for such the outcome was the absence, at that time, of the appropriate protocol of unstable pelvic ring fractures treatment in polytraumatized patients in our Clinical Centre.

Unstable pelvic ring and acetabulum injuries treated with the conventional closed methods often result in significant disability, and mortality rate drastically increase^{8, 9, 13}. We opted for a non-operative treatment in patients with multiple life-threatening chronic diseases and in patients where their families or they themselves did not agree to suggested surgical interventions, i.e., did not receive the consent of an anesthesiologist and internist for performing stable internal fixations in an adequate period of time, up to 4 weeks after the injury.

Some authors state that the use of external fixation significantly reduces venous and bone bleeding, maintains a good stability of the pelvic and that other interventions are not necessary^{6, 14, 15}. Biomechanical studies showed that external fixators could not provide sufficient stability to allow for mobilization without the risk of redislocation of fragments. The use of external fixators or C-clamps in unstable pelvic injuries is applied in urgent cases, and helps in stabilizing the hemodynamic status¹⁶. External fixators can be used temporarily in unstable injuries as part of emergency treatment to allow the patient to be placed in the upright position to improve ventilation. In our material, external fixator or C-clamp was applied in fourteen cases, and the same were removed within a period of 5–7 days and a definitive internal osteosynthesis was done. Patients with such stable osteosynthesis were earlier mobilized without a greater risk for redislocation of fragments. Early mobilization of patients is affected by whether there are other skeletal injuries which required surgical intervention, i.e., disburdening of that extremity^{17, 18}.

In sacroiliac joint (SI) injuries, stabilization technique with percutaneous techniques, cannulated screws, is biomechanically superior to other methods of internal fixation. Due to minimal surgical aggression, the bleeding is slight, functional results are satisfactory in 96% of cases while radiological results are satisfactory in 86% of cases^{4, 19}. In our patients, 14 percutaneous stabilizations of the SI joint with one or two screws were done. The fixation with 2 cannulated screws gave firmer stabilization without radiological signs of instability, which was noted in single screw fixation. This percutaneous technique is demanding and requires a good knowledge of anatomy and its radiological correlation in order to avoid complications.

A large number of authors agree that functional outcomes depend on whether the patients had associated injuries (open fractures, bladder and urethra injuries, craniovertebral and thoracic injuries ...) accompanied by deep vein thrombosis, pulmonary embolization and neurological outbursts of lumbosacral plexus^{17, 20}.

Prevalence of primary neurological injuries in this study is 26%. Four patients in the Group I with a combined motor and sensory neurological deficit at the L4, L5, S1 levels nerve fully recovered at the time of follow-up within 16–36 months. In all patients, a stable internal fixation was done, which a large number of authors cited as a reason for more favorable prognosis. Three patients from the Group II were monitored within a period of 36 months and did not have a satisfactory neurological recovery^{21–23}.

The results of this study (Group I) match with other studies which state a stable fixation of the anterior and/or posterior segment (Type-C) of pelvic ring injury with subsequent reduction of morbidity and mortality^{5, 24}. The patients from this study had a rapid improvement in their general condition during their stay and after discharge from the hos-

pital. They were earlier mobilized without a greater risk of redislocation of fragments, despite other skeletal injuries. Functional and radiological results were significantly worse in the Group II.

Conclusion

In pelvic ring injuries, isolated ones and those associated with injuries of other systems, the most important thing is the stabilization of vital parameters followed by a firm internal fixation. All this significantly reduces mortality. Just because of this fact, they represent a challenge for a small number of surgeons, for adequate treatment and guidance of these patients. Strict application of rational criteria and surgical techniques with stable internal fixation with early mobilization provide significantly better outcomes of these injuries than those which were non-operatively treated. Our analysis and the studies on a larger number of patients by other authors show that the rehabilitation period is shorter and that psychological and functional outcomes are significantly more favorable.

R E F E R E N C E S

- Gänsslen A, Pobleman T, Paul C, Lobenboffer P, Tscherne H. Epidemiology of pelvic ring injuries. *Injury* 1996; 27 Suppl 1: S-A13–20.
- Matta JM. Indications for anterior fixation of pelvic fractures. *Clin Orthop Relat Res* 1996; (329): 88–96.
- Tile M. Acute Pelvic Fractures: I. Causation and Classification. *J Am Acad Orthop Surg* 1996; 4(3): 143–51.
- Marsh JL, Slongo TF, Agel J, Broderick JS, Creevey W, DeCoster TA, et al. Fracture and dislocation classification compendium - 2007: Orthopaedic Trauma Association classification, database and outcomes committee. *J Orthop Trauma* 2007; 21(10 Suppl): S1–133.
- Van den Bosch EW, Van der Kleyn R, Hogervorst M, Van Vugt AB. Functional outcome of internal fixation for pelvic ring fractures. *J Trauma* 1999; 47(2): 365–71.
- Øvre S, Sandvik L, Madsen JE, Røise O. Comparison of distribution, agreement and correlation between the original and modified Merle d'Aubigné-Postel Score and the Harris Hip Score after acetabular fracture treatment: moderate agreement, high ceiling effect and excellent correlation in 450 patients. *Acta Orthop* 2005; 76(6): 796–802.
- Kabak S, Halici M, Tunel M, Ansarogullari L, Baktir A, Basturk M. Functional outcome of open reduction and internal fixation for completely unstable pelvic ring fractures (type C): a report of 40 cases. *J Orthop Trauma* 2003; 17(8): 555–62.
- Carroll EA, Huber FG, Goldman AT, Virkus WW, Pagenkopf E, Lorich DG, et al. Treatment of acetabular fractures in an older population. *J Orthop Trauma* 2010; 24(10): 637–44.
- Mardanpour K, Rabbar M. The outcome of surgically treated traumatic unstable pelvic fractures by open reduction and internal fixation. *J Inj Violence Res* 2013; 5(2): 77–83.
- Øvre S, Sandvik L, Madsen JE, Røise O. Modification of the Harris Hip Score in acetabular fracture treatment. *Injury* 2007; 38(3): 344–9.
- Moed BR, WillsonCarr SE, Watson JT. Results of operative treatment of fractures of the posterior wall of the acetabulum. *J Bone Joint Surg Am* 2002; 84-A(5): 752–8.
- Miller AN, Prasarn ML, Lorich DG, Helfet DL. The radiological evaluation of acetabular fractures in the elderly. *J Bone Joint Surg Br* 2010; 92(4): 560–4.
- Seral Garcia B, Seral Inigo D, Polanca M, Doblare M. Estudio tridimensional con elementos finitos de la fijación externa e interna en las fracturas de pelvis. *Ortop Traumatol* 1998; 43(4): 305–13.
- Ben-Menachem Y, Coldwell DM, Young JW, Burgess AR. Hemorrhage associated with pelvic fractures: causes, diagnosis, and emergent management. *AJR Am J Roentgenol* 1991; 157(5): 1005–14.
- Giannoudis PV, Grotz MR, Papakostidis C, Dinopoulos H. Operative treatment of displaced fractures of the acetabulum. A meta-analysis. *J Bone Joint Surg Br* 2005; 87(1): 2–9.
- Grubor P, Milicevic S, Biscovic M., Tanjga R. Selection of treatment method for pelvic ring fractures. *Med Arch* 2011; 65(5): 278–82.
- Tile M. Fractures of the pelvis and acetabulum. Baltimore: Williams & Wilkins; 1984.
- Matta JM, Tornetta P 3rd. Internal fixation of unstable pelvic ring injuries. *Clin Orthop Relat Res* 1996; (329): 129–40.
- Lindabl J, Hirvensalo E. Outcome of operatively treated type-C injuries of the pelvic ring. *Acta Orthop* 2005; 76(5): 667–78.
- Borrelli J Jr, Goldfarb C, Ricci W, Wagner JM, Engsborg JR. Functional outcome after isolated acetabular fractures. *J Orthop Trauma* 2002; 16(2): 73–81.
- Lindabl J, Hirvensalo E, Böstman O, Santavirta S. Failure of reduction with an external fixator in the management of injuries of the pelvic ring. Long-term evaluation of 110 patients. *J Bone Joint Surg Br* 1999; 81(6): 955–62.
- Matta JM, Saucedo T. Internal fixation of pelvic ring fractures. *Clin Orthop Relat Res* 1989; (242): 83–97.
- Helfet DL, Koval KJ, Hissa EA, Patterson S, DiPasquale T, Sanders R. Intraoperative somatosensory evoked potential monitoring during acute pelvic fracture surgery. *J Orthop Trauma* 1995; 9(1): 28–34.
- Webb LX, Gristina AG, Wilson JR, Rhyne AL, Meredith JH, Hansen ST Jr. Two-hole plate fixation for traumatic symphysis pubis diastasis. *J Trauma* 1988; 28(6): 813–7.

Received on April 1, 2017.
Accepted on April 24, 2017.
Online First April, 2017.