



The prevalence of peg-shaped and missing lateral incisors with maxillary impacted canines

Učestalost hipodoncije i atipičnih lateralnih sekutića udruženih sa impaktiranim maksilarnim očnjacima

Sanja Simić*, Jasna Pavlović*, Predrag V. Nikolić†, Amila Vujačić*,
 Vladanka Vukićević*, Radovan Jovanović‡

University of Priština, Faculty of Medicine, Kosovska Mitrovica, *Department of Orthodontics, ‡Department of Restorative and Endodontics, Kosovska Mitrovica, Serbia; University of Belgrade, Faculty of Dentistry, †Department of Orthodontics, Belgrade, Serbia

Abstract

Background/Aim. Many authors find that impacted maxillary canines is associated with missing and peg-shaped lateral incisor. The aim of this study was to examine the prevalence of peg-shaped and missing lateral incisor in subjects with impacted maxillary canines, and compare the size of maxillary lateral incisor on the side with palatally impacted canines and on the opposite side of the jaw where there is no impaction. **Methods.** The study included 64 patients with 80 impacted maxillary canines (23 males and 41 females, mean age 16.3). For each maxillary unerupted canine, precisely correct localization and classification into groups was done. We analyzed the morphology of the lateral incisor (normal, atypical) and frequency of missing of lateral maxillary incisors with canine impaction. Then, from the mentioned examinees sample with the maxillary canine teeth, a subgroup was formed. The criteria for selection were those with unilateral palatally impacted canines (33 subjects, 22 females and 11 males, mean age 17.8 years). The linear vari-

ables of the maxillary lateral incisor were measured by using digital measurements tools. The *t*-test was used to test the differences between the groups. Results. Normal morphology of the lateral incisors was found in 72% of the subjects with the impacted canines, 11.2% of the subjects had the peg-shaped lateral incisors, 6% had a bilateral and 4% had unilateral deficiency of lateral incisors. In the subgroup of the patients with unilateral palatal impaction, the middle value of the length of the lateral incisors was 1.9 mm shorter and the middle value of the width of the lateral incisors was smaller by 0.9 mm when comparing to the control group. **Conclusion.** The frequency of the deficiency of lateral incisors was statistically significantly higher in the group with palatal canine impaction. The maxillary lateral incisors on the side with palatally impacted canines were smaller than those on the side where there was no impaction.

Key words:
 cuspid; tooth, impacted; incisor; cone-beam computed tomography.

Apstrakt

Uvod/Cilj. Mnogi autori pronalazili su da su atipični lateralni sekutići, kao i njihov nedostatak, udruženi sa impaktacijama maksilarnih očnjaka. Cilj ovog rada bio je da se ispita učestalost atipičnih lateralnih sekutića i njihov nedostatak kod pacijenata sa impaktiranim maksilarnim očnjacima kao i da se uporede veličine maksilarnih lateralnih sekutića na strani gde postoji palatinalno impaktiran očnjak i na suprotnoj strani vilice, gde ne postoji impaktacija. Dužina i širina lateralnih sekutića merene su na trodimenzionalnim snimcima. **Metode.** Istraživanjem je bilo obuhvaćeno 64 ispitanika (23 muškog pola i 41 ženskog pola, prosečne starosti 16,3 godine) sa 80 impaktiranih maksilarnih očnjaka. Za svaki impaktirani očnjak precizno je određena njegova loka-

lizacija (bukalan, palatinalan ili sredina alveole) pomoću trodimenzionalnog snimka maksile na osnovu čega su podeljeni u grupe po mestu impakcije. Analizirana je morfologija lateralnih sekutića (normalni, atipični) i učestalost nedostatka lateralnih sekutića u grupi sa bukalnim i palatinalnim impaktacijama, a zatim je iz te grupe ispitanika izdvojena podgrupa. Kriterijum za odabir bile su unilateralne palatinalne impakcije očnjaka (33 ispitanika, 22 ženskog pola i 11 muškog pola, prosečne starosti 17,8 godina). *T*-test je korišćen za testiranje razlika između grupa. **Rezultati.** Ukupno 72% ispitanika sa impaktiranim očnjacima imalo je lateralne sekutiće normalne morfologije, 11,2% konične lateralne sekutiće, 6% ispitanika imalo je bilateralni nedostatak lateralnih sekutića i 4% unilateralni nedostatak lateralnog sekutića. U podgrupi ispitanika sa unilateralnim palatinalnim

impakcijama srednja vrednost dužine lateralnih sekutića bila je za 0,9 mm kraća, u poređenju sa kontrolnom grupom. **Zaključak.** Učestalost nedostatka lateranih sekutića bila je statistički značajno veća u grupi ispitanika sa palatinalnim impakcijama očnjaka nego u grupi sa bukalnim impakcijama očnjaka. Lateralni sekutići na strani palatinalno impaktiranih

očnjaka bili su manji od onih na strani na kojoj nije bilo impakcije.

Ključne reči:
očnjaci; zub, impakcija; sekutići; tomografija, kompjuterizovana, konusna.

Introduction

The impaction of maxillary canines is associated with lateral incisor anomalies and the other orthodontics malocclusions, some of which can be a cause or consequence for canine impaction.

Broadbent¹ stated that the most common reason given for palatal displacement of the permanent maxillary canine was the fact that it had a long and tortuous eruption path, beginning close to the floor of orbit. It was considered that, compared with other permanent teeth, this tooth had much further to travel before it erupted into the mouth and, therefore, it had a great chance of "losing its way". This has been standard teaching for many decades. Hitchin² considered that crowding of the dentition was the reason for this condition, although he offered no evidence to support his contention. In a series of other studies Jacoby³, Becker⁴, Becker et al.⁵ and Brin et al.⁶ pointed out that the likelihood of palatal displacement was much reduced where crowding was present. They showed it to be a far more prevalent occurrence when there was excessive space in dental arch.

Miller⁷ and Bass⁸ recorded a high prevalence of congenitally anomalies of maxillary lateral incisors associated with the palatally impacted maxillary canines. The canines initially had a strong mesial developmental path, which altered early on with the canine being guided downwards, apparently along the distal aspect of the lateral incisor root. They concluded that, in the absence of this guiding influence, the canine continued its mesial and palatal path. The tooth then became impacted in palatal area, posterior to the central incisors, and failed to erupt in its due time, if at all. Miller⁷ assumed that since a peg-shaped or otherwise abnormally small lateral incisor developed a root of more or less normal length, such a tooth would provide the required guidance for normal eruption of its adjacent canine. Therefore, he rationalized that these anomalous teeth could not be an aetiological factor in canine impaction.

A series of clinical studies that followed indicated a statistically significant number of normal, small and peg-shaped lateral incisors associated with impacted maxillary canines compared with the general population. In the general population, 93% of all lateral incisors have normal morphology, compared with only 52% of the subjects with impacted canines. The deficiency of lateral incisor was found in 1.8% of general population, compared with 5.5% in cases of impacted maxillary canines, which occur three times more often⁹. These results clearly support Bass's⁸ and Miller's⁷ theory that lateral incisor manage in normal eruption of the permanent canines. Without this guidance, normal eruption of permanent canines is compromised even five times.

It was reported that, in Israel population, the prevalence values of small lateral incisors were 4%, peg-shaped 1.8% and missing lateral incisor 1.3%. In one study, 42.6% of palatally displaced canines were found to be associated with lateral incisor anomalies, 25.3% of palatally displaced canines were adjacent to small lateral incisor, 13.3% had peg-shaped lateral incisor and 4% of the subjects had missing lateral incisor¹⁰.

A meta-analysis showed that the prevalence values of congenital absence of maxillary lateral incisors were 1.55% for males and 1.78% for females and there was no statistically significant difference between the sexes¹¹.

Becker and Chaushu¹² found that approximately a half of their subjects with palatally displaced canines had delayed dental development. Chaushu et al.¹³ subsequently stated that there might be two distinct palatally displaced canines subgroups among the male subjects but not among the female subjects. Nevertheless, Oliver¹⁴ found that both sexes with palatally displaced canines had delayed dental development, with a familial trend of delayed dental development among their siblings.

The latest study¹⁵ was to investigate the prevalence of peg-shaped maxillary lateral incisors and the incidence of associated dental anomalies in children. Among children with peg-shaped lateral incisors, the frequencies of associated dental anomalies were as follows: 31.8% of congenitally missing teeth, 19.7%, of dens *invaginatus*, 12.1% of palatally displaced canines, 7.6% of supernumerary teeth and 7.6% of transposition.

It has been reported that the mesiodistal width of the crown of the lateral incisors was smaller in a palatally displaced canines sample¹⁶. Palatally displaced canines were also showed to be associated with short lateral incisor roots, thus, it was suggested that there was a link between lateral incisor crown size and root length^{17,18}.

The aim of this study was to analyze morphology of maxillary lateral incisors and examine the prevalence of peg-shaped and missing of maxillary lateral incisors which were associated with maxillary impacted canines as well as to compare the size of maxillary lateral incisors between the group of lateral incisors with palatally displaced canines and the control group (on the contralateral side of jaw where there is no canine impaction).

Methods

This study included 64 examinees with 80 impacted maxillary canines (23 males and 41 females, mean age 16.3 years). Each patient underwent clinical examination, intraoral and extraoral photographs and the cone beam computed tomography (CBCT) image of maxilla were done.

For each maxillary unerupted canine, precisely correct localization was determined by impaction (buccal, palatal or midalveolar) and thus divided the subjects into groups. We analyzed the morphology of the lateral incisor (normal, atypical) and frequency of missing of lateral maxillary incisors in subjects in the group with the buccal impaction and the group with palatal impaction canines.

Then, a subgroup was formed from the mentioned examinees sample with the maxillary displaced canines. The criteria for selection included those with unilateral palatally impacted canines (33 examinees, 22 female and 11 male, mean age 17.8 years). The subjects with buccally or midalveolarly impacted canines, transposed canines and premolars, transposed canines and lateral incisors and severely resorbed maxillary lateral incisors were excluded. Thirty palatally impacted canines fulfilled the inclusion criteria and were available.

We measured the length and the width of the lateral incisors on the side where palatally impacted canines were and compared with lateral incisors on the contralateral side, where there was no impaction of canines. In this study, the width and the length of the lateral incisor was measured using three-dimensional CBCT images.

The cone-beam volumetric tomography DICOM files were imported into the *OnDemand* software (Cybermed. Inc version 2011) and the volumetric images (voxel size 0.2 mm, field of volume 75*100 mm) were reoriented with the long axis of lateral incisor vertical and then reconstructed into images of sagittal slice through the maxillary lateral incisors. The linear variables of the maxillary lateral incisors were measured by using digital measurement tools. The length of lateral incisors was measured on the sagittal slice image. The width of crowns were measured on the axial slice image across the equator of the lateral incisor crowns.

The data primarily obtained were analyzed with descriptive methods and methods for testing statistical hypotheses. From descriptive methods, measures of central tendency (median), measures of variability [standard deviation (SD), variation interval] and the relative numbers (structure indicators) were used. For testing hypotheses, the methods used were the χ^2 test, Student's *t*-test, Fisher's test.

Results

In this study, a total of 64 patients with CBCT images were enrolled and 80 impacted maxillary canines were diagnosed and analyzed individually. The mean age of the patients was 16.3 years (SD \pm 4.3 years, range: 12–33 years). Of 64 examinees in research, 41 (64.1%) were females which was significantly more important than the representation of 23 (35.9%) male examinees. Of 80 impacted maxillary canines, 19 (23.75%) were buccally impacted, 3 (3.75%) in the middle of alveolus and 58 (72.5%) palatally impacted canines.

The side and the frequency of impacted maxillary canines on the each side are presented in Table 1.

There were 48 subjects with unilaterally impacted maxillary canines. The female subjects prevailed – 32 (50%) in

comparison to the male subjects – 16 (25%), which was statistically significant difference ($\chi^2 = 8.46$; $p < 0.01$) (Figure 1).

Table 1
Descriptive data regarding morphology and location of impacted canines in 64 patients

Variable	n (%)
Canines (n = 80)	
unilateral	48 (75)
bilateral	16 (25)
Age (year of patients), mean \pm SD (range)	16.3 \pm 4.3 (12–33)
Gender	
male	23 (35.9)
female	41 (64.1)
Canine type	
right	39 (48.8)
left	41 (51.2)
Canine localization sagittal	
labial	19 (24)
palatal	57 (72)
midalveolar	3 (4)

All values are given as n (%) of canines or patients, except for age [mean \pm standard deviation (SD) (range)].

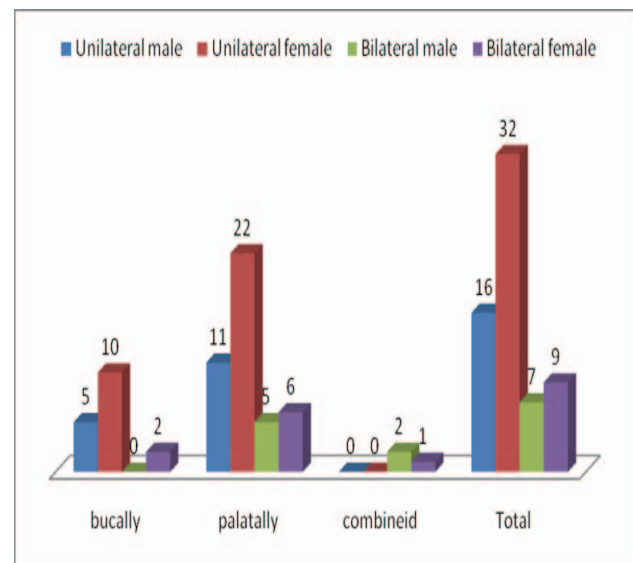


Fig. 1 – Distribution of unilateral and bilateral impacted maxillary canines according to the gender of subjects.

There was no statistically significant difference between the buccal and palatal impaction groups with missing lateral incisors (Fisher's exact probability test, $p = 0.498$). The missing of lateral incisors was present in 13 (16.3%) examinees only within the group of palatal impactions of maxillary canines. Atypical lateral incisors which were present within both groups, in the case with palatally impacted canines (7.5%) and with buccally impacted canines (3.7%). There was no statistically significant differences between gender regarding frequency of missing lateral incisors (the Fisher's exact probability test, $p = 0.757$) (Table 2).

Table 2
Distribution of missing and peg-shaped lateral maxillary incisors with impacted maxillary canines

Variable	Number (%)	<i>p</i> *
Morphology of lateral incisors		
missing	13 (16.3)	
normal	58 (72.5)	
peg shaped	9 (11.2)	
Missing lateral incisors by gender		
male	4 (13.3)	0.757*
female	9 (18)	
Missing lateral incisors by impacted canine side		
buccally impacted canine	0 (0)	0.498*
palatally impacted canine	13 (16.3)	
Peg-shaped lateral incisors		
with bucal impacted canine	3 (3.7)	0.638*
with palatally impacted canine	6 (7.5)	

*Fisher's exact probability test.

There was an interesting information in the study of the morphology of lateral incisors in the subjects with maxillary canine impaction. The results concerning our examinees with impacted maxillary canines were: 72% of all lateral maxillary incisors had normal morphology, 11.2% were peg-shaped, 4% of subjects had bilaterally missing lateral incisors and 6% had unilaterally missing lateral incisors (Figure 2).

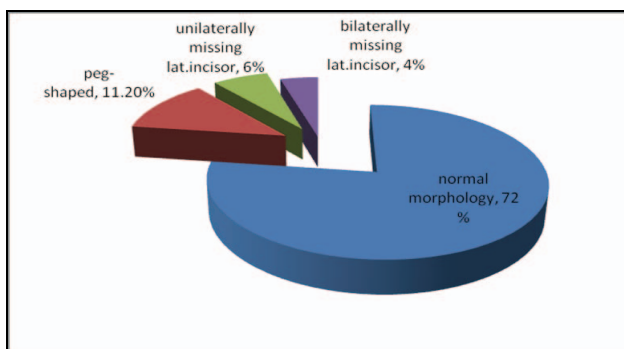


Fig. 2 – Morphology of lateral incisors with impacted maxillary canines.

In Table 3, the length of the lateral incisors and the width of lateral incisors in the subgroup with impacted canines and that with no canine impaction. The average value

of the width of the tested lateral incisors was 5.9 ± 0.6 mm while the control lateral incisors was 6.1 ± 0.5 mm, which was a statistically significant difference (Student's *t*-test, $t = 2.353$; $p = 0.022$).

The average value of the length of the tested lateral incisor was 19.7 ± 3.0 mm, while that of the control lateral incisors was 20.6 ± 1.7 mm, which was a statistically significant difference (Student's *t*-test, $t = 2.362$; $p = 0.022$), i.e. lateral incisors on the side with canine impaction were shorter than those in the control group.

Palatally displaced canines were associated with shorter lateral incisor roots by 1.9 mm compared with lateral incisor roots in the control group (Table 3).

Also, there was a statistically significant difference regarding the mesiodistal width of the lateral incisors where tested lateral incisors were smaller than the lateral incisors in the control group for 0.9 mm (Table 3).

Discussion

Palatally displaced canines have been associated with missing lateral incisors and other anomalies¹⁹⁻²². In another study, palatally displaced canines were reported to be associated with peg-shaped or missing lateral incisors, other impacted and missing teeth and deep bite with retroclined maxillary incisors²³.

Lai et al.²⁴ found that 70.9% of lateral incisors were normal within their subjects with impacted maxillary canines, 26.1% were peg-shaped and 2.99% missing lateral incisors. Garib et al.²⁵ found in a subgroup of patients with peg-shaped maxillary lateral incisors (aged 10 years and above) the prevalence of palatally displaced canines of 5.2%.

The similar results could be found in our subjects with impacted maxillary canines: 72% of all lateral maxillary incisors had normal morphology; 11.2% were peg-shaped, 4% of subjects have bilaterally missing lateral incisors and 6% had unilaterally missing lateral incisors.

In their researches, Liu et al.²⁶ and Scheied et al.²⁷ also found a statistically significant difference in length and width of lateral incisors in comparison with a control group of lateral incisors in the subjects where there was no canine impaction. However, the mean length of the lateral incisors reported in their study was much greater than that in our study because their measurements were mostly based on panoramic radiographs or periapical radiographs.

Table 3

Widths and lengths of lateral incisors in examined patients

Lateral incisor (mm)	mean \pm SD	Med	Min	Max	<i>p</i> *
Width					
tested	5.9 ± 0.6	6.0	4.0	7.0	0.022
control	6.1 ± 0.5	6.2	4.2	7.3	
Length					
tested	19.7 ± 3.0	20.3	12.5	22.3	0.022
control	20.6 ± 1.7	20.9	13.4	23.3	

SD – standard deviation; Med – median; Min-Max – minimal-maximal value; *Student's *t*-test.

Liuk et al.²⁸ used CBCT imaging and noted the difference in the length of lateral incisors by 2.1 mm, and in the width by 0.7 mm. Our study demonstrated that CBCT measurements were reliable and accurate, too.²⁹ In this study, the mean length of maxillary lateral incisors in the palatally displaced canine group was significantly shorter than the length in the control group by 1.9 mm, and the mean widths in dimension of the maxillary lateral incisors in the palatally displaced canine group were significantly smaller than those in the control group by 0.9 mm.

The authors conducted a comparison of the lateral dimensions of the maxillary incisors in subjects with palatally impacted canines and other subjects of the control group without impacted canines. The difference in lateral maxillary incisors was important because of the same subjects were involved of the maxilla different sides (therefore the appropriate subgroup with unilateral palatal impaction was isolated).

It was suggested that the smaller mesiodistal crown width of lateral incisors associated with palatally impacted canine might just reflect the shorter root length. In the patients with impacted maxillary incisors there was a higher incidence of peg-shaped or missing lateral maxillary incisors

and other malocclusion. It is important to carefully plan the curing to the end of the treatment in order to satisfy aesthetic and functional criteria of occlusion.

The limitation of this study was that the palatally displaced canine group from the radiology practice could not represent the general population.

Conclusion

The missing lateral incisors was present in 16.3% of the cases, only among the subjects with palatally impacted canines. Atypical lateral incisors were present in 11.2% of cases, which explains that the palatally impacted canines associated with missing and atypical lateral incisors were one of the important hereditary phenomena. The prevalence of missing lateral incisors was higher but not statistically significant group with palatally impacted canines in comparison with the group with the buccally impacted maxillary canines. The differences of width and length of lateral incisors in the group of palatally impacted canines was statistically significant in comparison to those of lateral incisors in the control group, i.e. on the side where there is no impacted canine.

R E F E R E N C E S

1. Broadbent BH. Ontogenic development of occlusion. *Angle Orthod* 1941; 11(4): 223–41.
2. Hitchin AD. The impacted maxillary canine. *Br Dent J* 1956; 100: 1–12.
3. Jacoby H. The etiology of maxillary canine impactions. *Am J Orthod* 1983; 84(2): 125–32.
4. Becker A. Aetiology of maxillary canine impactions. *Am J Orthod* 1984; 86(5): 437–8.
5. Becker A, Smith P, Behar R. The incidence of anomalous maxillary lateral incisors in relation to palatally-displaced cuspids. *Angle Orthod* 1981; 51(1): 24–9.
6. Brin I, Solomon Y, Zilberman Y. Trauma as a possible etiologic factor in maxillary canine impaction. *Am J Orthod Dentofacial Orthop* 1993; 104(2): 132–7.
7. Miller BH. The influence of congenitally missing teeth on the eruption of the upper canine. *Dent Pract Dent Rec* 1963; 13: 497–504.
8. Bass TB. Observations on the misplaced upper canine tooth. *Dent Pract Dent Rec* 1967; 18(1): 25–33.
9. Oliver RG, Mannion JE, Robinson JM. Morphology of the maxillary lateral incisor in cases of unilateral impaction of the maxillary canine. *Br J Orthod* 1989; 16(1): 9–16.
10. Brin I, Becker A, Shalhav M. Position of the maxillary permanent canine in relation to anomalous or missing lateral incisors: A population study. *Eur J Orthod* 1986; 8(1): 12–6.
11. Polder BJ, Van't Hof MA, Van der Linden FP, Kuijpers-Jagtman AM. A meta-analysis of the prevalence of dental agenesis of permanent teeth. *Community Dent Oral Epidemiol* 2004; 32(3): 217–26.
12. Becker A, Chausbu S. Dental age in maxillary canine ectopia. *Am J Orthod Dentofacial Orthop* 2000; 117(6): 657–62.
13. Chausbu S, Sharabi S, Becker A. Dental morphologic characteristics of normal versus delayed developing dentitions with palatally displaced canines. *Am J Orthod Dentofacial Orthop* 2002; 121(4): 339–46.
14. Oliver T. Palatally displaced canines: The relationship to dental maturation, vertical facial morphology and dental anomalies of genetic origin. St Lucia, Queensland, Australia: University of Queensland; 2008.
15. Leifert S, Jonas IE. Dental anomalies as a microsymptom of palatal canine displacement. *J Orofac Orthop* 2003; 64(2): 108–20. (English, German)
16. Kim JH, Choi NK, Kim SM. A Retrospective Study of Association between Peg-shaped Maxillary Lateral Incisors and Dental Anomalies. *J Clin Pediatr Dent* 2017; 41(2): 150–3.
17. Langberg BJ, Peck S. Tooth-size reduction associated with occurrence of palatal displacement of canines. *Angle Orthod* 2000; 70(2): 126–8.
18. Becker A, Zilberman Y, Tsur B. Root length of lateral incisors adjacent to palatally-displaced maxillary cuspids. *Angle Orthod* 1984; 54(3): 218–25.
19. Zilberman Y, Cohen B, Becker A. Familial trends in palatal canines, anomalous lateral incisors, and related phenomena. *Eur J Orthod* 1990; 12(2): 135–9.
20. Mucedero M, Ricchiuti MR, Cozza P, Baccetti T. Prevalence rate and dentoskeletal features associated with buccally displaced maxillary canines. *Eur J Orthod* 2013; 35(3): 305–9.
21. Mercuri E, Cassetta M, Cavallini C, Vicari D, Leonardi R, Barbato E. Skeletal features in patient affected by maxillary canine impaction. *Med Oral Patol Oral Cir Bucal* 2013; 18(4): e597–602.
22. Sajjani AK, King NM. Dental anomalies associated with buccally- and palatally-impacted maxillary canines. *J Investig Clin Dent* 2014; 5(3): 208–13.
23. Citak M, Cakici EB, Benkli YA, Cakici F, Bektas B, Bnyuk SK. Dental anomalies in an orthodontic patient population with maxillary lateral incisor agenesis. *Dental Press J Orthod* 2016; 21(6): 98–102.
24. Lai CS, Bornstein MM, Mock L, Heuberger BM, Dietrich T, Katsaras C. Impacted maxillary canines and root resorptions of neighbouring teeth: a radiographic analysis using cone-beam computed tomography. *Eur J Orthod* 2013; 35(4): 529–38.
25. Garib DG, Alencar BM, Lauris JR, Baccetti T. Agenesis of maxillary lateral incisors and associated dental anomalies. *Am J Orthod Dentofacial Orthop* 2010; 137(6): 732.e1-6; discussion 732–3.

26. *Liu DG, Zhang WL, Zhang ZY, Wu YT, Ma XC.* Localization of impacted maxillary canines and observation of adjacent incisor resorption with cone-beam computed tomography. *Oral Surg Oral Med Oral Pathol Oral Radiol Endod* 2008; 105(1): 91–8.
27. *Scheied RC, Weiss G, Woelfel JB.* Woelfel's dental anatomy. 8th ed. Philadelphia: Wolters Kuwer Health/Lippincott Williams & Wilkins; 2012.
28. *Liuk IW, Olive RJ, Griffin M, Monsour P.* Maxillary lateral incisor morphology and palatally displaced canines: A case-controlled cone-beam volumetric tomography study. *Am J Orthod Dentofacial Orthop* 2013; 143(4): 522–6.
29. *Eslami E, Barkbordar H, Abramovitch K, Kim J, Masoud MI.* Cone-beam computed tomography vs conventional radiography in visualization of maxillary impacted-canine localization: A systematic review of comparative studies. *Am J Orthod Dentofacial Orthop* 2017; 151(2): 248–58.

Received on February 25, 2017.

Revised on May 30, 2017.

Accepted on May 10, 2017.

Online First May, 2017.