



Hybrid treatment of thoracoabdominal aortic aneurysm: case series and review of the literature

Hibridni tretman aneurizmi torakoabdominalne aorte: serija bolesnika i pregled literature

Petar Zlatanović*, Igor Končar*[†], Miroslav Marković*[†], Ranko Trailović*,
Vladimir Cvetić*[†], Lazar Davidović*[†]

Clinical Center of Serbia, *Clinic for Vascular and Endovascular Surgery, Belgrade, Serbia; University of Belgrade, [†]Faculty of Medicine, Belgrade, Serbia

Abstract

Background/Aim. Open thoracoabdominal aortic aneurysm (ThAAAs) repair is a challenging mission. Total endovascular approach is performed at selected institutions in developing countries, however these are not generalizable. Hybrid procedures offer an alternative approach. The aim of this study was to present our results of the ThAAA hybrid treatment and a literature review. **Methods.** This is a retrospective study of all patients that underwent the hybrid ThAAA repair at our institution between January 2011 and January 2018. Hybrid ThAAA repair was done as a two-staged procedure – open visceral debranching followed by stent-graft placement (TEVAR). The following data from eligible studies were extracted and analyzed: first author, publication year, patient sample, 30-day/in-hospital mortality, permanent paraplegia rate, presence of endoleaks and graft patency after the follow-up period, overall survival and mean follow-up period. **Results.** Seven patients underwent the hybrid ThAAA repair at our institution. Neither intraoperative death nor technical failure due to TEVAR was observed. Mean follow-up rate after discharge was 51.71 months [95% confidence interval (CI): 14.67–88.74

months]. At the time of the follow-up, all bypasses were patent and no prosthesis migration was documented. After one year, a case of type Ib endoleak was identified and treated successfully. Twenty-five studies were eligible for the literature review. Primary technical success was 91.69% (95% CI: 85.34–97.24%). Mean percentage of permanent paraplegia was 5.27% (95% CI: 3.55–7.01%). Visceral graft patency during the mean follow-up of 27.54 months (95% CI: 17.41–37.66 months) was 94.5% (95% CI: 92.5–96.5%). Mean pooled percentage rate of overall endoleaks during the follow-up period was 16.72% (95% CI: 11.15–22.29%). Analysis revealed 15.32% (95% CI: 11.04–19.61%) of 30-day/in-hospital mortality and 65.98% (95% CI: 58.15–73.81%) of overall survival after the follow-up period. **Conclusion.** Although thought as less invasive, the hybrid ThAAA repair is still associated with a considerable morbidity and mortality.

Key words:

aortic aneurysm, thoracic; blood vessel prosthesis; vascular surgical procedures; endovascular procedures; treatment outcome.

Apstrakt

Uvod/Cilj. Otvoreni tretman aneurizmi torakoabdominalne aorte (ThAAA) je značajan i težak poduhvat. Totalni endovaskularni tretman je moguć, ali u specijalizovanim institucijama i nije svuda prisutan. Hibridni tretman nudi alternativan pristup u tretmanu ThAAA. Cilj rada bio je prezentovanje naših dosadašnjih rezultata hibridnog tretmana ThAAA, kao i pregled literature. **Metode.** U radu je prikazan restrospektivni pregled svih bolesnika sa hibridnim tretmanom ThAAA u našoj ustanovi u periodu od januara 2011 do januara 2018. Hibridni tretman ThAAA

je učinjen u dve faze: prvi stadijum je podrazumevao otvoreni visceralni debrančing, a drugi, nakon toga, plasiranje stent-grafta u odloženoj fazi. Pregledom literature izdvojeni su i analizirani sledeći podaci: ime prvog autora, godina publikacije, broj bolesnika, 30-dnevni/intrahospitalni mortalitet, procenat bolesnika sa permanentom paraplegijom, prisustvo endolika, prohodnost graftova, sveukupno preživljavanje nakon perioda prećenja i središnja vredost praćenja. **Rezultati.** Ukupno sedam bolesnika sa ThAAA je tretirano u našoj ustanovi. Nijedan slučaj intraoperativne smrti, niti nemogućnost plasmana endografa (TEVAR) nije zabeležen. Srednje vreme praćenja bolesnika je bilo 51,71 meseci (95% interval poverenja (IP): 14,67–88,74 meseci).

Na kraju perioda praćenja svi bajpasevi su bili prohodni i nijedan slučaj migracije stent-grafta nije zabeležen. Posle godinu dana kod jednog bolesnika je zabeležen endolik tip Ib koji je uspešno tretiran. Ukupno dvadeset-sedam studija je izdvojeno za literaturni pregled. Tehnički uspeh je bio 91,69% (95% CI: 85,34–97,24%). Srednja vrednost permanentne paraplegije je bila 5,27% (95% CI: 3,55–7,01%). Objedinjena stopa prohodnosti graftova tokom središnjeg perioda praćenja od 27,54 meseci (95% CI: 17,41–37,66 meseci) je bila 94,5% (95% CI: 92,5–96,5%). Objedinjena stopa endolikova tokom perioda praćenja je bila 16,72% (95% CI: 11,15–22,29%). Objedinjena stopa

30-dnevnog/intrahospitalnog mortaliteta je bila 15,32% (95% CI: 11,04–19,61%), a stopa preživljavanja tokom perioda praćenja od 27,54 meseci 65,98% (95% CI: 58,15–73,81%). **Zaključak.** Uprkos manjoj invazivnosti, hibridni pristup za tretman ThAAA je i dalje povezan sa značajnim morbiditetom i mortalitetom.

Ključne reči:

aneurizma, torakalna; krvni sudovi, proteze; hirurgija, vaskularna, procedure; endovaskularne procedure; lečenje, ishod.

Introduction

Surgical repair of thoracoabdominal aortic aneurysms (ThAAAs) is a challenging both for a patient and a surgeon. The results of high volume centers are excellent, where the cumulative 30-day mortality is even less than 10% in selected series^{1,2}. Overall mortality was shown to be 10% according to the American College of Surgeons National Surgical Quality Improvement Program from 2005 to 2010³. Total endovascular approach is available at the selected institutions. This approach is associated with better outcomes, lower rates of mortality, morbidity and spinal cord ischemia⁴⁻⁶. Unfortunately, these are not generalizable due to the anatomic restrictions, problems with access to devices and need for custom fabrication as well as their costs.

Hybrid procedures are an alternative approach to the ThAAA management. Because it is a combination of standardized open techniques and off-the-shelf endografts, this is applicable to a wide range of patient anatomy. This approach offers the potential advantage of being less invasive since

they avoid the extensive two cavity exposure, aortic cross-clamping and mechanical circulatory support that comprise open ThAAA repair.

In this paper we present our results of the hybrid procedures for a complex thoracoabdominal aortic aneurysm in seven patients with the ThAAA and a review of the literature.

Methods

Patient population

This is a retrospective study of all patients that underwent the hybrid ThAAA repair at our institution between January 2011 and January 2018. A total of seven consecutive patients were identified. The study was approved by the Ethics Committee of our institution and was conducted according to the principles of the Declaration of Helsinki.

At our institution, there is a clear protocol for the ThAAA treatment (Figure 1).

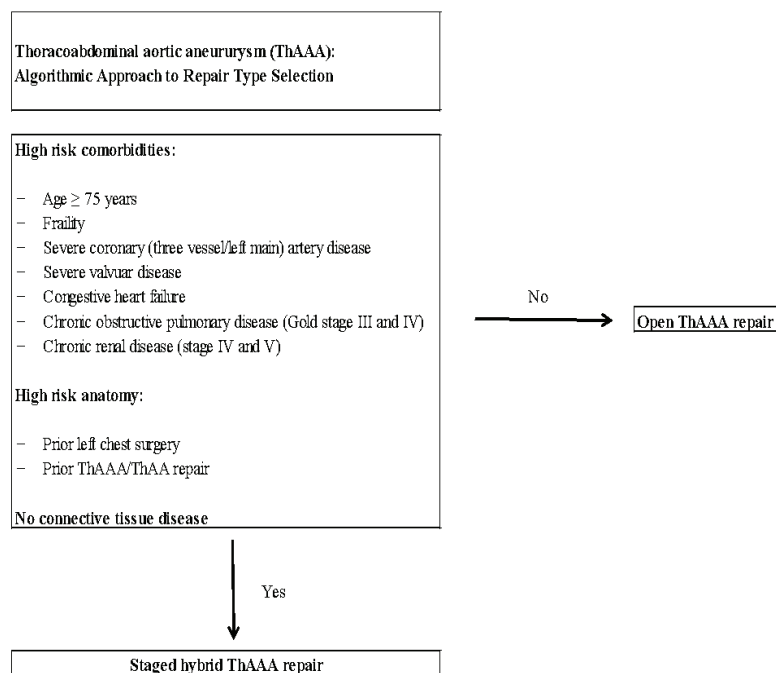


Fig. 1 – Algorithm for thoracoabdominal aneurysm (ThAAA) repair at our institution.

Patients aged ≥ 75 years, with a severe coronary artery (three vessel/left main) or severe valvular disease, congestive heart failure, chronic obstructive pulmonary disease (Gold class III and IV), chronic kidney disease (stage IV and V), prior left chest surgery, prior open ThAAA/ThAA repair and no connective tissue disease undergo staged hybrid ThAAA repair. There were a total of 174 elective patients with the ThAAA admitted to our institution in period between January 2011 and January 2018. By using this algorithm, 111 patients were treated with open repair, 7, as previously said, with the hybrid approach and 56 patients were rejected due to a high risk of both strategies.

Baseline characteristics of patients are shown in Table 1. The specific pathologies were as follows: five degenerative ThAAA (three type III and two type V) and two chronic post-dissected ThAAA (both type I). All patients underwent a thorough preoperative assessment which included a computed tomography (CT) scan to evaluate the extent of the aortic pathology and to select the endoprosthesis size (Figure 2) and transthoracic echocardiography. Technically, a successful placement of the stent-graft was defined as a successful deployment of the graft without mortality, endoleaks and conversion to open surgery or graft occlusion within the first 24 hours. CT scan was done in all patients before discharge (Figure 3). Follow-up CT scans were performed immediately after the intervention, as well as after the first and sixth month, and after that on a year basis.

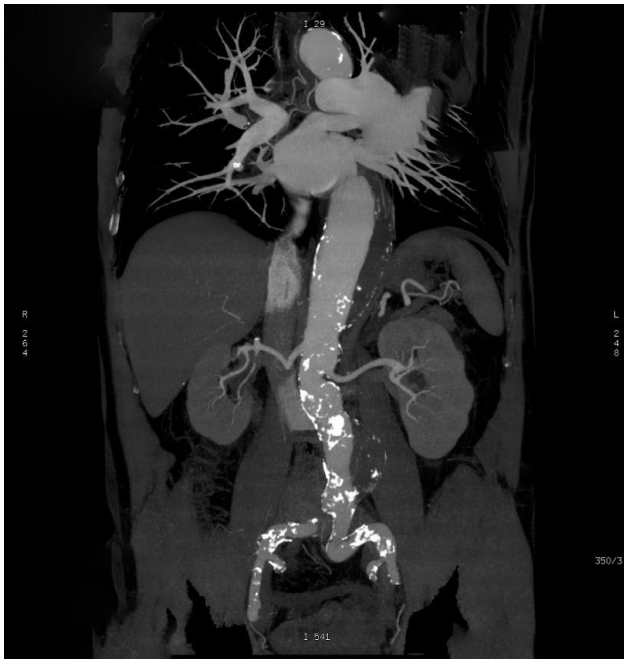


Fig. 2 – Preoperative computed tomography (CT) of the patient with type III thoracoabdominal aortic aneurysm (ThAAA).

Technical details

Hybrid ThAAA repair was done as a two-staged procedure, which consisted of the open visceral debranching and stent-graft placement. The first stage of visceral debranching

was achieved in all cases from a transabdominal approach via midline laparotomy. Prosthetic retrograde bypass grafts (all Dacron prosthesis) were constructed from the common iliac arteries or a Dacron graft which was used for the reconstruction of infrarenal AAA. Visceral target vessels were ligated proximal to the revascularization to prevent endoleak after the endoprosthesis placement. Celiac artery was identified through omentum minus and its revascularisation was performed in all cases with a bypass to the common hepatic artery in order to preserve visceral circulation. The superior mesenteric artery (SMA) was identified in some cases through omental bursa and in other at the base of the transverse colon. First option through the omental bursa has an advantage of being proximal to the origin of the middle colic artery allowing ligation of the SMA just proximal to the graft. The left and right renal artery were identified as they emerge from the aorta with the right renal artery behind the inferior vena cava. The prosthetic bypass grafts were used as a variety of custom-branched graft configurations.

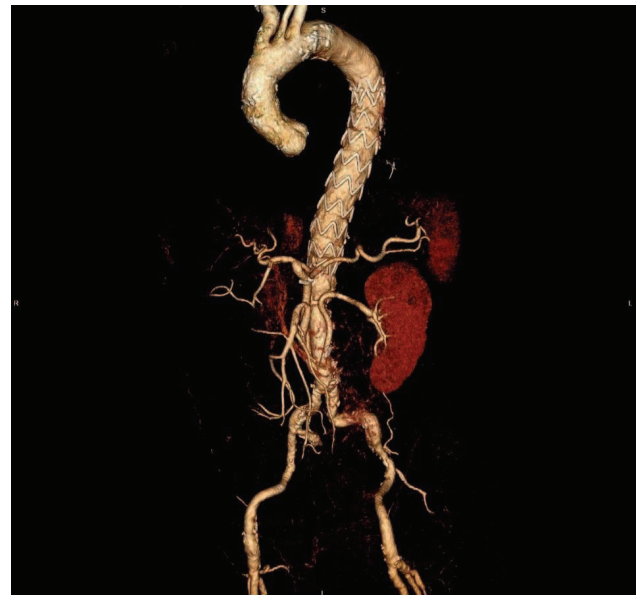

Fig. 3 – Postoperative computed tomography (CT) of the same patient with type III thoracoabdominal aortic aneurysm (ThAAA).

The second stage of the hybrid repair consisting of the stent-graft placement was performed in a delayed fashion since we did not have a hybrid operating room. All patients remained hospitalized between the first and second stage. Through the transfemoral approach in all 7 cases, a diagnostic aortography was accomplished with a pigtail catheter. An endoprosthesis was selected in order to cover the entire lesion and was oversized by 10%–20% according to the diameter of landing zones. An overlapping between two stent-grafts or between the stent-grafts and the Dacron prosthesis was done according to the instruction for use protocol for each type of graft. The postoperative mean blood pressure was kept above 100 mmHg and cerebrospinal fluid (CSF) drainage was used for the first 72 hours, as per our institutional protocol for the SCI prevention.

Table 1

	Patient 1	Patient 2	Patient 3	Patient 4	Patient 5	Patient 6	Patient 7
Gender	male	male	female	male	male	male	male
Age (years)	66	74	73	75	69	70	67
Hypertension	Yes	Yes	Yes	Yes	Yes	Yes	Yes
Diabetes on insulin	No	No	Yes	No	No	Yes	No
COPD	No	Yes	No	No	No	No	Yes
Smoker	Yes	Yes	No	Yes	Yes	Yes	Yes
Hyperlipidaemia	Yes	No	No	No	No	Yes	Yes
BMI (kg/m ²)	30.5	23.6	37.5	33.6	28.9	36.3	23
Chronic renal failure	Yes	No	Yes	Yes	No	Yes	No
Ejection fraction < 50%	No	No	Yes	No	No	Yes	No
Connective tissue disease	No	No	No	No	No	No	No
Prior stroke	Yes	Yes	No	No	No	Yes	No
Previous aortic surgery	AA replacement	No	No	AA replacement	No	AVR	No
ASA score	3	3	3	3	3	4	3
Aortic pathology	Postdissectional aneurysm	Degenerative aneurysm	Degenerative aneurysm	Degenerative aneurysm	Degenerative aneurysm	Postdissectional aneurysm	
Max. aortic diameter (cm)	7.2	6.8	7.0	8.4	6.7	9.1	7.5
Symptomatic	No	No	No	No	No	No	No
Status	Elective	Elective	Elective	Elective	Elective	Elective	Elective

COPD – chronic obstructive pulmonary disease; **BMI** – body mass index, **AA** – ascending aorta; **AVR** – aortic valve replacement.
ASA – American Society of Anesthesiologists.

Literature search strategy

All paper that were published about the hybrid ThAAA treatment until March 2018 were extensively searched. The following medical subject heading term search strategy for identification of the eligible studies was used: “thoracic”, “thoracoabdominal”, “aortic aneurysm”, “endovascular”, “stent-graft”, “visceral bypass graft”, “visceral revascularization”, “visceral debranching”, “hybrid”. The following electronic search engines were used: Google Scholar, Medline, Scopus and Cochrane Library. Furthermore, all retrieved articles were examined for a relevant case series. Hybrid repair should consist of two stages: open debranching followed by the endoprosthesis placement. Both staged and single procedures were analysed. The eligible study for this review should have: 1) a visceral bypass followed by the endoprosthesis placement; 2) at least one basic outcome criteria; 3) series of at least 15 patients. Exclusion criteria were: articles that were not in English, studies with the hybrid aortic arch debranching, case reports and papers with less than 15 patients. Some papers also reported patients with the combined visceral debranching and endovascular exclusion for different thoracoabdominal pathologies. These were also taken into account and analyzed as a part of a greater cohort of patients only if the data for them were separately shown. The eligible studies for this review were independently assessed by two reviewers. Data that were extracted and analyzed were: first author, year of publication, patient sample, 30-day/in-hospital mortality, percentage of permanent paraplegia, presence of endoleaks and graft patency after the follow-up period, overall survival and the mean follow-up period.

Results

Three patients underwent a concomitant infrarenal AAA repair with the visceral debranching (Figure 4). In other four cases, the visceral debranching was done as a retrograde bypass graft from the common iliac arteries. In one case, the hybrid aortic arch repair was previously performed. Technical success was achieved in 6 (85.71%) cases. Neither intraoperative death nor technical failure due to TEVAR was observed intraoperatively. Six patients were extubated 24 hours after the surgery. One patient was re-intubated on postoperative day 4 (POD 4) and re-intervened because of the peptic ulcer perforation and kept ventilated for 6 days due to a respiratory failure secondary to pneumonia. In one case, there was an early AMS graft occlusion which required early re-intervention and new bypass creation. No postoperative transient or permanent SCI occurred. In all cases the CSF drainage was performed for 72 hours as per protocol. Follow-up rate was 100%. Mean follow-up rate after discharge was 51.71 months (95% CI: 14.67–88.74). After the follow-up period, all bypasses were patent and no case of a stent-graft migration was noted. After one year, a case of type Ib endoleak was documented in patient number 7. This complication was successfully treated by endovascular means later on. Table 2 shows the intra- and postoperative data.

An abstract review showed that 168 studies out of total 539 were considered relevant. Out of 168, 143 papers were

excluded when the inclusion and exclusion criteria were applied. A total of 1,138 patients from 25 studies were analyzed. Pooled primary technical success rate was 91.69% (95% CI: 85.34–97.24%). Mean percentage of permanent paraplegia was 5.27% (95% CI: 3.55–7.01%). The visceral graft patency pooled rate during the mean follow-up period of 27.54 months (95% CI: 17.41–37.66 months) was 94.5% (95% CI: 92.5–96.5%). Mean pooled percentage rate of overall endoleaks during the follow-up period was 16.72% (95% CI: 11.15–22.29%). One hundred and sixty-six patients, 14.58% (95% CI: 11.04–19.61%) died during the first 30 postoperative days. The pooled rate of overall survival after the mean follow-up period of 27.54 months was 65.98% (95% CI: 58.15–73.81%) (Table 3)^{7–31}.

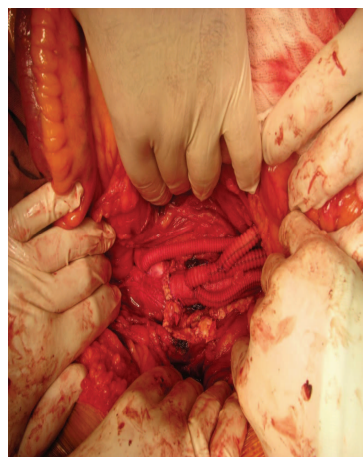


Fig. 4 – Intraoperative photo after the complete visceral debranching with simultaneous abdominal aortic aneurysm (AAA) repair.

Discussion

Since the first introduction of this hybrid procedure at our institution³², we have successfully treated patients with this approach because they were in a high risk for open ThAAA repair. Visceral debranching can be accomplished via a standard median laparotomy, without entering the chest cavity, and without the aortic cross-clamping or mechanical circulatory support. That is why the hybrid repair is “less-invasive” than the open ThAAA repair and results in less physiological derangement. The real-world data on the other side, show mixed results (Table 3), leaving ambiguity of the exact role of hybrid repairs^{7–35}.

This literature review was performed with a purpose to explore contemporary results and concerns of the technique. In order to avoid the bias of the small sample, we excluded case reports and small case series. When analyzing the morbidity and mortality rates, a significant heterogeneity was found, with the mean pooled rate of 14.58% for 30-day mortality and 5.27% for an irreversible spinal cord injury (SCI). Similar results were presented in the Society for Vascular Surgery (SVS) meeting in 2012 from the North American Complex Abdominal Aortic Debranching (NACAAD).

Table 2

Intraoperative and postoperative data	Intraoperative and postoperative data						
	Patient 1	Patient 2	Patient 3	Patient 4	Patient 5	Patient 6	Patient 7
Concomitant AAA repair	Yes	No	No	Yes	Yes	No	No
ThAAA class	I	III	V	III	III	I	V
Number of endografts	3	3	3	3	2	3	3
Endografts	Valiant Captiva®	Bolton Relay®	Zenith TX2®	Valiant Captiva®	Zenith TX2®	Valiant Captiva®	Valiant Captiva®
Proximal stentgraft diameter (mm)	28	42	40	42	36	46	40
Ventilation > 24 hours	No	No	No	No	No	Yes	No
Dyalisis	No	No	No	No	No	Yes	No
Stroke	No	No	No	No	No	No	No
SCI	No	No	No	No	No	No	No
Pneumonia	No	No	No	No	No	Yes	No
ICU length of stay (days)	3	5	6	5	5	12	7
In-hospital mortality	No	No	No	No	No	No	No
Follow-up (months)	102	86	83	57	12	8	14
Late endoleaks	No	No	No	No	No	No	Ib
Aorta related intervention	No	No	No	No	No	No	EVAR

AAA – abdominal aortic aneurysm; ThAAA class – thoracoabdominal aortic aneurysm (Crawford classification); SCI – spinal cord ischemia, ICU – intensive care unit; EVAR – endovascular aortic replacement.

Table 3

Major published series of hybrid thoracoabdominal aortic aneurysm (ThAAA) repair with more than 15 patients

Author	Year	Patients, n	30-day mortality (%)	Permanent paraplegia (%)	Endoleaks (%)	Graft patency (%)	Overall survival (%)	Mean follow-up (days)
Zhou et al. ⁷	2006	31	3.2	0	6	95	90% ^a	16
Black et al. ⁸	2006	22	23	0	42	98	-	9.5
Lee et al. ⁹	2007	17	24	0	12	96	76 ^a	8
Van der Mortel et al. ¹⁰	2008	16	31	0	13	95	69 ^a	13
Quinones-Baldrich et al. ¹¹	2009	20	0	6.6	30	100	76 ^a	17
Donas et al. ¹²	2009	58	8.6	3.4	17	97	74 ^a	22
Drinkwater et al. ¹³	2009	107	15	8.4	33	87 [*]	-	-
Patel et al. ¹⁴	2009	23	17	4	23	90	68 ^a	6
Chiesa et al. ¹⁵	2009	31	19.4	3.2	3.2	93.2	61.3 ^a	11.1
Kabbani et al. ¹⁶	2010	36	8.3	0	39	93	80 ^a	6
Patel et al. ¹⁷	2010	29	3.4	3.4	34	95 [*]	-	-
Kuratani et al. ¹⁸	2010	86	2.3	0	17	99	86 ^e	88
Smith et al. ¹⁹	2011	24	12.5	8.3	12	99	-	12
Hughes et al. ²⁰	2012	58	9	4	-	95	62 ^e	26
Tshomba et al. ²¹	2012	52	14	1.9	7.7	93	77 ^h	24 ^{**}
Bianchini Massoni et al. ²²	2014	45	24	13	-	79	45 ^f	26
Chiesa et al. ²³	2014	55	12.7	-	-	90.2	73.8 ^c	36
Rosset et al. ²⁴	2014	76	34.2	11.8	2.63	99.14	64.48 [*]	30
Gkremoutis et al. ²⁵	2014	30	26.7	10	3	95.3	57.8 ^b	12
Benrashid et al. ²⁶	2016	81	9.9	7.4	12.3	-	32 ^e	60
Jain et al. ²⁷	2016	19	0	5.26	15.78	100	100 ^c	36
Hawkins et al. ²⁸	2017	25	4	8	-	-	-	-
van de Graaf et al. ²⁹	2017	15	33	7	-	-	40 ^b	12
Tsilimparis et al. ³⁰	2018	22	15.3	4.3	-	92.05	55 ^a	16.4
Shuto et al. ³¹	2018	60	5	3	10	95	43.5 ^g	96

*30 day; **median; a – at end of follow period; b – 1-year Kaplan-Meier survival; c – 3-year Kaplan-Meier survival; d – 4-year Kaplan-Meier survival; e – 5-year Kaplan-Meier survival; f – 6-year Kaplan-Meier survival; g – 8-year Kaplan-Meier survival; h – freedom from aortic-related deaths at end of follow-up.

Their data for 30-day mortality was 16% and for SCI 14%, which was associated with the extent of the aortic disease and aneurysm rupture³⁶. Better results in our material might be explained by a low number of patients and careful selection. Available open repair option provides unbiased selection while most patients in our group had the chronic obstructive pulmonary disease (COPD) and obesity as a risk factor with the average age lower than reported.

Substantial mortality associated with this hybrid approach could be explained by the fact that a majority of these patients are elderly and with major comorbidities that cannot withstand this kind of reconstruction. This highlights the importance of patient selection. In our sample of patients, the mean age was 70.57 years, they were mainly obese (71.42%) and all of them had the American Society of Anesthesiologists (ASA) score ≥ 3 . In examining the specifics of the patients, as seen from the literature⁷⁻³⁶, it appears that they tend to be in a higher risk. It seems that hybrid repair can offer some advantage in high-risk patients, but it is certainly not the low-risk approach. Also, even more important is that it demonstrates that there are limits of how far the hybrid technique can be pushed. In the end, in the population of patients with the extremely high-risk, a non-operative approach may be actually the best option.

What is even more interesting point is that this technique was adopted by centers with little previous experience in treating patients with the ThAAA. A few large-volume centers both in the USA and Europe display the constant evidence of better results demonstrating how extensive experience in the treatment of this pathology, learning curve and an organized perioperative background are required for the best management.

There is no significant amount of data which demonstrates whether the endoprosthesis placement for the exclusion of the ThAAA should be done concomitantly or in a delayed fashion⁸. Those who are opponents of staged approach say that this leaves a patient to a potential rupture, although there are little data to support this approach⁹. This approach is associated with longer hospital stay at the Intensive Care Units (ICU) and higher morbidity rate³⁸. On the other side, the delayed approach has one major advantage. It allows the patients to recover from debranching surgery, before exposing them to the placement of the aortic endoprosthesis. This has the larger influence on the kidney function, as it allows them to recover from ischemia due to debranching surgery before exposing them to the contrast during the second, endovascular part of the hybrid repair that also has nephrotoxic effect. That is why this double-staged procedure should be mainstay of treatment for the patients who require the extensive ThAAA reconstruction, with single-staged reserved only to those who are at high-risk of aneurysm rupture.

Another concerns are the endograft complications, and on the other side, visceral graft patency. Our patient sample revealed 100% of the visceral graft patency during the mean follow-up of 51.71 months. One (14.28%) patient had an endoleak type Ib treated with additional endograft in the distal landing zone. The literature review data revealed the visceral graft patency of 94.5% during the mean follow-up of 27.54 months, whereas 16.72% had an endoleak. Kuratani et al.¹⁸, with the longest follow-up period (88.5 months, n = 86), reported two intraprocedural deaths, one patient died because of a visceral graft occlusion and bowel necrosis and the other because of a graft infection.

Due to financial and technical reasons we do not perform branched or fenestrated procedures in our country. Inaccessibility of these treatment options brings non-selectivity, but on the other hand, our institution has extensive experience with the open repair³⁷⁻⁴¹ as an option in treatment of this complex pathology. For unfit patients, the hybrid repair is the only viable option. We think that a thorough case selection and a choice of the right procedure are two most important things. In large-volume centers or those with suitable expertise, visceral hybrid repair is an alternative treatment strategy for the high-risk population of patients with the limited open and fully endovascular therapeutic alternatives.

Our study has several limitations. Firstly, this was a retrospective study with prospectively collected data in a single center where a patient accrual required nearly seven years. Secondly, our study was performed on a small number of patients. Thirdly, there was an absence of a control group. The main strength of this study is detailed clinical information, especially in the literature review which provides enough statistical power to make valid conclusions.

Conclusion

Although thought as less invasive, hybrid ThAAA repair is still associated with a considerable morbidity and mortality rate since it is frequently performed in fragile patients. Despite the improvements in the branched and fenestrated procedures, hybrid approach may continue to have a role in the hostile anatomy of those patients or when advanced stent grafts are not available. That is why this should be reserved for the large-volume centers with enough experience that can determine a patient suitability and offer all treatment options with high standards of perioperative care.

Acknowledgments

This article is a part of a scientific research project (No 175008) supported by the Ministry of Education, Science and Technological Development of the Republic of Serbia.

R E F E R E N C E S

1. *Lemaire SA, Price MD, Green SY, Zarda S, Coselli JS.* Results of open thoracoabdominal aortic aneurysm repair. *Ann Cardiothorac Surg* 2012; 1(3): 286–92.
2. *Estreza AL, Sheinbaum R, Miller CC, Harrison R, Safi HJ.* Neuromonitor-guided repair of thoracoabdominal aortic aneurysms. *J Thorac Cardiovasc Surg.* 2010; 140(6 Suppl): S131–5; discussion S142–6.

3. Bentsley RP, Curran T, Hurks R, Lo RC, Wjers MC, Hamdan AD, et al. Open repair of intact thoracoabdominal aortic aneurysms in the American College of Surgeons National Surgical Quality Improvement Program. *J Vasc Surg* 2010; 58(4): 894–900.
4. Reilly LM, Rapp JH, Grenon SM, Hiramoto JS, Sobel J, Chuter TA. Efficacy and durability of endovascular thoracoabdominal aortic aneurysm repair using the caudally directed cuff technique. *J Vasc Surg* 2012; 56(1): 53–63; discussion 63–4.
5. Guillou M, Bianchini A, Sobocinski J, Maurel B, D'elia P, Tyrrell M, et al. Endovascular treatment of thoracoabdominal aortic aneurysms. *J Vasc Surg* 2012; 56(1): 65–73.
6. Greenberg R, Eagleton M, Mastracci T. Branched endografts for thoracoabdominal aneurysms. *J Thorac Cardiovasc Surg* 2010; 140(6 Suppl): S171–8.
7. Zhou W, Reardon M, Peden EK, Lin PH, Lumsden AB. Hybrid approach to complex thoracic aortic aneurysms in high-risk patients: Surgical challenges and clinical outcomes. *J Vasc Surg* 2006; 44(4): 688–93.
8. Black SA, Wolfe JHN, Clark M, Hamady M, Cheshire NJ, Jenkins MP. Complex thoracoabdominal aortic aneurysms: endovascular exclusion with visceral revascularization. *J Vasc Surg* 2006; 43(6):1081–9; discussion 1089.
9. Lee WA, Brown MP, Martin TD, Seeger JM, Huber TS. Early results after staged hybrid repair of thoracoabdominal aortic aneurysms. *J Am Coll Surg* 2007; 205(3): 420–31.
10. Van de Mortel RHW, Vabl AC, Balm R, Buth J, Hamming JF, Schurink GW, et al. Collective experience with hybrid procedures for suprarenal and thoracoabdominal aneurysms. *Vascular* 2008; 16(3): 140–6.
11. Quinones-Baldrich W, Jimenez JC, DeRubertis B, Moore WS. Combined endovascular and surgical approach (CESA) to thoracoabdominal aortic pathology: A 10- year experience. *J Vasc Surg* 2009; 49(5): 1125–34.
12. Donas KP, Lachat M, Rancic Z, Oberkofler C, Pfammatter T, Guber I, et al. Early and midterm outcome of a novel technique to simplify the hybrid procedures in the treatment of thoracoabdominal and pararenal aortic aneurysms. *J Vasc Surg* 2009; 50: 1280–4.
13. Drinkwater SL, Böckler D, Eckstein H, Cheshire NJ, Kotelis D, Wolf O, et al. The visceral hybrid repair of thoraco-abdominal aortic aneurysms—a collaborative approach. *Eur J Vasc Endovasc Surg* 2009; 38(5):578–85.
14. Patel R, Conrad MF, Paruchuri V, Kwolek CJ, Chung TK, Cambria RP. Thoracoabdominal aneurysm repair: Hybrid versus open repair. *J Vasc Surg* 2009; 50(1): 15–22.
15. Chiesa R, Tshomba Y, Melissano G, Logaldo D. Is hybrid procedure the best treatment option for thoraco-abdominal aortic aneurysms? *Eur J Vasc Endovasc Surg* 2009; 38(1): 26–34.
16. Kabbani LS, Criado E, Upchurch GR, Patel HJ, Eliason JL, Rectenwald J, et al. Hybrid repair of aortic aneurysms involving the visceral and renal vessels. *Ann Vasc Surg* 2010; 24(2): 219–24.
17. Patel HJ, Upchurch GR, Eliason JL, Criado E, Rectenwald J, Williams DM, et al. Hybrid debranching with endovascular repair for thoracoabdominal aneurysms: A Comparison with open repair. *Ann Thorac Surg* 2010; 89(5): 1475–81.
18. Kuratani T, Kato M, Shirakawa Y, Shimamura K, Sawa Y. Long-term results of hybrid endovascular repair for thoraco-abdominal aortic aneurysms. *Eur J Cardiothorac Surg* 2010; 38(3): 299–304.
19. Smith TA, Gatens S, Andres M, Modrall JG, Clagett GP, Arko FR. Hybrid repair of thoracoabdominal aortic aneurysms involving the visceral vessels: comparative analysis between number of vessels reconstructed, conduit, and gender. *Ann Vasc Surg* 2011; 25(1): 64–70.
20. Hughes GC, Andersen ND, Hanna JM, McCann RL. Thoracoabdominal aortic aneurysm: hybrid repair outcomes. *Ann Cardiothorac Surg* 2012; 1(3): 311–9.
21. Tshomba Y, Melissano G, Logaldo D, Rinaldi E, Bertoglio L, Civilini E, et al. Clinical outcomes of hybrid repair for thoracoabdominal aortic aneurysms. *Ann Cardiothorac Surg* 2012; 1(3): 293–303.
22. Bianchini Massoni C, Geisbüsch P, Gallitto E, Hakimi M, Gargiulo M, Böckler D. Follow-up outcomes of hybrid procedures for thoracoabdominal aortic pathologies with special focus on graft patency and late mortality. *J Vasc Surg* 2014; 59(5): 1265–73.
23. Chiesa R, Tshomba Y, Logaldo D, Kahlberg A, Baccellieri D, Apruzzi L. Possible graft-related complications in visceral debranching for hybrid B dissection repair. *Ann Cardiothorac Surg* 2014; 3(4): 393–9.
24. Rosset E, Ben Ahmed S, Galvaing G, Favre JP, Sessa C, Lermusiaux P, et al. Editor's Choice- Hybrid treatment of thoracic, thoracoabdominal, and abdominal aortic aneurysms: A multicenter retrospective study. *Eur J Vasc Endovasc Surg* 2014; 47(5): 470–8.
25. Gkremoutis A, Schmandra T, Meyn M, Schmitz-Rixen T, Keese M. Hybrid approach to emergent and urgent treatment of complex thoracoabdominal aortic pathology. *Eur J Vasc Endovasc Surg* 2014; 48(4): 407–13.
26. Benrashid E, Wang H, Andersen ND, Keenan JE, McCann RL, Hughes GC. Complementary roles of open and hybrid approaches to thoracoabdominal aortic aneurysm repair. *J Vasc Surg* 2016; 64(5): 1228–38.
27. Jain A, Flohr TF, Johnston WF, Tracci MC, Cherry KJ, Upchurch GR Jr, et al. Staged hybrid repair of extensive thoracoabdominal aortic aneurysms secondary to chronic aortic dissection. *J Vasc Surg* 2016; 63(1): 62–9.
28. Hawkins RB, Mehoff JH, Narabari AK, Jain A, Ghanta RK, Kron IL, et al. Improved outcomes and value in staged hybrid extent II thoracoabdominal aortic aneurysm repair. *J Vasc Surg* 2017; 66(5): 1357–63.
29. van de Graaf RA, Grune F, Hoeks SE, Ten Raa S, Stolker RJ, Verhagen HJ, et al. One-Year Follow-Up After Hybrid Thoracoabdominal Aortic Repair. *Vasc Endovascular Surg* 2017; 51(1): 23–7.
30. Tsilimparis N, Debus SE, Biehl M, Spanos K, Larena-Avellaneda A, Wipperfurth S, et al. Fenestrated-branched endografts and visceral debranching plus stenting (hybrid) for complex aortic aneurysm repair. *J Vasc Surg* 2018; 67(6): 1684–9.
31. Shuto T, Wada T, Miyamoto S, Kamei N, Hongo N, Mori H. Ten-year experience of the thoraco-abdominal aortic aneurysm treatment using a hybrid thoracic endovascular aortic repair. *Interact Cardiovasc Thorac Surg* 2018; 26(6): 951–6.
32. Davidović L, Ilić N, Končar I, Dimić A, Čolić M, Sindjelić R. Hybrid procedure in the treatment of thoracoabdominal aortic aneurysms: case report. *Srp Arh Celok Lek* 2013; 141(1–2): 89–94. (Serbian)
33. Canaud L, Karthikesalingam A, Jackson D, Cresswell L, Cliffe M, Markar SS, et al. Clinical outcomes of single versus staged hybrid repair for thoracoabdominal aortic aneurysm. *J Vasc Surg* 2013; 58: 1192–200.
34. Rigberg DA, McGory ML, Zingmond DS, Maggard MA, Agustin M, Lawrence PF, et al. Thirty-day mortality statistics underestimate the risk of repair of thoracoabdominal aortic aneurysms: a statewide experience. *J Vasc Surg* 2006; 43(2): 217–22; discussion 223.
35. Moulakakis KG, Mylonas SN, Antonopoulos CN, Liapis CD. Combined open and endovascular treatment of thoracoabdominal aortic pathologies: a systematic review and meta-analysis. *Ann Cardiothorac Surg* 2012; 1(3): 267–76.
36. Oderich GS, Timaran C, Farber M, Quinones-Baldrich W, Escobar G, Głowiczki P et al. RR14. Spinal cord injury after hybrid endovascular repair of thoracoabdominal aortic aneurysms in the North American Complex Abdominal Aortic Debranching (NACAAD) Registry. *J Vasc Surg* 2012; 5(6 Suppl): 93S–4S.

37. *Lin PH, Kougas P, Bechara CF, Weakley SM, Bakaeen FG, Lemaire SA, et al.* Clinical outcome of staged versus combined treatment approach of hybrid repair of thoracoabdominal aortic aneurysm with visceral vessel debranching and aortic endograft exclusion. *Perspect Vasc Surg Endovasc Ther* 2012; 24(1): 5–13.
38. *Davidović L, Marković M, Sindjelić R, Savić N, Kostić D, Cinara I, et al.* Early results in the surgical treatment of Crawford type IV thoracoabdominal aneurysms. *Acta Chir Jugosl* 2005; 52(3): 49–54. (Serbian)
39. *Davidović LB.* Surgical treatment of thoracoabdominal aortic aneurysms. *Srp Arh Celok Lek* 2006; 134 Suppl 1: 17–26. (Serbian)
40. *Davidović LB, Ilić N, Koncar I, Dragas M, Marković M, Sindjelić R, et al.* Some technical considerations of open thoracoabdominal aortic aneurysm repair in a transition country. *Vascular* 2011; 19(6): 333–7.
41. *Koncar IB, Colić M, Davidović LB, Sindelić RB, Ilić N, Dragas M.* Ruptured thoracoabdominal aneurysm with aortocaval fistula, aortic dissection type III, and bilateral femoral aneurysms in patient with Marfan syndrome. *Am Surg* 2010; 76(6): 657–9.

Received on June 6, 2018.

Accepted on November 23, 2018.

Online First December, 2018.