



## Clear cell/endometrioid type ovarian carcinoma associated with endometriosis of the ipsilateral ovary

Svetloćelijski/endometrioidni karcinom jajnika udružen sa endometriozom u istom jajniku

Ivana Rudić Biljić-Erski\*, Mladenko Vasiljević\*<sup>†</sup>, Snežana Rakić\*<sup>†</sup>,  
Olivera Džatić-Smiljković\*<sup>†</sup>, Sladjana Mihajlović\*

\*Clinic of Gynecology and Obstetrics “Narodni Front”, Belgrade, Serbia; University of Belgrade, <sup>†</sup>Faculty of Medicine, Belgrade, Serbia

### Abstract

**Introduction.** Ovarian endometriosis has been identified as a risk factor for occurrence of endometriosis-associated ovarian carcinoma. We presented a rare case of simultaneous clear cell/ endometrioid ovarian carcinoma and endometriosis of the ipsilateral ovary. **Case report.** A 47-year-old patient underwent surgery for right ovarian endometriotic cyst. A total hysterectomy with bilateral salpingo-oophorectomy, lymphadenectomy in the right psoas muscle region and omentectomy were performed as well as multiple peritoneal biopsies. Six cycles of chemotherapy were instituted postoperatively using the Taxol-CBDCA protocol. Abdominal and pelvic CT did not demonstrate recurrence of the disease postoperatively and after completed chemotherapy treatment. Six months after the completion of treatment, the patient felt well without the disease recurrence. **Conclusion.** Clear cell and endometrioid subtypes of ovarian carcinoma have good prognosis if they are diagnosed and treated at an early stage of the disease. In our patient, the carcinoma was detected in the first stage and successfully treated with combination therapy, i.e., surgical and chemotherapy.

### Key words:

adenocarcinoma, clear cell; diagnosis; endometriosis; ovarian neoplasms; treatment outcome.

### Apstrakt

**Uvod.** Endometrijoza jajnika je identifikovana kao faktor rizika od nastanka karcinoma jajnika udruženog sa endometriozom. Prikazali smo bolesnicu sa istovremenom pojavom svetloćelijskog/endometrioidnog tipa karcinoma jajnika i endometrioze u istom jajniku. **Prikaz bolesnika.** Bolesnica, stara 47 godina, podvrgnuta je operativnom zahvatu zbog endometriotične ciste na desnom jajniku. Urađena je histerektomija sa obostranom adneksotomijom, limfadenektomija regije desnog slabinskog mišića, omentektomija i višestruke biopsije peritoneuma. Posle operacije primenjena je hemioterapija u toku šest ciklusa po protokolu Taxol-CBDCA. Nakon hiruškog zahvata i sprovedenog lečenja hemioterapijom urađen je kontrolni CT abdomena i male karlice i kod bolesnice nisu nađeni znakovi recidiva bolesti. Šest meseci posle završenog lečenja bolesnica se dobro osećala i nije imala recidiv bolesti. **Zaključak.** Svetloćelijski i endometrioidni podtip karcinoma jajnika imaju dobru prognozu ako se otkriju i leče u ranom stadijumu bolesti. Kod prikazane bolesnice karcinom je otkriven u prvom stadijumu i uspešno je lečen kombinovanom terapijom tj. hiruški i hemioterapijom.

### Ključne reči:

adenokarcinom svetlih ćelija; dijagnoza; endometrijoza; jajnik, neoplazme; lečenje, ishod.

### Introduction

Endometriosis is a benign gynecological condition characterised by specific histological, molecular and clinical findings. Prevalence of endometriosis among the women of reproductive age is 10%–15%, increasing to 30% in the infertile women<sup>1</sup>. Endometriosis is considered as a considerable risk factor for development of several subtypes of epithe-

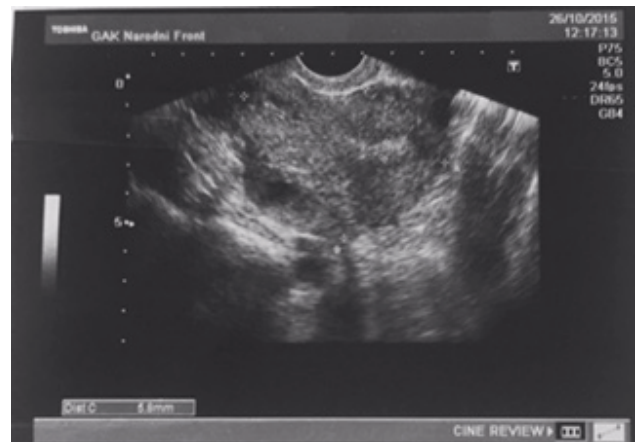lial ovarian carcinoma (clear cell and endometrioid carcinoma) known as endometriosis-associated ovarian carcinoma (EAOC)<sup>2,3</sup>. The incidence of ovarian cancer in general population ranges between 5 and 9 new cases per 100,000 women per year, and ovarian cancer is known to develop in 0.3%–1.6% of women with endometriosis<sup>4</sup>. We presented a rare case of simultaneous clear cell/endometrioid ovarian carcinoma and endometriosis of the ipsilateral ovary.

### Case report

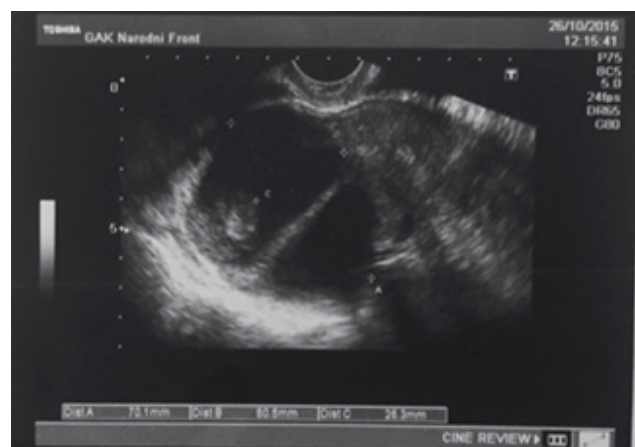A 47-year-old patient was admitted to our clinic for surgery due to presence of a right ovarian endometriotic cyst and pelvic pain. The onset of pelvic pain was one month prior to hospital admission. Menstrual cycles were regular, 25 days in length. The patient was a nulligravida. The patient appeared generally well, with a normal nutritional status and blood pressure. The right ovarian endometriotic cyst was diagnosed by ultrasound 4 years before. Furthermore, the patient had history of laparoscopic surgery 13 years ago for a benign left ovarian cyst. The patient did not see her doctor for regular gynecologic exams. Family history was negative for malignancies. The gynecologic bimanual exam revealed a palpable and tender right adnexal cystic mass, measuring 50–60 mm. Two-dimensional transvaginal ultrasound revealed the anteverted uterus with a normal external uterine contour, measuring 70 × 51 × 51 mm. Endometrial lining had normal contours and its thickness measured 6 mm. A multiloculated cystic tumour of the right ovary measured 70 × 60 mm and contained hyperechoic and viscous material on ultrasound. A solid hyperechoic formation, measuring 25 × 25 mm, was seen in the lower half of the right ovarian cystic mass. The capsule of the cyst measured 3.5 mm. The left ovary measured 28 × 22 mm and was normal on ultrasound. Abdominal ultrasound was normal. Para-aortic and pelvic lymph nodes were not enlarged. Pre-operative ultrasound findings of internal genitalia are demonstrated on Figures 1, 2 and 3.

Colour flow Doppler of pericystic vessels and the blood vessels of solid portions of the cyst were performed and the resistance indices (RI) of 0.50 and 0.42 were measured respectively. Increased tumour marker levels of the cancer antigen 125 (CA-125) were noted at 594 U/mL (normal range is less than 46 U/mL). Human epididymis protein 4 (HE4) levels were within a normal reference range (HE4 = 42.8 pmol/L). The risk of ovarian malignancy algorithm (ROMA index) value was calculated to be 18%, which was considered a high-risk in a premenopausal woman. Complete blood count, urea, creatinine, electrolytes, liver function tests, urinalysis and urine culture were all within normal limits. Colposcopic exam and Pap smear were normal. Internal medicine and anaesthesiology consults were sought and the examinations were found to be normal. The patient underwent a total abdominal hysterectomy with bilateral salpingo-oophorectomy. Wide adhesions covering the fundus and anterior uterus were noticed intraoperatively and adhered to the anterior pelvic wall and bladder peritoneum. A cystic formation measuring 60 × 70 mm was seen on the right ovary, which adhered to the uterus, right Fallopian tube and the lateral pelvic wall. The left ovary and Fallopian tube had a normal gross appearance, with adhesions to the uterus and peritoneum of the lateral pelvic wall. Multiple endometriotic implants were seen on the uterosacral ligaments and the pouch of the Douglas peritoneum. During the resection of right ovarian adhesions, the ovarian cyst ruptured. Gross pathological changes were not seen on the liver, stomach, large and small intestines, and the omentum. The histopathology results revealed the following: ovarian adenocarcinoma I, endometrioid/clear cell type, HG1 NG2, which was

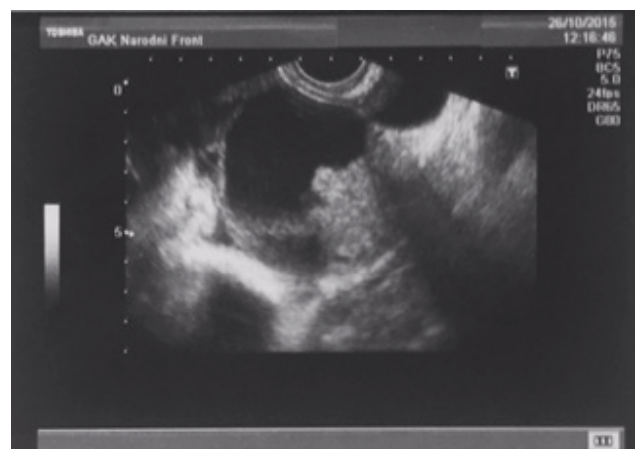also found on the surface of the cyst. Further histopathology revealed ovarian endometriosis. Histopathology of the Fallopian tubes was normal. Uterine histopathology revealed an intramural fibroid and adenomyosis. Cervical histopathology revealed chronic cervicitis. The histopathology of removed right ovary diagnosed both endometriosis and ovarian carcinoma (Figure 4).



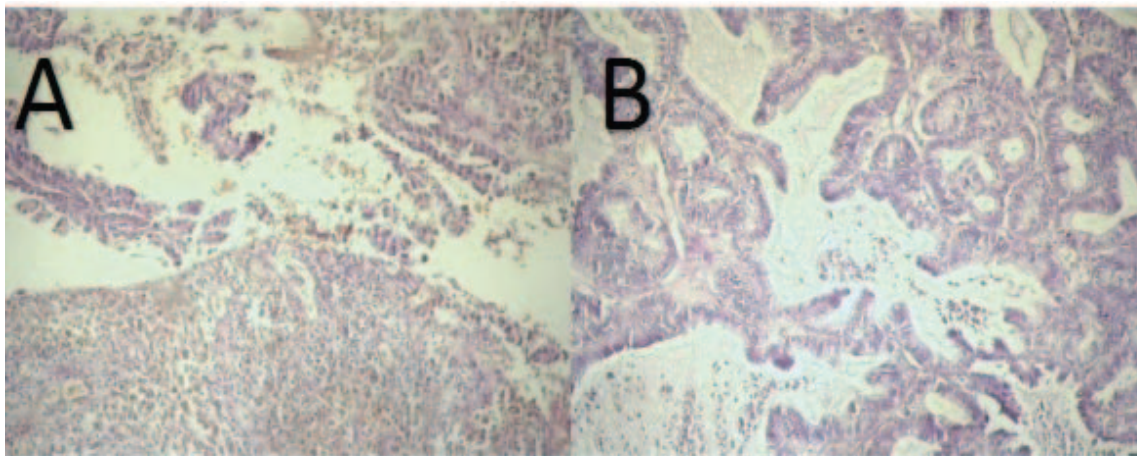
**Fig. 1 – A normal sized uterus with a homogeneous echotexture.**



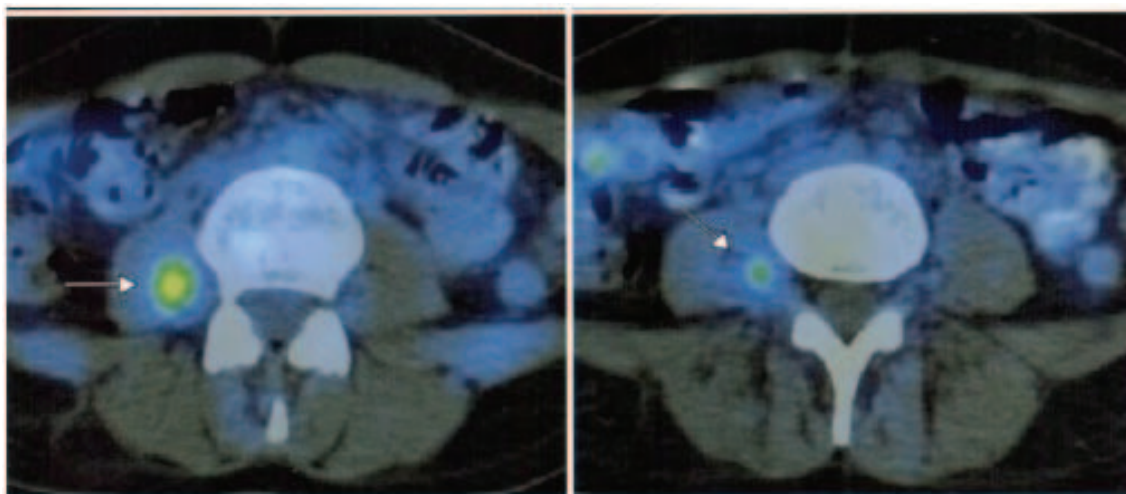
**Fig. 2 – Right ovarian bilocular cystic tumour with viscous content. A regular and thin septum is present within the cyst. A hyperechoic solid tissue element is visible in the inferior half of the cyst.**



**Fig. 3 – Hyperechoic solid tissue element at the inferior pole of the right ovarian cyst.**



**Fig. 4 – Histopathological types of ovarian carcinoma of the right ovary: A) Clear cell carcinoma and endometriosis (hematoxylin and eosin,  $\times 10$ ); B) Endometrioid carcinoma (hematoxylin and eosin,  $\times 20$ ).**

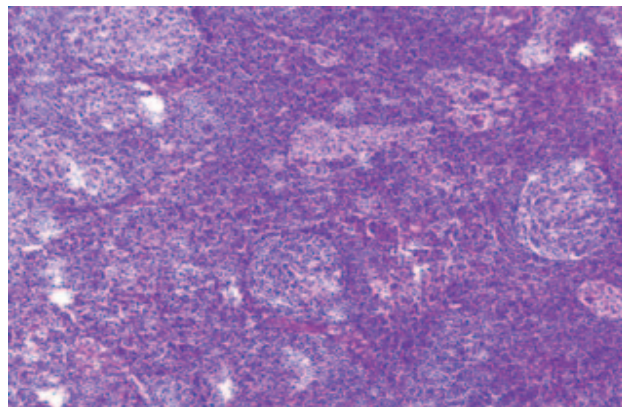


**Fig. 5 – Positron emission tomography-computed tomography (PET-CT) scan: an enlarged lymph node, suspicious of metastases, is visible between the right psoas muscle and the spinal column.**

The disease was staged using the Tumor-Node-Metastasis (TNM) and International Federation of Gynecology and Obstetrics (FIGO) classifications and was classified as follows: pT1c-N0-M0 (FIGO IC). The patient's case was presented to the Council for Malignant Gynecologic Diseases and the Council decided to perform positron emission tomography (PET) and computed tomography (CT) of the abdomen and pelvis. PET/CT of the abdomen and pelvis did not find any pathological lesions; pelvic and paraaortic lymph nodes were not enlarged. An enlarged lymph node, suspicious of metastasis, measuring  $15 \times 10$  mm, was noted in-between the right psoas muscle and the spine. Postoperative findings of the PET/CT scan are shown in Figure 5.

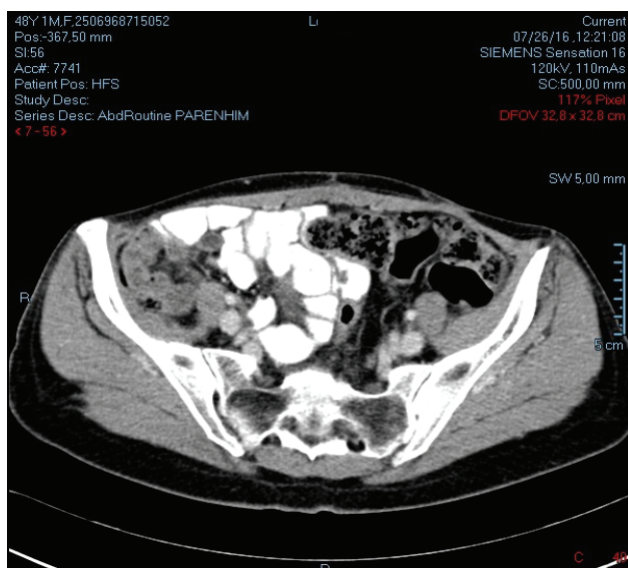
The PET/CT findings were presented and the Council decided that the patient should undergo radical surgery according to the protocol for ovarian cancer. The patient underwent the second surgery with lymphadenectomy in the right psoas muscle region, omentectomy and multiple peritoneal biopsies. Swabs from the peritoneum of the pouch of Douglas, bilateral paracolic gutters, and subdiaphragmatic areas were obtained. Cytological washings of the peritoneal

cavity were obtained. The histopathology results were as follows: Reactive follicular hyperplasia and sinus histiocytosis lymphadenopathy; fragments of peritoneal connective vascular tissue without pathological significance. The cytological finding was negative for malignancy. The histopathological findings of the removed lymph node are shown in Figure 6.

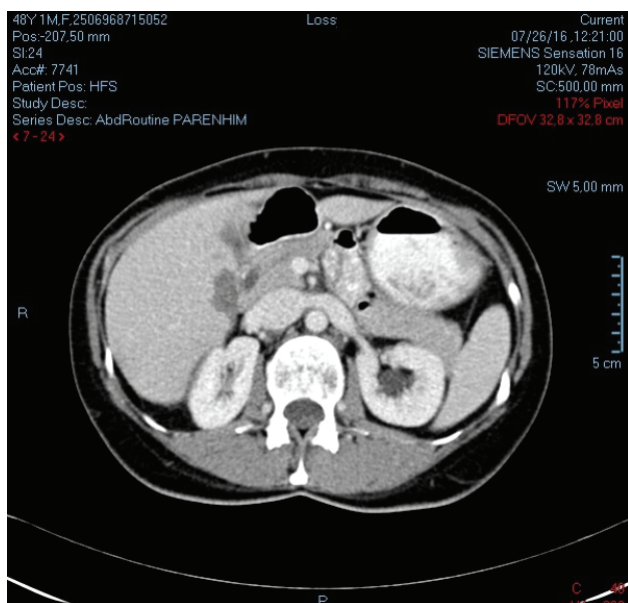


**Fig. 6 – Sinus histiocytosis of the lymph node with reactive follicular hyperplasia.**

These findings were presented to the Council for Malignant Gynecologic Diseases, and a decision to commence chemotherapy was made, using six cycles of the Taxol (125 mg/m<sup>2</sup>) and carboplatin CBCDA (250 mg/m<sup>2</sup>) protocol. Tumour markers (CA-125 and HE4) or CT of the pelvis and abdomen were to be repeated before commencing and after the completion of chemotherapy regimen. Prior to commencing chemotherapy, the CA-125 value was reported to be 70 U/L, and the abdominal/pelvic CT did not show any pathological changes. The patient was treated with six cycles of chemotherapy. The follow-up CT of the abdomen and pelvis was normal; CA-125 levels were also within a normal reference range. Six months after treatment, the patient felt generally well, without signs of metastatic disease. The follow-up CT findings of the pelvis and abdomen are shown in Figures 7 and 8.



**Fig. 7 – Pelvic computed tomography (CT) demonstrates normal bladder and intestines.**



**Fig. 8 – Normal computed tomography (CT) of abdominal organs.**

## Discussion

Endometriosis has been found to be associated with some histological subtypes of epithelial ovarian carcinoma, such as clear cell, endometrioid and low malignant potential serous carcinoma. These are known as EAOCs<sup>5,6</sup>. EAOCs are usually diagnosed at an early stage in the patients with endometriosis, and these are usually low malignant potential carcinomas. Endometriosis is diagnosed in 4.2% of patients with ovarian carcinoma<sup>6</sup>. Endometriosis and epithelial carcinoma of the ipsilateral ovary have been associated in 2.5% of patients. The women with endometriosis have a 1.7 times higher risk of ovarian cancer than the women without endometriosis. The nulliparous women with endometriosis have a three times increased risk of ovarian cancer than the women who have given birth<sup>2</sup>. Our patient had a history of infertility which was assessed and had been treated. Endometrioid tumours constitute 15%–25% of epithelial ovarian carcinomas. Clear cell subtype constitutes 5%–25% of epithelial ovarian carcinomas. The mixed clear cell/endometrioid subtype constitutes 1.3% of all ovarian carcinomas. There are 30% to 40% of women who have an endometrioid carcinoma associated with endometriosis, while this frequency is 30%–55% in the women with clear cell carcinoma<sup>5,7</sup>. The mechanism by which endometriosis influence the development of ovarian carcinoma is unknown. The molecular level research has identified oxidative stress, inflammation and hyperestrogenism as important mechanisms by which endometriosis may lead to ovarian carcinoma. Due to repeated hemorrhage, heme and free iron accumulate in the endometriotic lesion, leading to the production of oxydative stress, which creates a hypoxic environment that promotes the DNA damage and mutation accumulation. These events play a role in pathophysiology of ovarian carcinoma<sup>2</sup>. Endometriosis is characterized by genetic instability: like neoplasms endometriosis seems to be monoclonal in origin, Advances in genetic have led to the discovery of new mutations and a better understanding of the function of genes and pathways associated with EAOCs<sup>8</sup>. Tumor suppressor genes that were identified as contributors to the development of EAOCs include TP53, PTEN, and ARID1A as well as a proto-oncogene KRAS. ARID1A mutation (AT rich interactive domain 1A) was seen in 46% of ovarian clear-cell carcinomas and in 30% endometrioid carcinomas and was described as a possible early evant in the malignant transformation of endometriosis into carcinoma<sup>9,10</sup>. The TP53 mutations were seen in 30% of endometriosis associated with clear-cell carcinomas. Hence, the TP53 abnormalities may be involved in malignant transformation of ovarian endometriosis. Some studies suggest that mutation of the tumor suppressor gene PTEN play a part in the malignant transformation of endometriosis<sup>11</sup>. Furthermore, inflammation also has a role in the development of EAOCs. Some studies showed that the peritoneal fluid of women with endometriosis had the increased levels of proinflammatory cytokines and growth factors such as TNF- $\alpha$ , IL-1, IL-6 and IL-8, but these women also had the serum inflammatory markers comparable to those found in the women with ovarian carcinoma<sup>12</sup>. IL-1 may upregulate the

COX2 gene expression leading to the increased secretion of PGE<sub>2</sub>; PGE<sub>2</sub> stimulates processes that are characteristic of tumor growth such as angiogenesis, cell proliferation and inhibition of apoptosis. The women with a positive family history for colon cancer or endometrial cancer (Lynch syndrome 2) or hereditary nonpolyposis colorectal carcinoma, have an increased risk of endometrioid ovarian cancer<sup>13</sup>. The women who have mutations in BRCA1 or BRCA2 genes on chromosome 17 and 13 have an increased risk of breast and ovarian carcinomas<sup>14</sup>. The prognosis of EAOC is good at the early stage of the disease. The treatment options include surgical management and chemotherapy, either as

separate modalities or in combination<sup>7</sup>. Our patient was treated both surgically and with chemotherapy. Six months after the treatment completion, the patient felt well without the disease recurrence.

### Conclusion

Clear cell and endometrioid subtypes of ovarian carcinoma have good prognosis if they are diagnosed and treated at an early stage of the disease. In our patient, the carcinoma was detected in the first stage and successfully treated with combination therapy, i.e., surgical and chemotherapy.

### R E F E R E N C E S

1. *Lyttle B, Bernardi L, Pavone ME*. Ovarian cancer in endometriosis: Clinical and molecular aspects. *Minerva Ginecol* 2014; 66(2): 155–64.
2. *Forté A, Cipollaro M, Galderisi U*. Genetic, epigenetic and stem cell alterations in endometriosis: New insights and potential therapeutic perspectives. *Clin Sci* 2014; 126(2): 123–38.
3. *Pavone ME, Lyttle BM*. Endometriosis and ovarian cancer: Links, risks, and challenges faced. *Int J Womens Health* 2015; 7: 663–72.
4. *Jemal A, Bray F, Center MM, Ferlay J, Ward E, Forman D*. Global cancer statistics. *CA Cancer J Clin* 2011; 61(2): 69–90.
5. *Wang S, Qiu L, Lang JH, Shen K, Yang JK, Huang MF, et al*. Clinical analysis of ovarian epithelial carcinoma with coexisting pelvic endometriosis. *Am J Obstet Gynecol* 2013; 208: 413.e1–413.e5.
6. *Burghaus S, Häberle L, Schrauder M, Heusinger K, Thiel F, Hein A, et al*. Endometriosis as a risk factor for ovarian or endometrial cancer—results of a hospital-based case control study. *BMC Cancer* 2015; 15: 751.
7. *Noli S, Cipriani S, Scarfone G, Villa A, Grossi E, Monti E, et al*. Long term survival of ovarian endometriosis associated clear cell and endometrioid ovarian cancers. *International journal of gynecological cancer* 2013; 23(2): 244–8.
8. *Ma X, Hui Y, Lin L, Wu Y, Zhang X, Qin X*. Possible relevance of tumor-related genes mutation to malignant transformation of endometriosis. *Eur J Gynaecol Oncol* 2016; 37(1): 89–94.
9. *Suryavanshi S, Huang X, Elishaev E, Budiu RA, Zhang L, Kim S, et al*. Complement pathway is frequently altered in endometriosis and endometriosis-associated ovarian cancer. *Clin Cancer Res* 2014; 20(23): 6163–74.
10. *Borrelli GM, Abrão MS, Taube ET, Darb-Esfahani S, Köbler C, Chiantera V, et al*. (Partial) Loss of BAF250a (ARID1A) in rectovaginal deep-infiltrating endometriosis, endometriomas and involved pelvic sentinel lymph nodes. *Mol Hum Reprod* 2016; 22(5): 329–37.
11. *Rechsteiner M, Zimmermann A, Wild PJ, Caduff R, Teichman A, Fink D, et al*. TP53 mutations are common in all subtypes of epithelial ovarian cancer and occur concomitantly with KRAS mutations in the mucinous type. *Exp Mol Pathol* 2013; 95(2): 235–41.
12. *Worley MJ, Lin S, Hua Y, Kvoek JS, Samuel A, Hou L, et al*. Molecular changes in endometriosis-associated ovarian clear cell carcinoma. *Eur J Cancer* 2015; 51(13): 1831–42.
13. *Helder-Woolderink JM, Blok EA, Vasen HFA, Hollema H, Mourits MJ, De De Bock GH*. Ovarian cancer in Lynch syndrome: as systematic review. *Eur J Cancer* 2016; 55: 65–73.
14. *Teixeira N, Mourits MJ, Vos JR, Kolk DM, Jansen L, Oostervijk JC, et al*. Ovarian cancer in BRCA1/2 mutation carriers: The impact of mutation position and family history on the cancer risk. *Maturitas* 2015; 82(2): 197–202.

Received on December 15, 2016.

Revised on March 02, 2017.

Accepted on March 03, 2017.

Online First March, 2017.