



## Unilateral agenesis of the right ovary and Fallopian tube in an infertile patient with a normal uterus

Jednostrana agenezija desnog jajnika i jajovoda kod infertilne pacijentkinje sa normalnom matericom

Ivana Rudić Biljić-Erski\*, Mladenko Vasiljević\*<sup>†</sup>, Snežana Rakić\*<sup>†</sup>,  
Sladjana Mihajlović\*<sup>†</sup>

\*Clinic of Gynecology and Obstetrics “Narodni Front”, Belgrade, Serbia;  
University of Belgrade, <sup>†</sup>Faculty of Medicine, Belgrade, Serbia

### Abstract

**Introduction.** Unilateral ovarian and Fallopian tube agenesis is an extremely rare anomaly that is usually associated with uterine and renal anomalies. This anomaly is usually incidentally detected during laparoscopy or laparotomy performed for other indications. We have reported a rare case of unilateral ovarian and Fallopian tube agenesis in an infertile patient with a normal uterus. **Case report.** A 34-year-old infertile patient was admitted to our clinic for laparoscopy and hysteroscopy, indicated for the right Fallopian tube occlusion and an endometrial polyp. The patient underwent laparoscopy and hysteroscopy. Unilateral right ovarian and Fallopian tube agenesis was diagnosed during laparoscopy. Upon exploration of peritoneal surfaces, omentum and intestinal serosa, neither ectopic nor remnant tissues of the ovary or Fallopian tube were found. Renal anomalies were not identified on the ultrasound examination. The hormone panel and karyotype were normal. Her partner's semen analysis was normal. The patient conceived spontaneously one year later. Serial ultrasound examinations showed normal fetal intrauterine growth and development. The patient vaginally delivered a live, female newborn at 40 weeks' gestation, weighing 3,350 grams, 53 cm long, with 9/10 Apgar scores at birth. The patient and her newborn were discharged home on the third postpartum day. **Conclusion.** Unilateral ovarian and Fallopian tube agenesis is rarely associated with a normal uterus. Laparoscopy is the gold standard in the diagnosis of ovarian and Fallopian tube agenesis. Unless other obstetric indications are present, this anomaly is not specific and it is not an indication for a Caesarean section, and vaginal delivery is a possibility at term pregnancy.

### Key words:

congenital abnormalities; diagnosis; fallopian tubes; infertility; laparoscopy; ovary.

### Apstrakt

**Uvod.** Jednostrana agenezija jajnika i jajovoda je ekstremno retko stanje i obično je udružena sa anomalijama materice i bubrega. Ova anomalija se obično otkriva slučajno na laparoskopiji i laparotomiji, koje se izvode zbog nekih drugih ginekoloških i opstetričkih razloga. Prikazali smo redak slučaj jednostrane agenezije jajnika i jajovoda kod infertilne pacijentkinje sa normalnom matericom. **Prikaz bolesnika.** Pacijentkinja stara 34 godine, sa primarnim infertilitetom, primljena je na našu kliniku za laparoskopiju i histeroskopiju zbog okluzije levog jajovoda i endometrijalnog polipa u šupljini materice. Urađena je laparoskopija i histeroskopija. Na laparoskopiji je dijagnostikovana unilateralna agenezija desnog jajnika i desnog jajovoda, sa normalnom matericom. Pri eksploraciji peritonealnih površina, omentuma i serozecreva nije nađeno ektopično tkivo ni za ostalo tkivo jajnika i jajovoda. Ultrazvučnim pregledom urinarnog trakta isključene su anomalije bubrega. Hormonske analize i kariotip kod pacijentkinje su bili normalni. Spermogram partnera je bio uredan. Godinu dana kasnije pacijentkinja je spontano ostala trudna. Serijskim ultrazvučnim pregledima u toku trudnoće dijagnostikovano je normalni intrauterusni razvoj ploda. Pacijentkinja se porodila u 40. nedelji trudnoće, spontano, vaginalnim imputem. Rodila je žensko, živo novorođenče, telesne mase 3,350 gr, dužine 53 cm, Apgar score 9/10 na rođenju. Pacijentkinja je zajedno sa novorođenčetom treći dan posle porođaja otpuštena kući. **Zaključak.** Jednostrana agenezija jajnika i jajovoda je retko udružena sa normalnom matericom. Laparoskopija predstavlja zlatni standard za dijagnozu agenezije jajnika i jajovoda. Ukoliko ne postoje druge akušerske indikacije za carski rez, ova anomalija nije indikacija *per se* za carski rez i moguć je vaginalni porođaj u terminskoj trudnoći.

### Ključne reči:

anomalije; dijagnoza; jajovodi; neplodnost; laparoskopija; jajnik.

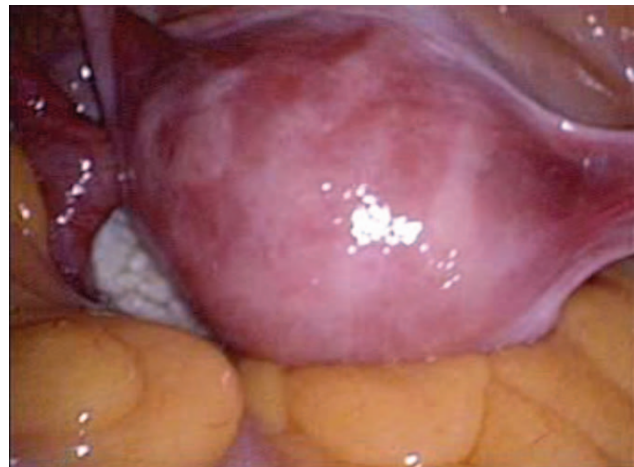
## Introduction

Unilateral ovarian and Fallopian tube agenesis is a very rare anomaly with an unknown incidence. In the article printed in 1986, Sivanesaratnom<sup>1</sup> reported the incidence of 1 in 11,240 women. The research is limited and knowledge pertaining to this anomaly is based mostly on case reports<sup>2</sup>. Three hypotheses are postulated in the etiology of ovarian and Fallopian tube agenesis. Firstly, it is hypothesized that adnexal torsion during fetal or early neonatal period may be the cause of this anomaly. Secondly, anomalous embryologic development of the gonadal ridge and upper ends of Mullerian ducts may also be involved in etiology of this anomaly. The third etiologic factor may be a vascular accident with ischemic injuries to the upper ends of Mullerian ducts during embryologic development<sup>3,4</sup>. Since it is asymptomatic, this anomaly is most commonly an incidental finding during laparoscopy or laparotomy indicated for other obstetric/gynecologic conditions. It is thought that this anomaly can decrease a woman's fertility. However, it is not considered the cause of primary infertility if the contralateral Fallopian tube is patent.

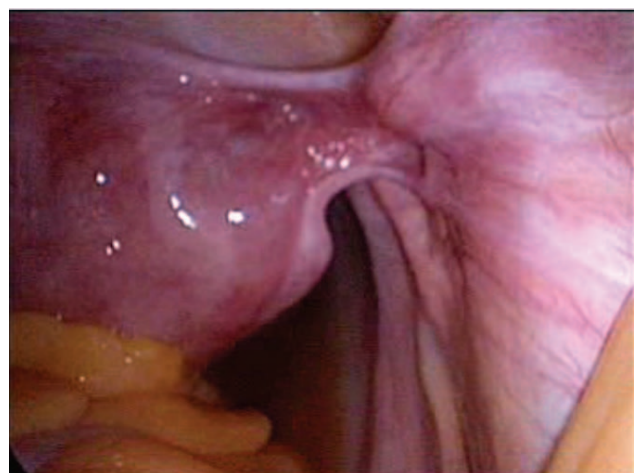## Case report

We reported a case of a 34-year-old patient with primary infertility, who was admitted to our clinic for laparoscopic and hysteroscopic surgery, indicated for the right Fallopian tube occlusion and an endometrial polyp. Her menstrual cycles were regular, occurring every 26 to 28 days; menarche occurred at 14 years of age. The patient was trying to conceive for the past year. There was no history of previous pelvic or abdominal surgeries and no history of acute pelvic pain. The uterine cavity was morphologically normal and the left Fallopian tube patent on hysterosalpingography, but the right Fallopian tube was not seen. An endometrial polyp was suspected after a transvaginal ultrasound was performed. Hormone panel was within normal reference ranges. The partner's semen analysis was normal. Upon admission to our clinic, pelvic examination and ultrasound were performed. The pelvic exam revealed normal appearance of the external genitalia, cervix and vagina. On bimanual examination, a normal and mobile uterus was palpated; the left ovary was palpable, while the right ovary could not be palpated. Transvaginal ultrasound demonstrated an anteverted and anteflexed uterus, measuring 50 x 33 x 27 mm, with a focal 5 x 5 mm endometrial thickening resembling an endometrial polyp; the left ovary had a normal appearance, measuring 28 x 20 mm, while the right ovary was not visualized. The patient underwent diagnostic laparoscopy and hysteroscopy. Upon the hysteroscopic exploration, a normal endometrial cavity, without a polyp, was seen, and the endometrium was biopsied; the left tubal ostium was visible, while the right tubal ostium was not visible. Pathohistology of the endometrial biopsy demonstrated a proliferative phase endometrium. Laparoscopy demonstrated the uterus of normal size and shape as well as normal appearance of the left ovary and Fallopian tube (Figure 1). However, the right

ovary and Fallopian tube were absent (Figure 2). The infundibulopelvic, broad, round and cardinal ligaments were normal. The vesicouterine and the pouch of Douglas peritoneum had a normal appearance. The omentum had a normal appearance and adhesions were not seen in the pelvic cavity. Neither ectopic nor remnant ovarian and Fallopian tube tissues were seen on the omentum, peritoneal and serosal surfaces. Transcervical chromopertubation with methylene blue revealed a patent left Fallopian tube. On the first postoperative day, abdominal and urinary tract ultrasounds were performed, and did not reveal any abnormalities. Both kidneys were of normal size and contours in their usual anatomic location. The patient was discharged home. Her karyotype was normal. One year postoperatively, the patient conceived spontaneously. Serial first, second and third trimester ultrasounds confirmed a normal pregnancy with normal fetal growth and development, normal insertion of the placenta and amniotic fluid volume. Doppler flow ultrasound of the uteroplacental, umbilical and cerebral circulation was normal. At 40 weeks of pregnancy, the patient delivered vaginally a live healthy female newborn, weighing 3,350 grams, 53 cm long, with 9/10 Apgar score at birth. The mother and newborn were discharged home on the third postpartum day.



**Fig. 1 – Laparoscopic appearance of a normal uterus with the left ovary and Fallopian tube.**



**Fig. 2 – Laparoscopic appearance of a normal uterus, the right ovary and Fallopian tube are absent.**

## Discussion

In terms of anatomy and function, the ovary and Fallopian tube are closely associated, but their embryologic origins differ. The upper ends of Mullerian ducts produce Fallopian tubes, while the ovaries arise from the gonadal ridge<sup>5</sup>. Except for streak ovaries, occurring in cases of gonadal dysgenesis, other ovarian anomalies are very rare. The complete absence of an ovary is very rare, and is usually associated with ipsilateral Fallopian tube and renal agenesis. Fallopian tube anomalies are usually asymptomatic, and the absence of one Fallopian tube is usually associated with uterine anomalies, most commonly unicornuate uterus. Mullerian duct anomalies can coexist with gonadal anomalies. We reported a case of a patient with primary infertility who was laparoscopically diagnosed with unilateral agenesis of the right ovary and Fallopian tube, while her uterine and renal anatomy was normal. After attempting for one year, the patient was unable to conceive despite regular sexual intercourse and normal semen analysis. Since the research is solely based on case reports, the exact incidence of unilateral ovarian and Fallopian tube agenesis is unknown. Only a few cases have been reported in the literature, and the majority of authors cite the incidence as reported by Sivanestarnam<sup>1</sup>, who found the incidence of unilateral ovarian and Fallopian tube agenesis to be 1 in 11,240 women based on two cases at one centre. This anomaly is usually asymptomatic and incidentally detected during laparoscopy or laparotomy performed for other obstetric and gynecologic indications. Unilateral adnexal agenesis is commonly associated with uterine malformations, such as unicornuate uterus and unilateral renal agenesis. A case of women with unicornuate uterus and unilateral ovarian agenesis was reported by Stuti et al.<sup>6</sup>. Unilateral agenesis of the ovary and Fallopian tube can occur in the presence of a normal uterus and kidneys. Our patient had a normal uterus and kidneys. Chen et al.<sup>7</sup> reported a case of an infertile patient with a normal uterus and unilateral agenesis of the left ovary and Fallopian tube. At the time of Caesarean section of a multiparous patient, Maurya and Gupta<sup>8</sup> found unilateral right ovarian and Fallopian tube agenesis without uterine and renal anomalies. A case of an infertile patient with unilateral left ovarian, Fallopian tube and round ligament agenesis in the presence of normal uterus and kidneys was reported by Rastogi et al.<sup>9</sup>.

The etiology of unilateral ovarian and Fallopian<sup>3</sup> tube agenesis is unknown. Three hypotheses regarding the etiology are postulated in the literature. Adnexal torsion, leading to ischemia, necrosis and organ resorption, during fetal or the early neonatal period is considered as a potential etiologic factor. However, adnexal torsion is also possible during childhood. The symptoms of adnexal torsion may be minimal, and may not present typically with acute pain in the lower abdomen. Remnant ovarian tissue residing on the omentum was found in a patient with unilateral left ovarian and distal Fallopian tube agenesis, which would support the previously described hypothesis<sup>3</sup>. Furthermore, this hypothesis is also supported by a case reported by Yerebasmaz et al.<sup>10</sup> who described left ovarian and Fallopian tube agenesis

with remnant ovarian and tube tissues on the intestinal serosa. Anomalous embryologic development of the gonadal ridge and upper ends of Mullerian ducts may also play a role in the etiology of unilateral adnexal agenesis. The next hypothesis postulates a vascular accident as an etiologic factor of unilateral adnexal agenesis. Namely, ischemia of the upper ends of mullerian ducts during embryologic development can lead to autocrine and paracrine dysregulation, which may lead to gonadal agenesis and tubal malformation<sup>4</sup>. Disturbance in embryologic development is the least likely in our case since we did not find congenital anomalies of other organs and the patient did not have a history of acute abdomen. For this reason, we are considering a vascular accident as a potential etiologic factor of unilateral ovarian and Fallopian tube agenesis in our patient. Despite the lack of history of acute abdominal pain, we cannot rule out with certainty adnexal torsion during the fetal period. Our patient had a normal karyotype, which rules out aberrant chromosomes that would be potentially associated with this anomaly. Unilateral adnexal agenesis is rarely associated with primary infertility. Nevertheless, this anomaly was discovered in numerous patients who underwent infertility investigations. Unilateral agenesis of the right ovary and Fallopian tube were discovered in a patient with primary infertility by Sukhadiya and Grover<sup>11,10</sup>. Unilateral agenesis of the left ovary and tube in an infertile patient with a normal uterus was reported by Chen et al.<sup>7</sup>. Fruzzetti et al.<sup>12</sup> reported the case of a nulliparous patient, who was undergoing laparoscopic surgery for an ovarian teratoma, and at the time of this surgery, unilateral adnexal agenesis was discovered. Barsky et al.<sup>2</sup> reported two cases of unilateral ovarian and Fallopian tube agenesis in nulliparous patients, who were undergoing surgery for the contralateral ovary. The first case involved agenesis of the left adnexa, while the second case involved the agenesis of the right adnexa; the existing ovaries were removed in both cases leading to premature menopause. A study by Yerebasmaz et al.<sup>10</sup> reported four cases of nulliparous patients with the ovarian and Fallopian tube agenesis. The first case involved a patient with unilateral right adnexal agenesis. The second case was that of the left ovarian and Fallopian tube agenesis, with remnants of the fimbrial and ovarian tissue, measuring 5 x 5 mm on the intestinal serosa. The third case was a patient with the left ovarian and Fallopian tube agenesis. The fourth case was patient with the right unicornuate uterus and right ovarian agenesis. Whether unilateral adnexal agenesis could contribute to infertility is a conundrum. There is a lot of controversy among researchers and clinicians. On one hand, researchers believe that unilateral adnexal agenesis cannot contribute to infertility unless it is associated with uterine malformations. On the other hand, researchers believe that unilateral adnexal agenesis can contribute to infertility, but that conception is possible if the contralateral adnexa are functional. This statement is reinforced by case reports, which describe patients with unilateral adnexal agenesis, but who achieved normal pregnancies ending in deliveries. Erkilinc et al.<sup>13</sup> reported an incidentally discovered case of unilateral Fallopian tube agenesis in a patient undergoing Caesarean section. A case of multigravida with unilateral

right adnexal agenesis, normal uterus and kidneys discovered during a Caesarean section was reported by Maurya and Gupta<sup>8</sup>.

### Conclusion

Unilateral agenesis of the ovary and Fallopian tube with a normal uterus and kidneys is a very rare anomaly. More commonly, this anomaly is associated with a unicornuate uterus and ipsilateral renal agenesis. Unilateral adnexal

agenesis is usually asymptomatic and incidentally discovered in fertile and infertile women during laparoscopy or laparotomy performed for other obstetric and gynecologic indications. This anomaly does not cause infertility, but it is contemplated that it can lead to decreased fertility. Laparoscopy is the gold standard in the diagnosis of ovarian and Fallopian tube agenesis. Unless other obstetric indications are present, this anomaly is not specific and it is not an indication for a Caesarean section, and vaginal delivery is a possibility at term pregnancy.

### R E F E R E N C E S

1. *Sivanesaratnom V*. Unexplained unilateral absence of ovary and fallopian tube. *Eur J Obstet Gynecol Reprod Biol* 1986; 22(1–2): 103–5.
2. *Barsky M, Beaulieu AM, Sites CK*. Congenital ovarian-fallopian tube agenesis predisposes to premature surgical menopause: A report of two cases. *J Androl Gynaecol* 2015; 3(1): 3.
3. *Uckayıu A, Ozçimen EE, Sevinciftci FC*. Unilateral congenital ovarian and partial tubal absence: Report of four cases with review of the literature. *Fertil Steril* 2009; 91(3): 936.e5–8.
4. *Pabuccu E, Kahraman K, Taskın S, Atabekoglu C*. Unilateral absence of fallopian tube and ovary in an infertile patient. *Fertil Steril* 2011; 96(1): e55–7.
5. *Sadler TW*. Langman's medical embryology. 13th ed. Philadelphia, Pennsylvania: Wolters Kluwer Health; 2015.
6. *Stuti T, Suchitra J, Surinder S, Pragya Y*. An incidental finding of unicornuate uterus with unilateral ovarian agenesis and ipsilateral twining of fallopian tubes during cesarean. *JARMS* 2015; 7(1): 11–3.
7. *Chen B, Yang C, Sahebally Z, Jin H*. Unilateral ovarian and Fallopian tube agenesis in an infertile patient with a normal uterus. *Exp Ther Med* 2014; 8(3): 831–5.
8. *Maurya NR, Gupta AS*. A case of unilateral complete absence of fallopian tube and ovary. *JPGO* 2015; 3: 1.
9. *Rastogi R, Gupta Y, Gupta B, Sinha P, Chaudbary M, Parasbar S, et al*. Unilateral agenesis of adnexa: A rare clinico-radiological condition. *J Med Diagn Meth* 2016; 5: 228.
10. *Yerebasmaz N, Dilbaz B, Sengül Ö, Altınbaş S, Çakır L*. Four cases with congenital unilateral absence of ovary and fallopian tube: Review of the literature. *J Clin Anal Med* 2016; 7(Suppl 3): 275–8.
11. *Sukbadiya M, Grover SV*. Unexplained unilateral absence of fallopian tube and ovary: A rare occurrence. *J South Asian Feder Menopause Soc* 2014; 2(1): 46–7.
12. *Fruzzetti F, Bucci F, Perini D, Gadducci A*. Unilateral adnexal agenesis and dermoid cyst: Fertility implications. *Gynecol Endocrinol* 2015; 31(6): 438–40.
13. *Erkilinc S, Güzel AI, Doganay M, Özer I, Ümit C*. Incidental unilateral tubal absence detected during cesarean section: Report of a case. *Gynecol Obstet Reprod Med* 2014; 20: 60–1.

Received on February 13, 2017.

Revised on April 21, 2017.

Accepted on July 6, 2017.

Online First September, 2017.