



## Anatomic study of septocutaneous system of the human fetuses' lower leg: posterior tibial artery

Anatomska studija septokutanog sistema donjeg ekstremiteta fetusa:  
*arteria tibialis posterior*

Goran R. Stevanović\*, Marija Z. Daković-Bjelaković†, Boban Djordjević§§,  
Jadranka M. Paravina\*, Ivan Z. Golubović||, Irena D. Janković\*, Milan D.  
Radojković¶, Milica D. Nestorović¶, Nebojša S. Ignjatović¶, Miljan S. Krstić\*\*

Clinical Center Niš, \*Clinic for Plastic, Reconstructive and Aesthetic Surgery;  
†Department of Orthopedics and Traumatology, †Clinic for General Surgery,  
\*\*Department of Pathology, Niš, Serbia; University of Niš, Faculty of Medicine,  
‡Department of Anatomy, Niš, Serbia; Military Medical Academy, ‡Clinic for Plastic  
Surgery and Burns, Belgrade, Serbia; University of Defence, §Faculty of Medicine of the  
Military Medical Academy, Belgrade, Serbia

### Abstract

**Background/Aim.** Lower-leg septocutaneous system of perforating blood vessels represents the vascular basis of fasciocutaneous flaps. Additionally, it is of a particular importance when designing distally based fasciocutaneous flaps which represent the “workhorse” in the reconstruction of the distal third of the lower leg and foot. The aim of this study was to analyse the vascular anatomy of posterior tibial artery and its septocutaneous (fasciocutaneous) perforating arterial vessels. **Methods.** The dissection was conducted on 20 fetuses of both sexes and of gestational age from 20 to 28 weeks. Cluster analysis was applied to the data on vascular anatomy of posterior tibial artery and its septocutaneous perforating arterial vessels. **Results.** A total of 212 perforating arterial vessels was identified. The average number of perforating arterial vessels was 5.32 (ranging from 4 to 7). It

was identified that septocutaneous perforating blood vessels are more likely to be found at certain levels (“safe levels of finding perforators”). These are: second, third, fifth and sixth tenth (measured as a distance from intermalleolar line to popliteal crease). **Conclusion.** The presence of septocutaneous system of perforating blood vessels and reliability of their localization even in the fetal period allows application of these findings in the lower leg reconstructions in children of early age. It also contributes to the greater level of understanding of anatomy of the lower-leg vascular system. Finally, it provides a basis for understanding the development of this system as it is now possible to compare results obtained on fetuses with those obtained on adults.

**Key words:**  
anatomy; fetus; leg; surgical flaps; tibial arteries.

### Apstrakt

**Uvod/Cilj.** Perforatori septokutanog sistema krvnih sudova potkolenice predstavljaju vaskularnu osnovu fasciokutananih režnjeva. Poseban značaj imaju pri dizajniranju distalno baziranih fasciokutananih režnjeva koji predstavljaju moćnu metodu u rekonstrukciji defekata distalne trećine potkolenice i stopala. Cilj rada bio je detaljno kvantitativno ispitivanje vaskularne anatomije zadnje tibijalne arterije i njenih septokutananih (fasciokutananih) perforatora. **Metod.** Istraživanje je sprovedeno na 20 fetusa oba pola gestacione starosti 20–28 nedelja. Primenom „Cluster” analize, obradjeni su podaci dobijeni u ovom istraživanju. **Rezultati.** Ukupan broj

septokutananih perforatora iznosio je 212. Prosečan broj perforatnih krvnih sudova (arterijskih) bio je 5,32 (minimum 4, maksimum 7). Istraživanje je pokazalo da je verovatnoća nalazanja septokutananih perforatora bila veća na određenim nivoima (tzv. „sigurni nivoi nalazanja perforatora”). To su: druga, treća, peta i šesta desetina (mereno kao distanca od intermalleolarne linije do zatkolene brazde). **Zaključak.** Prisustvo perforatora septokutanog sistema krvnih sudova i pouzdanost njihove lokalizacije još u fetalnom periodu omogućava primenu ovih nalaza u rekonstrukciji potkolenice i stopala već kod dece. Ovo istraživanje takođe doprinosi dubljem razumevanju anatomije vaskularnog sistema potkolenice. Ono obezbeđuje osnovu razumevanja razvoja ovog

sistema krvnih sudova i mogućnost poređenja rezultata dobijenih istraživanjima na fetusima sa rezultatima dobijenih kod odraslih.

**Ključne reči:**  
anatomija; fetus; noga; režnjevi, hirurški;  
aa. tibiales.

## Introduction

Discovery of fasciocutaneous blood vessels system of the lower leg by Ponten<sup>1</sup> in the eighties of the last century resulted in more profound understanding of skin vascularization. The main arteries of the body were reexamined with an emphasis on the perforating branches which provide direct skin vascularization. Flaps, that are based on the blood vessels passing through the septum duplication in the lower leg, consist of skin, subcutaneous adipose tissue, and deep fascia and are named fasciocutaneous flaps<sup>2,3</sup>. They can be either direct or indirect flaps<sup>4</sup>. The initial advancement in this area was followed by a period when numerous studies on this blood vessels system were conducted. This period was marked by two distinct pathways: solving disagreements and confusion in the nomenclature of perforator flaps and further exploration and understanding of new concepts of perforator flaps<sup>5</sup>.

From the practitioners' point of view, a discovery of this type of flaps was especially important because of its structural characteristics and lack of reliable flap locations for lower leg area<sup>6</sup>. Patient studies showed that flaps are the best choice when it comes to the lower leg reconstruction. The greatest advantages are the simplicity of the procedure, very high success rate and relatively small number of minor disadvantages. Furthermore, the procedure can be applied to wounds of different origin (e.g., fourth degree burn injuries, blast and high-velocity projectile wounds, distal tibial fracture) and injuries of various size, location and depth<sup>7</sup>.

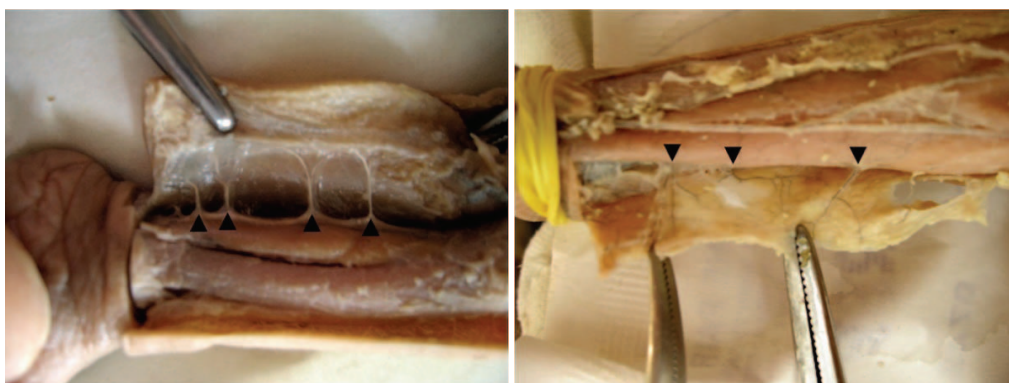
Numerous anatomical studies on cadavers were carried out in order to determine the localization of perforating blood vessels of the main lower-leg arterial trunk. The results, although often significantly different, were of a great help in planning and designing the distally based flaps of the lower leg ("separated asseptocutaneous perforators of the lower leg"). However, studies on fetuses that would shed some light on the vascular anatomy of this system of blood vessels are very rare and often inconclusive, despite the fact that pediatric cases are more complicated<sup>8,9</sup> and require further theoretical knowledge. The aim of this study was to pro-

vide a comprehensive, clear and conclusive overview of the lower-leg septocutaneous system of skin blood supply in fetal age. The results were statistically analyzed in order to enable comparison with other studies of this kind. Implications of this article go beyond contribution to the theoretical knowledge, as the information provided can be applied to cases of lower leg reconstruction in children.

## Methods

The study was conducted on 40 lower extremities from 20 human fetuses. The fetuses were prepared by fixation in 10% formalin and blood vessels of 10 fetuses were injected with Micropaque solution (barium sulfate) (Merck, Darmstadt, Germany) for better visualization. Fetuses were collected in the Department of Anatomy between 1962 and 1985. All fetuses were medico-legally obtained from the Clinic of Gynecology and Obstetrics of the Faculty of Medicine in Niš, Serbia. The study was approved by the Ethics Committee of the Faculty of Medicine, University Niš, Serbia (permission from 22.9.2016). No established anatomical deformities or systematic diseases were recorded.

Fetal age ranged from the third to the ninth lunar month and was established by measuring crown-rump length. Microdissection of the fetal lower extremities was performed under 5× magnifying lenses. Two horizontal cuts and one vertical cut of the skin were made (Figure 1). The first horizontal cut was made at the level of the popliteal fold and the second was made at the level of the medial and lateral malleolus (Figure 1). The vertical cut extended from the middle of the upper horizontal cut at the level of the popliteal fold to the middle of the lower horizontal cut. After that, the dissection was going through the skin, subcutaneous tissue, and fascia, and then carefully continued medially and laterally until reaching medial and lateral septum of the lower leg. There, we noted the origin of arterial septocutaneous vessels from the posterior tibial artery. Also, we could clearly measure the distance from the lower horizontal cut to the origin of perforating vessels. Characteristic cases were photographed (Figure 1).



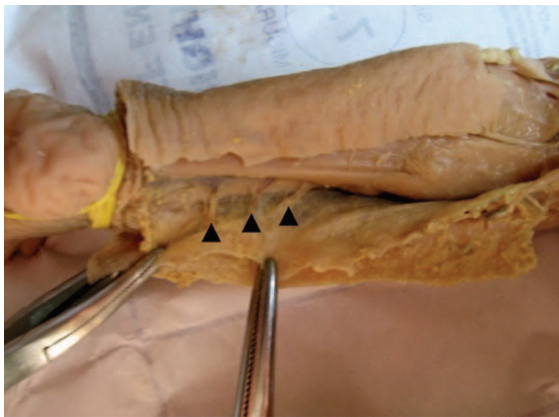
**Fig. 1 – Posterior tibial artery perforators (fetal dissections with injected contrast).**

### Data analysis

Cluster analysis was conducted on the raw data obtained from the primary research. The portable IBM SPSS Statistics v19 was used. K-means cluster analysis was conducted. Due to the small data set, the number of iterations was set at 10 in order to determine whether it is possible to run this type of analysis. The SPSS conducted the command without any further notifications, meaning that the data set is large enough. The number of clusters was set at three and clusters were divided on the basis of the number of perforators found in each area of fetuses' lower leg. Clusters were divided into the low, medium and high-density area. Additionally, the cluster membership information was saved.

### Results

The anatomical microdissection of fetal lower legs with (Figure 1) or without contrast injected (Figure 2) was used in order to define the number of septocutaneous perforator vessels and their localization.



**Fig. 2 – Posterior tibial artery perforators (without contrast) from their origin to the deep fascia.**

The examination of septocutaneous perforating vessels of posterior tibial artery confirmed the existence of 4 such vessels in 6 dissections and 5 in 20 dissections. Furthermore,

there were 6 perforating vessels in 9 dissections and in 5 dissections their number was 7 with an average value of 5.32 and with the standard deviation of 0.88 (total of 212 perforating vessels). The septocutaneous perforating vessels of posterior tibial artery originated between the flexor digitorum longus muscle and soleus muscle.

In order to statistically process the data, conduct the subsequent analysis and enable comparability of the results obtained by our research and the results of other similar studies, the fetal lower legs were “divided” into 10 equal parts.

The levels at which perforating blood vessels were encountered as well as the outbreak schedule of perforating vessels of posterior tibial artery and peroneal artery, obtained by dissection of the fetuses, were counted and shown in Table 1.

Finally, the K-means cluster analysis was performed on the data set and the variable of interest was the number of dissections where the perforating vessels of septocutaneous perforating vessels of posterior tibial artery were found (labeled Variable 1). The analysis conducted on Variable 1 showed that, on average, 4 septocutaneous perforating vessels were found in the cluster 1 ( $M = 4$ ), 33 were found in the cluster 2 ( $M = 33$ ) and 22 were found in the cluster 3 ( $M = 22$ ). The analysis also showed that the cluster 2 was represented with 4 cases while the cluster 1 and 3 consisted of 3 cases each. The cluster membership showed that the high density cluster was the cluster 2. The low-density areas (cluster 1) were the first, ninth and tenth 1/10 of the lower leg. The medium-density areas (cluster 3) were fourth, seventh and eighth 1/10 of the lower leg, while the high-density areas were the second, third, fifth and sixth 1/10.

Additionally, the independent samples *t*-test was used in order to determine whether there was a statistically significant difference between distributions of dissections in the areas where perforators were found as observed in adults (in our previous study<sup>10</sup>) and fetuses. Age was used as a grouping variable with the value 1 assigned to adults and value 2 assigned to fetuses. As the number of adult cadavers was higher than the number of fetal cadavers, instead of using absolute values, the test was run on the percentages of the total number of dissections for each of the ten areas.

**Table 1**

**Number (and percentage) of fetuses with the septocutaneous perforating vessels of posterior tibial artery and their percentage per each group**

Septocutaneous perforating vessels*	Dissections where perforators were found (n)	Total number of dissections (%)	Total number of perforators (%)
First	5	12.25	2.36
Second	36	90	16.98
Third	32	80	15.09
Fourth	19	47.5	8.96
Fifth	35	87.25	16.51
Sixth	30	75	14.15
Seventh	19	47.5	8.96
Eighth	27	67.5	12.73
Ninth	6	15	2.83
Tenth	2	5	0.9

\*1/10 length of the lower leg (from intermalleolar line to popliteal crease).

The results of the *t*-test showed that there was no statistically significant difference between adults and fetuses ( $t = 0.146$ ,  $p = 0.866$ ), which means that the distribution of dissections in ten areas where perforators were found was highly similar for the fetal and adult cadavers.

## Discussion

The lower leg area has been a focus of interest of many different research papers and extensive studies. However, knowledge about this body area is still far from complete. While the importance of the topic was recognized, it is still fairly insufficiently researched (for example, the posterior lower leg skin and its vascular anatomy<sup>11–13</sup> illustrate this statement). Implications of such theoretical gaps extend into the practice. Consequentially, numerous challenges arise, such as often quoted poor success rates of lower leg soft tissue reconstruction<sup>14</sup>. A step forward in this area was made with the recognition of importance of fasciocutaneous perforators and flaps. Technology development was one of the biggest obstacles and once when color duplex imaging was introduced, it would become feasible to access deep fascia<sup>7</sup>. Ponten<sup>1</sup> was the first to recognize potential of fasciocutaneous flap when it comes to surgical solutions for soft tissue defects. After that, a long stream of researches followed. Hupkens et al.<sup>13</sup> conducted an anatomical study to localize and classify the lateral lower leg perforators. The same author gave his contribution by researching the medial lower leg perforators, their distribution and characteristics. Apart from anatomical studies focused on the general characteristics, a number of published papers revolved around soft tissue reconstruction and the role of fasciocutaneous flaps in the reconstruction process<sup>7,14–16</sup>. While it is evident that this area of research is becoming more complex and compatible with practical needs, a vast majority of studies was conducted on adults. The studies conducted on children are quite rare (the study by Whaib<sup>9</sup> is one of the very few ones exploring reconstruction of full thickness of soft tissue defect of lower extremities in children<sup>9</sup>) but still more present than the studies on fetuses. We identified a lack of studies conducted on fetuses as a serious research gap. A study undertaken by Ugrenović et al.<sup>17</sup> on neurovascular stalk of the superficial sural flap is one of the few ones conducted on fetuses.

We identified several reasons why this research gap should be bridged. The septocutaneous system of lower leg perforators is already very well developed in the fetal period. There is a rather clear clustering pattern of perforators at different levels which reflects the pattern we find in adults. Having this in mind, as well as the fact that this system represents the vascular basis of fasciocutaneous flaps, we can conclude that the skin and soft tissue defects of distal lower leg area can be taken care of during early childhood by implementing this reconstructive method<sup>18–20</sup>. The significance

of this research lies in the fact that now pre-operative mapping and finding perforators using ultrasound is significantly easier (and it is almost not necessary at all), because the operative method requires presence of at least one reliable perforator and in this study we showed the exact levels of emergence of the most distal perforators. Furthermore, this paper also contributes to increasing the level of understanding of anatomy of the lower-leg vascular system.

The independent samples *t*-test, applied to results of our research obtained in fetuses and adults, confirmed that there is no statistically significant difference between adults and fetuses, which means that the distribution of dissections in ten areas where perforators were found is highly similar for fetal and adult cadavers.

Finally, our research provides a basis for understanding the development of this system as it is now possible to compare results obtained on fetuses with those obtained on adults. Despite the well-known fact that during embryogenesis and fetal development significant changes occur in the number and caliber of the lower leg vascular vessels as well as obliteration of some blood vessels and creation of new ones, the basic model of blood vessels pattern of this system stays rather stable until its final stage of development.

Results of this study is not only of academic importance but also of practical one. Lower leg defects in children can be posttraumatic (motor vehicle accidents, burns, war injuries) or postoperative (after tumor removal). Many factors should be considered in reconstruction of this kind of defects in children. In addition to the lack of children cooperation postoperatively and functional requirements, a surgeon must be aware of anatomical limitations, such as small structures and state of growth and developments of vascular system of the lower leg.

Results obtained in this study clearly show that there is exactly defined the schedule outbreak of septocutaneous perforators of posterior tibial artery.

## Conclusion

Despite the fact that sample size for this kind of analysis is not as huge as it could be, it is sufficient in a way that we can draw some important conclusions: the septocutaneous system of posterior tibial artery is well-established in late fetal age already; there is the precisely defined schedule of septocutaneous perforator's outbreak which is very similar to the pattern we found in adults (there is no statistical difference between these two study groups).

All this means that a reconstructive surgeon can safely use this data to plan reconstruction of almost any kind of the lower leg and foot defects in children, using the fasciocutaneous flaps (perforator flaps, flaps with reverse flow etc.) whose vascularisation relies on the septocutaneous system of vessels.

## R E F E R E N C E S

1. *Pontén B.* The fasciocutaneous flap: Its use in soft tissue defects of the lower leg. *Br J Plast Surg* 1981; 34(2): 215–20.
2. *Humzab MD, Gilbert PM.* Fasciocutaneous blood supply in below-knee amputation. *J Bone Joint Surg Br* 1997; 79(3): 441–3.
3. *Tolhurst D.* Fasciocutaneous Flaps. Rotterdam: Erasmus University; 1988.
4. *Wolff KD.* Perforator flaps: the next step in the reconstructive ladder. *Br J Oral Maxillofac Surg* 2015; 53(9): 787–95.
5. *Geddes CR, Morris SF, Neligan PC.* Perforator flaps: evolution, classification, and applications. *Ann Plast Surg* 2003; 50(1): 90–9.
6. *Mukherjee M, AlamParvaž M, Chakravarty B, Langer V.* Perforator flap: a novel method for providing skin cover to lower limb defects. *Med J Armed Forces India* 2012; 68(4): 328–34.
7. *Bulla A, De Luca L, Campus GV, Rubino C, Montella A, Casoli V.* The localization of the distal perforators of posterior tibial artery: A cadaveric study for the correct planning of medial adipofascial flaps. *Surg Radiol Anat* 2015; 37(1): 19–25.
8. *Chen B, Song H, Gao Q, Xu M.* Pedicled fasciocutaneous flaps for correcting scar contracture in pediatric patients—a retrospective study of 22 cases. *J Pediatr Surg* 2016; 51(7): 1207–15.
9. *Whaib A.* Reconstruction of Full Thickness Soft Tissue Defect Of Lower Extremities In Children. *Tikrit Med J* 2010; 16(2): 134–44.
10. *Stevanović G, Djordjević B, Daković M, Trenkić S, Stojiljković D, Jeremić S,* et al. Fasciocutaneous perforators of the lower leg— anatomic study and clinical significance. *Vojnosanit Pregl* 2010; 67(2): 136–44. (Serbian)
11. *Kosutić D, Pejković B, Anderhuber F, Vahnjal-Donlagić S, Zic R, Gulic R,* et al. Complete mapping of lateral and medial sural artery perforators: anatomical study with Duplex-Doppler ultrasound correlation. *J Plast Reconstr Aesthet Surg* 2012; 65(11): 1530–6.
12. *Hallock GG.* Evaluation of fasciocutaneous perforators using color duplex imaging. *Plast Reconstr Surg* 1994; 94(5): 644–51.
13. *Hupkens P, Westland PB, Schijns W, van Abeelen MHA, Kloeters O, Ulrich DJO.* Medial lower leg perforators: An anatomical study of their distribution and characteristics. *Microsurgery* 2017 37(4): 319–26.
14. *Vaianti L, Leone F, Brioschi M, Marchesi A, Calori GM, Parodi PC.* Posterior tibial artery perforator flaps for coverage of Achilles region defects. *Injury* 2014; 45 Suppl 6: S133–7.
15. *Akhtar MS, Khurram MF, Choudhary R, Khan AH, Ahmad I.* Distally based posterior tibial artery perforator flap for coverage of defects around the ankle, heel and lower third of leg. *Eur J Plast Surg* 2014; 37(10): 547–54.
16. *Yu D, Hou Q, Liu A, Tang H, Fang G, Zhai X,* et al. Delineation the anatomy of posterior tibial artery perforator flaps using human cadavers with a modified technique. *Surg Radiol Anat* 2016; 38(9): 1075–81.
17. *Ugrenović S, Jovanović I, Vasović Lj, Stefanović N, Kovačević P, Stojanović V.* Neurovascular stalk of the superficial sural flap: human fetus anatomical study. *Plast Reconstr Surg* 2005; 116(2): 546–50.
18. *Özalp B, Aydinol M.* Perforator-based propeller flaps for leg reconstruction in pediatric patients. *J Plast Reconstr Aesthet Surg* 2016; 69(10): e205–11.
19. *Guerra AB.* Soft-tissue reconstruction after meningococcal septicemia using a posterior tibial artery perforator flap in a 6-year-old boy. *Pediatr Surg Int* 2005; 21(6): 466–9.
20. *Ver Halen JP, Soto-Miranda MA, Hammond S, Konofaos P, Neel M, Rao B.* Lower extremity reconstruction after limb-sparing sarcoma resection of the proximal tibia in the pediatric population: case series, with algorithm. *J Plast Surg Hand Surg* 2014; 48(4): 238–43.

Received on December 15, 2016.

Revised on March 02, 2017.

Accepted on March 03, 2017.

Online First March, 2017.