



A fatal case of fulminant myocarditis caused by influenza A virus

Fatalni ishod fulminantnog miokarditisa izazvanog virusom influence A

Mila Kovačević*[†], Ilija Srdanović*[†], Milana Jaraković*, Dragana Bogdanović*,
Milenko Čanković*[†]

*Institute of Cardiovascular Diseases of Vojvodina, Sremska Kamenica, Serbia;
University of Novi Sad, [†]Faculty of Medicine, Novi Sad, Serbia

Abstract

Introduction. Myocarditis is defined as an inflammation of a heart muscle, which can be caused by a number of agents, among which viruses are the most common. Fulminant myocarditis is a rapidly progressive, life-threatening myocarditis, followed by the development of cardiogenic shock. Among viruses, there are a number of common ones, but according to our knowledge, there are only a few cases of fulminant myocarditis caused by influenza A virus described in the literature.

Case report. We presented a 44-year-old man who was admitted to the Cardiology Intensive Care Unit because of the clinical as well as electrocardiographic signs pointing to the ST-segment elevated myocardial infarction with peracute development of heart failure and cardiogenic shock and subsequently lethal outcome, despite applied circulatory support. The urgent coronarography showed no signs of coronary artery disease, while the autopsy revealed myocarditis and the real-time polymerase chain reaction of nasopharyngeal swab revealed influenza A(H3) virus. **Conclusion.** Fulminant myocarditis is a life-threatening cardiac disease which should be treated in Intensive Care Units with both medicament and mechanical circulatory support and antiviral therapy and which, despite the applied therapy, has a high mortality rate. Influenza A virus is a rare cause of fulminant myocarditis which should be taken into consideration.

Key words:

diagnosis; influenza a virus; influenza, human; myocarditis; shock, cardiogenic; treatment outcome.

Apstrakt

Uvod. Miokarditis je zapaljenje srčanog mišića izazvano velikim brojem različitih agenasa, među kojima su najčešći virusi. Fulminantni miokarditis je rapidno progresivni, životnougrožavajući miokarditis, koji je praćen razvojem kardiogenog šoka. Različiti virusi su česti uzročnici međutim, u literaturi je, prema našem znanju, opisano samo nekoliko slučajeva fulminantnog miokarditisa izazvanog influenza A virusom. **Prikaz bolesnika.** Prikazali smo bolesnika starog 44 godine, primljenog u Jedinicu intenzivne kardiološke nege zbog kliničkih simptoma i elektrokardiografskih znakova koji su pobudili sumnju na akutni infarkt miokarda sa ST elevacijom. Zbog perakutnog razvoja akutne srčane slabosti do nivoa kardiogenog šoka i pored primenjene cirkulatorne potpore došlo je do fatalnog ishoda. Kod bolesnika je urgentnom koronarografijom isključeno postojanje koronarne bolesti, autopsijom dokazano prisustvo miokarditisa, a „real-time” metodom lančane reakcije polimeraze prisustvo virusa influenza A (H3) u nazofaringealnom brisu. **Zaključak.** Fulminantni miokarditis je teško kardiološko oboljenje koje se leči u jedinicama intenzivne nege medikamentnom i mehaničkom cirkulatornom potporom, uz hitno započinjanje antivirusne terapije koje, i pored primenjene terapije ima visoku stopu mortaliteta. Virus influenza A je redak uzročnik fulminantnog miokarditisa koji treba razmotriti pri postavljanju dijagnoze.

Ključne reči:

dijagnoza; grip a virus; grip; miokarditis; šok, kardiogeni; lečenje, ishod.

Introduction

Myocarditis is defined as an inflammation of a heart muscle, which can be caused by various of external antigens such as viruses, bacteria, parasites, toxins and medications as well as by internal triggers, such as autoimmune activation vs. own antigens^{1,2}.

Viruses are the most common cause of myocarditis. Among viruses, the most common are: enteroviruses including coxsackie virus, adenovirus, parvovirus, hepatitis C virus, human immunodeficiency virus, while others, such as influenza A virus are rare causes of myocarditis, especially in a fulminant form. To our knowledge, there are only few cases of fulminant myocarditis caused by influenza A virus described in the literature³⁻⁶.

Case report

A 44-year-old male patient, previously healthy driver instructor, was admitted to the Cardiology Intensive Care Unit because of short loss of consciousness, nausea and vomiting one hour prior to admission. A history of flu-like symptoms four days prior to admission and profuse sweating night before admission, without measured fever was provided. No history of typical angina-like chest pain was reported.

At admission, the patient was conscious, adequately communicative, oriented, normotensive (120/80 mmHg), tachycardic (heart rate of 120 beats per minute), afebrile (35.9°C), dyspnoic and tachypnoic (respiratory rate of 30 per minute), with signs of a heart failure, Killip class II/III.

An arterial blood gas analyses obtained at admission showed pH 7.38 [normal range (nr) 7.35–7.45], pCO₂ 42 mmHg (nr 35–45 mmHg), pO₂ 65 mmHg (nr 90–100 mmHg), SaO₂ 92%, (nr > 95%), lactate 1.2 mmol/L (nr < 1.0 mmol/L), BE- 0.2 mmol/L (nr -2 to +2 mmol/L).

Electrocardiogram (ECG) at admission showed sinus tachycardia (120 beats per minute) with ST elevation of +2 mm in DII, DIII, aVF, V2-V6 leads (Figure 1). Bedside echocardiography was performed in the Intensive Care Unit, and showed normal dimensions of left ventricle (end-diastolic dimension of 4.5 cm, end-systolic dimension of 3.6 cm), with the presence of diffuse left ventricular hypokinesia, reduced ejection fraction (EF) of 45% (normal EF 50–70%) and a first grade diastolic dysfunction. Right ventricle dimension was normal, without direct or indirect signs of pulmonary hypertension.

Based on the echocardiography, one of the proposed differential diagnoses, acute pulmonary thromboembolism, was excluded. The possible other three differential diagnoses were the acute myocardial infarction, early phase of acute lung injury – pneumonia and myocarditis as well.

Immediately after admission, in order to exclude the acute myocardial infarction, transradial coronary angiography was performed, with only 30 cc of contrast media and with no complications and hemodynamic compromise during the procedure. It showed normal finding (Figure 2).

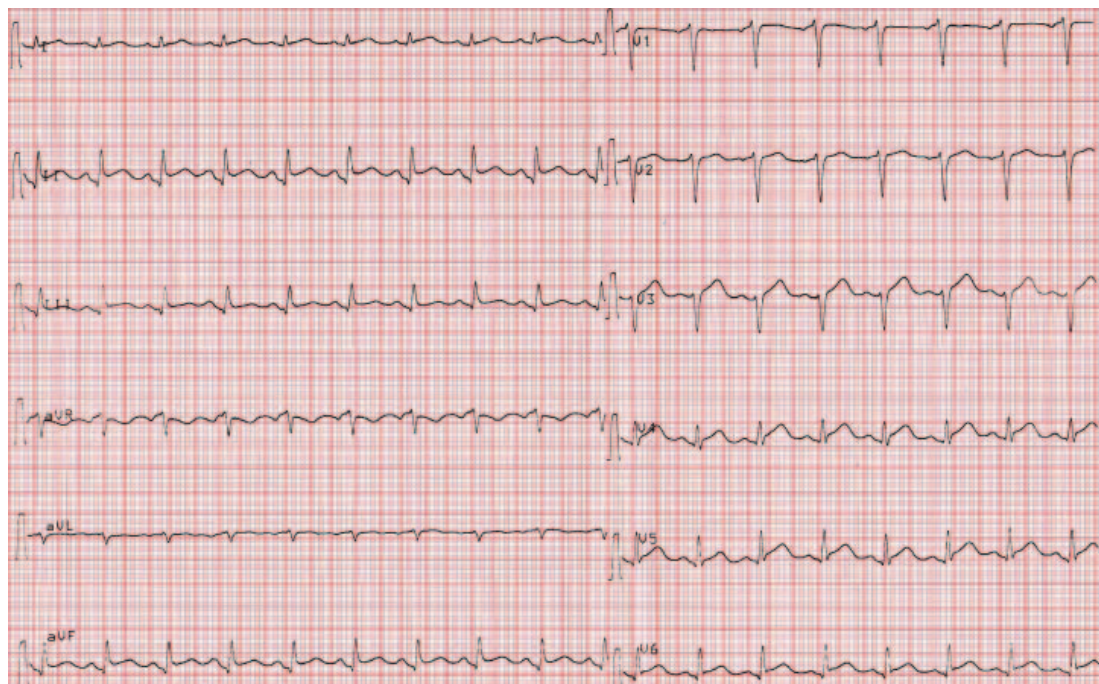


Fig. 1 – Normal coronary angiogram electrocardiogram at admission showed sinus tachycardia (120 beat/min) and ST elevation of +2 mm in diaphragmatic and anteroseptal (V2–V6) leads.

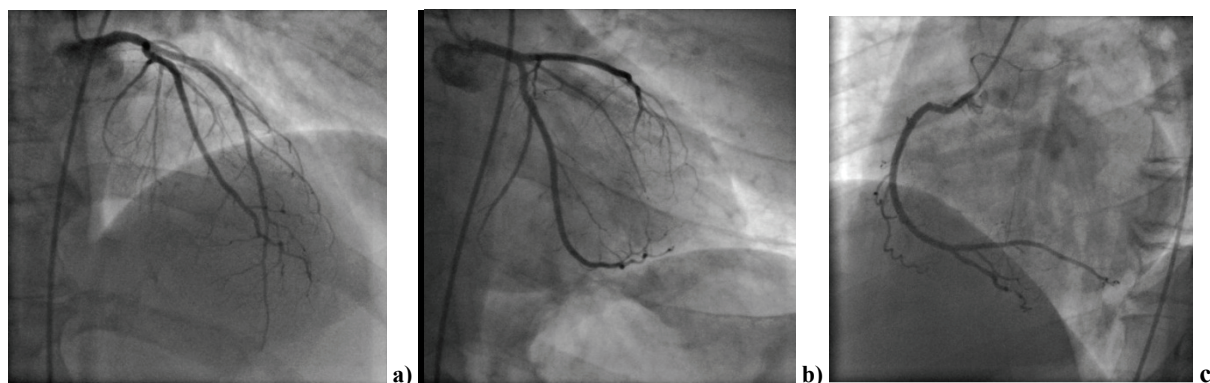


Fig. 2 – a) and b) left anterior and circumflex coronary arteries; c) right coronary artery.

During the first two hours after admission to the Cardiology Intensive Care Unit, the patient was conscious, breathing spontaneously using oxygen supplementation, normotensive (systolic pressure 110–130 mmHg), tachycardic (100–120 beats per minute), and afebrile. Due to the symptoms and signs of acute heart failure, the furosemid and nitroglycerin intravenous infusion (5 µg/min) was administered with continuous invasive arterial monitoring via the left radial artery.

The laboratory tests showed the elevated levels of Troponin I, N-terminal pro-brain natriuretic peptide (NT-proBNP) and C-reactive protein (Table 1). There were no other specific abnormalities in laboratory findings (Tables 1 and 2). The chest X-ray showed the emphasized right pulmonary hilum and a stricter bronchovascular drawing (Figure 3).

Table 1
Laboratory findings at admission

Parameter	Value	Reference range
Troponin I (µg/L)	0.16	< 0.01
Creatine kinase – CK (U/L)	97	0–200
CK myocardial band (U/L)	25	0–25
C-reactive protein (mg/L)	7.7	0–5
Fibrinogen (g/L)	3.3	2.2–4.9
D-dimer (mg/mL)	< 500	< 500
NT-proBNP (pg/mL)	1552	125
Urea (mmol/L)	4.2	2.5–7.5
Creatinine (µmol/L)	95	65–120
Lactat dehydrogenase (U/L)	336	230–460
Aspartate aminotransferase (U/L)	38	0–40
Alanine aminotransferase (U/L)	33	0–40

NT-proBNP – N-terminal pro-brain natriuretic peptide.

Table 2
Complete blood count

Parameter	Value	Reference range
Leukocytes ($\times 10^9/L$)	6.60	4.0–10.0
Erythrocytes ($\times 10^{12}/L$)	5.23	3.9–6.0
Hemoglobin (g/L)	153	120–170
Hematocrit (g/L)	0.416	0.350–0.540
Thrombocytes ($\times 10^9/L$)	235	150–400
Lymphocytes ($\times 10^9/L$)	1.1	1.18–3.74
Monocytes ($\times 10^9/L$)	0.2	0.24–0.86
Neutrophils, ($\times 10^9/L$)	5.24	1.78–6.13
Eosinophils, ($\times 10^9/L$)	0.06	0.04–0.36

During that time, echocardiography in the Cardiology Intensive Care Unit as well as coronary angiography were performed.

During the third hour of hospitalization, there was a rapid progression of antegrade heart failure with the rapid evolution to cardiogenic shock. The patient became hypotensive (70/40 mmHg) and extremely dyspnoic, with low urine output (less than 0.5 mL/kg/hour). The fluid challenge of 250 mL of 0.9% sodium chloride was performed without adequate response, so inotropic and vasopressor stimulation was

applied. Due to the rapid respiratory failure, the endotracheal intubation was performed immediately afterwards, and the patient was artificially ventilated. Bicarbonates were applied according to the blood gas analyses.

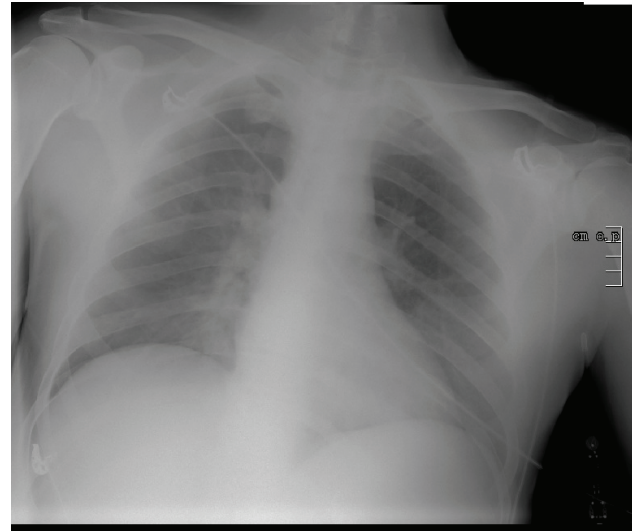


Fig. 3 – Chest radiogram showed emphasized right pulmonary hilum and a stricter bronchovascular drawing.

Despite the artificial ventilation and high inotropic (dobutamine of 10 mg/kg/min) and vasopressor (norepinephrine of 1.8 µg/kg/min) support, there was no improvement of hemodynamic status of the patient. Furthermore, the patient was markedly hypotensive with the mean arterial pressure not exceeding 50 mmHg. The deterioration of arterial blood gas analysis was noticed as well, with the high lactate levels (lactate of 9.1 mmol/L).

To evaluate the cause of rapid and refractory cardiogenic shock, bedside echocardiography was repeated and noticed the decrease in the global contractility (EF estimated of 20%), and no mechanical complications were found. At the same time, the lung ultrasound revealed pulmonary edema. A diagnosis of acute respiratory distress syndrome (ARDS) with PaO₂/FiO₂ ratio = 60, was proposed, too.

According to the clinical presentation, laboratory and echocardiography findings there was a high suspicion to myocarditis and viral pneumonia.

After the performed examinations, a possible correlation of the patient's condition with influenza epidemic was suggested. Due to the epidemic of H1N1 viral infection in previous months with observed poor outcomes, empiric oseltamivir phosphate (Tamiflu®) was administered. An implantation of intra-aortic balloon pump, as the only mechanical circulatory support at that time, was considered, but at the beginning of the fourth hour of hospitalization, a cardiac arrest with pulseless electrical activity occurred. Cardiopulmonary resuscitation was performed with no results and the patient died at the end of the fourth hour from the presentation to the Cardiology Intensive Care Unit.

The real-time polymerase chain reaction (PCR) of the nasopharyngeal swab was influenza A (H1N1) negative, but influenza A (H3) positive (Table 3).

Table 3
Real-time polymerase chain reaction of the nasopharyngeal swab

Virus	Result
Influenza A (H1N1)	Negative
Influenza A (H1)	Negative
Influenza A (H3)	Positive
Influenza A (H5)	Negative
Influenza A (H7)	Negative
Influenza B	Negative

On autopsy, the macroscopic histopathological analysis showed the globally slightly dilated heart, weighted 410 g. The coronary arteries were slightly atherosclerotic without significant stenosis. Myocardium was pale, grayish, softened and thin, with focal small dotty hemorrhages. There were no signs of previous or new ischemic lesions.

The microscopic histopathological analysis revealed the myocardium infiltrated with a dense inflammatory lymphocyte infiltrate, rare neutrophil and rare eosinophil granulocytes and histiocytes with the focal areas of necrotic cardiomyocytes and extensive interstitial edema (Figures 4–6).

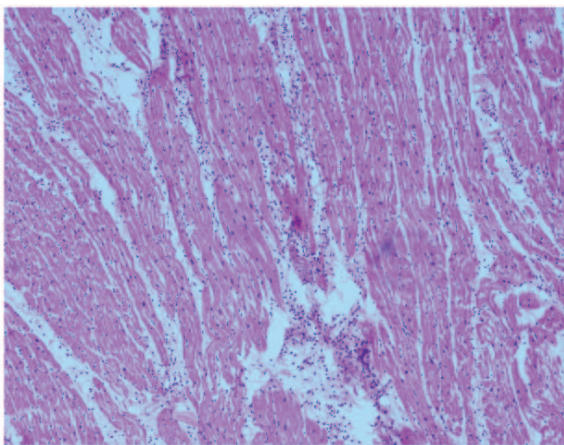


Fig. 4 – Dense lymphocyte infiltrate and interstitial edema [haematoxylin/eosin (HE), ×10].

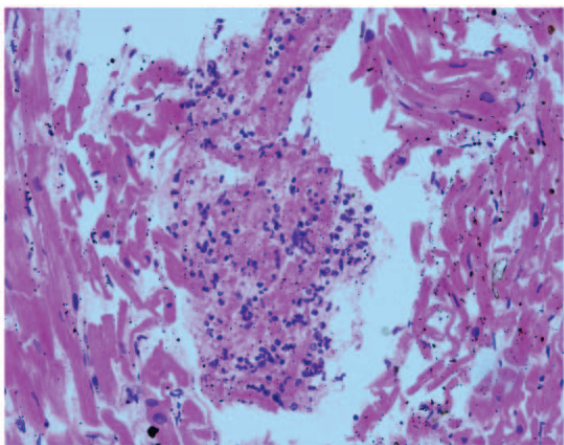


Fig. 5 – Area of necrotic cardiomyocytes with lymphocyte infiltrate and rare neutrophil and eosinophil granulocytes (HE, ×40).

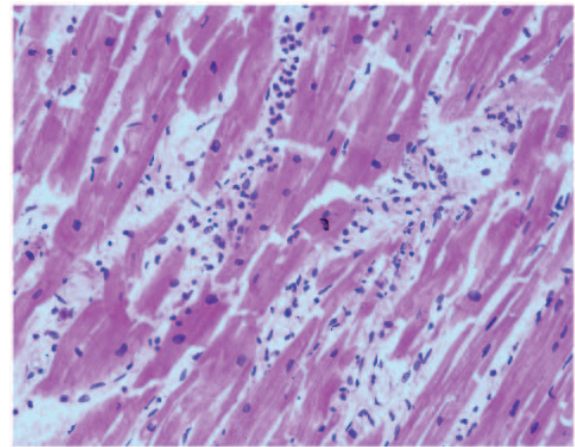


Fig. 6 – Broken cardiomyocyte fibres with interstitial edema and focal dense inflammatory infiltrate (HE, ×40).

The pulmonary histopathological findings revealed the thickened alveolar walls, interstitial edema and alveolar lumen filled with transudate – the picture of cardiogenic pulmonary edema (Figures 7–8).

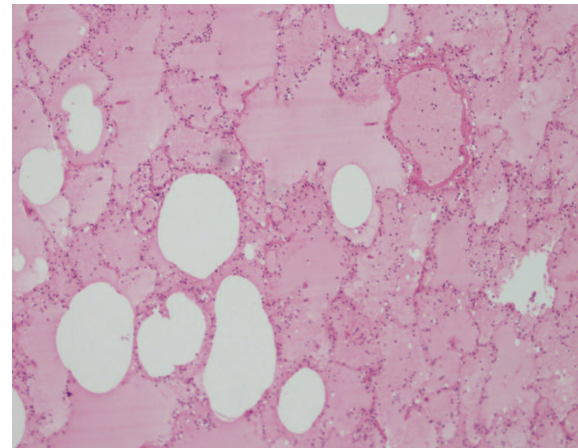


Fig. 7 – Thickened alveolar walls with interstitial edema and transudate in alveolar lumen (HE, ×10).

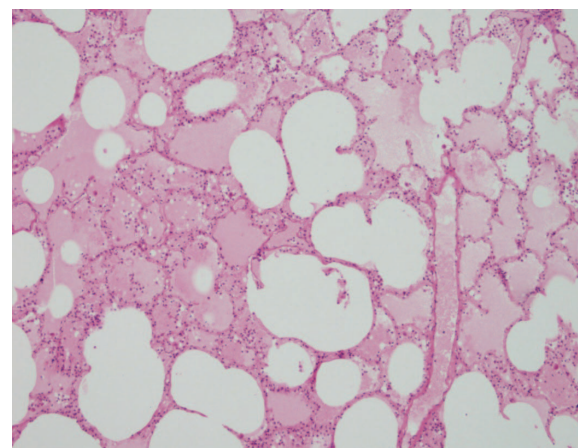


Fig. 8 – Thickened alveolar walls with interstitial edema and transudate in alveolar lumen (HE, ×10).

Discussion

Fulminant myocarditis is a rapidly progressive, life-threatening myocarditis, followed by the development of cardiogenic shock^{7,8}.

Precise incidence of myocarditis is difficult to evaluate and according to some data it is about 8 to 10 per 100,000 population. A pathologic series of Fabre and Sheppard⁸ showed that the inflammatory disorders, including lymphocytic myocarditis and cardiac sarcoidosis, accounted for 8.6% of all sudden adult cardiac deaths.

Viruses are the most common cause of myocarditis. Among viruses, the most common are enteroviruses including the coxsackie virus, adenovirus, parvovirus, hepatitis C virus, human immunodeficiency virus, while other viruses, such as influenza A virus, rarely cause myocarditis. Recently, by using the modern molecular methods, a simultaneous presence of more viral antigens is discovered. These viruses possibly strengthen the virulence of one another, but a genetic defect in a human immune system which leads to incapability to destroy multiple viral forms is possible, as well^{9,10}.

It is shown that during influenza epidemics, 5% to 10% of infected patients may have cardiac symptoms². The patients with fulminant myocarditis often have flu-like symptoms for 2–4 weeks prior the cardiac presentation. The physical examination at the time of presentation to the Intensive Care Unit shows the New York Heart Association (NYHA) class III or IV heart failure symptoms, hypotension, tachycardia, livid cold extremities, hemodynamic instability and respiratory failure².

In our case report, flu like symptoms (cough and sweating) were present four days prior to admission. However, body temperature was normal. To make a diagnosis even more difficult to establish, a short loss of consciousness was the main reason for the doctor's attention. In the physical finding, the heart failure symptoms and signs of heart failure Killip class II/III were present.

At the time of admission, the proposed differential diagnosis were the acute pulmonary thromboembolism, acute myocardial infarction with the heart failure, acute lung injury and fulminant myocarditis.

The initial laboratory tests usually show elevated inflammatory markers (erythrocyte sedimentation rate and C-reactive protein), however they do not confirm the diagnosis and are often increased in other circumstances such as acute pericarditis¹¹.

Despite that cardiac troponins are more sensitive of myocyte injury than creatine kinase enzyme, they are not specific for myocarditis, and when normal, do not exclude myocarditis. Brain natriuretic peptides and circulating cytokines are nonspecific for myocarditis, as well^{12,13}.

The current European Society of Cardiology (ESC) guidelines strongly recommend the assessment of troponins, erythrocyte sedimentation rate, C-reactive protein levels in all patients while a routine viral serology testing is not recommended¹⁴.

Except slightly elevation of troponin I (0.16 mg/L), NT-pro BNP (1,550 pg/mL) and C-reactive protein (7.7 mg/L),

there were no other specific abnormalities in our patient laboratory at admission. This is also a confirmation of severe and rapidly progressive form of fulminant myocarditis.

The electrocardiographic abnormalities range from the T wave inversion to the ST segment elevation, as well as disorders in the intraventricular conduction (wide QRS complex), and both supraventricular and ventricular arrhythmias. However, the ECG signs are neither specific nor sensitive for myocarditis¹⁵. In combination with the elevated cardiac enzymes and echocardiography finding, the suspicion of acute myocardial infarction as differential diagnosis could be established as well.

Echocardiography is the first choice imaging technique in the evaluation of cardiac function. According to the study of Felker et al.¹⁶, among the patients with fulminant myocarditis, echocardiogram usually shows low ejection fraction, normal end-diastolic diameter of left ventricle and increased left ventricle wall thickness due to inflammatory response resulting in interstitial oedema. In our report, bedside echocardiography, a slightly decreased global contractility (EF of 45%) was showed at first, along with a rapid progression of myocardial function and three hours after admission, EF was estimated to 20%.

Coronary angiography is recommended for all adult patients in order to exclude thrombosis of epicardial coronary artery and it is extremely important among the patients with the known risk factors for coronary disease.

Cardiac magnetic resonance imaging (MRI) is considered to be the most sensitive noninvasive imaging method for the diagnostics of myocarditis, showing a subepicardial late enhancement pattern, thereby visualizing myocarditis-related necrosis¹⁷. The cardiac MRI findings consistent with myocarditis should be based on the Lake-Louise criteria¹⁸.

However, most of the patients with fulminant myocarditis are hemodynamically unstable and therefore MRI is not possible. In our report, the clinical deterioration was so rapid, that performing MRI could not be done.

Furthermore, cardiac MRI cannot replace the endomyocardial biopsy (EMB).

The EMB and histopathological analysis has a critical role in the evaluation of the patients with an unexplainable acute heart failure and it has the American College of Cardiology/the American Heart Association (ACC/AHA) class I indication in the evaluation of the hemodynamically unstable patients with the cardiac insufficiency lasting less than two weeks, with the optimal sensitivity as soon as the symptoms started².

Intensive myocardial inflammation with cardiomyocyte necrosis is pathological, but it is a nonspecific sign of fulminant myocarditis. Histological findings can be classified according to the Dallas criteria as the active myocarditis, borderline myocarditis and negative. Despite being a gold standard for an unequivocal diagnosis of myocarditis, there are a number of reasons for the insensitivity of Dallas criteria^{17,19}.

The myocardial samples, each 1–2 mm in size, taken from the EMB should be analysed using histology, immunohistochemistry and viral PCR. A high quality EMB confirms the diagnosis of myocarditis, identifies the underlying etiol-

ogy and the type of inflammation (e.g., giant cell, eosinophilic myocarditis, sarcoidosis), and therefore can guide different treatments and predict prognosis¹⁴.

According to the current position statement of the ESC, the diagnostic criteria for clinically suspected myocarditis include: ≥ 1 clinical presentations (acute chest pain, new onset (days up to three months), or worsening of dyspnea; subacute/chronic (> 3 months) worsening of dyspnea; palpitation, syncope, aborted sudden cardiac death; unexplained cardiogenic shock) and ≥ 1 diagnostic criteria from different categories (ECG/Holter/stress test features, myocardiocytolysis markers, functional and structural abnormalities on cardiac imaging [echo/angio/cardiovascular magnetic resonance (CMR)], tissue characterization by CMR) in the absence of angiographically identified coronary stenosis $\geq 50\%$, preexisting cardiovascular disease or extracardiac causes that could explain the syndrome¹⁴.

There is no specific therapy of fulminant myocarditis. Since the patients are usually hemodynamically unstable, supportive therapy is used as the first choice of therapy. In our report, endotracheal intubation, inotropic and vasopressor support were the first line of therapy. However, the result of supportive measures was very poor. There was also a lack of time to implant the intra-aortic balloon pump (IABP) as the second line therapy, mainly due to a highly progressive cardiogenic shock with the subsequent cardiac arrest.

Despite the intensive treatment, the mortality associated with fulminant myocarditis is high, from 39% for the patients with fulminant myocarditis associated with the H1N1 reported by Ukimura et al.²⁰ to the mortality rate of 83% reported by Saji et al.²¹ in the patients with fulminant myocarditis who failed to respond to an initial supportive medical treatment without a mechanical circulatory support.

If the patient does not respond to the aggressive supportive therapy during the first few hours or days, an implantation of extracorporeal membrane oxygenation, because of its simplicity, should be considered to be the first choice, or the ventricular assist devices as an alternative. Many cases of spontaneous recovery without the need for the heart transplantation after the use of extracorporeal membrane oxygenation are reported²².

Conclusion

Fulminant myocarditis is a life-threatening cardiac disease which should be treated in intensive care units with both medication and mechanical circulatory support and antiviral therapy and which, despite a therapy applied, has a high mortality rate. Influenza A virus is a rare cause of fulminant myocarditis, which should be taken into consideration, especially in times of epidemic.

R E F E R E N C E S

1. Cooper LT Jr. Myocarditis. *N Engl J Med* 2009; 360(15): 1526–38.
2. Bonow RO, Mann DL, Zipes DP, Libby P. Braunwald's Heart Disease: A Textbook of Cardiovascular Medicine. 9th ed. Philadelphia: Elsevier Saunders; 2012.
3. Himmel F, Hunold P, Schunkert H, Bode F. Influenza A positive but H1N1 negative myocarditis in a patient coming from a high outbreak region of new influenza. *Cardiol J* 2011; 18(4): 441–5.
4. Letouze N, Jokic M, Maragnes P, Rouleau V, Flais F, Vabret A, et al. Fulminant influenza type A associated myocarditis: a fatal case in an 8 year old child. *Arch Mal Coeur Vaiss* 2006; 99(5): 514–6. (French)
5. Nolte KB, Alakija P, Oty G, Shaw MW, Subbarao K, Guarner J, et al. Influenza A virus infection complicated by fatal myocarditis. *Am J Forensic Med Pathol* 2000; 21(4): 375–9.
6. Monteriol A, Wiramus S, Ribeiri A, Attard N, Nait-Saidi L, Kerbaul F, et al. Successful management of Influenza A associated fulminant myocarditis: mobile circulatory support in intensive care unit: a case report. *Cases J* 2008; 1: 46.
7. Nakamura T, Ishida K, Taniguchi Y, Nakagawa T, Seguchi M, Wada H, et al. Prognosis of patients with fulminant myocarditis managed by peripheral venoarterial extracorporeal membranous oxygenation support: a retrospective single-center study. *J Intensive Care* 2015; 3(1): 5.
8. Fabre A, Sheppard MN. Sudden adult death syndrome and other non-ischemic causes of sudden cardiac death. *Heart* 2006; 92(3): 316–20.
9. Kubl U. Viral Persistence in the Myocardium Is Associated With Progressive Cardiac Dysfunction. *Circulation* 2005; 112(13): 1965–70.
10. Noutsias M, Fechner H, de Jonge H, Wang X, Dekeers D, Houtsmuller AB, et al. Human coxsackie-adenovirus receptor is colocalized with integrins $\alpha v \beta 3$ and $\alpha v \beta 5$ on the cardiomyocyte sarcolemma and upregulated in dilated cardiomyopathy: Implications for cardiotropic viral infections. *Circulation* 2001; 104(3): 275–80.
11. Caforio AL, Brucato A, Doria A, Brambilla G, Angelini A, Ghirardello A, et al. Anti-heart and anti-intercalated disk autoantibodies: evidence for autoimmunity in idiopathic recurrent acute pericarditis. *Heart* 2010; 96(10): 779–84.
12. Jensen J, Ma LP, Fu ML, Svaninger D, Lundberg P, Hammarsten O. Inflammation increases NT-proBNP and the NT-proBNP/BNP ratio. *Clin Res Cardiol* 2010; 99(7): 445–52.
13. Deswal A, Petersen NJ, Feldman AM, Young JB, White BG, Mann DL. Cytokines and Cytokine Receptors in Advanced Heart Failure: An Analysis of the Cytokine Database from the Vesnarinone Trial (VEST). *Circulation* 2001; 103(16): 2055–9.
14. Caforio AL, Pankunweit S, Arbustini E, Basso C, Gimeno-Blanes J, Felix SB, et al. Current state of knowledge on aetiology, diagnosis, management, and therapy of myocarditis: a position statement of the European Society of Cardiology Working Group on Myocardial and Pericardial Diseases. *Eur Heart J* 2013; 34(33): 2636–48.
15. Ukena C, Mahfoud F, Kindermann I, Kandolf R, Kindermann M, Böhm M. Prognostic electrocardiographic parameters in patients with suspected myocarditis. *Eur J Heart Fail* 2011; 13(4): 398–405.
16. Felker G, Boehmer JP, Hruban RH, Hutchins GM, Kasper EK, Baughman KL, et al. Echocardiographic findings in fulminant and acute myocarditis. *J Am Coll Cardiol* 2000; 36(1): 227–32.
17. Mahrholdt H, Goedecke C, Wagner A, Meinhardt G, Athanasiadis A, Vogelsberg H, et al. Cardiovascular magnetic resonance assessment of human myocarditis: a comparison to histology and molecular pathology. *Circulation* 2004; 109(10): 1250–8.
18. Friedrich MG, Sechtem U, Schulz-Menger J, Holmvang G, Alakija P, Cooper LT, et al. International Consensus Group on Cardiovas-

- cular Magnetic Resonance in Myocarditis. Cardiovascular magnetic resonance in myocarditis: A JACC White Paper. *J Am Coll Cardiol* 2009; 53(17): 1475–87.
19. *Chow LH, Radio SJ, Sears TD, Mcmanus BM.* Insensitivity of right ventricular endomyocardial biopsy in the diagnosis of myocarditis. *J Am Coll Cardiol* 1989; 14(4): 915–20.
 20. *Ukimura A, Izumi T, Matsumori A.* Clinical Research Committee on Myoc. Clinical Research Committee on Myocarditis Associated with 2009 Influenza A (H1N1) Pandemic in Japan organized by Japanese Circulation Society A national survey on myocarditis associated with the 2009 influenza A (H1N1) pandemic in Japan. *Circ J* 2010; 74(10): 2193–9.
 21. *Saji T, Matsuura H, Hasegawa K, Nishikawa T, Yamamoto E, Ohki H,* et al. Comparison of the Clinical Presentation, Treatment, and Outcome of Fulminant and Acute Myocarditis in Children. *Circ J* 2012; 76(5): 1222–8.
 22. *Hsu K, Chi N, Yu H, Wang C, Huang S, Wang S,* et al. Extracorporeal membranous oxygenation support for acute fulminant myocarditis: analysis of a single center's experience. *Eur J Cardiothorac Surg* 2011; 40(3): 682–8.

Received on September 28, 2017.

Revised on December 29, 2017.

Accepted on January 22, 2018.

Online First January, 2018.