



## The arteriovenous hemangioma of the right ventricle – case report and literature review

### Arteriovenski hemangiom desne komore

Aleksandar Mikić\*<sup>†</sup>, Miloš Matković\*, Petar Vukićević<sup>§§</sup>,  
Biljana Obrenović-Kirćanski<sup>||</sup>, Nemanja Karamarković\*,  
Miloš Velinović\*<sup>†</sup>, Marko Šamanović\*, Svetozar Putnik\*<sup>†</sup>

Clinical Center of Serbia, \*Department of Cardiac Surgery, <sup>||</sup>Department of Cardiology, Belgrade, Serbia; University of Belgrade, <sup>†</sup>Faculty of Medicine, Belgrade, Serbia; University of Defence, <sup>‡</sup>Faculty of Medicine of the Military Medical Academy, Belgrade, Serbia; Military Medical Academy, <sup>§</sup>Clinic for Cardiac Surgery, Belgrade, Serbia

#### Abstract

**Introduction.** Cardiac hemangiomas of the right ventricle are very rare and mostly asymptomatic benign tumors. The surgical excision is the first line treatment. **Case report.** We report a case of 69-year-old woman with an asymptomatic arteriovenous hemangioma of the right ventricle. The complete surgical excision was performed with the use of cardiopulmonary bypass and the patient was discharged on the postoperative day 6 after the uneventful postoperative course. There was no relapse during the six-month follow-up. Literature review revealed totally 35 cases of this tumors including our case **Conclusion.** Described procedure can be performed safely with the excellent long-term results.

#### Key words:

hemangioma; heart ventricles; cardiac surgical procedures; diagnosis; treatment outcome.

#### Apstrakt

**Uvod.** Hemangiomi desne komore srca su izuzetno retki i uglavnom asimptomatski benigni tumori. Hirurško lečenje je terapija izbora. **Prikaz bolesnika.** Kod bolesnice stare 69 godina dijagnostikovao je asimptomatski benigni tumor srca tipa arteriovenskog hemangioma desne komore. Totalna hirurška ekscizija učinjena je uz pomoć vantelesnog krvotoka. Postoperativni tok je bio uredan i bolesnica je otpuštena kući šest dana posle zahvata. Na kontrolnom pregledu posle šest meseci nije bilo znakova recidiva. Pregledom literature pronađeno je ukupno 35 slučajeva ovog tumora uključujući i prikazanu bolesnicu. **Zaključak.** Opisana procedura se može bezbedno koristiti kao terapija izbora sa odličnim dugoročnim rezultatima.

#### Ključne reči:

hemangiom; srce; komora; hirurgija, kardijalna, procedure; dijagnoza; lečenje, ishod.

#### Introduction

Hemangiomas of the heart are exceptionally rare benign tumors constituting 1%–2% of all cardiac tumors which may occur in all cardiac layers: pericardium, myocardium or endocardium. Their location in the right ventricle is highly uncommon and usually without any symptoms. The cardiac hemangiomas are clinically classified into three subcategories: capillary, cavernous and arteriovenous type<sup>1</sup>. This report accounts for a case of arteriovenous cardiac hemangioma, an extremely rare subtype of this tumor.

#### Case report

We report a 69-year-old woman without any reported symptoms who was accidentally diagnosed with the tumor of the right ventricle during a routine echocardiography. She is a nonsmoker with previous history of hypertension and under control by therapy. Transthoracic echocardiography showed a mass in the right ventricle with no tricuspid regurgitation, normal right ventricle diameter and normal left ventricular function. The cardiac magnetic resonance imaging (MRI) showed an intermediate-density mass 20 × 25 cm fixed with

a small pedicle to the anterior wall of the right ventricle. The coronary angiography did not show signs of coronary disease (Figure 1a and b). The laboratory test results were all within normal ranges, as well as serum tumor markers.

Under general anesthesia, the median sternotomy was performed. After the institution of bicaval cardiopulmonary bypass, the heart was arrested with warm blood cardioplegia in normothermic conditions. The tumor was resected completely with a clear margin through right atriotomy, there was no involvement of the tricuspid valve (Figure 1c). There was no need for the ventricle wall reconstruction.

The histopathology exam revealed the mixture of arterial and venous vessels confirming the diagnosis of arteriovenous hemangioma (Figure 2a and c). The endothelial markers CD 31 were positive on immunohistochemical staining (Figure 2 b).

The patient was discharged on the postoperative day 6 with the uneventful postoperative course. After six-month follow-up, the patient was alive and well, with no relapse of the hemangioma showing at the control echocardiography.

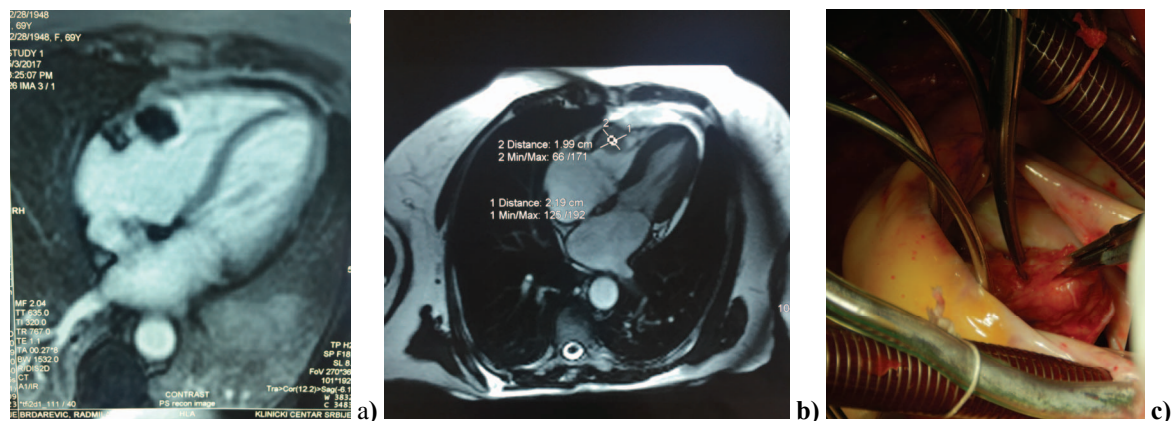
### Discussion

The cardiac hemangiomas are extremely rare benign tumors of the heart. They can occur in all three layers of the myocardium and can be present anywhere in the heart cavities or pericardium. They consist of small arterial or venous vessels and cavernous vascular channels, leading to the divi-

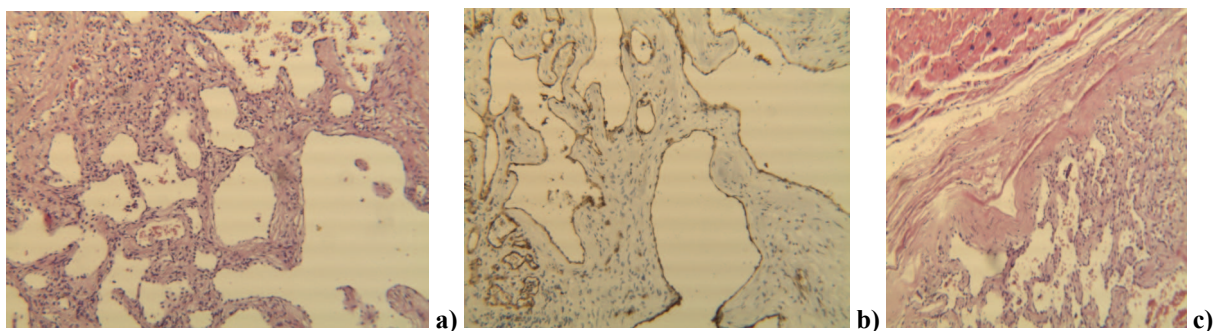
sion on three subtypes: capillary, cavernous and arteriovenous. They are very uncommon in the right ventricle, especially the arteriovenous type presented in our case. The disease can appear in the patients of all ages, and the clinical presentation depends on the localization and the size of the tumor – it can vary from the asymptomatic to the signs of right ventricle congestion, but they are usually asymptomatic<sup>2</sup>. There are some cases described to result in a sudden cardiac death, rhythm disturbances in hemangioma localized in the vicinity of the atrioventricular (AV) node and tamponade caused by a ruptured hemangioma in the pericardium. The tumors localized in the valvular apparatus can cause the orifice obstruction and distal embolization<sup>3</sup>.

There was an indication for a surgical procedure because of the malignant localization of the tumor (it was even supposed to be benign), as well as for the definite histopathology exam confirmation of the tumor type. Especially because the right-sided heart tumor mass is always suspicious for malignancy because the high frequency of cardiac metastases originate from the primary malignant tumor (bronchogenic carcinoma, breast, hepatic and renal carcinoma) via venous dissemination<sup>4</sup>.

The diagnosis was made on the basis of echocardiography followed by a confirmation of the contrast-enhanced computed tomography (CT) or cardiac MRI. Coronary angiography is useful in determining the relationship with coronary arteries if necessary, or in excluding the concomitant coronary artery disease if suspected<sup>5</sup>.



**Fig. 1 – Magnetic resonance imaging (a, b) and intraoperative image (c) showing the hemangioma in the right ventricle.**



**Fig. 2 – Microscopic view of the arteriovenous hemangioma of the right ventricle (a, c) and the CD 31 positive marker staining (b).**

MRI was performed in order to visualize the tissue structure and the possible invasiveness of the tumor mass. The MRI and echocardiography together give more information on the tumor origin in the right heart that was histopathologically confirmed after the surgical tumor removal than the echocardiography alone, especially for the right heart localization due to a difficulty in obtaining this view on the standard echocardiography<sup>6</sup>. The contrast enhancement feature of the MRI is highly predictive for malignancy, as well as the ability of the MRI to show the exact localization and tissue invasiveness, in addition to pleural effusion presentation, which are all predictive for cardiac malignancy. The T1 and T2 sequence contrast density alongside the presence of the contrast enhancement can differentiate between the different types of tumor masses. The cardiac lipomas are hyperintense while fibromas and myxomas are hypointense. The cardiac hemangiomas are homogeneous, intermediate-to-high signal on T1-weighted, and diffusely hyperintense on the T2-weighted images<sup>7</sup>.

The treatment of choice is a surgical resection with a clear margin, with the ventricle wall reconstruction if needed<sup>8</sup>.

The first hemangioma of the right ventricle was described by Hochberg in 1950, and up to date, 35 cases have been found in the relevant literature, including the one pre-

sented here. The median sternotomy was used predominantly, and the thoracotomy was used only in two cases. The total resection with a clear margin was performed in 31 patients, while 4 patients had the biopsy done without resection. Over 90% of surgeries were performed with the use of cardiopulmonary bypass (CPB) mainly, with the aortic cross clamping and the use of cardioplegic arrest of the heart. The follow-up data was available for 80% of patients (from 6–24 months), and there were no relapses or fatal outcomes. The main localization was the anterior wall (63%) of the right ventricle, while the right ventricle outflow tract (35%) had the most dramatic clinical presentation. Three tumors had the apical ventricular localization and these hemangiomas may require the right ventricle (RV) wall reconstruction similar to the aneurysmectomy. Jiang et al.<sup>9</sup> reported this procedure with a satisfactory postoperative cardiac function.

### Conclusion

The cardiac hemangiomas of the right ventricle are very rare and mostly asymptomatic benign tumors. The surgical excision is the first line treatment. The procedure can be safely done with the use of CPB while the complete excision is mainly achieved with a low rate of recurrence and excellent long-term survival.

### R E F E R E N C E S

1. *Shikata D, Nakagomi T, Yokoyama Y, Yamada Y, Nakajima M, Oyama T, et al.* Debulking surgery for venous hemangioma arising from the epicardium: report of a case. *World J Surg Oncol* 2017; 15(1): 81.
2. *Brizard C, Latremouille C, Jebara VA, Acar C, Fabiani JN, Deloche A, et al.* Cardiac hemangiomas. *Ann Thorac Surg* 1993; 56(2): 390–4.
3. *Rafajlowski S.* Hemangiomas of the heart. In: *Rafajlowski S*, editor. *Tumors of the heart*. Belgrade: Military Medical Academy; 2010. p. 61–5. (Serbian)
4. *Lynch M, Clements SD, Shanewise JS, Chen CC, Martin RP.* Right-sided cardiac tumors detected by transesophageal echocardiography and its usefulness in differentiating the benign from the malignant ones. *Am J Cardiol* 1997; 79(6): 781–4.
5. *Papadopoulos K, Makrides CA, Eleutheriou E.* A cardiac haemangioma: the contribution of myocardial contrast echocardiography in the diagnosis. *BMJ Case Rep* 2015; 201: pii: bcr2015210075.
6. *Araoz PA, Eklund HE, Welch TJ, Breen JF.* CT and MR imaging of primary cardiac malignancies. *Radiographics* 1999; 19(6): 1421–34.
7. *Hoffmann U, Globits S, Schima W, Loewe C, Puig S, Oberhuber G, et al.* Usefulness of magnetic resonance imaging of cardiac and paracardiac masses. *Am J Cardiol* 2003; 92(7): 890–5.
8. *Colli A, Budillon AM, DeCicco G, Agostinelli A, Nicolini F, Tzjaltas D, et al.* Recurrence of a right ventricular hemangioma. *J Thorac Cardiovasc Surg* 2003; 126(3): 881–3.
9. *Jiang WJ, Li JH, Dai J, Lai YQ.* Cardiac hemangioma at the apex of the right ventricle: a case report and literature review. *J Thorac Cardiovasc Surg* 2014; 147(3): e18–21.

Received on November 08, 2017.

Revised on January 29, 2018.

Accepted on February 06, 2018.

Online First February, 2018.