



The influence of the skin tumors excision width in the postoperative facial asymmetry

Uticaj širine ekscizije tumora kože lica na postoperativnu asimetriju

Saša Milićević*, Aleksandar Jevtić†, Nenad Stepić**

Military Medical Academy, *Clinic for Plastic Surgery and Burns, †Clinic for Orthopedic Surgery and Traumatology, Belgrade, Serbia; University of Defence,

‡Faculty of Medicine of the Military Medical Academy, Belgrade, Serbia

Abstract

Background/Aim. Planning an elliptical excision of the facial skin, caused by lines of minimum tension, is very important in order to achieve good aesthetic results. The width of the tumor excision affects the possibility of a direct closure of the post-excision defect. The aim of the study was to determine the minimum width of excision that does not affect postoperative symmetry of the face, in relation to the preoperative one, using an objective scanning method with a line laser scanner. **Methods.** The study included 50 patients of both sexes, older than 50 years, who had verified facial skin tumor and established medical indication for surgical elliptical excision and direct suture. All patients had laser scanning preoperatively, and then seven days and 90 days postoperatively, giving x, y, and z coordinates of 5 cephalometric points on the face, which determined the shape of the examined region. Patients were divided into three groups depending on the width of the excision (< 10 mm, 10–15 mm, > 15 mm). The shape of the examined region among different width of excision was compared, preoperatively, 7 days and 90 days postoperatively, using Procrustes analysis and analysis of the coordinates of cephalometric points. **Results.** Taking into account preoperative and postoperative x, y and z coordinates of the cephalometric points, statistically significant differences between the group of patients with the width excision < 10 mm and the other two groups (excision width 10–15 mm and > 15 mm) were found. **Conclusion.** The width of the skin tumors excision < 10 mm does not affect the postoperative facial asymmetry when a post-excisional defect is closed by direct suture.

Key words:

facial neoplasms; reconstructive surgical procedures; postoperative period; facial asymmetry; lasers; cephalometry.

Apstrakt

Uvod/Cilj. Planiranje elipsastih ekscizija na koži lica, uslovljeno linijama minimalne tenzije, veoma je bitno u postizanju dobrih estetskih rezultata. Širina ekscizije tumora utiče na mogućnost direktnog zatvaranja postekscizionog defekta. Cilj rada bio je određivanje najmanje širine ekscizije koja ne utiče na postoperativnu simetriju lica, u odnosu na preoperativnu simetriju, primenom objektivne metode skeniranja lica linijskim laser skenerom. **Metode.** Istraživanjem je bilo obuhvaćeno 50 ispitanika oba pola, starijih od 50 godina, kod kojih je verifikovan tumor kože lica i postavljena medicinska indikacija za hiruršku elipsastu eksciziju i direktnu suturu. Svi ispitanici su skenirani laser skenerom preoperativno, a potom 7 dana i 90 dana postoperativno. Na taj način dobijene su x, y i z koordinate pet kefalometrijskih tačaka na licu, koje su određivale oblik ispitivane regije. Ispitanici su podeljeni u tri grupe u zavisnosti od širine ekscizije (< 10 mm, 10–15 mm, > 15 mm). Upoređivan je oblik ispitivane regije između različitih širina ekscizije, preoperativno, kao i 7 dana i 90 dana postoperativno, primenom Prokrustove analize i analize koordinata kefalometrijskih tačaka, nađena je statistički značajna razlika u obliku ispitivane regije između grupe ispitanika sa širinom ekscizije < 10 mm u odnosu na ostale dve grupe ispitanika (širina ekscizije 10–15 mm i > 15 mm), **Zaključak.** Širina ekscizije tumora kože lica < 10 mm ne utiče na postoperativnu asimetriju kada se postekscizionni defekt zatvara direktnom suturom.

Ključne reči:

lice, neoplazme; hirurgija, rekonstruktivna, procedure; postoperativni period; facijalna asimetrija; laseri; kefalometrija.

Introduction

The basic postulates in plastic and reconstructive surgery with a consequent good aesthetic result are remodeling, restoring lost or establishing a new position. Face, as the most exposed part of the body, has always been a region of the greatest challenges for the plastic surgeon. In order to achieve good aesthetic results on site, planning the excision is conditioned on knowledge of the lines of minimum tension^{1,2}.

In assessing the aesthetic results, plastic surgeons have used the symmetry of objectification, although they eventually realized that harmony is an additional important moment in the evaluation. Historically speaking, many methods for assessing symmetry were developed³⁻⁵.

Unfortunately, geometry with mathematical precision could not be applied in clinical practice, since geometric and biological laws affect the renewal of tissue. On the other hand, using geometry is the most precise, the best, and the most objective way of assessing symmetry⁶.

Although the use of geometry in measuring and estimating the obtained results is the most accurate method, it was very difficult to find the best way to use geometry. It is necessary to decide what is measured, how it is measured, and how to evaluate the measurement results. In the initial development of morphometry, representing the method of shape measurement, the orientation points were first determined, after which the distance between the orienting points was measured. In order to compare the distances, it was necessary to standardize the position of the orientation points or to perform scaling of the measured shapes. In that way, all the measured shapes would be of the same size. The distance between the orientation points of measured shapes would be the measurement of two shapes' difference. The big problem was to determine the position of the reference plane so that no errors in the measurement occurred as a result of an inadequate position of the plane in terms of rotation along the vertical or horizontal axis of rotation. Even when all the stated difficulties in measuring were corrected, the question arose as to how to compare the obtained results, because the positions of measured points, or the distance between the measured points, did not provide information about the whole shape of the measured region. It was necessary to standardize the positions of all measured points and find a way to statistically compare the shapes of the measured region in several patients. But, the statistical analysis of the position of the measured points individually presented a more detailed analysis of the shape, presenting which exact points changed the shape of the measured region. All of the above conditions could be satisfied with the use of a line laser in scanning faces because it is the most precise first step in measuring the position of the points. After that, it is necessary to do the scaling and positioning of the level of the measured face in order to define the coordinate start, after which the orientation points receive their *x*, *y* and *z* coordinates⁷.

In addition to this, a major problem was in defining the shape variables, determining the statistical significance of the difference between the measured shapes and in assessing the asymmetry between the shapes. The above problem was re-

solved using the Procrustes analysis, which involved translating, rotating and scaling scanned shapes, in order to bring them to a level so that the orientation points could be measured. After that, the Procrustes distance was determined, representing the square root of the square of the difference sum between the analog measured points, presenting the difference between the two forms. In statistical data processing, ANOVA and MANOVA with post-hoc tests for coordinates of measured points, ie. Procrustes distance between measured shapes, which are characterized by measured points, is a selection method for an adequate estimation of the difference between the measured shapes. This methodology has wide application in many morphometric analyzes, and can also be applied in plastic surgery as the most objective method for assessing the level of asymmetry, on the basis of the statistical significance of the difference between the patient groups in relation to the independent variable and among the same groups of patients at different time intervals in relation to the time of the operation. The described methodology can also be used in measuring other regions of the body⁸.

Laser light in the assessment within two points in the space base was used ten years ago for the first time in the world for the formation of a low-budget hardware-software package for the three-dimensional scanning and editing models⁹.

Laser light today has a great application in estimating the distance between two points in space. It has found its place in many scientific disciplines and spheres of life, mostly in forensics, construction, anthropology, and traffic. When we talk about the application of laser light in morphological analyses in medicine and dentistry, nowadays it is most commonly used in the prosthetics^{10,11}.

In accordance with the basic principles of plastic and reconstructive surgery, including aesthetic surgery, when the morphological aspect is one of the essential elements in the assessment of postoperative results, the use of laser light in a precise assessment of morphological characteristics and the relationship of anatomical entities can find its important place and role in the scientific research, as well as in the clinical practice^{12,13}.

The aim of the study was to determine the minimum width of excision that does not affect the postoperative symmetry of the face, in relation to the preoperative one.

Methods

The study included 50 patients of both sexes, older than 50 years, who had verified facial skin tumor and established medical indication for surgical elliptical excision and direct suture.

All patients had laser scanning preoperatively, and 7 days and 90 days postoperatively, giving the three-dimensional (3D) coordinates (*x*, *y* and *z*) of five cephalometric points on the face (nasion, endocanthal central point, pronasale, lower palpebral point, endocanthion).

The excision width was determined, as an independent variable, in order to compare the obtained results with different excision widths.

The width of excision implied the sum of the tumor width and the width of the excised healthy skin on both sides of the tumor, in the widest part of excision. Measurement of excision width was done before surgery, after scanning with a line laser scanner, and also we measured x, y and z coordinates of cephalometric points before the surgery. After the surgery, on the 7th and 90th day, we measured x, y, and z coordinates of cephalometric points.

Patients were divided into three groups depending on the excision width (< 10 mm, 10–15 mm, > 15 mm).

Equipment for three-dimensional scanning (recommended by the Institute for Robotics and Process Control, University of Braunschweig, Germany) was consisted of a red laser line laser (first class, 650 nm adjustable focus) and auto focusable camera Logitech QuickCam Pro 9000, a resolution of 1600 × 1200 pixels, and laser projection lines were recorded on the faces of patients included in the study. The equipment was connected during the scan to a computer and data processing was done using a professional licensed Laserscanner software. This result was the virtual model with 400.000–600.000 points having defined x, y and z coordinate, to the accuracy of 0.2 mm¹⁴.

Using 3D coordinates, by Procrustes analysis of five cephalometric facial points, we determined Procrustes distance, given by Procrustes coordinates, as a measure of the shape variability of the examined region. Procrustes distance was determined using the MorphoJ program (MorphoJ, version 1.06d, 2014), while all other statistical analyses were done in the SPSS program (SPSS 23, IBM, 2015).

Our methodology in estimating the level of asymmetry of the face after the excision of facial skin tumors has not been applied in our institution until now, and according to the available literature, the complete methodology described has not been applied in plastic surgery regarding the evaluation of postoperative asymmetry at different widths of facial skin tumor excision.

Results

The mean values of Procrustes distances between facial coordinates in patients with facial tumors excised by using three excision widths (< 10 mm, 10–15 mm, > 15 mm), preoperatively, 7 days after surgery and 90 days after surgery, were presented in Figure 1.

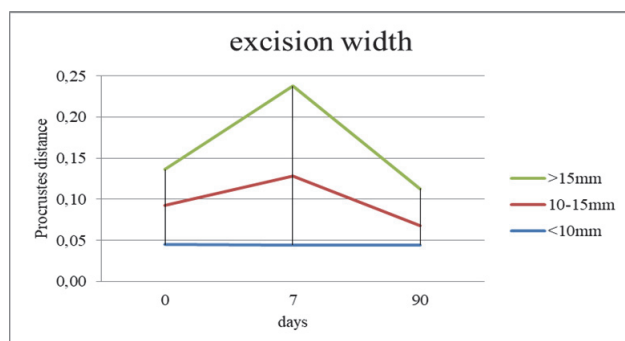


Fig. 1 – Procrustes distances among the different excision widths in patients with facial skin tumors in all scanning times (0, 7, 90 days).

Excision width: < 10 mm, 10–15 mm, > 15 mm.

We found a very similar value of Procrustes distances in the group with excision width < 10 mm, in all three scanning times. Seven days postoperatively, we found the highest value of Procrustes distances in two groups (10–15 mm, > 15 mm), while 90 days postoperatively, the value of Procrustes distances was lower than preoperatively, in the same groups. Preoperatively, median of Procrustes distances was lower than mean in the group with excision width < 10 mm and 10–15 mm, while median was higher than mean in the group with excision width > 15 mm; 7 days postoperatively median was lower in the group with excision width < 10 mm and in > 15 mm, and higher in the group with excision width 10–15 mm; 90 days postoperatively median was lower than mean in all three groups.

The statistical significance of Procrustes distance differences between different excision widths in all of three scanning times was analyzed using ANOVA and post-hoc Tukey test, and presented in Table 1. We found statistically highly significant difference among all three excision width groups, 7 and 90 days postoperatively.

Table 1
Procrustes distances (Pd) between different excision widths in all three scanning times (0, 7, 90 days)

Pd (mm)	Days		
	0	7	90
	<i>p</i> -value		
< 10 vs. 10–15	0.259	0.000	0.000
10–15 vs. > 15	0.070	0.000	0.000
< 10 vs. > 15	0.793	0.000	0.005

Excision width: < 10 mm, 10–15 mm, > 15 mm.

The statistical significance of Procrustes distance differences of different excision width in all of three scanning times was analyzed using ANOVA and post-hoc Tukey test, and presented in Table 2. We found statistically highly significant difference in two groups (10–15 mm and > 15 mm) between all scanning times.

Table 2
Procrustes distances (Pd) of different excision width between all three scanning times (0, 7, 90 days)

Pd (mm)	Days		
	0 vs. 7	7 vs. 90	0 vs. 90
	<i>p</i> -value		
< 10	0.098	0.902	0.098
10–15	0.000	0.000	0.000
> 15	0.000	0.000	0.000

Excision width: < 10 mm, 10–15 mm, > 15 mm.

MANOVA results of statistically significant difference among the coordinates of all three excision widths in all three scanning times (0, 7, 90 days) were presented in Table 3.

We found statistically highly significant difference between 0 and 7 days, and between 7 and 90 days, in two groups (10–15 mm and > 15 mm), in x2, y2–4, in z4 in > 15 mm (0–7 days), in z2 and z4 in > 15 mm (7–90 days), and in x2, y2 and y4 in 10–15 mm and > 15 mm, in 0–90 days. There was no statistically significant difference in the group with excision width < 10 mm between all the scanning times.

Table 3

Influence of different excision width (< 10 mm, 10–15 mm, > 15 mm) on x, y and z coordinates in all scanning times (0, 7, 90 days)

Coordinate	0 vs. 7			7 vs. 90			0 vs. 90		
	< 10 mm	10–15 mm	> 15 mm	< 10 mm	10–15 mm	> 15 mm	< 10 mm	10–15 mm	> 15 mm
	<i>p</i> -value								
x1	1.000	1.000	1.000	1.000	1.000	1.000	1.000	1.000	1.000
x2	1.000	0.000	0.000	1.000	0.000	0.000	1.000	0.001	0.000
x3	1.000	1.000	1.000	1.000	1.000	1.000	1.000	1.000	1.000
x4	1.000	1.000	1.000	1.000	1.000	1.000	1.000	1.000	1.000
x5	1.000	1.000	1.000	1.000	1.000	1.000	1.000	1.000	1.000
y1	1.000	1.000	1.000	1.000	1.000	1.000	1.000	1.000	1.000
y2	0.956	0.000	0.000	1.000	0.000	0.000	1.000	0.000	0.000
y3	1.000	0.000	0.000	1.000	0.000	0.000	1.000	1.000	1.000
y4	1.000	0.000	0.000	1.000	0.000	0.000	1.000	0.000	0.000
y5	1.000	1.000	1.000	1.000	1.000	1.000	1.000	1.000	1.000
z1	1.000	1.000	1.000	1.000	1.000	1.000	1.000	1.000	1.000
z2	1.000	0.083	0.000	1.000	0.083	0.000	1.000	1.000	1.000
z3	1.000	0.946	1.000	1.000	1.000	1.000	1.000	0.946	1.000
z4	1.000	0.083	0.000	1.000	0.083	0.000	1.000	1.000	1.000
z5	1.000	1.000	1.000	1.000	1.000	1.000	1.000	1.000	1.000

Discussion

Previous studies have shown a large number of methods for the evaluation of facial asymmetry, ranging from digital photography, and ending with a three-dimensional laser scanning faces^{15–17}.

The introduction of laser light in the estimation of two points distance in space was the basis used for the first time in the world ten years ago for the creation of a low-budget hardware-software package for three-dimensional scanning and editing of the model. Laser light today has a great application in estimating two points distance in space and has found its place in many scientific disciplines and spheres of life, mostly in forensics, construction, anthropology, and traffic. When we talk about the application of laser light in morphological analyses in medicine and dentistry, it is most commonly used to date in the prosthetics^{18–20}. In accordance with the basic principles of plastic and reconstructive surgery, including aesthetic surgery, when the morphological aspect is one of the essential elements in the assessment of postoperative results, the use of laser light in a precise assessment of morphological characteristics and the relationship of anatomical entities can find its important place and role, regarding both scientific and clinical aspect. The historically observed use of laser light in determining the morphology of three-dimensional objects has not essentially changed since the first days. The forms of laser light application were the only modifications, resulting in measurements of greater precision. The most widely used laser light was initially red, but due to its contrast and laser length, it was eventually concluded that the laser green and blue light gave more accurate results in the measurement. Having done further analysis of measurement accuracy improvement, scien-

tists have concluded that the brightness of the room and the observation object are very important because, in this way, a more precise measurement result is obtained with better contrast. In addition to this, the precision of the optics is an essential part of the camera that records the movement of the laser line through the object of observation^{21–23}.

In accordance with the basic postulates in plastic and reconstructive surgery, the application method that allows an objective assessment of asymmetry is necessary regarding the purpose of objective assessment and postoperative facial asymmetry results. When talking about the characteristics of the skin cover, elasticity and skin quality are the most important, as well as the presence of possible comorbidity with skin exposure^{24, 25}.

Analyzing the impact of the excision skin tumor width in the postoperative facial asymmetry, we found no statistically significant difference in the operated region shape between the groups of patients with various excision width preoperatively. However, there was the statistically highly significant difference among all the groups of patients, postoperatively in all scanning times. We can conclude that excision width has a role in the postoperative facial asymmetry. Besides, there was no statistically significant difference of operated region shape in the group with excision width < 10 mm, between all the scanning times. On the other hand, there was statistically highly significant difference in the groups with excision width 10–15 mm and > 15 mm, between all the scanning times. Thus, we can conclude that excision width < 10 mm does not cause postoperative asymmetry in patients with excised facial skin tumors.

Analyzing x, y and z coordinates of cephalometric points in the region of medial cheek, we found that there was no statistically significant difference among them in the

group of patients with excision width < 10 mm, regarding different scanning times, in relation to the same results when we analyzed the shape of operated region, but x2, y2 and y4 were changed postoperatively in the groups 10–15 mm and > 15 mm. That could be explained by high concavity and small surface, as morphologic characteristics of medial canthal region. In this region, the excision of higher width moved the landmarks more significantly than in other regions of the face.

The elasticity of the skin certainly influenced the decision on the suture line tension, but the overall morphological result was taken into account, and not only in the area of the suture line. In order to achieve a total good morphological-aesthetic result, it would be necessary to use the inductive-deductive, bi-directional and comprehensive approach. The quality of the skin in a similar way affected the overall morphologic-aesthetic re-

sult as well as the elasticity, but it was a more dominant biological aspect in the healing phase of the wound^{24,25}.

Conclusion

The determination of the x, y and z coordinates of the face, most accurately and most objectively, can be done with laser scanning. A modern method in morphometric analyses of scanned faces implies Procrustes analysis, as well as single coordinated measurements determining the level of statistically significant differences in shape.

The obtained results show that excision width of less than 10 mm does not affect the postoperative facial symmetry in the region of the medial cheek when post excisional defect is closed by direct suture.

R E F E R E N C E S

1. Boyette JR, Vural E. Cervicofacial advancement-rotation flap in midface reconstruction: forward or reverse? *Otolaryngol Head Neck Surg* 2011; 144(2): 196–200.
2. Cheong YW, Lo LJ. Facial asymmetry: etiology, evaluation, and management. *Chang Gung Med J* 2011; 34(4): 341–51.
3. Olesen OV, Paulsen RR, Højgaard L, Roed B, Larsen R. Motion tracking in narrow spaces: a structured light approach. *Med Image Comput Assist Interv* 2010; 13(Pt 3): 253–60.
4. Khavkin J, Ellis DA. Standardized photography for skin surface. *Facial Plast Surg Clin North Am* 2011; 19(2): 241–6.
5. Couch SM. Correction of Eyelid Crease Asymmetry and Ptosis. *Facial Plast Surg Clin North Am* 2016; 24(2): 153–62.
6. Kang SH, Kim MK, An SI, Lee JY. The effect of orthognathic surgery on the lip lines while smiling in skeletal class III patients with facial asymmetry. *Maxillofac Plast Reconstr Surg* 2016; 38(1): 18.
7. Galatius A, Goodall RN. Skull shapes of the Lissodelphininae: radiation, adaptation and asymmetry. *J Morphol* 2016; 277(6): 776–85.
8. Young NM, Sberathiya K, Gutierrez L, Nguyen E, Bekmezian S, Huang JC, et al. Facial surface morphology predicts variation in internal skeletal shape. *Am J Orthod Dentofacial Orthop* 2016; 149(4): 501–8.
9. Darby LJ, Millett DT, Kelly N, McIntyre GT, Cronin MS. The effect of smiling on facial asymmetry in adults: a 3D evaluation. *Aust Orthod J* 2015; 31(2): 132–7.
10. Belcastro A, Willing R, Jenkyn T, Johnson M, Galil K, Yazdani A. A Three-dimensional Analysis of Zygomatic Symmetry in Normal, Uninjured Faces. *J Craniofac Surg* 2016; 27(2): 504–8.
11. Tominaga K, Habu M, Tsurushima H, Takahashi O, Yoshioka I. CAD/CAM splint based on soft tissue 3D simulation for treatment of facial asymmetry. *Maxillofac Plast Reconstr Surg* 2016; 38(1): 4.
12. Xiong Y, Zhao Y, Yang H, Sun Y, Wang Y. Comparison Between Interactive Closest Point and Procrustes Analysis for Determining the Median Sagittal Plane of Three-Dimensional Facial Data. *J Craniofac Surg* 2016; 27(2): 441–4.
13. Thiesen G, Gribel BF, Freitas MP. Facial asymmetry: a current review. *Dental Press J Orthod* 2015; 20(6): 110–25.
14. Winkelbach S, Molkenstruck S, Wahl FM. Low-Cost Laser Range Scanner and Fast Surface Registration Approach. Berlin Heidelberg: Springer, Verlag; 2006. p. 718–28.
15. Riml S, Piontke A, Larcher L, Kompatscher P. Quantification of faults resulting from disregard of standardised facial photography. *J Plast Reconstr Aesthet Surg* 2011; 64(7): 898–901.
16. Popić Ramac J, Hebrang A, Ivanović-Herceg Z, Vidjak V, Brnić Z, Novčić K, et al. The possibilities and limitations of direct digital radiography, ultrasound and computed tomography in diagnosing pleural mesotelioma. *Coll Antropol* 2010; 34(4): 1263–71.
17. Li G, Ballangrud A, Kuo LC, Kang H, Kirov A, Lovelock M, et al. Motion monitoring for cranial frameless stereotactic radiosurgery using video-based three-dimensional optical surface imaging. *Med Phys* 2011; 38(7): 3981–94.
18. Eren G, Aubreton O, Meriaudeau F, Sanchez Secades LA, Fofi D, Naskali AT, et al. Scanning from heating: 3D shape estimation of transparent objects from local surface heating. *Opt Express* 2009; 17(14): 11457–68.
19. Hashimoto T, Thompson GE, Zhou X, Wuthers PJ. 3D imaging by serial block face scanning electron microscopy for materials science using ultramicrotomy. *Ultramicroscopy* 2016; 163: 6–18.
20. Borrett S, Hughes L. Reporting methods for processing and analysis of data from serial block face scanning electron microscopy. *J Microsc* 2016; 263(1): 3–9.
21. Colon J, Lim H. Shaping field for 3D laser scanning microscopy. *Opt Lett* 2015; 40(14): 3300–3.
22. Kim SH, Jung WY, Seo YJ, Kim KA, Park KH, Park YG. Accuracy and precision of integumental linear dimensions in a three-dimensional facial imaging system. *Korean J Orthod* 2015; 45(3): 105–12.
23. Lippold C, Liu X, Wangdo K, Drerup B, Schreiber K, Kirschneck C, et al. Facial landmark localization by curvature maps and profile analysis. *Head Face Med* 2014; 10: 54.
24. Charlier P, Froesch P, Huynh-Charlier I, Fort A, Hurel A, Jullien F. Use of 3D surface scanning to match facial shapes against altered exhumed remains in a context of forensic individual identification. *Forensic Sci Med Pathol* 2014; 10(4): 654–61.
25. Masuda Y, Oguri M, Morinaga T, Hirao T. Three-dimensional morphological characterization of the skin surface microtopography using a skin replica and changes with age. *Skin Res Technol* 2014; 20(3): 299–306.

Received on June 13, 2018

Revised on July 30, 2018

Accepted on September 3, 2018

Online first September, 2018.