



Suppurative gastritis in a HIV-positive patient: A case report

Supurativni gastritis kod HIV pozitivnog bolesnika

Dragomir Damjanov*[†], Tomislav Preveden**[‡], Snežana Brkić**[‡],
Daniela Marić**[‡], Mirjana Živojinov*[§], Dimitrije Damjanov*[†], Željka Savić*[†],
Ivana Urošević*^{||}

University of Novi Sad, *Faculty of Medicine, Novi Sad, Serbia; Clinical Center of
Vojvodina, [†]Clinic for Gastroenterology and Hepatology, [‡]Clinic for Infectious Diseases,
[§]Center for Pathology and Histology, ^{||}Clinic of Haematology, Novi Sad, Serbia

Abstract

Introduction. Suppurative gastritis (SG) is a rare disease characterized by a bacterial infection of the stomach wall. This condition has high mortality rate, especially in patients with predisposing factors such as alcoholism, immunodeficiency and previous endoscopic gastric procedures. **Case report.** A 41 year old male was hospitalized with epigastric pain, fever and vomiting. The symptoms started a few days after esophagogastroduodenoscopy (EGD). His personal medical history included periodical excessive alcohol consumption. Based on initial blood tests the patient was diagnosed with sepsis and was promptly started a treatment with antibiotics. In the first few days of hospitalization there was an improvement in inflammation marker levels, but the patient was still febrile and with the referred epigastric pain. A computed tomography scan showed marked thickening of the gastric wall and EGD revealed deep ulcers in the stomach with fibrinopurulent exudate. Histological examination of gastric biopsies showed necrosis and abscesses. Blood cultures were positive for *Stenotrophomonas maltophilia* and *Pseudomonas aeruginosa* with subsequent change in antibiotics. The repeated blood tests showed leucopenia and the patient tested positive for human immunodeficiency virus (HIV). A second EGD showed pus in the stomach, with a gastric aspirate culture positive for *Enterococcus spp.* The treatment was modified and a third EGD showed healed gastric mucosa confirmed by histopathological evaluation. **Conclusion.** Taking in consideration the high mortality rate of SG, it is necessary to make an early diagnosis and start the treatment against specific pathogens, since it can be crucial for a better outcome of this clinical condition.

Key words:

gastritis; hiv infections; diagnosis; anti-bacterial agents; treatment outcome.

Apstrakt

Uvod. Supurativni gastritis (SG) je retko oboljenje koje karakteriše bakterijska infekcija želudačnog zida. Ovo stanje prati visoka stopa mortaliteta, naročito kod bolesnika sa predisponirajućim faktorima kao što su alkoholizam, imunodeficijencija i prethodne endoskopske procedure u želucu. **Prikaz bolesnika.** Muškarac starosti 41 godinu je hospitalizovan zbog epigastričnog bola, febrilnosti i povraćanja. Simptomi su počeli nekoliko dana nakon ezofagogastroduodenoskopije (EGD). U ličnoj anamnezi naveo je periodično ekscesivno konzumiranje alkohola. Na osnovu prvobitnih laboratorijskih nalaza, bolesniku je postavljena dijagnoza sepse i započeta antibiotska terapija. Prvih nekoliko dana hospitalizacije došlo je do poboljšanja markera inflamacije, ali su kod bolesnika perzistirali febrilnost i epigastrični bol. Kompjuterizovanom tomografijom zabeleženo je zadebljanje zida želuca, a tokom EGD viđene su duboke ulceracije i fibrinopurulentni eksudat u želucu. Histološkim pregledom biopsija želuca uočeno je prisustvo nekroze i apscesa. Hemokulture su bile pozitivne na *Stenotrophomonas maltophilia* i *Pseudomonas aeruginosa*, nakon čega je korigovana antibiotska terapija. U ponovljenim laboratorijskim nalazima zabeležena je leukopenija, a test na virus humane imunodeficijencije (HIV) je bio pozitivan. Kontrolnom EGD viđeno je prisustvo gnoja u želucu, a kulturom gastričnog aspirata izolovan je *Enterococcus spp.* Terapija je korigovana i poslednjom EGD viđena je zaceljena sluznica želuca, što je i potvrđeno patohistološkim pregledom. **Zaključak.** Uzimajući u obzir visoku stopu mortaliteta SG, neophodno je rano postaviti dijagnozu i započeti lečenje protiv specifičnog uzročnika, što može biti presudno za bolji ishod ovog kliničkog stanja.

Ključne reči:

gastritis; infekcija, hiv; dijagnoza; antibiotici; lečenje, ishod.

Introduction

Suppurative gastritis (SG), also known as phlegmonous gastritis, is a rare disease characterized by a bacterial infection of the stomach wall¹⁻³. It is usually related to *Streptococcus* infection⁴. This condition has high mortality rate, around 27%, especially in patients with predisposing factors such as alcoholism, immunodeficiency and previous endoscopic gastric procedures^{1,5}. Early diagnosis and rapid antibiotic treatment, with or without surgery, are pivotal for the survival of patients with SG^{1,3}.

Herein, we report the first case, to our knowledge, of SG caused by *Enterococcus spp.* in a human immunodeficiency virus (HIV) patient.

Case report

A 41 year old male presented at the Emergency Department of Clinical Center of Vojvodina in Novi Sad (Serbia), with a two days history of severe epigastric pain, fever and vomiting. These symptoms started a few days after the execution of esophagogastroduodenoscopy (EGD) following the eradication treatment for *Helicobacter pylori* gastritis. His personal medical history included periodical excessive alcohol consumption and multiple fractures after a car accident.

Laboratory test results on hospital admission revealed increased inflammatory markers – C reactive protein 285.9 mg/L, procalcitonin 40.76 ng/mL, increased levels of blood urea nitrogen (14.2 mmol/L) and serum creatinine (323 μmol/L) and thrombocytopenia (119×10^9 /mL). Based on these results the patient was initially diagnosed with sepsis and was promptly started a treatment with ceftriaxone, ciprofloxacin and metronidazole. An abdominal computed tomography (CT) scan showed marked thickening of the gastric wall, splenomegaly and enlarged mesenteric lymph nodes. In the first few days of hospitalization, we registered an improvement in inflammation marker levels, but the patient was still febrile and with the referred epigastric pain. However, the blood cultures were negative.

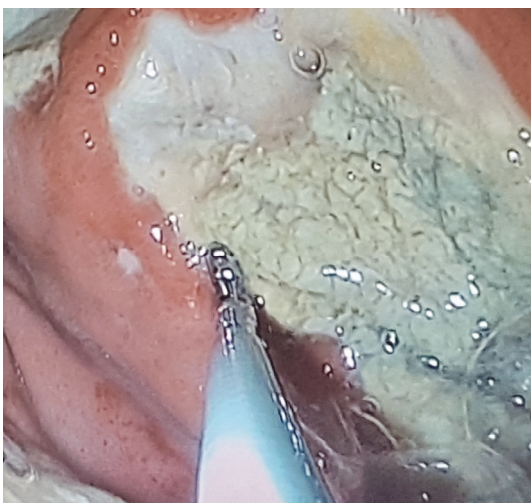


Fig. 1 – Esophagogastroduodenoscopy revealed multiple deep ulcer (diametar 3.5 cm) in the gastric corpus with fibrinopurulent exudate.

Due to the CT finding, EGD was performed and it revealed multiple deep ulcers (diameter 3.5 cm) in the gastric corpus with fibrinopurulent exudate (Figure 1). Consequently, the patient was switched to total parental nutrition. New blood cultures were positive for *Stenotrophomonas maltophilia* and *Pseudomonas aeruginosa*, with subsequent change in antibiotic treatment with amoxicillin and gentamicin. Histological examination of gastric biopsies showed necrotic detritus on the surface of gastric mucosa with coagulation necrosis and abscesses (Figure 2).

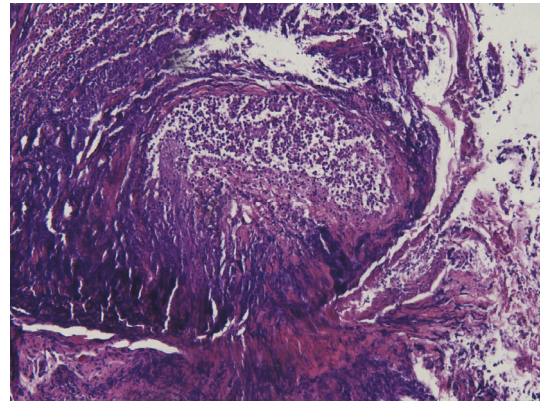


Fig. 2 – Histological examinations of gastric biopsies showed necrotic detritus on the surface of gastric mucosa with coagulation necrosis and abscesses.

Blood tests, repeated in the third week after admission, showed leucopenia, and in suspicion of immunodeficiency the patient was screened for HIV and the test came back positive. In the fifth week of illness, a second EGD was performed and showed signs of inflammation and pus in the stomach (Figure 3), with a gastric aspirate culture positive for *Enterococcus spp.* In accordance with antibiotic resistance, the treatment was modified with vancomycin, and after two weeks, a third EGD showed healed gastric mucosa confirmed by histopathological evaluation (Figure 4).

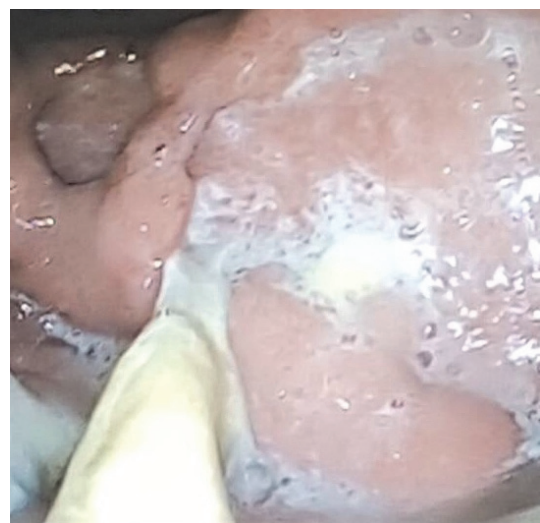

Fig. 3 – A second esophagogastroduodenoscopy in the fifth week of illness was performed and showed signs of inflammation and pus in the stomach.

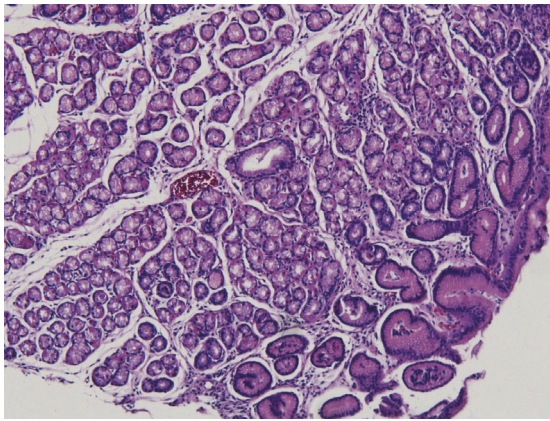


Fig. 4 – A third esophagogastroduodenoscopy showed healed gastric mucosa confirmed by histopathological evaluation.

Discussion

SG is an exceedingly rare diagnosis⁶. It is more common in patients with gastrointestinal comorbidities that cause mucosal injury such as chronic gastritis, gastric cancer or ulcer⁵. Medical history might reveal esophagectomy, gastric biopsies and other invasive procedures performed in weeks preceding the initiation of symptoms¹. Around half of the patients diagnosed with purulent gastritis have immunosuppression factors¹. It is also closely related to septicemia⁵.

Gastric ulcers in patients with HIV infection are most commonly associated with opportunistic infections (*Mycobacterium avium*, cytomegalovirus or herpes simplex virus) or opportunistic tumors. So far, the only known case of purulent gastritis in a HIV patient was related to a patient with Kaposi sarcoma⁷. Pathogens causing SG can be identified from gastric tissue and fluid cultures². The most frequent pathogen is *Streptococcus spp.* (especially *S. pyogenes*) in about 57%–70% of cases^{1,3,4}. Other identified pathogens include *Staphylococcus spp.*, *Escherichia coli*, *Haemophilus in-*

fluenzae, as well as *Proteus* and *Clostridium spp*^{1,3,4}. Polymicrobial infection is described in around 17% of cases¹. In our case two bacteria were identified in the blood cultures, and *Enterococcus spp.* was isolated from the gastric aspirate.

The usual clinical presentation of SG consists of severe and acute epigastric pain, fever and vomiting⁵. As these symptoms are nonspecific, SG is often misdiagnosed as more common conditions such as perforated peptic ulcer and other causes of acute abdomen⁵.

SG can be initially diagnosed by EGD, abdominal CT or endoscopic ultrasound (EUS), while the definitive diagnosis is acquired by histological examination and culture of the gastric biopsies⁵. Typical signs of SG during EGD include erythema and edema of the gastric folds with fibrinopurulent exudate¹. CT scan and EUS may show thickening of the gastric wall^{1,3}.

Although SG predominantly involves the submucosa of the stomach, the inflammation may progress and involve all layers³. Histopathologically, the submucosa is thickened due to infiltration by neutrophil granulocytes and plasma cells^{3,5}. In advanced cases, possible histological findings include necrosis, abscess formation, intramural hemorrhage and thrombosis of the submucosal blood vessels⁵. Differential diagnosis of SG commonly includes superinfected malignancy, gastric lymphoma, gastrointestinal stromal tumor, tuberculosis^{1,6}.

Optimal treatment for SG consists of antibiotics with surgery reserved for refractory and complicated cases¹. The histological description was a key factor in our case because it provided prompt diagnosis and early treatment.

Conclusion

Taking in consideration the high mortality rate of SG, it is necessary to make an early diagnosis and start the treatment against specific pathogens, since it can be crucial for a better outcome of this clinical condition.

REFERENCES

1. Rada-Palomino A, Muñoz-Díaz A, Pérez-Romero N, Vargas-Pierola H, Puértolas-Rico N, Ruiz-Campos L, et al. Phlegmonous gastritis: A rare entity as a differential diagnostic of an acute abdomen. Description of a case and a bibliographic review. *Rev Esp Enferm Dig* 2014; 106(6): 418–24.
2. Kato K, Tominaga K, Sugimori S, Nagami Y, Kamata N, Yamagami H, et al. Successful treatment of early-diagnosed primary phlegmonous gastritis. *Int Med* 2015; 54(22): 2863–6.
3. Kim GY, Ward J, Henessey B, Peji J, Godell C, Desta H, et al. Phlegmonous gastritis: case report and review. *Gastrointest Endosc* 2005; 61(1): 168–74.
4. Choong NW, Levy MJ, Rajan E, Kolars JC. Intramural gastric abscess: case history and review. *Gastrointest Endosc* 2003; 58(4): 627–9.
5. Park CW, Kim A, Cha SW, Jung SH, Yang HW, Lee YJ, et al. A case of phlegmonous gastritis associated with marked gastric distension. *Gut Liver* 2010; 4(3): 415–8.
6. Munroe CA, Chen A. Suppurative (phlegmonous) gastritis presenting as a gastric mass. *Dig Dis Sci* 2010; 55(1): 11–3.
7. Yu QQ, Tariq A, Unger SW, Cabello-Inchausti B, Robinson MJ. Phlegmonous gastritis associated with Kaposi sarcoma: a case report and review of the literature. *Arch Pathol Lab Med* 2004; 128(7): 801–3.

Received on July 3, 2018.

Accepted on July 16, 2018.

Online First September, 2018.