



Anterior intra-pelvic approach and *corona mortis* vascular anastomoses: A clinical anatomical study shows high frequency

Prednji intra-karlični pristup i *corona mortis* vaskularne anastomoze: kliničko anatomsko studija pokazuje visoku učestalost

Yunus Güzel*, Nuh Mehmet Elmadağ†, Mehmet Arazi‡, Kemal Emre Özen§, Aynur Emine Çiçekcibaşı||

Ordu University, Faculty of Medicine, *Department of Orthopedics and Traumatology, Ordu, Turkey; Bezmialem Vakif University, Faculty of Medicine, †Department of Orthopedics and Traumatology, İstanbul, Turkey; Private Farabi Hospital, ‡Department of Orthopedics and Traumatology, Konya, Turkey; İzmir Kâtip Çelebi University, Faculty of Medicine, §Department of Anatomy, İzmir, Turkey; Necmettin Erbakan University, Meram Faculty of Medicine, ||Department of Anatomy, Konya, Turkey

Abstract

Background/Aim. *Corona mortis* vascular anastomoses (CMVA) must be located during surgical gold standard treatment method for displaced acetabular fractures. This study aimed to answer the following questions: What is the clinical frequency observed of CMVA? What is the composition of CMVA: arterial, venous or a combination? **Methods.** A retrospective review was made of 31 patients (24 males, 7 females; mean age 43.5 years) who underwent surgery for acetabular fractures between 2011 and 2015. The anterior intra-pelvic (AIP) approach was applied to all patients. By examination of the intraoperative CMVA compositions, the frequency of CMVA was determined together with identification of venous or arterial formation and distance from the pubic symphysis. **Results.** CMVA was observed during dissection in 29 (94%) patients and was ligated. In 14 (45%) patients, CMVA was recorded as venous, in 7 (23%) patients as arterial and in 8 (26%) patients as both. The mean distance of CMVA from the pubic symphysis was 35.9 mm (range 21.6–48.7 mm). **Conclusion.** The results showed very high CMVA frequency in the AIP approach, higher than previously reported in the English literature. Orthopedic surgeons should be aware about CMVA while doing this approach in surgical treatment of acetabular fractures.

Key words: arteriovenous anastomosis; anatomy; orthopedics; acetabulum; wounds and injuries; pubic symphysis.

Apstrakt

Uvod/Cilj. *Corona mortis* vaskularne anastomoze (CMVA) moraju biti identifikovane i locirane u toku hirurškog zahvata koji predstavlja zlatni standard u lečenju dislociranih preloma acetabuluma. Cilj rada bio je da se odgovori na sledeća pitanja: kolika je klinička učestalost CMVA, kao i kakva je struktura CMVA – arterijska, venska ili kombinovana. **Metode.** Izvršena je retrospektivna analiza 31 bolesnika (24 žene i sedam muškaraca, prosečne starosti 43,5 godina) koji su operisani zbog frakture acetabuluma u periodu od 2011. do 2015. godine. Prednji intrakarlični (PIK) pristup je bio primenjen kod svih bolesnika. Intraoperativno su bili praćeni i beleženi: struktura CMVA i učestalost, istovremeno sa identifikacijom venske ili arterijske formacije, kao i udaljenost od pubične simfize. **Rezultati.** CMVA su bile uočene tokom disekcije kod 29 (94%) bolesnika i podvezane. Kod 14 (45%) bolesnika CM, kod sedam (23%) bolesnika arterijske i kod njih osam (26%) kombinovane. Prosečna udaljenost CMVA od pubične simfize iznosila je 35,9 mm (opseg 21,6–48,7 mm). **Zaključak.** Rezultati su pokazali veoma visoku učestalost CMVA kod PIK pristupa, višu od ranije objavljenih u literaturi na engleskom jeziku. Ortopedi bi trebali da ovo imaju u vidu kod PIK pristupa u hirurškom lečenju frakture acetabuluma.

Ključne reči: anastomoze, arteriovenske; anatomija; ortopedija; acetabulum; povrede; pubična simfiza.

Introduction

Surgical treatment is the gold standard treatment method for displaced acetabular fractures and successful clinical results have been reported in the long-term following internal fixation where anatomic reduction has been achieved^{1,2}. The most frequently used surgical approaches are the Kocher-Langenbeck and ilioinguinal approaches¹⁻⁵. The extended iliofemoral approach is recommended for complex fractures, but this approach also has high rates of complications and morbidity^{2,6}. In the last few decades, the anterior intrapelvic (AIP) approach has become known as a relatively less invasive approach for complex fractures, especially those involving the load-bearing roof and medial wall⁷⁻¹¹. There has continued to be increasing popularity of the technique due to highly encouraging studies^{5,7,9,11}.

In the AIP and ilioinguinal approaches, vascular anastomoses which provide the connection between the external and internal iliac vascular system on the posterior side of the superior pubic ramus, may be the cause of significant bleeding. Obturator vessels and nerves are the most important structures requiring attention because of their direct contact with the quadrilateral surface¹⁰. These vessels, which are known as *corona mortis* vascular anastomoses (CMVA), must be located during surgical exposure and appropriately tied or cauterized. First described by Albrecht von Haller (1708–1777), various studies have been conducted on the frequency of observation of these vessels, the anatomic variations and structural properties. The rate of frequency of observation has been reported as ranging from 1% to 100%^{9,12-17}.

The aim of this study was to answer the following questions: What is the clinical frequency observed of CMVA? In clinical cases, what is the composition of CMVA: arterial, venous or a combination?

Methods

A retrospective evaluation was made from the records of patients who had been treated for acetabular fractures with the AIP approach, between 2011 and 2015, in two different centers. Children fractures and geriatric age patients were excluded and a total of 31 patients' records were included in the study. The AIP approach had been applied to all patients and the operations were performed by two surgeons experienced in the field of trauma and pelvis surgery. Approval for the study was granted by the local Ethics Committee and the study was performed in accordance with the ethical standards laid down in the Declaration of Helsinki from 1964 and all subsequent revisions.

Preoperative anteroposterior (AP), iliac and obturator oblique pelvis radiographs and computed tomography (CT) images were taken. The fractures were classified according to the Judet et al.¹⁸ classification. All the fractures were evaluated clinically and radiologically as unstable and the decision was taken for surgery. In three patients, fractures were bilateral and extended to both hemipelvis. In four patients, there was acetabulum fracture together with a displaced pelvic fracture.

Surgical technique

The AIP approach technique was applied as defined in detail in the articles of Cole and Bolhofner³ and Hirvensalo et al.¹⁹. Patients were placed supine on the operating table to allow adequate visualization on AP and Judet radiographs (pelvic). Prophylactic antibiotic (cefazolin, 1 g iv) was routinely administered. The presence of CMVA was investigated during exposure in all cases. In this process, the anatomic properties of CMVA were recorded (placement, distance from the pubic symphysis, arterial, venous or both). Then, the vessels were appropriately tied.

Results

Demographic data of the included patients are shown in Table 1.

Table 1
Demographic data of included patients

Parameters	Values
Mean age in years (range)	43.5 (21–65)
Male : female, n (%)	24 : 7 (77.4 : 22.6)
Letournel classification, n	
anterior column	15
both columns	2
anterior column plus posterior hemi-transverse	6
transverse	6
T shaped	2

Very different rates related to CMVA visualization have been reported in cadaver and endoscopic studies (Table 2). The patients were operated on at mean 3.9 days, range: 1 to 9 days (Figure 1). Before the reduction of the particular fracture, any CMVA was found and ligated to prevent extensive bleeding. CMVA were determined during dissection in 29 (94%) patients. In respect of vascular composition of CMVA, three types were identified (Figure 2): type I, purely arterial CMVA (n = 7/31, 23%); type II, purely venous CMVA (n = 14/31, 45%) and type III, a combination of both arterial and venous connections located on the behind of superior ramus of the pubic bone (n = 8/31, 26%). The average distance of CMVA from the pubic symphysis was 35.9 mm (range 21.6 – 48.7 mm).

Postoperative foot drop was observed in one patient, obturator nerve palsy in two patients, partial iliac vein damage in one patient, and external femoral vein damage also in one patient. All vascular injuries were treated with primary sutures during the surgery. Drop foot was resolved after six months and all obturator nerve palsies resolved within 3 months after the index surgeries.

Table 2
Incidence of various connections (vascular, arterial and venous) from the references and the present study

Study	Corona mortis (%)	Arterial connections (%)	Venous connections (%)	Arterial and venous connections (%)	Specimens
Berberoğlu et al. ¹²	-	8	96	-	7 cadaver dissection and 28 patients endoscopic
Karakurt et al. ²⁴	-	28.5	-	-	98 patients, angiography
Sarikcioglu et al. ¹⁷	-	20	14	-	54 cadaver halves
Okcu et al. ²²	61	19	52	-	150 cadaver halves
Hong et al. ²⁸	72	-	-	-	50 cadaver halves
Pungpapong et al. ²⁹	77.27	-	-	-	66 pelvic halves
Darmanis et al. ¹³	83	-	-	-	80 cadaver halves
Rusu et al. ¹⁶	80	31	18	53	40 cadaver halves
Kacra et al. ¹⁰	40	-	40	-	10 cadaver halves
Stavropoulou-Deli and Anagnostopoulou ²³	28.5	40	50	-	70 cadaver halves
Elmadağ et al. ⁹	100	29.4	70.6	-	17 patients (AIP)
Current study	94	24	48	28	31 patients (AIP)

AIP – anterior intra-pelvic.

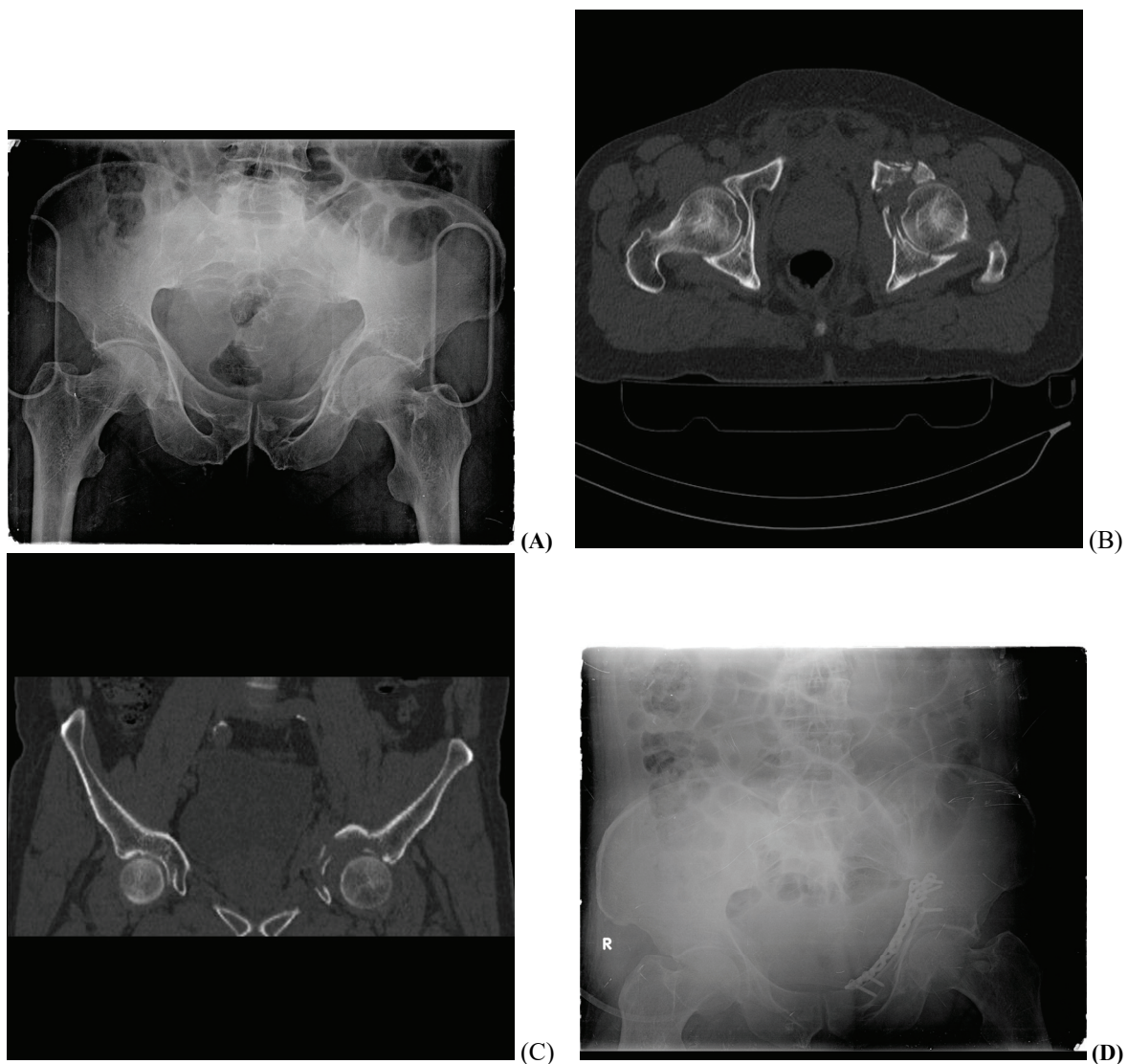
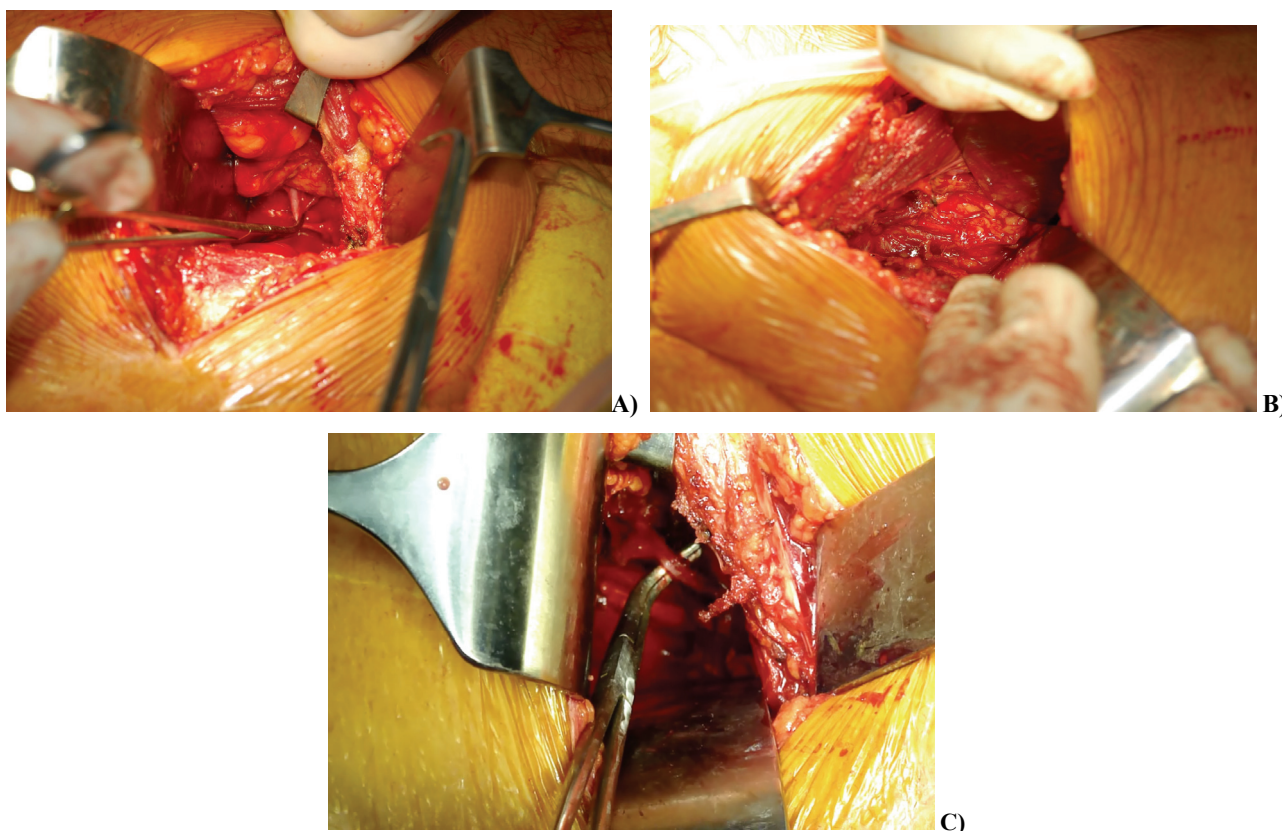


Fig. 1 – A 65-year-old male patient suffered with an acetabular fracture of the left hip after a simple fall (A); Tomography scans show dome impaction and displaced anterior column fracture on the left acetabular bone (B, C); Anatomic surgical reduction of the fracture and restoration of the dome impaction can be seen on the postoperative pelvic x-ray (D).



**Fig. 2 – Surgical exploration of *corona mortis* vascular anastomoses (CMVA):
A) arterial; B) venous; C) both.**

Discussion

While *corona mortis* has a place in some studies as an anatomic variation, other researchers have stated that there are anatomic variations within CMVA. In this study, the AIP approach was applied to 31 patients and CMVA were identified in the majority of the patients (29/31, 94%). There was some form of anastomosis in almost all the hemi-pelvises. The thickness varied but nearly all were large enough to be a cause of bleeding.

In studies of 50 cadaver halves by Tornetta et al.²⁰, anastomosis was determined between the obturator and external iliac system vessels at the rate of 84%. In these cases, the arterial type was determined together with *corona mortis* at 34%, venous at 70% and a combination of both types at 20%. In dissections of 7 cadavers by Berberoğlu et al.¹², and in additional endoscopic evaluations of 28 cases, venous anastomosis was seen in 96% and in 8% accessory branches of the obturator artery. In the endoscopic examination of 141 hemi-pelvises of 121 patients by Lau and Lee²¹, *corona mortis* was encountered as arterial in 22%, aberrant obturator vein in 27%, and as arterial or venous in 40%. Sarikcioglu et al.¹⁷ determined venous anastomosis at a rate of 20% in 27 cadavers (54 cadaver halves) and the obturator artery was seen to originate from the inferior epigastric artery in 14%. In dissections of 150 cadaver halves of 75 cadavers, Okcu et al.²² determined vascular anastomoses between the obturator and external iliac systems in 91 of 150 sides (61%), and an-

astomotic veins in 78 of 150 exposures (52%), arterial connections were seen in 29 (19%) of the exposures.

Rusu et al.¹⁶ noticed the differences and systematically recorded the possibilities of CMVA, thereby determining in a study of 40 hemi-pelvis dissections from 20 cadavers, 32 (80%) CMVA, of which 10 (31%) were arterial, 16 (53%) arterial and venous and 6 (18%) venous. In the dissection of 10 hemi-pelvic cadavers, Kacra et al.¹⁰ determined 4 (40%) venous CMVA. In the dissection of 20 hemi-pelvis of 10 cadavers by Stavropoulou-Deli and Anagnostopoulou²³, eight arterial and 10 venous CMVA were determined. In the current study, CMVA were present in 94% and determined as venous in 45% (n = 14/31), arterial in 23% (n = 7/31) and a combination of both in 26% (n = 8/31) of the patients. Darmanis et al.¹³, in an examination of the hemipelvis of 80 cadavers, any vessel was determined crossing the superior pubic ramus in 83%, arterial anastomosis was determined in 36% and venous anastomosis in 60%, but in 492 operations applied with an anterior approach (ilioinguinal or AIP), *corona mortis* was encountered in only 5 cases. Findings in the operational group could be interpreted in complete contrast to those of the current study. However, there are few studies in literature presenting data supporting this.

When clinical studies have been examined, Elmadağ et al.⁹ determined CMVA in all of 17 acetabular fractures operated on with the AIP approach, 70.6% of which were reported as venous and 29.4% as arterial CMVA. In a series of 55 cases, Cole and Bolhofner³, who first defined the AIP

approach, first reported that anatomic vascular blockage related to the technique was anastomosis between the obturator vessels and the inferior epigastric artery and these anastomoses are often to be found but they are sometimes of different dimensions. From clinical studies, Cole and Bolhofner³ and Elmadağ et al.⁹ determined CMVA in every case at rates similar to those of the current study. There are angiographic studies of *corona mortis* in literature, but angiographic studies only evaluate arterial anastomoses and do not give information about venous connections^{16, 24}. Advanced radiological techniques and fine slice thicknesses can provide the determination of higher incidence of *corona mortis*.

When examined anatomically, CMVA are immediately behind the superior pubic ramus and lateral of the pubic symphysis. In various studies in literature there are a series of findings about the thickness of CMVA and the distance to the pubic symphysis (Table 3). Rusu et al.¹⁶ classified CMVA into four arterial subtypes, three venous subtypes and the combined type of arterial and venous anastomosis together. In studies by Sakthivelavan et al.²⁵ in which the origin of the obturator artery was examined in 116 hemi-pelvis, the obturator artery was determined to originate from the internal iliac system in 60.3% and from the external iliac system in 39.7% of cases. It was determined that, in 90% of the hemi-pelvises, the superior pubic ramus was crossed by various shapes and numbers of veins, to be drained from external iliac vein to obturator foramen. Similarly, Pai et al.²⁶ reported that in the majority of cases, the superior pubic ramus was traversed by multiple venous vessels but a percentage was not reported, whereas the rate of obturator artery crossing the superior pubic ramus was stated as 21% in total (19% originating from the external iliac system and 2% of dual origin, n = 98). There are studies in literature stating that the

condition is less important when vascular diameter is < 1 mm¹². The high incidence of CMVA obtained in the current study and that these vessels were of a thickness which could lead to bleeding, raises the question of whether very small diameter CMVA (< 1 mm) have been disregarded by many researchers or could not be determined. The importance of this question is further increased in studies not reflecting the findings of vessels below 2 mm²⁷⁻²⁹.

The area of this study offering enlightenment can be considered to be not the presence of CMVA but that there may be variations in origins and thickness of the veins which comprise CMVA. In addition, CMVA not seen in some cases in clinical studies may be due to injury during trauma, and not visualized in some cases in cadaver studies may be due to vascular collapse occurring due to the lack of blood circulation in the veins which form CMVA or because of a fixation technique and time elapsed since the fixation. Examination of fresh cadavers in anatomic studies in this area would raise rates of CMVA encountered by researchers. One of the strengths giving importance to the current study is that CMVA could be seen in the majority of the cases in a living population. In this respect, need to make a careful surgery is essential for the AIP approach.

Limitations of this study are following: the number of cases was low, vascular diameters were not measured quantitatively, and detailed origins of the vessels were not determined. As the incision did not allow for it during the operation and because of the inherent risk, vessel origins were not determined. However, strong aspect of the study is that it drew attention to the high presence of CMVA. In addition, showing live CMVA which did not collapsed during the operation is strength of this study compared to previous cadaver and angiographic studies.

Table 3

The distance between the *corona mortis* and the pubic symphysis

Study	Arterial <i>corona mortis</i>		Venous <i>corona mortis</i>		Arterial or venous connecting vessel	
	Diameter	Distance from pubic symphysis	Diameter	Distance from pubic symphysis	Diameter	Distance from pubic symphysis
Berberoğlu et al. ¹² mean (range), mm	0.98 (0.6–1.2)	-	3.3 (2.2–4.9)	-	-	40.4 (33.2–52.7)
Hong et al. ²⁸ mean (range), mm	-	-	-	-	2.60 (2.0–4.2)	52 (38–68)
Karakurt et al. ²⁴ mean (range), mm	-	33.4 (21.4–41)	-	-	-	-
Okcu et al. ²² mean (range), mm	-	64 (45–90)	-	56 (37–80)	-	-
Tornetta et al. ²⁰ mean (range), mm	-	-	-	-	-	62 (30–90)
Darmanis et al. ¹³ mean (range), mm	-	71 (42–88)	-	65 (39–82)	-	-
Stavropoulou-Deli and Anagnostopoulou ²³ (mean), mm	3	52.4	3.13	46.7	-	-
Current study mean (range), mm	-	-	-	-	-	35.9 (21.6–48.7)

Conclusion

As this study was the clinical one with the very high observed frequency of CMVA, higher than previously re-

ported in the English literature, it can be considered necessary to take great care with these vessels during surgical exposure. Anastomoses have a different anatomic structure and include variations in size and origin.

R E F E R E N C E S

- Rommens P, Broos P, Vanderschot P. Preparation and technique for surgical treatment of 225 acetabulum fractures. 2 year results of 175 cases. *Unfallchirurg* 1997; 100(5): 338–48. (German)
- Tannast M, Najibi S, Matta JM. Two to twenty-year survivorship of the hip in 810 patients with operatively treated acetabular fractures. *J Bone Joint Surg Am* 2012; 94(17): 1559–67.
- Cole JD, Bolbofner BR. Acetabular fracture fixation via a modified Stoppa limited intrapelvic approach. Description of operative technique and preliminary treatment results. *Clin Orthop Relat Res* 1994; (305): 112–23.
- Hammad AS, El-Khadrawe TA. Accuracy of reduction and early clinical outcome in acetabular fractures treated by the standard ilio-inguinal versus the Stoppa/iliac approaches. *Injury* 2015; 46(2): 320–6.
- Isaacson MJ, Taylor BC, French BG, Poka A. Treatment of acetabulum fractures through the modified Stoppa approach: strategies and outcomes. *Clin Orthop Relat Res* 2014; 472(11): 3345–52.
- Hirvensalo E, Lindabl J, Kiljunen V. Modified and new approaches for pelvic and acetabular surgery. *Injury* 2007; 38(4): 431–41.
- Archdeacon MT, Kazemi N, Guy P, Sagi HC. The modified Stoppa approach for acetabular fracture. *J Am Acad Orthop Surg* 2011; 19(3): 170–5.
- Bastian JD, Tannast M, Siebenrock KA, Keel MJ. Mid-term results in relation to age and analysis of predictive factors after fixation of acetabular fractures using the modified Stoppa approach. *Injury* 2013; 44(12): 1793–8.
- Elmadag M, Güzel Y, Acar MA, Uzer G, Arazi M. The Stoppa approach versus the ilioinguinal approach for anterior acetabular fractures: a case control study assessing blood loss complications and function outcomes. *Orthop Traumatol Surg Res* 2014; 100(6): 675–80.
- Kacra BK, Arazi M, Çiçekcibaş AE, Büyükmumcu M, Demirci S. Modified medial Stoppa approach for acetabular fractures: an anatomic study. *J Trauma* 2011; 71(5): 1340–4.
- Sagi HC, Afsari A, Dzijadosz D. The anterior intra-pelvic (modified rives-stoppa) approach for fixation of acetabular fractures. *J Orthop Trauma* 2010; 24(5): 263–70.
- Berberoğlu M, Uz A, Özmen MM, Bozkurt MC, Erkan C, Taner S, et al. Corona mortis. *Surg Endosc* 2001; 15(1): 72–5.
- Darmanis S, Lewis A, Mansoor A, Bircher M. Corona mortis: an anatomical study with clinical implications in approaches to the pelvis and acetabulum. *Clin Anat* 2007; 20(4): 433–9.
- Gobrecht U, Kühn A, Fellman B. Injury of the corona mortis during vaginal tape insertion (TVT-Secur™ using the U-Approach). *Int Urogynecol J* 2011; 22(4): 443–5.
- Ramser M, Messmer AS, Zbinden I, Von Holzen U, Nebiker CA. Incarcerated obturator hernia—laparoscopic repair with intra-operative view of the corona mortis. *J Surg Case Rep* 2014; 2014(8): pii: rju081.
- Rusu MC, Cergan R, Motoc AG, Folescu R, Pop E. Anatomical considerations on the corona mortis. *Surg Radiol Anat* 2010; 32(1): 17–24.
- Sarikcioglu L, Sindel M, Akyildiz F, Gur S. Anastomotic vessels in the retropubic region: corona mortis. *Folia Morphol (Warsz)* 2003; 62(3): 179–82.
- Judet R, Judet J, Lanzetta A, Letournel E. Fractures of the acetabulum. Classification and guiding rules for open reduction. *Arch Orthop* 1968; 81(3): 119–58. (Italian)
- Hirvensalo E, Lindabl J, Böstman O. A new approach to the internal fixation of unstable pelvic fractures. *Clin Orthop Relat Res* 1993; (297): 28–32.
- Tornetta P 3rd, Hochwald N, Levine R. Corona mortis. Incidence and location. *Clin Orthop Relat Res* 1996; (329): 97–101.
- Lau H, Lee F. A prospective endoscopic study of retropubic vascular anatomy in 121 patients undergoing endoscopic extraperitoneal inguinal hernioplasty. *Surg Endosc* 2003; 17(9): 1376–9.
- Okcu G, Erkan S, Yercan HS, Ozic U. The incidence and location of corona mortis: a study on 75 cadavers. *Acta Orthop Scand* 2004; 75(1): 53–5.
- Stavropoulou-Deli A, Anagnostopoulou S. Corona mortis: anatomical data and clinical considerations. *Aust N Z J Obstet Gynaecol* 2013; 53(3): 283–6.
- Karakurt L, Karaca I, Yilmaz E, Burma O, Serin E. Corona mortis: incidence and location. *Arch Orthop Trauma Surg* 2002; 122(3): 163–4.
- Sakthivelavan S, Aristotle S, Sendiladibban SD, Jebakani CF. Variability of the obturator artery and its surgical implications in a South Indian population. *Eur J Anat* 2013; 17(3): 159–65.
- Pai MM, Krishnamurthy A, Prabhu LV, Pai MV, Kumar SA, Hadimani GA. Variability in the origin of the obturator artery. *Clinics (Sao Paulo)* 2009; 64(9): 897–901.
- Teague DC, Graney DO, Routh ML Jr. Retropubic vascular hazards of the ilioinguinal exposure: a cadaveric and clinical study. *J Orthop Trauma* 1996; 10(3): 156–9.
- Hong HX, Pan ZJ, Chen X, Huang ZJ. An anatomical study of corona mortis and its clinical significance. *Chin J Traumatol* 2004; 7(3): 165–9.
- Pungpapong S, Thum-umnanysuk S. Incidence of corona mortis; preperitoneal anatomy for laparoscopic hernia repair. *J Med Assoc Thai* 2005; 88(Suppl 4): S51–3.

Received on February 1, 2018.

Revised on August 14, 2018.

Accepted on September 12, 2018.

Online First September, 2018.