



The influence of temporary occlusion of parent vessel on outcome of surgical treatment of ruptured cerebral aneurysms

Uticaj privremene okluzije nosećeg krvnog suda na rezultat hirurškog lečenja rupturiranih cerebralnih aneurizmi

Vesna Nikolov*, Miša Radisavljević*, Boban Jelenković*,
Marija Andjelković Apostolović†

Clinical Center of Niš, *Department of Neurosurgery, Niš, Serbia; †Institute for Public Health, Niš, Serbia

Abstract

Background/Aim. Aneurysm rupture followed by subarachnoid or intracerebral haemorrhage is always current topic and poses a great challenge to neurosurgeons. The aim of the study was to establish whether applying temporary occlusion before placing a final clip was justified. **Methods.** A prospective study was conducted on patients with aneurysm rupture, treated at Neurosurgical Clinic in Niš from January 2012 to December 2016. Patients belonging to I and II and 1, 2 and 3 grades according to the Hunt-Hess grading system and Fisher scale, respectively, were monitored. **Results.** In 85, out of total 182 bleeding aneurysms that were treated, a neurosurgeon decided to apply temporary clipping before placing the final clip. Temporary occlusion significantly influenced the presence of resulting neurological deficit. **Conclusion.** The application of temporary occlusion facilitates placing the final clip but also affects the occurrence of neurological deficits. It is assumed that this is a consequence of caused vasospasm, considering that these are bleeding aneurysms.

Key words:

intracranial aneurysm; aneurysm ruptured; therapeutic occlusion; neurosurgical procedures; vascular surgical procedures; treatment outcome.

Apstrakt

Uvod/Cilj. Ruptura aneurizme praćena subarahnoidalnom ili intecerebralnom hemoragijom je uvek aktuelna i predstavlja veliki izazov za neurohirurge. Cilj rada je bio da se ustanovi da li je opravdana primena privremene okluzije pre plasiranja definitivnog klipa. **Metode.** Sprovedena je je prospektivna studija u koju su bili uključeni bolesnici kod kojih je došlo do rupture aneurizme, lećeni na Neurohirurškoj klinici u Nišu, u periodu od januara 2012. do decembra 2016. godine. Bolesnici su po Hunt-Hess-ovoj gradaciji pripadali I i II, a po Fisher-ovoj skali 1, 2 i 3 stepenu gradacije. **Rezultati.** Od ukupno rešavane 182 krvareće aneurizme, kod njih 85 hirurg se odlučio da primeni privremeno klipovanje pre definitivnog plasiranja klipa. Privremena okluzija imala je znaćajan uticaj na prisustvo rezultirajućeg neurološkog deficita. Primena privremene okluzije znaćajno je uticala na prisustvo nastalog neurološkog deficita. **Zaključak.** Primena privremene okluzije olakšava plasiranje definitivnog klipa, ali utiće i na pojavu neurološkog deficita. Pretpostavlja se da je to posledica izazivanog vazospazma, uzimajući u obzir da se radi o krvarećim aneurizmama.

Ključne reći:

aneurizma, intrakranijalna; aneurizma, ruptura; okluzija, terapijska; neurohirurške procedure; hirurgija, vaskularna, procedure; lećenje, ishod.

Introduction

Aneurysms are a distention to the brain blood vessels caused by the weakness of the blood vessel wall. The spots where arteries branch off are the most common places in which aneurysms can be found. Over time, under the influence of blood wave in the blood vessel itself, the wall is getting increasingly thinner and

the distention becomes sac-shaped (saccular distention) or spindle-shaped (fusiform distention). Such an aneurysm does not give any symptoms. It is usually detected as a sporadic finding during the examination. A serious manifestation of an aneurysm is its rupture. The annual incidence of bleeding is 10–14/100.000; 15–20% aneurysms bleed in the course of life, most often between the age of 40 and 60 ¹.

According to most literature data, total aneurysm-related mortality due to subarachnoid bleeding is 32–67%, decreasing with the advancement of therapy in the last three decades by about 0.5% per year²⁻⁴. Studies also say that gender does not affect the patient's outcome after aneurysm rupture^{4,5-7}.

The symptoms of bleeding aneurysm are a severe headache accompanied by nausea and vomiting, as well as impaired consciousness. The depth of consciousness impairment depends on the magnitude of aneurysm bleeding. Usually, soon after rupture, it is temporarily spontaneously closed by a coagulum. The patient's condition stations at a certain level and then diagnostics can be approached. The method of choice today is brain multislice computed tomography (MSCT) with angio scan revealing both the existence of subarachnoid hemorrhage or intracerebral hematoma and the site of aneurysmal enlargement on the blood vessel. A surgeon decides whether aneurysm diagnosis using MSCT angio scan is sufficient or it is necessary to approach digital subtraction angiography (DSA). This diagnostic method enables a better display of localization, size and especially the position of the aneurysm neck in relation to the blood vessel. Diagnosis is followed by aneurysm treatment with two methods used in practice, surgical treatment by aneurysm clipping, or endovascular closing of enlargement using spirals. In this paper, we focused on the surgical way of treating a bleeding aneurysm and on the frequent surgeon's dilemma whether to apply a temporary occlusion before the final clipping of an aneurysm or not. Elective temporary occlusion in the treatment of intracranial aneurysms was first performed by Jefferson in 1928. Temporary clamping and moderate hypothermia in the treatment of aneurysms were reported by Suzuki et al.⁸ in 1969. The authors pointed that intermittent reperfusion allowed prolongation of the total time of temporary occlusion. The technique of safe clipping as generally used depends on the temporary occlusion of the cerebral vasculature during surgery. It may lessen the risk of intraoperative aneurysm rupture and also allows evacuation of intramural calcification and thrombosis before definitive clipping in large aneurysms⁹.

Methods

A prospective study was conducted on patients with aneurysm rupture, treated at the Neurosurgical Clinic in Niš,

in the period from January 2012 to December 2016. According to initial clinical status, we could grade patients using the Hunt-Hess scale, and, according to their brain CT scan findings they were graded by using the Fisher scale. Patients who belonged to I and II and 1, 2 and 3 grades by the Hunt-Hess and Fisher scales, respectively, were monitored. The study covered a total of 182 patients who were surgically treated for aneurysmal change in brain blood vessels. Patients were all of the cases initially postoperatively treated in the Intensive Care Unit. All of the patients received anti-edematous therapy, analgesics before and after the operation.

Results

Out of total 182 bleeding aneurysms treated, in 85 a surgeon decided to apply temporary clipping before placing the final clip (Figure 1).

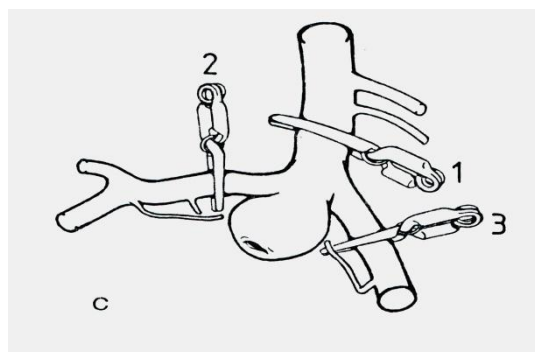


Fig. 1 – The application of a temporary occlusion.

As far as the localization of treated aneurysms was concerned, no statistical significant difference was found in relation to the application of temporary clipping before the final clip placement ($\chi^2 = 0.632$; $p = 0.959$), (Table 1).

Ischemic changes diagnosed using the brain MSCT with associated neurological deficit were recorded in 12 (12/85; 14.1%) of the patients treated with temporary occlusion while the same was present in 8 (8/97; 8.2%) of the patients with no temporary occlusion.

The application of temporary occlusion caused significantly higher incidence of neurological deficit in comparison with the treatment with no use of temporary clipping ($\chi^2 = 8.801$; $p = 0.003$), (Table 2).

The lethal outcome occurred in 7 (7/85, 8.2%) of the

Table 1

Aneurysm localisation	Localization of surgically treated aneurysms		χ^2	p
	With applied temporary occlusion	Without applied occlusion		
Arteria carotis	10	12	0.632	0.959
Arteria cerebri posterior	8	12		
Arteria cerebri anterior	5	5		
Arteria cerebri media	38	44		
Arteria communicans antrior	24	24		
Total	85	97		

Table 2

Neurological deficit				
Ischemic changes	With applied temporary occlusion, n (%)	Without applied occlusion, n (%)	χ^2	<i>p</i>
No	73 (85.9)	89 (91.8)	8.801	0.003
Yes	12 (14.1)	8 (8.2)		
Total	85 (100)	97 (100)		

Table 3

Lethal outcome				
Lethal outcome	With applied temporary occlusion, n (%)	Without applied occlusion, n (%)	χ^2	<i>p</i>
No	78 (91.8)	71 (73.2)	10.522	0.001
Yes	7 (8.2)	26 (26.8)		
Total	85	97		

Table 4

Duration of temporary occlusion				
Duration (min)	Resulting ischemia, n (%)	Lethal outcome, n (%)	χ^2	<i>p</i>
Up to 3	0 (0)	0 (0)		
4–10	4 (33.3)	2 (28.6)	0.046	0.829
Over 10	8 (66.7)	5 (71.4)		
Total	12 (100)	7 (100)		

patients with applied temporary occlusion while in the group without temporary occlusion, 26 (26/97, 26.8%) of the patients succumbed to the effects of the intervention.

The lethal outcome was significantly more frequent among patients without applied temporary occlusion ($\chi^2 = 10.522$; $p = 0.001$), (Table 3).

The duration of temporary occlusion did not significantly affect the final outcome of the patients treated ($\chi^2 = 0.046$; $p = 0.829$) (Table 4).

Discussion

An early surgical procedure involving aneurysmal change clipping and basal cisterns blood clearing is a significant therapeutic procedure in preventing vasospasm occurrence, as shown by other authors^{10,11}.

Surgical treatment of brain blood vessel aneurysms requires a rich experience, precision and good manual capability of an operator. To well observe the aneurysmal change, preserve all the surrounding branches, do good neck preparation and prepare it for putting the final clip require serious and painstaking work. Bleeding aneurysms are especially difficult to manage due to the condition of the very brain mass that is swollen, tense, prone to frequent bleeding, preventing the preparation of supply vessels and access to the very aneurysmal change.

Roganović et al.¹² described the main artery occlusion in 4 patients and in 3 more patients the posterior communicating artery was asymptotically occluded along with the aneurysm. *Arteria carotis interna* (ACI) was occluded in two patients while distal *arteria cerebri anterior* (ACA) segment (parasagittal frontal and frontobasal infarction) and the final branch of *arteria cerebri media* (ACM) (temporoparietal infarction) were occluded in one patient, each. The risk of re-rupture in the course of the work

is also high. Postoperative complications in the form of incomplete closure of the aneurysm, perforator occlusion, occlusion (subocclusion) of the main artery stem are also present. It is suggested that another clip should be previously placed distally in relation to the aneurysm in order to prevent filling of the fundus^{13,14}.

During our research, out of the total 182 bleeding aneurysms, in 85 of them the operator decided to apply temporary clipping before placing the final clip. As far as the localization of treated aneurysms was is concerned, no statistical significance was found in relation to the application of temporary clipping before the final clip placement ($\chi^2 = 0.632$; $p = 0.959$).

Placement of a temporary clip on the supply blood vessel with an aneurysm enables reduced blood flow through the blood vessel and therefore through the aneurysm. Aneurysmal change volume reduces making the aneurysm easier for manipulation and enabling better preparation and separation of the surrounding branches. In the case of aneurysm rupture, the blood quantity is lower and under lower pressure, therefore clip placement is facilitated. Our study showed that, compared to the surgical treatment of ruptured cerebral aneurysms without previous temporary clipping, the application of temporary occlusion significantly reduced the presence of the resulting neurological deficit ($\chi^2 = 8.801$; $p = 0.003$). Similarly, the lethal outcome was significantly more frequent among patients who were not treated with temporary occlusion ($\chi^2 = 10.522$; $p = 0.001$). Some studies have shown that postoperative complications in terms of ischemic lesions and neurologic defects are associated with the duration of temporary occlusion^{15,16}. However, studies of other authors have not shown that there is a connection between the duration of occlusion and the occurrence of ischemia^{17,18}. During our study, we also did not record the effect of temporary occlusion duration on the

outcome of treated patients ($\chi^2 = 0.046$; $p = 0.829$). Also, independently of placing temporary occlusion, vasospasm can occur as a postoperative complication leading to a neurological deficit and lethal outcome. Development of ischemia depends on following factors: reduction of blood vessel lumen by at least 50%, blood pressure values, intracranial pressure and blood viscosity. Also, atherosclerotic changes and levels of oxygen, carbon dioxide and haemoglobin in blood significantly influence the occurrence of vasospasm. The length of the stenosis caused by vasospasm and the quality of anastomoses on the base and in the Circle of Willis are also significant¹⁹. Contrary to this, the research of Malinova et al.²⁰ has shown that the use of temporary occlusion does not lead to provocation of vasospasm and these authors believe that one should not hesitate in using elective temporary clipping if it is considered appropriate.

In our opinion, surgical treatment of ruptured cerebral aneurysms requires extensive experience, knowledge, precision, and despite the effort made, the prognosis of healing is uncertain. There still remains a dilemma on whether it is desirable to place a temporary clip.

Conclusion

The application of temporary occlusion in the treatment of ruptured cerebral aneurysms enables easier placement of the final clip. The application of temporary occlusion influence the presence of the resulting neurological deficit. There still remains a dilemma: to apply temporary occlusion or not? Our research has shown that it is necessary to avoid the use of elective temporary occlusion, but if the situation requires, it is not disputed to apply it. It is assumed that it may be one of the causes of vasospasm provocation, considering that these are bleeding aneurysms.

REFERENCES

1. Epidemiology of aneurysmal subarachnoid hemorrhage in Australia and New Zealand: incidence and case fatality from the Australasian Cooperative Research on Subarachnoid Hemorrhage Study (ACROSS). *Stroke* 2000; 31(8): 1843–50.
2. Ostbye T, Levy AR, Mayo NE. Hospitalization and case-fatality rates for subarachnoid hemorrhage in Canada from 1982 through 1991. The Canadian Collaborative Study Group of Stroke Hospitalization. *Stroke* 1997; 28(4): 793–8.
3. Rordorf G, Ogilvy CS, Gress DR, Crowell RM, Choi IS. Patients in poor neurological condition after subarachnoid hemorrhage: early management and long term outcome. *Acta Neurochir (Wien)* 1997; 139(12): 1143–51.
4. Yamashita K, Kashimagi S, Kato S, Takasago T, Ito H. Cerebral aneurysms in the elderly in Yamaguchi, Japan. Analysis of the Yamaguchi Data Bank of Cerebral Aneurysm from 1985 to 1995. *Stroke* 1997; 28(10): 1926–31.
5. Hamada J, Hasegawa S, Kai Y, Morioka M, Fujioka S, Ushio Y. Surgery and long-term outcome for ruptured anterior circulation aneurysms in patients in their ninth decade of life. *Surg Neurol* 1999; 52(2): 123–6 ; discussion 126–7.
6. Lin CL, Kwan AL, Hoving SL. Surgical outcome of anterior communicating artery aneurysms. *Kao Hsiung J Med Sci* 1998; 14(9): 561–8.
7. Lan Q, Ikeda H, Jimbo H, Izumiyama H, Matsumoto K. Considerations on surgical treatment for elderly patients with intracranial aneurysms. *Surg Neurol* 2000; 53(3): 231–8.
8. Suzuki J, Kwak R, Okudaira Y. The safe time limit of temporary clamping of cerebral arteries in the direct surgical treatment of intracranial aneurysm under moderate hypothermia. *Tohoku J Exp Med* 1979; 127(1): 1–7.
9. Taskapilioglu MO, Guler TM, Ocakoglu G, Korfali E. Effect of Pre/Postconditioning at Temporary Clipping. *Turk Neurosurg* 2016; 26(1): 1–7.
10. de Rooij NK, Linn FH, van der Plas JA, Algra A, Rinkel GJ. Incidence of subarachnoid haemorrhage: a systematic review with emphasis on region, age, gender and time trends. *J Neurol Neurosurg Psychiatry* 2007; 78(12): 1365–72.
11. Solomon RA. Neurosurgical Complications of Aneurysms and Arteriovenous Malformations. In: Post KD, Friedman E, McCormick P, editors. *Postoperative Complications in Intracranial Neurosurgery*. New York: Thieme Medical Publishers; 1993. p. 208–21.
12. Roganović Z, Pavličević G. Complications and mortality in surgery of cerebral aneurysms. *Vojnosanit Pregl* 2002; 59(4): 355–61. (Serbian)
13. Thrift AG, Dewey HM, Sturm JW, Srikanth VK, Gilligan AK, Gall SL, ET AL. Incidence of stroke subtypes in the North East Melbourne Stroke Incidence Study (NEMESIS): differences between men and women. *Neuroepidemiology* 2009; 32(1): 11–8.
14. Fox JL. Management of aneurysms of anterior circulation by intracranial procedures. In: Youmans JR, editor. *Neurological Surgery*. Philadelphia: WB Saunders Co; 1990. p. 1689–732.
15. Roganović Z, Pavličević G, Tadić R, Djirković S. Risk factors for the onset of vasospasm and rebleeding after spontaneous subarachnoid hemorrhage. *Vojnosanit Pregl* 2001; 58(1): 17–23. (Serbian)
16. Ferch R, Pasqualin A, Pinna G, Chioffi F, Bricolo A. Temporary arterial occlusion in the repair of ruptured intracranial aneurysms: an analysis of risk factors for stroke. *J Neurosurg* 2002; 97(4): 836–42.
17. Hindman BJ, Bayman EO, Pfisterer WK, Torner JC, Todd MM. IHAIST Investigators. No association between intraoperative hypothermia or supplemental protective drug and neurologic outcomes in patients undergoing temporary clipping during cerebral aneurysm surgery: findings from the Intraoperative Hypothermia for Aneurysm Surgery Trial. *Anesthesiology* 2010; 112(1): 86–101.
18. Roganović Z, Pavličević G. Intraoperative rupture of cerebral aneurysms and use of temporary arterial occlusion. *Vojnosanit Pregl* 2002; 59(2): 125–30. (Serbian)
19. Kovacevic V, Peulic M, Nikolic R, Mijailovic M, Lukic S, Miletic Kovacevic M, et al. Cerebral vasospasm after aneurysmal subarachnoid hemorrhage, management and treatment outcome. *Pons Med J* 2012; 10(1): 17–23. (Serbian)
20. Malinova V, Schatlo B, Voit M, Suntheim P, Rohde V, Mielke D. The impact of temporary clipping during aneurysm surgery on the incidence of delayed cerebral ischemia after aneurysmal subarachnoid hemorrhage. *J Neurosurg* 2018; 129(1): 84–90.

Received on October 14, 2018.

Revised on December 11, 2018.

Accepted on December 17, 2018.

Online First December, 2018.