



# Orthotopic ileal neobladder “Belgrade pouch” in females

## Ortotopska ilealna neobešika „Belgrade pouch” kod žena

<sup>1</sup>Predrag Aleksić, <sup>1</sup>Vladimir Bančević

Military Medical Academy, Urology Clinic, Belgrade, Serbia; University of Defence,  
Faculty of Medicine of Military Medical Academy, Belgrade, Serbia

<sup>1</sup>equal first authorship

### Abstract

**Background/Aim.** Orthotopic continent neobladder provides adequate capacity, low pressure reservoir, acceptable rate of continence and satisfactory voiding frequency. Standard surgical techniques require the usage of an ileal segment in the length of 50–65 cm for neobladder creation with favorable results. However, the usage of a long intestinal segment is associated with high neobladder capacity, voiding problems, and metabolic complications. The aim of this study was to analyze clinical outcomes of the “Belgrade pouch” orthotopic bladder replacement in female patients and to promote the usage of shorter ileal segment for neobladder creation. **Methods.** A prospective study conducted in our institution from 2009 to 2019 included 37 female patients who underwent orthotopic bladder replacement according to “Belgrade pouch” technique with the usage of shorter ileal segment whose average length for neobladder creation was 28 cm. Inclusion criteria were: female continent patients older than 18, organ-confined muscle-invasive bladder carcinoma and, the American Society of Anesthesiologists (ASA) score 1 or 2. Exclusion criteria were: diabetes mellitus, obstructive pulmonary diseases, systemic illnesses and metabolic diseases which may have some influence on results interpretation, renal deterioration and preoperative incontinence. We analyzed operative time, blood loss, histopathological findings, continence rate, metabolic disor-

ders, immediate and delayed complications and survival rate in two-year periods of follow-up. **Results.** Average age of patients was 58 (32–67) years. Average time of surgical procedures was 199 (155–320) min. Blood transfusion was intraoperatively applied in 32.43% of the patients in average volume of 385 (300–640) mL. A total of 29.47% patients had anemia preoperatively. In the early postoperative period we reported one patient with paralytic ileus which was resolved conservatively and one patient with urinary fistula appearance; 56.75% of the patients were in pT2 stage. Two years following the surgery, daytime continence was achieved in 91.89% of the patients, neobladder capacity was 459 (345–592) mL, post-void residual urine volume was 27 (0–40) mL, 24 h voiding frequency 6, metabolic acidosis appeared in 2.7% of the patients. Survival rate in 2-year period was 86.48%. **Conclusion.** Orthotopic ileal neobladder created from the shorter ileal segment (“Belgrade pouch”) in females provides a high level of continence without a significant increase of voiding frequency, with adequate capacity, without urinary tract retention and with decrease of metabolic complications.

### Key words:

colonic pouches; female; postoperative complications; serbia; treatment outcome; urinary bladder neoplasms; urological surgical procedures.

### Apstrakt

**Uvod/Cilj.** Ortotopska kontinentna neobešika omogućava adekvatan kapacitet, nizak pritisak, visok nivo kontinencije i zadovoljavajuću frekvenciju mokrenja. Standardne hirurške tehnike preporučuju upotrebu segmenta tankog creva u dužini od 50 do 65 cm za kreiranje neobešike, uz zadovoljavajuće rezultate. Upotreba dužeg crevnog segmenta za kreiranje neobešike može da dovede do nepotrebnog povećanja kapaciteta neobešike, problema sa mokrenjem i metaboličkih poremećaja. Cilj ove studije je bio da prikaže rezultate kreiranje neobešike po metodi „Belgrade pouch” i da

promoviše upotrebu kraćeg segmenta tankog creva za kreiranje neobešike. **Metode.** Prospektivna studija, sprovedena u periodu od 2009. do 2019. godine u našoj ustanovi, je uključila 37 bolesnika, operisanih po metodi „Belgrade pouch” uz upotrebu kraćeg segmenta tankog creva prosečne dužine 28 cm. Kriterijumi za uključanje u studiju su bili: kontinentne bolesnice starije od 18 godina sa ograničenim karcinomom prelaznog epitela mokraćne bešike i *American Society of Anesthesiologists* (ASA) skorom 1 ili 2. Kriterijumi za isključenje iz studije su bili: *diabetes mellitus*, opstruktivne bolesti pluća, metaboličke i sistemske bolesti koje bi imale uticaja na interpretaciju rezultata, bubrežna

slabost i preoperativna inkontinencija. Analizirali smo vreme operacije, potrebu za transfuzijom krvi, patohistološki nalaz, kontinenciju, metaboličke poremećaje, neposredne i udaljene komplikacije, kao i stopu preživljavanja u dvogodišnjem periodu praćenja. **Rezultati.** Prosečna životna dob pacijentkinja bila je 58 (32–67) godina. Prosečno vreme operacije iznosilo je 199 (155–320) minuta. Transfuzija krvi primenjena je intraoperativno kod 32.43% bolesnica, u prosečnoj zapremini od 385 (300–640) mL. Ukupno 29.47% bolesnica je preoperativno imalo anemiju. U ranom postoperativnom periodu kod jedne bolesnice je došlo do razvoja paralitičkog ileusa koji je rešen konzervativno. Jedna bolesnica je imala urinarnu fistulu. Patohistološka analiza je pokazala da je najviše bolesnica (56.75%) bilo u pT2 stadijumu. Dve godine nakon operacije, dnevna kontinencija je postignuta kod 91.89% operisanih. Kapacitet neobeške je

iznosio 459 (345–592) mL, zapremina rezidualnog urina 27 (0–40) mL, 24-časovna frekvencija mokrenja je bila 6, a metabolička acidoza je zabeležena kod 2.70% bolesnica. Stopa preživljavanja u dvogodišnjem periodu iznosila je 86.48%. **Zaključak.** Ortotopska ilealna neobeška kreirana upotrebom kraćeg segmenta tankog creva po metodi „Belgrade pouch“ obezbeđuje visok nivo kontinencije, bez značajnog povećanja frekvencije pražnjenja. Adekvatnog je kapaciteta, bez značajnijeg rezidualnog urina, uz minimalan broj slučajeva ureterohidronefroze i uz značajno manje metaboličkih komplikacija.

#### Ključne reči:

**creva, rezervoari; žene; postoperativne komplikacije; srbija; lečenje, ishod; mokraćna bešika, neoplazme; hirururgija, urološka, procedure.**

### Introduction

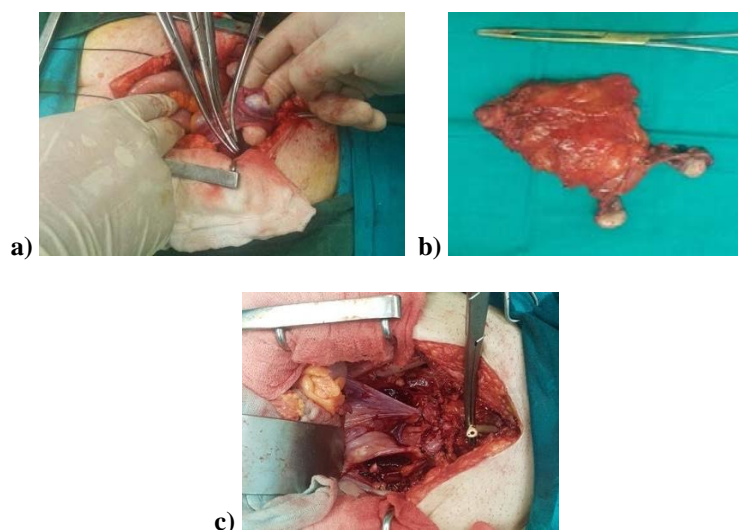
Bladder tumor is the sixth most common malignancy in human population, and it appears 3.5–4 times more rarely in female population <sup>1</sup>. Despite the fact that this malignancy is not so frequent in females, bladder cancer in this subgroup of population is presented with more advanced disease forms and has worse survival rate <sup>2</sup>. In 25% of patients, bladder cancer appears in its muscle-invasive form <sup>3</sup>. Radical cystectomy (RC) is the gold standard management for muscle-invasive bladder cancer (MIBC). RC in females includes removal of the bladder, anterior vagina wall, uterus, ovaries, fallopian tubes and regional lymph nodes. After RC, urinary diversion may be resolved through ureterocutaneostomy, ileal conduit or neobladder substitution.

The aim of this study was to present our very first results of the "Belgrade pouch" technique in females and to promote the usage of a shorter ileal segment for neobladder creation in females.

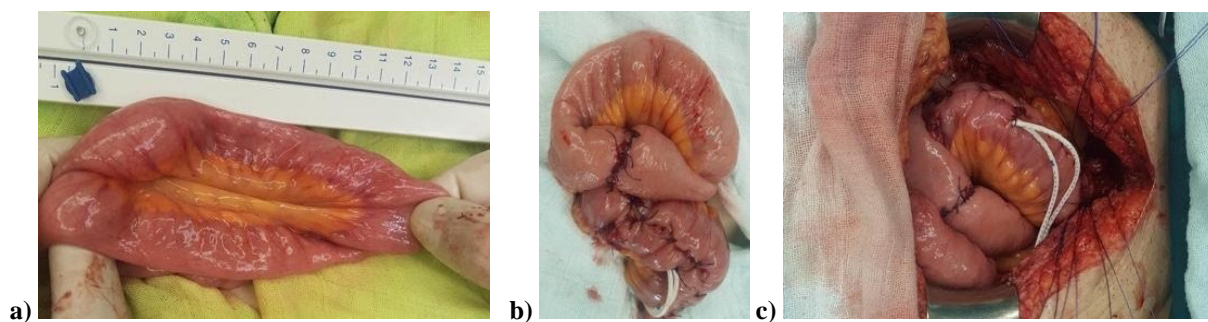
### Methods

In the prospective clinical study, we included 37 female patients surgically treated in the 2009–2019 period at the

Urology Clinic of Military Medical Academy (MMA) in Belgrade, Serbia. The "Belgrade pouch" technique was approved by the Ethics Committee of the MMA and all the patients signed informed consent for this procedure. Inclusion criteria were: female continent patients older than 18 years, organ-confined muscle-invasive bladder carcinoma (transitional cell carcinoma – TCC) and the American Society of Anesthesiologists (ASA) score 1 or 2. Exclusion criteria were: diabetes mellitus, obstructive pulmonary diseases, systemic illnesses and metabolic diseases which could have certain influence on results interpretation, renal deterioration and preoperative incontinence. Ileal orthotopic neobladder was constructed according to the original "Belgrade pouch" technique with the usage of a shorter ileal segment for neobladder construction. Terms "neobladder" and "pouch" are used as synonyms. After ovariectomy and hysterectomy, cystectomy with removal of anterior vaginal wall was performed (Figure 1). Ileal segment in the average length of 28 cm was resected with raw preservation of mesenterial root. Detubularisation of ileal segment was performed and a U-shaped plate was formed. The next step was spherical neobladder formation. Previously, ureters were implanted in the neobladder roof directly, from both sides separately with ureteral stents conducted to the anterior



**Fig. 1 – a) ovariectomy; b) hysterectomy; c) cystectomy with resection of anterior vaginal wall.**



**Fig. 2 – a, b) creation of U-shaped “Belgrade pouch” from a shorter ileal segment; c) neobladder-urethral anastomosis.**

abdominal wall through a small incision. Neobladder-urethral anastomosis was formed with 5–7 stitches (Figure 2). Three days following the surgery, we started to flush neobladder through the catheter with 20–30 mL of saline liquid twice a day. Urethral stents were removed, in average 12 (11–14) days following the surgery. We considered those with the use of 0–1 pad/24 hrs as continence patients. A detailed description of the “Belgrade pouch” technique was previously published by Bančević et al. <sup>4</sup>.

### Results

Average age of patients was 58 (32–67) years. Twenty-one (56.76%) and 16 (43.24%) of the patients were classified as the ASA 1 and ASA 2 score, respectively.

Average operation time was 199 (155–320) minutes. Average intestinal length used for neobladder creation was 28 (25–35) cm.

Eleven (29.74%) patients had anemia preoperatively. Blood transfusion was applied intraoperatively in 12 (32.43%) of the patients in average volume of 385 (300–640) mL.

We did not notice neither wound dehiscence nor high body temperature during hospitalization.

In the early postoperative period we observed one (2.7%) patient with paralytic ileus which was resolved conservatively within 8 days postoperatively with prokinetic drugs, correction of serum potassium concentration and prolonged nasogastric tube placement.

One (2.7%) patient had a urinary fistula that appeared two months following the surgery. This patient did not receive chemotherapy. After 4 weeks of conservative treatment and catheter placement, that fistula did not heal spontaneously. Endoscopy showed a 5-millimeter neobladder-vaginal fistula. Transvaginal fistula repair using the Martius flap technique was performed with satisfying results.

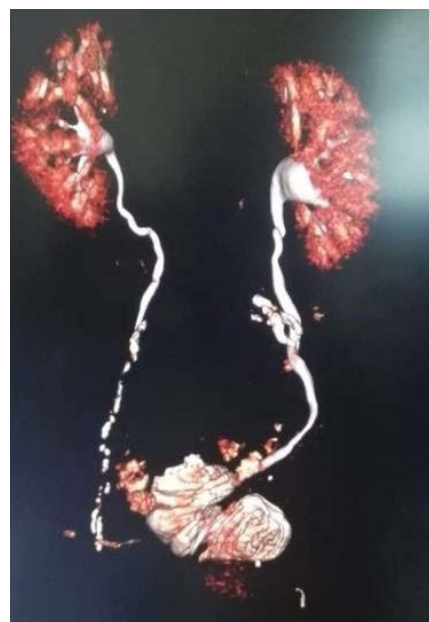
Our histopathological examination confirmed TCC in all patients, in 3 (8.11%) with squamocellular component, in 4 (10.81%) with sarcomatoid component beside TCC. G3 pT1 stage was reported in 2 (5.41%) patients, and both of them underwent multiple transurethral resections for recurrent, *Bacillus Calmettequerin* (BCG) refractory TCC. Twenty-one (56.75%) patients were in pT2 stage, 10

(27.02%) patients were in pT3a stage, and 4 (10.82%) patients in pT3b stage. In 2 (5.41%) of the patients N1 stage was reported.

In the youngest patient, aged 32, the right ovary was preserved, and in other two patients, aged 37 and 42, internal genital organs were preserved.

Two years following the surgery, two patients had hydronephrosis, and 35 (94.59%) of the patients were with normal finding on upper urinary tract (Figure 3). One patient during the second year of the follow-up underwent bilateral reimplantation of ureter in neobladder with JJ stent insertion due to bilateral hydronephrosis. In the same period of the follow-up, we reported just one patient with mild acidosis, but all other patients were with normal pH value without the need for any kind of alkalizing agents. Delayed characteristics and complications in our patients are shown in Table 1.

Survival rate in the 2-years periods was 86.48%.



**Fig. 3 – Multislice computed tomography (MSCT) of kidneys, ureters and “Belgrade pouch” two years following the surgery shows adequate pouch capacity and absence of hydronephrosis in a female patient.**

**Table 1**  
**Characteristics and delayed complications of “Belgrade pouch” in female patients**

Characteristics complications	3 months	6 months	1 years	2 years
Day continence, n (%)	20 (54.05)	28 (75.66)	31 (83.78)	34 (91.89)
Night continence, n (%)	18 (48.65)	27 (72.97)	30 (81.08)	33 (89.20)
Neobladder capacity (mL), mean (range)	287 (220–348)	371 (285–449)	436 (330–504)	459 (345–592)
PVR urine volume (mL), mean (range)	10 (0–18)	16 (0–21)	19 (0–39)	27 (0–40)
24-voiding frequency, n	9	8	7	6
Acidosis, n (%)	0	0	3	1 (2.7)
Vitamin B12 deficiency, n (%)	0 (0)	0 (0)	0 (0)	0 (0)
Pouch calculus, n (%)	0 (0)	0 (0)	0 (0)	1 (2.7)
Hydronephrosis, n				
bilateral	4 (grade I)	2 (grade I)	1 (grade II)	1 (grade III) Re-anastomosis
unilateral	0		1 (grade I)	1 (grade III) PCN

PVR – post-voided residual; PNC – percutaneous nephrostomy.

## Discussion

Standard orthotopic ileal neobladder techniques require the usage of an intestinal segment in the length of 55–60 cm<sup>5, 6</sup>. The “Belgrade pouch” surgical technique for orthotopic neobladder construction was aimed to create a urinary reservoir that may obtain adequate capacity and continence with reasonable frequency and reduction of metabolic disorders. Standard surgical techniques such as Studer’s and Hautmann’s neobladder finally gain unnecessary large capacity with increased residual urine<sup>5</sup>. Moreover, these neobladders have been associated with significant metabolic problems. Therefore, the usage of a shorter intestinal segment for the creation of neobladder appeared challenging to minimize the above mentioned problems. Our team reported promising results using this technique in a group consisted of mainly male patients<sup>4</sup>. During the time, there is a constant enlargement of neobladder capacity, which may be the reason for voiding problems and metabolic disorders. The key point of the presented technique is to use a shorter ileal segment for neobladder orthotopic construction, to preserve favorable characteristics of the other types of ileal substitutes and to attempt the reduction of metabolic and other complications. In our experience, the “Belgrade pouch” is a surgical technique which requires the usage of the shortest ileal segment for neobladder construction. Our idea was to take an ileal segment in the length of 30 cm, but the vessels distribution in intestinal mesentery and the attempt to provide maximal vascular preservation after transluminescence of mesentery resulted in the average length of the ileal segment in our study of 28 cm.

The patients scheduled for orthotopic urinary derivation are often younger, usually under the age of 65<sup>7</sup>. In this study cohort, the average age of the patients was 58, and the youngest one was at the age of just 32. Although age is not a contraindication for orthotopic diversion, the majority of authors do not perform this kind of surgery in octogenarians<sup>8, 9</sup>.

The most common early complications of such kind of surgical procedure in other studies were ileus (up to 15%) and wound infection (up to 12%)<sup>10</sup>. In this study, there was only one patient with paralytic ileus and there was no report of any wound infection and dehiscence, but our results are probably influenced by a smaller number of patients.

Referent studies reported that one-quarter to one-third of patients received blood transfusion intraoperatively<sup>11</sup> and similar results have been reported in this study. Some higher results in our study are in correlation with a higher percentage of preoperative anemia in the patients.

Urinary fistula is an uncommon, but possible complication. Carmel et al.<sup>12</sup> described their experience with this kind of complications and suggested that Martius or omental flap should be interposed between vagina and (neo)bladder, after the excision of fistulous channel and closure of the defect. The procedure using Martius flap, through transvaginal approach was done in our one patient and with excellent results.

Kretschmer et al.<sup>13</sup> reported 22.4% of patients with tumor *in situ* (TIS), 23.0% of patients in pT1 stage, 27.6% in pT2 stage, 18.4% in pT3 and 4.6% in pT4 stage with missing data in 4% of patients. The majority of patients in our study were in pT2 and pT3 stage. Some of them had unfavorable histopathological features of squamocellular or sarcomatoid components which might influence the treatment outcome as well as nodal involvement. Although we used the “Belgrade pouch” technique only in patients with malignancy, it is suitable also for patients with benign conditions requiring cystectomy.

In the youngest patient, aged 32, the right ovary was preserved. In other two patients aged 37 and 42, uterus and ovaries were preserved, on their own request. For selected patients, sparing of internal genitalia has proven to be oncologically safe, but still there are no strict recommendations for such cases<sup>14</sup>.

Oncological outcome and continence probably are the most important facts for improved life quality after a radical cystectomy with orthotopic diversion. Different factors have the influence on the quality of micturition and continence:

strength of urethral sphincter, neobladder capacity and shape, position of neobladder in pelvis and angle with urethra, diameter of urethra-neobladder anastomotic channel, body mass index and intraabdominal pressure, patients level of training for micturition in new wave, post-voiding residual urine volume and mucus production<sup>15</sup>. The experience of surgeons (> 100 previous cystectomies) has been demonstrated to be a prognostic predictor for continence<sup>13</sup>. During the time, there is a constant enlargement of pouch capacity which improves continence level during the first period. In our previous publication, the neobladder constructed from a shorter ileal segment 12 months following the surgery achieved the average capacity of 440 (290–710) mL, compared to the standard-dimensioned pouch which achieved some unnecessarily large capacity of average 840 (480–2050) mL<sup>16</sup>.

The pouch may become unnecessarily large and become a reason for voiding problems and metabolic complications. Diverse studies reported daytime continence in range of 88–99% and during the night 10–20% lower continence<sup>17, 18</sup>. In 11 studies reported, daytime and night-time continence rates were 58–100% and 42–100%, respectively, and self-catheterisation rate was 9.5–78%<sup>19</sup>. Our study showed that even with a shorter length of the intestinal segment, it was possible to create a neobladder with adequate capacity and reasonable voiding frequency, with a high level of continence one year following the surgery. During the first months after the surgery, we observed the higher level of incontinence, because a small pouch needs time to enlarge its capacity which is an important factor for continence achievement. Smith et al.<sup>20</sup> reported hypercontinence in 10–20% of patients as one of the most frequent problems in females following the surgery. In our study, we had no patients with hypercontinence problem, so there were no patients for intermittent catheterization. We suppose that the smaller pouch, adequate capacity, spherical shape and position in pelvis contribute to avoiding hypercontinence.

The absorption of potassium, hydrogen and chloride ions results in a hyperchloraemic metabolic acidosis. A prolonged metabolic acidosis may include calcium resorption and decreased circulating phosphate levels, leading to hyperparathyroidism, osteomalacia and osteoporosis<sup>21</sup>. Kim et al.<sup>22</sup> reported metabolic acidosis rate of 52%, 19.5%, and 7.3% in 1 month, 1 year and 2 years after the surgery, respectively. One of the goals of this novel “Belgrade pouch” technique is to prevent acidosis and our data showed just one patient in the second year of the follow-up with mild acidosis. Studer<sup>5</sup> recommends the intake of

sodium bicarbonate (2–6 g/day) to all patients, but in our study alkalinizing agents were not used.

The appearance of neobladder calculi can be found in 10–20% of patients<sup>21</sup>. Mucus production, infections, urethral stenosis may be risk factors for stone formation in neobladder. Also, a higher concentration of urinary calcium caused by metabolic acidosis may predispose patients to a higher risk of urinary calculi formation. Just one of our patients, at the end of the follow-up period, had pouch calculus and this result is encouraging.

The reasons for ureterohydronephrosis appearance in patients after the neobladder construction may be stricture on uretero-pouch anastomosis, urine reflux, calculosis of the renal pelvis or ureter, tumor in ureter or extraluminal compression on ureter. An early, postoperative transitional hydronephrosis may be caused by edema at anastomosis and reduced compliance and capacity of the neobladder<sup>23</sup>. Ureterohydronephrosis rate in referent studies appears in 5–19% of patients<sup>23</sup>. In our study, initially higher number of low grade bilateral hydronephrosis was caused by urine reflux during the period while neobladder was still with a smaller capacity. This kind of hydronephrosis is transitional, and usually is not connected with renal deterioration and infection rate. On the other hand, in the two-year period of follow-up we reported one patient with hydronephrosis grade III, which was resolved by placing a percutaneous nephrostomic tube. The other patient was resolved through a very complicated surgical procedure of reimplantation of both ureters in the neobladder.

Vitamin B12 deficiency is more frequent in neobladders constructed of more than 60 cm of terminal ileum. Fujisawa et al.<sup>24</sup> reported 13.6% of patients vitamin B12 deficiency, detected between 9 months and 3 years after surgery. In our study we did not observe any vitamin B12 deficiency.

## Conclusion

The orthotopic ileal neobladder created from a shorter ileal segment, the so-called “Belgrade pouch”, provides a high level of continence with adequate capacity, insignificant residual urine without urinary tract retention and without significant increasing of voiding frequency. We reported a small percentage of pouch calculosis without significant acidosis and without vitamin B12 deficiency in two years of the follow-up. The appearance of refluxive ureterohydronephrosis is transient, low-grade and caused by smaller neobladder capacity in the first months after the operation.

## REFERENCES

1. Siegel RL, Miller KD, Jemal A. Cancer statistics, 2015. *CA Cancer J Clin* 2015; 65(1): 5–29.
2. Liu S, Yang T, Na R, Hu M, Zhang L, Fu Y, et al. The impact of female gender on bladder cancer-specific death risk after radical cystectomy: a meta-analysis of 27,912 patients. *Int Urol Nephrol* 2015; 47(6): 951–8.
3. Witjes JA, Bruins HM, Cathomas R, Compérat EM, Cowan NC, Gakis G, et al. European Association of Urology Guidelines on Muscle-invasive and Metastatic Bladder Cancer: Summary of the 2020 Guidelines. *Eur Urol* 2020; S0302-2838(20): 30230-X.
4. Bančević V, Aleksić P, Stamenković D. Orthotopic ileal neobladder creation according to original surgical method “Belgrade



- pouch"- a ten years experience. *Vojnosanit Pregl* 2021; 78(4):421-8.
5. *Studer UE*. Surgical atlas-Orthotopic ileal neobladder. *BJU Int* 2014; 93(1): 183-93.
  6. *Hautmann RE*. Surgery illustrated - surgical atlas ileal neobladder. *BJU Int* 2010; 105(7): 1024-35.
  7. *Crozjer J, Hennessey D, Sengupta S, Bolton D, Lawrentschuk N*. A systematic review of Ileal conduit and neobladder outcomes in primary bladder cancer. *Urology* 2016; 96: 74-9.
  8. *Saika T, Suyama B, Murata T, Manabe D, Kurashige T, Nasu Y*, et al. Orthotopic neobladder reconstruction in elderly bladder cancer patients. *Int J Urol* 2001; 8(10): 533-8.
  9. *Bancević V, Aleksić P, Milović N, Spasić A, Kovacević B, Tosevski P*, et al. Radical cystectomy in elderly. *Vojnosanit Pregl* 2015; 72(2): 136-9.
  10. *Lee YS, Jung HB, Choi DK, Cho ST, Kim KK, Lee YG*. Functional Assessment of the Hautmann Ileal Neobladder with Chimney Modification Using Uroflowmetry and a Questionnaire. *Biomed Res Int* 2016; 2016: 8209589.
  11. *Rogbmann F, Becker A, Trinh QD, Djahangirian O, Tian Z, Meskawi M*. Updated assessment of neobladder utilization and morbidity according to urinary diversion after radical cystectomy: A contemporary US-population-based cohort. *Can Urol Assoc J* 2013; 7(9-10): E552-60.
  12. *Carmel ME, Goldman HB, Moore CK, Rackley RR, Vasavada SP*. Transvaginal neobladder vaginal fistula repair after radical cystectomy with orthotopic urinary diversion in women. *Neurourol Urodyn* 2016; 35(1): 90-4.
  13. *Kretschmer A, Grimm T, Buchner A, Stief CG, Karl A*. Prognostic features for quality of life after radical cystectomy and orthotopic neobladder. *Int Braz J Urol* 2016; 42(6): 1109-20.
  14. *Kalampokis N, Grivas N, Ölschläger M, Hassan FN, Gakis G*. Radical Cystectomy in Female Patients - Improving Outcomes. *Curr Urol Rep* 2019; 20(12): 83.
  15. *Herdiman O, Ong K, Johnson L, Lawrentschuk N*. Orthotopic bladder substitution (Neobladder): part II: postoperative complications, management, and long-term follow-up. *J Wound Ostomy Continence Nurs* 2013; 40(2): 171-80; quiz E1-2.
  16. *Aleksić P, Bančević V, Milović N, Košević B, Stamenković DM, Karanikolas M*, et al. Short ileal segment for orthotopic ileal neobladder: A feasibility study. *Int J Urol* 2010; 17(9): 768-75.
  17. *Sevin G, Soyuppek S, Armagan A, Hoscan MB, Oksay T*. Ileal orthotopic neobladder (modified Hautmann) via a shorter detubularized ileal segment: Experience and results. *BJU Int* 2004; 94(3): 355-9.
  18. *Schrier BP, Laguna MP, van der Pal F, Isorna S, Witjes JA*. Comparison of orthotopic sigmoid and ileal neobladders: continence and urodynamic parameters. *Eur Urol* 2005; 47(5): 679-85.
  19. *Veskimäe E, Neuzillet Y, Rouanne M, MacLennan S, Lam TBL, Yuan Y*, et al. Systematic review of the oncological and functional outcomes of pelvic organ-preserving radical cystectomy (RC) compared with standard RC in women who undergo curative surgery and orthotopic neobladder substitution for bladder cancer. *BJU Int* 2017; 120(1): 12-24.
  20. *Smith AB, Crowell K, Woods ME, Wallen EM, Prutbi RS, Nielsen ME*, et al. Functional Outcomes Following Radical Cystectomy in Women with Bladder Cancer: A Systematic Review. *Eur Urol Focus* 2017; 3(1): 136-43.
  21. *Türk TM, Koleski FC, Albala DM*. Incidence of urolithiasis in cystectomy patients after intestinal conduit or continent urinary diversion. *World J Urol* 1999; 17(5): 305-7.
  22. *Kim KH, Yoon HS, Yoon H, Chung WS, Sim BS, Ryu DR*, et al. Risk factors for developing metabolic acidosis after radical cystectomy and ileal neobladder. *PLoS One* 2016; 11(7): e0158220.
  23. *Narita T, Hatakeyama S, Koie T, Hosogoe S, Matsumoto T, Soma O*, et al. Presence of transient hydronephrosis immediately after surgery has a limited influence on renal function 1 year after ileal neobladder construction. *BMC Urol* 2017; 17(1): 72.
  24. *Fujisawa M, Gotob A, Nakamura I, Hara IS, Okada H, Yamanaoka N*, et al. Long-term assessment of serum vitamin B(12) concentrations in patients with various types of orthotopic intestinal neobladder. *Urology* 2000; 56(2): 236-40.

Received on April 16, 2020.

Revised on May 7, 2020.

Accepted on May 12, 2020.

Online First May, 2020.