



Melanoma and squamous cell carcinoma developing on a burn scar

Melanom i skvamocelularni karcinom kože nastali na ožiljku od opekotine

Nikola Ostojić^{*†}, Nenad Stepić^{*†}, Milica Rajović^{*†}, Jovana Končar[‡],
Marijan Novaković[§]

^{*}Military Medical Academy, Clinic for Plastic Surgery and Burns, Belgrade, Serbia;

[†]University of Defence, Faculty of Medicine of the Military Medical Academy, Belgrade,

Serbia; [‡]Institute for Oncology and Radiology of Serbia, Department of Surgery,

Belgrade, Serbia; [§]Academy of Medical Sciences of the Serbian Medical Society,
Belgrade, Serbia

Abstract

Introduction. Development of malignancy in chronic burn scars is described in 2% of cases, with cutaneous squamous cell carcinoma (cSCC) being the most frequent. It develops several years after the burn injury, as a consequence of malignant transformation in chronically inflamed tissue. Melanoma in a burn scar is, however, quite rare; in several cases, a synchronous or metachronous appearance of melanoma and cSCC was noted. Based on the previous rare reports, melanoma and cSCC can concurrently arise on thermal burn scars, as well as on the areas treated with skin grafts. **Case report.** We reported a case of a 67-year-old male who was accidentally scalded by boiling water at the age of 14. The patient subsequently developed melanoma at the age of 60, according to clinical and dermoscopic examination at the site of the burn scar, and after excision and histopathological analysis, the diagnosis of melanoma was confirmed (superficial spreading melanoma, Breslow 0.87 mm, with ulceration, pT1b). Complete surgical excision was done, and the diagnosis was confirmed with histopathological analysis. After the diagnosis of melanoma, regular follow-up every six months was scheduled, and three years later, cSCC was suspected and confirmed after surgical excision and histopathologic analysis. **Conclusion.** This case highlights the importance of long-term dermatological follow-up after burn injuries and early detection and treatment of skin cancer that can lead to better outcomes in these patients.

Key words:

carcinoma, squamous cell; early diagnosis; diagnosis, differential; histological techniques; melanoma; burns; cicatrix.

Apstrakt

Uvod. Maligni tumori kože nastali na terenu ožiljaka od opekotina opisani su kod 2% bolesnika, a planocelularni karcinom kože (karcinom skvamoznih ćelija kože, *cutaneous squamous cell carcinoma* – cSCC) je najčešći. On se javlja nekoliko godina posle opekotine kao posledica maligne transformacije ćelija u hronično inflamiranom tkivu. Razvoj melanoma na ožiljku od opekotine je veoma redak; opisano je nekoliko slučajeva sinhronog ili metahronog pojavljivanja melanoma i cSCC. Melanom i cSCC mogu se istovremeno pojaviti na ožiljku od opekotine, kao i na regiji sa autotransplantatom kože. **Prikaz bolesnika.** Prikazali smo muškarca starog 67 godina koji je imao opekotinu od ključale vode u 14. Godini života. U 60. godini života, na mestu ožiljka od opekotine, kliničkim i dermoskopskim pregledom posumnjano je na melanom, a nakon ekscizije i histopatološke analize potvrđena je sumnja i postavljena dijagnoza melanoma (površinsko šireći, *Breslow* 0,87 mm, sa ulceracijom, pT1b). Nakon postavljene dijagnoze bolesnik je redovno kontrolisan svakih šest meseci. Tokom treće godine praćenja, zbog sumnje na cSCC, učinjena je kompletna hirurška ekscizija i dijagnoza cSCC je potvrđena histopatološkom analizom. **Zaključak.** Prikazani slučaj naglašava važnost dugotrajnog dermatološkog praćenja osoba nakon opekotina kože, i ranu dijagnozu i odgovarajuće hirurško lečenje nastalih malignih karcinoma kože jer se na taj način poboljšava ishod lečenja ovih bolesnika.

Ključne reči:

karcinom, planocelularni; dijagnoza, rana; dijagnoza, diferencijalna; histološke tehnike; melanom; opekotine; ožiljak.

Introduction

About 2% of chronic burn scars develop into malignant tumors many years after the burn occurrence¹. Cutaneous squamous cell carcinoma (cSCC) is the most frequent cancer that arises on the affected skin², even though in the general population, this form of a malignant tumor is less common than basal cell carcinoma. Available empirical evidence suggests a mean time latency of 23 to 37 years³. However, not many cases of melanoma on thermal burn scars are reported in pertinent literature^{1, 2, 4-7}. They nonetheless suggest that melanoma (MM) and cSCC can concurrently arise on thermal burn scars, as well as on the areas treated with skin grafts^{2, 6}.

Case report

We reported a case of a 67-year-old male who suffered burns after being accidentally scalded by boiling water at the

age of 14. The first symptoms appeared 46 years after the burn when the patient noticed painless pigmented and crusty lesions in the middle of the burn scar that were clinically indicative of melanoma.

Clinical examination of his right lumbar region revealed an asymmetric pigmented flat lesion exceeding 3 cm in diameter that was brown and black in color, with irregular borders, according to the ABCDE rule. It was accompanied by one tumefaction covered in brown crusts on the surface of the surrounding skin (Figure 1). After clinical examination, wide surgical excision and local flap reconstruction were performed [Figures 2 a) and b)].

Histopathological diagnosis of one lesion was ulcerated superficial spreading melanoma (SSM) in the scar tissue (Breslow 0.85 mm, Clark III, pT1b), whereas the other lesion was diagnosed as lentiginous melanocytic hyperplasia (LMH). Final pathological findings confirmed negative excision margins, which extended 1 cm into the surrounding tissue, in accordance with the European guidelines (Figures 3 a–d).

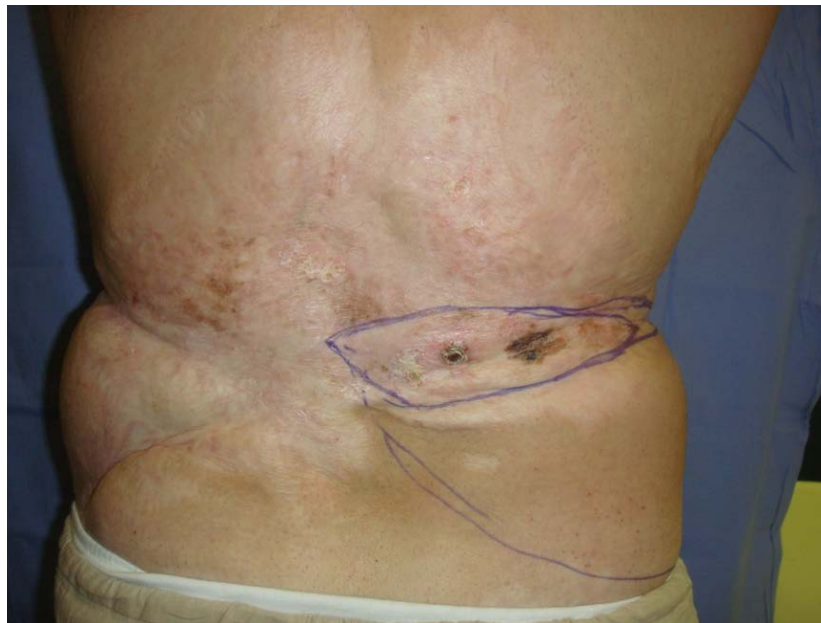

Fig. 1 – Two painless black lesions in the middle of the burn scar, developing 46 years after the burn.

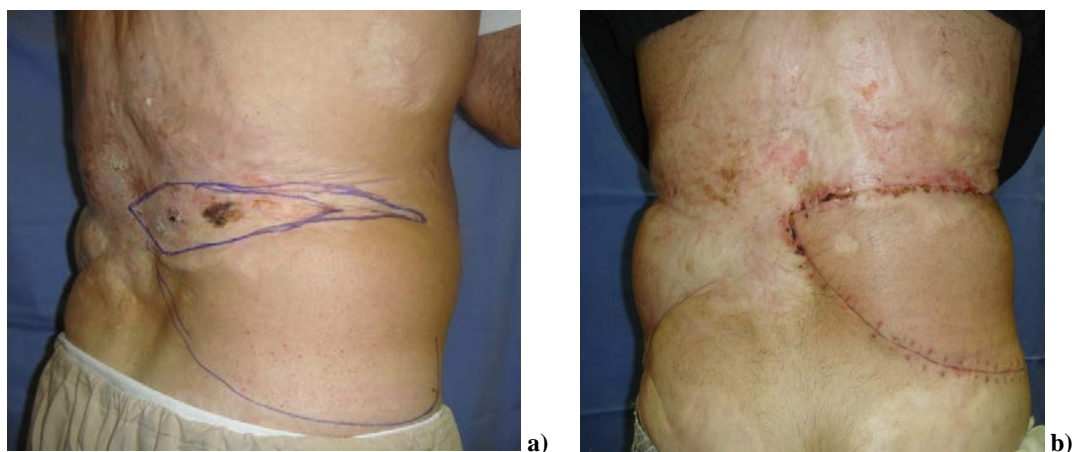


Fig. 2 – a) Planning and b) performing wide surgical excision with local flap reconstruction.

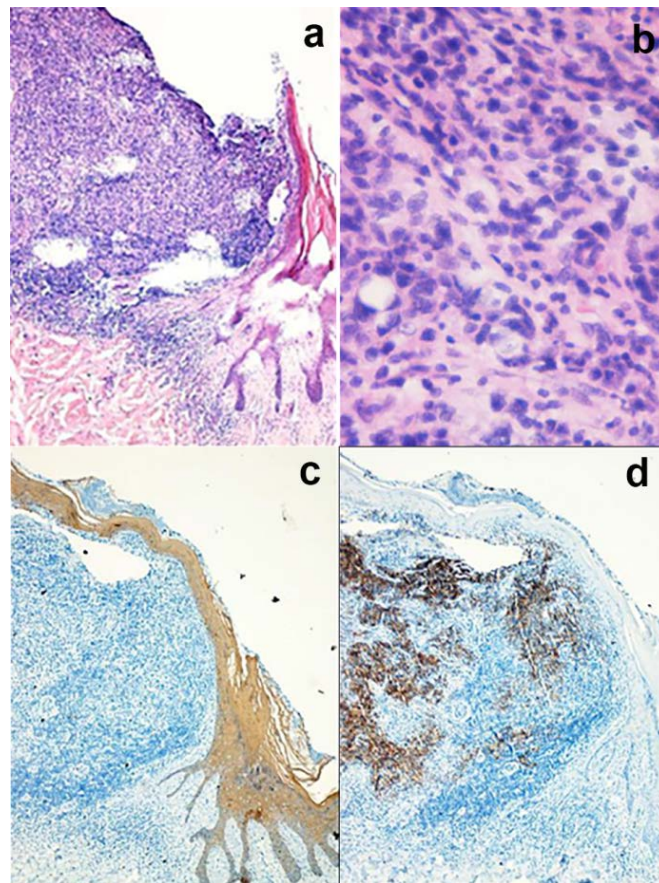


Fig. 3 – Histopathologic analysis showing:
a) Ulcerated superficial spreading melanoma (SSM) in a scar tissue (Breslow 0.85 mm, Clark III, pT1b) [hematoxylin and eosin (HE), $\times 10$]; b) atypical melanocytes (HE, $\times 10$); c) pan-cytokeratin antibody staining ($\times 10$); d) HMB-45 antibody staining ($\times 10$).

At the three-year follow-up, an area of persistent erythema and desquamation was observed on the lumbar region, which was clinically suspicious of malignant transformation [Figures 4 a) and b)]. Consequently, wide surgical excision with skin auto-

transplantation was performed (Figure 5) and intraepithelial cSCC with clear margins was histologically confirmed (Figure 6). The patient attends regular follow-ups and remains free of the disease until today (six years after the intervention).

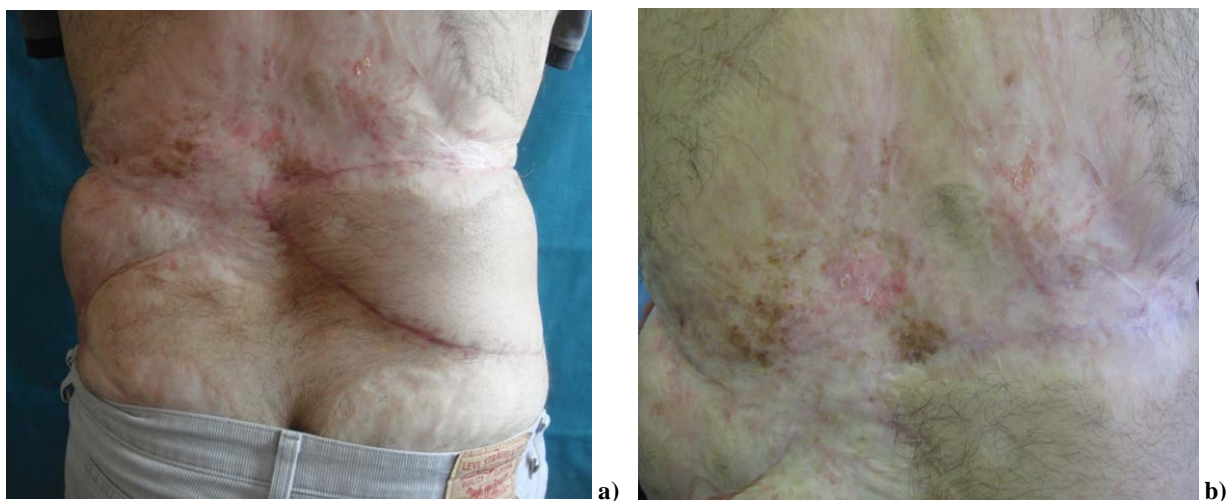


Fig. 4 – a) and b): during the follow-up, 3 years later, area of persistent erythema and desquamation was observed on the lumbar region.

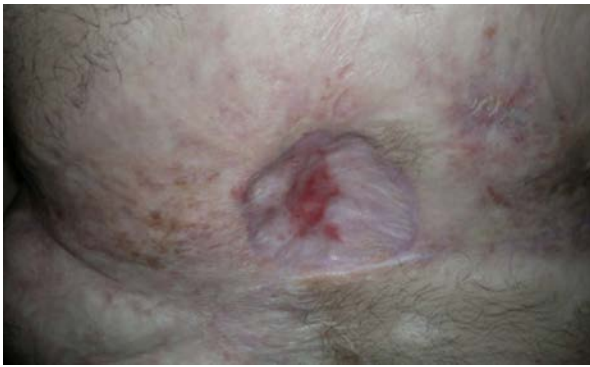

Fig. 5 – Wide surgical excision with skin autotransplantation was performed.

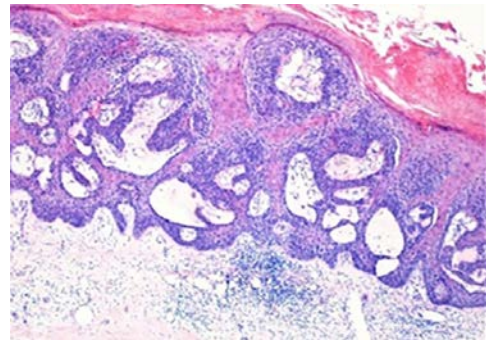


Fig. 6 – Histopathologic analysis showed intraepithelial squamous cell carcinoma with clear margins [hematoxylin and eosin (HE), ×5].

Discussion

In the presented patient, the burn resulted in the development of extensive scarring of the skin on his back, which subsequently led to the emergence of two different malignant tumors in the burn scar region. Melanoma occurred 46 years after the burn, followed by a squamous cell carcinoma 3 years later.

There are fewer epidemiological data available on the risk of skin cancer arising in scars but is described to occur in 2% of patients. A review by Wallingford et al. ⁸ has identified a major gap in scientific knowledge regarding the incidence of scar neoplasms, despite a significant number of case reports. Although burn patients are not at higher risk of developing skin cancers in general, a modest increase in the prevalence of cSCC at sites of past burn injuries cannot be excluded, nor can excess risk in longer study follow-up periods be disregarded.

In the study conducted by Sadeh Fazeli et al. ⁹, cSCC was the most common diagnosis in association with chronic cutaneous inflammation and burns, which was well-differentiated most of the time. Moreover, several cases of concurrent melanoma and sarcoma have been reported. Koh et al. ¹⁰ described an extremely rare, aggressive variant of cSCC with extreme acantholysis, pseudoangiosarcomatous SCC developing on a burn scar. In this report, the authors emphasized the importance of establishing a diagnosis based on histological and immunohistochemical examination.

The development of melanoma on a burn scar is relatively rare; in several cases, a synchronous or metachronous appearance of melanoma and cSCC was reported ^{2, 11, 12}. In one report, multiple melanomas developed at the site of a burn scar, and in another, rare desmoplastic melanoma with regional lymph node metastases was described ^{13, 14}.

In the largest review, 23 cases of melanoma and 5 cases with concomitant presence of cSCC and melanoma were de-

scribed, and in the majority of patients, skin cancer developed after a long period from the age of burn occurrence to the melanoma diagnosis (41 ± 26 years in the 23 malignant melanoma only cases, and 48 ± 13 years in the 5 cases involving both cSCC and MM) ⁸. Furthermore, in another report, the average latency time from burn to melanoma diagnosis was 45 years ¹. Our patient developed melanoma 46 years after burn injury, which was followed by a diagnosis of cSCC three years later. A very long latency period was reported by Uchida et al. ⁷, who described a case of a 78-year-old Japanese female with malignant melanoma that developed on a thermal burn scar after more than 70 years. This suggests the need for a long-term dermatological follow-up of all burn patients.

The mortality rate associated with cSCC is about 1% ¹⁵, while in skin cancers developing in a scar, it can be as high as 21–38% based on previous literature, median survival after scar cancer diagnosis was reported to be 25 months, while 5-year survival rate varies from 52% to 80% ². In patients with involvement of regional lymph nodes, median survival was 16 months, increasing to 66 months for those without lymph node metastases ³. Our patient is on regular follow-ups and is disease-free during the six-year follow-up.

Self-skin examination and regular clinical and dermoscopic follow-up should be recommended to patients with burn injuries for an early diagnosis of skin cancer to avoid complications and poor outcome in advanced disease. Initial early grafting for a deep burn wound and proper scar care is also advised ¹⁶.

Conclusion

Periodical and very long follow-up of thermal burn scars is important for early diagnosis of malignant transformation and timely and adequate treatment in order to improve the outcome in these patients.

REFERENCES

1. *Atzeni M, Serratore F, Zaccbeddu F, Buosi M, Nemolato S, Ribuffo D.* Multiple melanoma arising on a burn scar and extensive sunburn: a case report and a review of the literature. *Melanoma Res* 2009; 19(4): 195–8.
2. *Kowal-Vern A, Criswell BK.* Burn scar neoplasms: a literature review and statistical analysis. *Burns* 2005; 31(4): 403–13.
3. *Edwards MJ, Hirsch RM, Broadwater JR, Netscher DT, Ames FC.* Squamous cell carcinoma arising in previously burned or irradiated skin. *Arch Surg* 1989; 124(1): 115–7.
4. *Ribero S, Grassi M, Caliendo V, Lauro D, Macripò G.* Melanoma arising on a scar 10 years after a burn: management and review of the literature. *Ann Plast Surg* 2012; 69 (1): 27–9.

5. *Hwang K, Han JY, Lee SI.* Multiple Malignant Melanomas at Different Burn Scar Areas: A Case Report. *Dermatol Surg* 2004; 30(4): 562–65.
6. *Hiscutt EL, Adams JR, Ryan JM, Langtry JA, Natarajan S.* Atypical fibroxanthoma, lentigo maligna melanoma and squamous cell carcinoma arising in the site of a thermal burn treated with skin grafts. *Br J Oral Maxillofac Surg* 2009; 47(2): 157–8.
7. *Ucbida S, Oiso N, Shiga K, Narita T, Kawada A.* Malignant Melanoma on a Thermal Burn Scar with an Interval of More Than 70 Years. *Case Rep Dermatol* 2016; 8(2): 207–9.
8. *Wallingsford SC, Olsen CM, Plasmeijer E, Green AC.* Skin Cancer Arising in Scars: A Systematic Review. *Dermatol Surg* 2011; 37(9): 1239–44.
9. *Sadegh Fazeli M, Lebaschi AH, Hajirostam M, Keramati MR.* Marjolin's ulcer: clinical and pathologic features of 83 cases and review of literature. *Med J Islam Repub Iran* 2013; 27(4): 215–24.
10. *Kob SH, Oh SJ, Chun H, Kim SG.* Pseudoangiosarcomatous squamous cell carcinoma developing on a burn scar: A case report and review of the literature. *BURNS* 2014; 40 (7): e47–52.
11. *Spring PM, Myers JN, El-Naggar AK, Langstein HN.* Malignant melanoma arising within a burn scar case report and review of the literature. *Ann Otol Rhinol Laryngol* 2001; 110(4): 369–76.
12. *Lee HB, Han SE, Chang LS, Lee SH.* Malignant melanoma on a thermal burn scar. *Arch Craniofac Surg* 2019; 20(1): 58–61.
13. *Cantwell P, Brooks A.* Multiple melanoma in a burns scar. *BMJ Case Rep* 2018; 11(1): e227295.
14. *Pertusi G, Miglino B, Giorgione R, Ramponi A, Gattoni M, Boggio P, et al.* Amelanotic desmoplastic melanoma arising on an occipitoparietal burn scar. *G Ital Dermatol Venereol* 2017; 152(6): 680–2.
15. *Jensen AO, Olesen AB, Dethlefsen C, Sorensen HT.* Do incident and new subsequent cases of non-melanoma skin cancer registered in a Danish prospective cohort study have different 10-year mortality? *Cancer Detect Prev* 2007; 31(5): 352–8.
16. *Huang CY, Feng CH, Hsiao CY, Chuang SS, Yang JY.* Burn scar carcinoma. *J Dermatolog Treat* 2010; 21(6): 350–6.

Received on August 12, 2020

Revised on September 24, 2020

Accepted on September 25, 2020

Online First September, 2020