

INCOMPLETE OSSIFICATION OF THE HUMERAL CONDYLE (IOHC) IN A THREE-YEAR-OLD GERMAN SHEPHERD

MITROVIĆ Marko^{1*}, SAMOY Yves², LAZAREVIĆ MACANOVIĆ Mirjana¹,
van BREE Henri², GIELEN Ingrid^{1,2}

¹University of Belgrade, Faculty of Veterinary Medicine, Department of Radiology and Radiation Hygiene, Serbia; ²Ghent University, Faculty of Veterinary Medicine, Department of Medical Imaging and Small Animal Orthopaedics, Merelbeke, Belgium

Received 18 August 2017; Accepted 22 October 2017

Published online: 30 November 2017

Copyright © 2017 Mitrovic et al. This is an open-access article distributed under the Creative Commons Attribution License, which permits unrestricted use, distribution, and reproduction in any medium, provided the original work is properly cited.

Abstract

An unusual case of forelimb lameness in a three-year-old German Shepherd has been described. An incomplete ossification of the humeral condyle (IOHC) in both elbows has been diagnosed, which is a rare condition in this breed. The original radiographs and clinical examination were inconclusive. The diagnosis was established after scintigraphy proving elbow involvement and followed by a CT examination of both elbows. An arthroscopic examination showed a cleft in the articular cartilage between both humeral condyles. Because of the absence of lameness at the moment of admittance, initially conservative treatment was performed, which consisted of rest and avoiding trauma. The dog remained lameness-free during one year, whereafter he showed severe lameness in the left front leg. Although a second CT examination showed some progress of the lesions, it was decided to treat the left elbow with forage and physiotherapy consisting of laser treatment and therapeutic ultrasound. The dog responded favourably to the therapy and remains free of lameness to date. The optimal treatment of this disease remains debatable but the results of the treatment of this patient suggest that forage combined with physiotherapy could offer a justifiable option.

Key Words: Computed tomography, Dog, Forelimb lameness, Incomplete ossification of the humeral condyle, Orthopaedics

*Corresponding author – e-mail: markom@vet.bg.ac.rs

CASE PRESENTATION

Forelimb lameness in dogs is often localized in the elbow joint (Cook, 2001; Scott & Witte, 2011). Differential diagnosis of elbow lameness of the dog includes flexor enthesopathy (De Bakker, et al.; 2013) non-traumatic elbow joint luxation, traumatic disorders such as the jumping down syndrome, and congenital and developmental disorders like luxation, asynchronous growth and elbow dysplasia (Scott & Witte, 2011). Elbow dysplasia includes four primary lesions: osteochondrosis of the medial humeral condyle, ununited anconeal process, incongruity of articular surfaces and medial coronoid disease. The latter is the main cause of forelimb lameness (Samoy et al., 2006; Villamonte-Chevalier, et al., 2015).

A more uncommon cause of elbow lameness in the dog is incomplete ossification of the humeral condyle (IOHC) which is characterised by the presence of a fissure between the medial and lateral condyles of the humerus, which corresponds to the location of the cartilaginous plate that separates the two ossification centres prior to their fusion. The humeral condyle develops from three separate ossification centres: a medial ossification centre, a lateral centre and a smaller centre that goes on to form the medial epicondyle. The medial and lateral centres should fuse at between 8 and 12 weeks of age in dogs. IOHC is a developmental failure of fusion of these centres of ossification (Moore, 2006). There is often extension of the fissure to the supratrochlear foramen proximal to the growth plate, probably due to stress fracture (Moore, 2006). Incomplete ossification of the humeral condyle can cause significant pain and lameness in dogs and limit the affected individual's ability to exercise (Moore, 2006; Fitzpatrick, et al., 2009). Furthermore, the weakness present within the humerus can result in a complete spontaneous fracture during regular activity, such as running in a field or jumping from a low wall. The resulting fracture can be in the form of a lateral condylar (two piece) or bi-condylar "Y" (three piece) fracture (Fitzpatrick, et al., 2009).

The condition is most commonly seen in the English Springer Spaniel, Cocker Spaniel and other Spaniel breeds (Marcellin-Little et al., 1994; Moore, et al., 2012), but also in the Labrador and Rottweiler (Moore, 2006). Dogs with IOHC may show no signs, may present with lameness, or may present suffering from a humeral condylar fracture secondary to their condition (Moore, 2006; Fitzpatrick, et al., 2009).

Diagnosis of IOHC requires visualisation of a condylar fissure. High-quality, cranio-caudal radiographs can enable visualisation of the fissure, but the x-ray beam has to be exactly parallel to the fissure for it to be evident. Therefore, several cranio-caudal projections may be required. It has been suggested that a 15° craniomedial-caudolateral oblique projection is most likely to demonstrate the fissure (Moore, 2006). The fissure may be partial, only extending partway to the supratrochlear foramen, or it may be complete, extending all the way. It is important that IOHC is not mistakenly diagnosed on the basis of seeing a Mach line – a visual anomaly created by the superimposition of one bone edge on another, which can appear as a radiolucent line through the condyle.

New bone, or a periosteal reaction, along the lateral margin of the lateral epicondylar ridge can be seen occasionally, as can sclerosis around the supratrochlear foramen (Hoskinson & Tucker, 2001; Cook & Cook, 2009). Computed tomography (CT) is the preferred imaging technique for visualising the fissure. The fissure is readily evident on transverse slices through the condyle, demonstrable as a saw-toothed, intercondylar complete or incomplete hypoattenuating defect with hyperattenuating margins. The contralateral side should also be checked, as this condition is often bilateral. Joint incongruity, evidence of medial coronoid disease and degenerative joint disease has also been found (Carrera *et al.*, 2008). Elbow arthroscopy can also be of diagnostic use, revealing a linear fissure in the articular cartilage of the humeral condyle in many affected dogs (Meyer-Lindenberg *et al.*, 2002).

Management of IOHC remains controversial. Conservative treatment of IOHC is associated with high rates of complete humeral condylar fracture. If the patient is not lame or suffering problems related to the IOHC, treatment is not necessary. However, in the majority of cases, surgery has been recommended to resolve pain caused by the abnormality, to restore the patient to soundness and to remove the possibility of a complete fracture occurring in the future. The usual protocol is to place a large screw across the condyle to stabilise the IOHC and to strengthen the area. Other types of treatment have been tried, such as placing bone grafts into the region, but these have not been proven to give a better outcome than traditional screw placement. Since it is not expected that the area of incomplete ossification or fissure fracture will fuse or “heal”, the screw is constantly subjected to stress and loading. This can lead to metal fatigue and ultimately breakage, and the patient will become lame again (or in the worst case the humeral condyle could fracture completely). This complication can occur months to years after the original surgery. A revision operation is usually necessary to repair the fracture or to replace the broken screw (Moores, 2006; Fitzpatrick, *et al.*, 2009).

The outcome after IOHC surgery is usually good to excellent, with most patients returning to full soundness and active exercise within 6-8 weeks post-surgery. Most patients suffering from IOHC will develop osteoarthritis (despite surgery) in the longer term, but this is usually mild and does not cause any significant issues apart from mild stiffness after resting after activity (Butterworth & Innes, 2001; Meyer-Lindenberg *et al.*, 2002; Moores, 2006; Fitzpatrick, *et al.*, 2009).

In this case report, an incomplete ossification of the humeral condyle (IOHC) in a three-year-old male German Shepherd is described. A subtle lameness of the left front leg of two months duration was noticed by the owner. No history of trauma was known. The dog showed persistent lameness during exercise and stiffness particularly after rising. The dog was treated by a local veterinarian with corticosteroids and standard painkillers but responded poorly. Radiographs of both elbows were performed one month before admittance to the clinic at the Faculty of Veterinary Medicine, but no radiographic changes were found.

The dog was admitted and the general examination revealed no abnormalities. He showed a stiff gait but no obvious lameness. A visible muscular atrophy of the forelimbs was obvious as well as a slight distension of both elbows. There was no obvious pain reaction on palpation or on flexion and extension. A neurologic examination was also

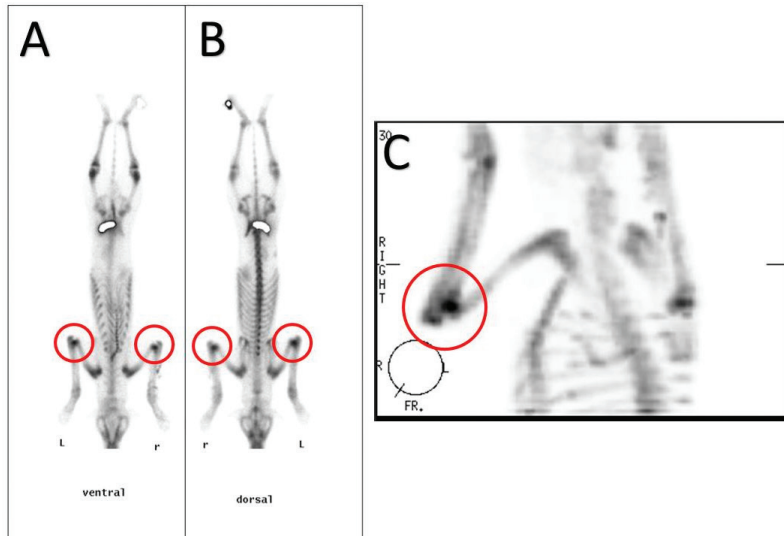


Figure 1. Scintigraphic study performed one week after admittance. On all acquisitions in the area of both elbows an increased uptake of the tracer can be appreciated (left > right) (red circle) **A:** Ventral total body scan. **B:** Dorsal total body scan. **C:** SPECT of the right fore limb.

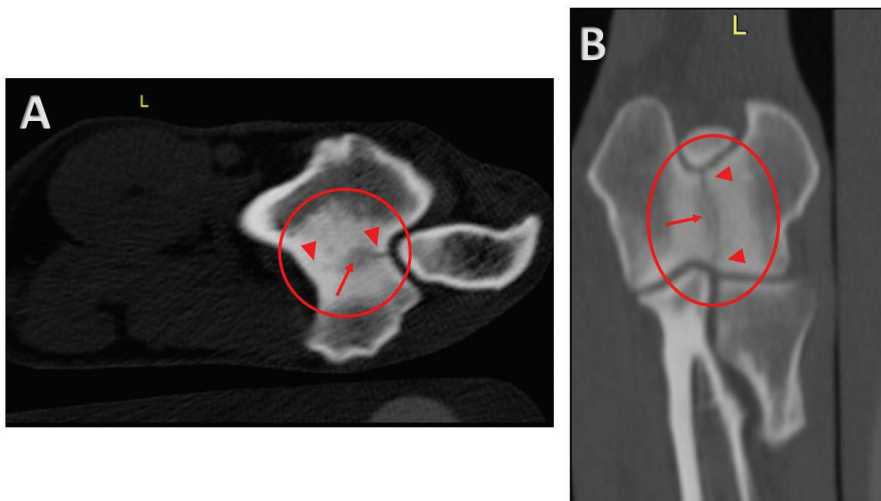


Figure 2. CT images of the left elbow one month after admittance. **A:** Transverse image through the left elbow in the area of the distal humerus and the olecranon. A prominent hyperdense zone is visible (circle) with a central, linear, broad hypodense zone (arrow) involving both cortices (arrow heads). **B:** Dorsal reconstruction at the level of the humeral condyles. A prominent hyperdense zone can be appreciated (circle) with, in the centre, a local broad hypodense zone (arrow) involving both the proximal and distal cortices (arrow heads).

carried out but revealed no abnormalities. Because of the distension of both elbow joints, an elbow problem was expected. Flexion tests of both elbows and shoulders were negative. Because of the lack of radiographic findings on the radiographs of the referring veterinarian and the unclear clinical findings, scintillography was performed (Debruyne *et al.*, 2013) (Figure 1). The results of this examination proved clear involvement of both elbows.

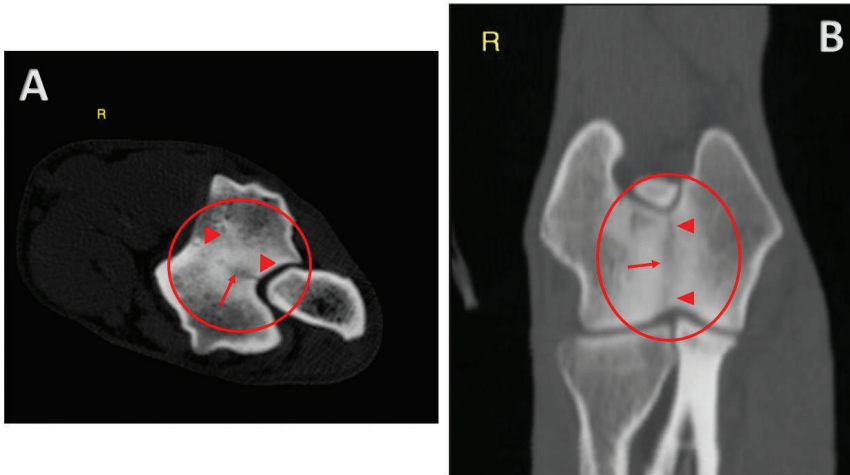


Figure 3. CT images of the right elbow one month after admittance. **A:** Transverse image through the right elbow at the level of the distal humerus and olecranon. A prominent hyperdense zone is visible (circle) with a central, linear, broad hypodense zone (arrow) involving both cortices (arrow heads). **B:** Dorsal reconstruction at the level of the humeral condyles. A prominent hyperdense zone can be appreciated (circle) with, in the centre, a local broad hypodense zone (arrow) involving both the proximal and distal cortices (arrow heads).

Because of this result, a CT scan of both elbows was advised and performed one month after the first admittance (De Rycke *et al.*, 2002) (Figures 2 and 3). On these images, a prominent hyperdense zone can be appreciated in both elbows, with a central, linear, broad hypodense area, and with involvement of both the dorsal and caudal cortices. These images are compatible with incomplete ossification of the humeral condyle (IOHC) in both elbows.

After the CT examination, an arthroscopic examination of the left elbow was performed to check the status of the articular cartilage (Meyer-Lindenberg *et al.*, 2002). A superficial line between both condyles could be seen (Figure 4). The articular cartilage showed a smooth appearance without degenerative changes. The rest of the joint showed no abnormalities. The final diagnosis of this case was bilateral incomplete ossification of the humeral condyles (IOHC), based on the CT and arthroscopic findings.

The classical treatment in such a case is a trans-condylar screw but because of the absence of obvious lameness, a conservative treatment was initiated, which consisted of rest and avoiding trauma (Moores, 2006). Also, physiotherapeutic treatment was

advised to stimulate healing. As an alternative option, forage was advised, which involves penetrating both condyles with a small bur in order to stimulate bone healing. The owners decided not to start with physiotherapy and rejected forage treatment. They preferred to rest the dog and to avoid possible trauma. The dog showed no lameness during the following year, but thereafter, he started increasingly limping on his left front leg. NSAIDs were administered, but only offered temporary relief. The lameness became aggravated, to the extent that the dog was sometimes incapable of bearing its own weight. Therefore, the dog was admitted once more for an orthopaedic examination. On inspection, the dog showed a stiff gait and on palpation, a severe muscle atrophy of the left front leg and a moderate atrophy of the right front leg were noticed. On palpation, moderate distension of both elbows could be appreciated and some pain reaction could be elicited on extension. It was decided to perform a new CT examination to evaluate the progression of the lesions (Figures 5 and 6). When the new CT images of the left elbow were compared with those obtained one year previously, it was clear that proximally, the hypodense line was less prominent but distally, it remained the same. The sclerosis remained comparable as well. On the new

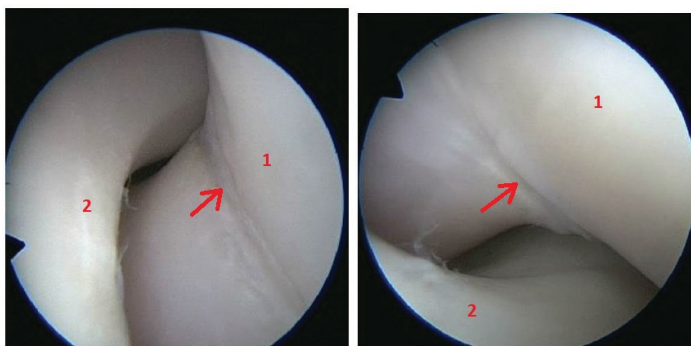


Figure 4. Arthroscopic image of the left elbow. An intercondylar fissure between both humeral condyles can be appreciated (arrow). The articular cartilage looks unaffected. 1: Distal humerus. 2: Incisura trochlearis ulnae.

CT images of the right elbow, the radiolucent line became less distinct compared with the previous images. The sclerotic reaction, however, had increased. These findings suggested that in both elbows, a slight progression of the original lesions had occurred. Due to the aggravation of the clinical symptoms in the left elbow, it was decided to perform forage and to start physiotherapy.

Three weeks later, the forage was conducted using a 1.5-mm Kirschner wire through mini skin incisions. Four to five drillings (forages) were applied to both humeral condyles. The first physiotherapeutic session consisted of laser treatment with a Class IV K-Laser, and therapeutic ultrasound was performed afterwards. The laser emitted a visible red beam at 850 nm wavelength with a dose of 936 joules per session. Fifty

% pulsed ultrasound therapy was applied with a treatment frequency of 1 MHz. and a stimulation of 0.6 W/m^2 .

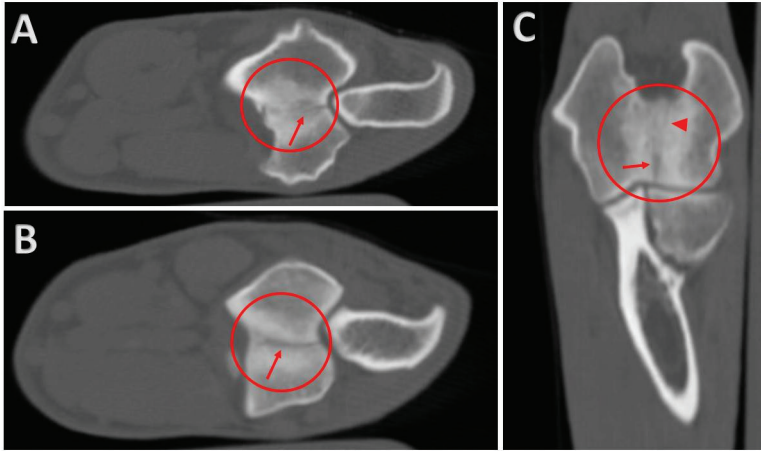


Figure 5. **A & B:** Transverse CT images through the left elbow in the area of the distal humerus and the olecranon. In comparison to the images of one year earlier, the hypodense zone has decreased in size (arrows). The sclerotic zone more or less remained the same (circle). **C:** Dorsal reconstruction: the hypodense zone proximally is less visible (arrow head). Distally (arrow), it has a similar aspect as one year ago. The hyperdense area (sclerosis) remains comparable (circle).

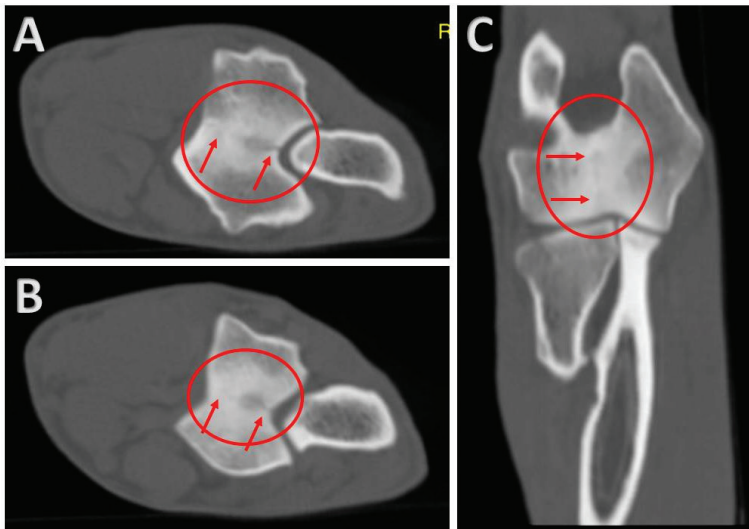


Figure 6. **A & B:** Transverse CT images through the right elbow in the area of the distal humerus and the olecranon. In comparison to the images of one year earlier, the hypodense zone looks less distinct (arrows). The sclerotic zone has increased in size (circle). **C:** Dorsal reconstruction: the hypodense zone looks less defined than one year ago (arrows). The hyperdense area (sclerosis) has increased in size (circle).

The patient remained hospitalised and recovered well. Eight sessions were carried out in a two-week period, after which the dog was clinically examined. According to the owners, the dog improved and showed no signs of lameness at inspection. On palpation, only a slight swelling could be appreciated at the surgical site. At a follow-up visit one year later, the dog showed no signs of lameness.

DISCUSSION

This report describes an unusual case of elbow lameness. Elbow lameness is most often due to elbow dysplasia, and incomplete ossification of the humeral condyle (IOHC) is a rather rare orthopaedic condition and the diagnosis can be challenging. In this case the breed and onset of the lameness are atypical. Most cases described involve the Cocker Spaniel (Marcellin-Little et al., 1994; Moores, et al., 2012), while the German Shepherd is not a predisposed breed. Mostly the patients are of middle age at the time of presentation, but the presented German Shepherd was only three years of age. This was one of the reasons that a diagnosis of IOHC was not initially made, and moreover, the initial radiographs were unremarkable and did not show the typical radiolucent line in the area of the distal humerus representing the fissure. This was probably due to the fact that the cranio-caudal radiographs were not taken at the right angulation. In order to visualise a fissure or fracture line, the radiographic beams must be parallel to the fissure line. Often, multiple radiographs with different angulations have to be prepared, which was not done in this particular case.

On the other hand the clinical symptoms were quiet compatible with IOHC. The dog showed an intermittent lameness aggravating during and after exercise and which was not responsive to medical treatment. At the time of the first presentation, the patient only showed a stiff gate but no obvious lameness. Although muscle atrophy and slight distension of both elbows was present, no pain reaction could be elicited on flexion or extension. Because of the uncertain localisation, a scintigraphic examination was carried out which showed obvious elbow involvement. As scintigraphy is very sensitive but not very specific, a CT scan was conducted. This clearly showed the typical CT features of IOHC – a saw-toothed intercondylar complete or incomplete hypoattenuating defect with hyperattenuating sclerotic margins. The diagnosis was confirmed by an arthroscopic examination, revealing a linear fissure in the articular cartilage of the distal humeral condyle.

Because of the lack of lameness at the time of presentation, the owners preferred conservative treatment consisting of rest and avoiding trauma. The dog responded favourably to this option for a one-year period, but subsequently relapsed and was unresponsive to medical treatment. Although on a repeated CT examination the lesions seemed to have improved, it was decided to start physiotherapy and forage to stimulate fusion. The more common therapy of trans-condylar screwing was declined because of possible complications such as screw breaking. The dog responded well to

the combination of forage and physiotherapy, but it is, of course, difficult to conclude which part of the therapy was effective.

The conclusion of this case is that in dogs with elbow lameness without clear symptoms and inconclusive radiographic examination, a differential diagnosis of IOHC should be considered and a CT examination of both elbows is amply justified. The superiority of CT over conventional radiographs with regard to CT's sensitivity and specificity in elbow pathology cannot be overemphasised. The use of CT eliminates the superposition of bony structures and provides better visualization of the lesions (Villamonte-Chevalier, et al., 2015). The optimal treatment remains debatable but the results of the treatment of this patient suggest that forage combined with physiotherapy could offer a justifiable option.

Authors' contributions

M. Mitrović – Writer of the manuscript, Y. Samoy – Orthopedic examination, M. Lazarević Macanović – Radiological and CT examination, I. Gielen – CT examination, H. van Bree – Scintigraphic study

Declaration of conflicting interests

We confirm that there is no a competing interest with other people or organisations regarding this manuscript.

REFERENCES

- Carrera I., Hammond G.J.C., Sullivan M. 2008. Computed tomographic features of incomplete ossification of the canine humeral condyle. *Veterinary Surgery*, 37:226-231. doi: 10.1111/j.1532-950X.2008.00370.x.
- Cook J.L., Forelimb lameness in the young patient. 2001. *Vet Clin North Am Small Anim Pract*, 31:55-83. [https://doi.org/10.1016/S0195-5616\(01\)50038-8](https://doi.org/10.1016/S0195-5616(01)50038-8).
- Cook C.R., Cook J.L. 2009. Diagnostic imaging of canine elbow dysplasia: a review. *Veterinary Surgery*, 38:144-53. doi: 10.1111/j.1532-950X.2008.00481.x.
- De Bakker E., Gielen I., Saunders J.H., Polis I., Vermeire S., Peremans K., Dewulf J., van Bree H., van Ryssen B. 2013. Primary and concomitant flexor enthesopathy of the canine elbow. *Veterinary and Comparative Orthopaedics and Traumatology*, 26:1-10. doi: 10.3415/VCOT-12-02-0025.
- Debruyne K., Peremans K., Vandermeulen E., Van Ryssen B., J Saunders. 2013. Evaluation of semi-quantitative bone scintigraphy in canine elbows. *Veterinary Journal*, 196:424-30. doi: 10.1016/j.tvjl.2012.10.022.
- De Rycke L., Gielen I., van Bree H., Simoens P. 2002. Computed tomography of the elbow joint in clinically normal dogs. *American Journal of Veterinary Research*, 63:1400-7. <https://doi.org/10.2460/ajvr.2002.63.1400>.
- Fitzpatrick N., Smith T.J., O'Riordan J., Yeadon R. 2009. Treatment of incomplete ossification of the humeral condyle with autogenous bone grafting techniques. *Veterinary Surgery*, 38:173-184. doi: 10.1111/j.1532-950X.2008.00485.x.

- Hoskinson J.J., Tucker R.L. 2001. Diagnostic imaging of lameness in small animals. *Vet Clin North Am Small Anim Pract* 31:165-80. [https://doi.org/10.1016/S0195-5616\(01\)50043-1](https://doi.org/10.1016/S0195-5616(01)50043-1).
- Marcellin-Little D., Deyoung D., Ferries K. Berry C. 1994. Incomplete ossification of the humeral condyle in spaniels. *Veterinary Surgery* 23:475-487.
- Meyer-Lindenberg A., Heinen V., Fehr M., Nolte I. 2002. Incomplete ossification of the humeral condyle as the cause of lameness in dogs. *Veterinary and Comparative Orthopaedics and Traumatology*, 3:187-194.
- Moore A. 2006. Humeral condylar fractures and incomplete ossification of the humeral condyle in dogs. *In Practice*, 28:391-397. <http://dx.doi.org/10.1136/inpract.28.7.391>
- Moore A., Agthe P., Schaafsma I. 2012. Prevalence of incomplete ossification of the humeral condyle and other abnormalities of the elbow in English Springer Spaniels. *Veterinary and Comparative Orthopaedics and Traumatology*, 25:211-216. doi: 10.3415/VCOT-11-05-0066.
- Samoy Y., Van Ryssen B., Gielen I., Walschot N., van Bree H. 2006. Review of the literature: elbow incongruity in the dog. *Veterinary and Comparative Orthopaedics and Traumatology*, 19:1-8.
- Scott H., Witte P. 2011. Investigation of lameness in dogs 1. Forelimb. *In Practice*, 33:20-7.
- Villamonte-Chevalier A., van Bree H., Broeckx B., Dingemans W., Soler M., van Ryssen B., and Gielen I. 2015. Assessment of medial coronoid disease in 180 canine lame elbow joints: a sensitivity and specificity comparison of radiographic, computed tomographic and arthroscopic findings. *BMC Veterinary Research*, 11:243. <https://doi.org/10.1186/s12917-015-0556-9>.

NEPOTPUNA OSIFIKACIJA KONDILUSA RAMENE KOSTI DIJAGNOSTIKOVANA KOD NEMAČKOG OVČARA STAROG TRI GODINE

MITROVIĆ Marko, SAMOY Yves, LAZAREVIĆ MACANOVIĆ Mirjana,
van BREE Henri, GIELEN Ingrid

Kratak sadržaj

U ovom radu je prikazan slučaj nepotpune osifikacije kondilusa ramene kosti kod nemačkog ovčara starog tri godine. Ovo patološko stanje se retko javlja kod pomenute rase pasa, a klinički se ispoljava hromošću prednjih ekstremiteta. Na osnovu kliničkog pregleda i analize rendgenskih snimaka, kod obolele životinje nije bilo moguće postaviti dijagnozu. Oboljenje je, međutim, uspešno dijagnostikovano metodom scintigrafije i kompjuterizovane tomografije, dok su artroskopskim pregledom verifikovana oštećenja na zglobnim hrskavicama u interkondilarnom delu ramene kosti. S obzirom na to da u trenutku prijema pacijenta intermitentna hromost nije bila uočljiva, preporučeno je samo smanjenje fizičke aktivnosti životinje. Iako klinički znaci bolesti nisu bili prisutni tokom godinu dana, hromost prednjeg levog ekstremiteta se nakon tog perioda ponovo javila. Pri kontrolnom pregledu metodom kompjuterizovane tomografije uočeno

je progrediranje oštećenja. Pored korekcije ishrane, uključena je i fizikalna terapija koja je podrazumevala primenu lasera i ultrazvučnih talasa. Na upotrebu ove vrste terapije je pas povoljno reagovao i do sada se hromost nije ponovo javila. S obzirom na postignute rezultate kod ovog pacijenta, kao i to da ne postoji specifičan tretman nepotpune osifikacije kondilusa ramene kosti, korekcija ishrane i fizikalna terapija bi mogle predstavljati dobru opciju u tretiranju ovog oboljenja.

Ključne reči: hromost prednjih ekstremiteta, kompjuterizovana tomografija, nepotpuna osifikacija kondilusa ramene kosti, ortopedija, pas