

## **EFFECTS OF LOCAL ADMINISTRATION OF PLATELET-RICH PLASMA AND GUIDED TISSUE REGENERATION ON BONE HEALING IN EARLY INSERTED DENTAL IMPLANTS – A HISTOMORPHOMETRIC ANALYSIS**

DUKA Miloš<sup>1\*</sup>, LAZIĆ Zoran<sup>1</sup>, BUBALO Marija<sup>1</sup>, MIHAILOVIĆ Branko<sup>1</sup>, MILADINOVIĆ Milan<sup>1</sup>, GVOZDIĆ Dragan<sup>2</sup>

<sup>1</sup>Military Medical Academy, Department of Oral Surgery, Clinic for Dentistry, Crnotravska 17, 11000 Belgrade, Serbia; <sup>2</sup>University of Belgrade, Faculty of Veterinary Medicine, Department of Pathophysiology, Bulevar oslobođenja 18, 11000 Belgrade, Serbia

Received 25 December 2017; Accepted 27 November 2018

Published online: 13 February 2019

Copyright © 2019 Duka et al. This is an open-access article distributed under the Creative Commons Attribution License, which permits unrestricted use, distribution, and reproduction in any medium, provided the original work is properly cited

### **Abstract**

*Introduction.* In order to provide the most favorable conditions for bone healing following implant loading, new techniques such as the use of growth factors to directly or indirectly regulate cell and tissue growth are becoming increasingly popular. Simplicity in producing concentrated thrombocytes derived from platelet-rich plasma has led to increasing application of growth factors derived from thrombocytes, such as PDGF, TGF- $\beta$ , IGF and VEGF, in order to increase the percentage of bone-to-implant contact that provides better implant stability and possibly earlier functional loading. The aim of the study was to determine the effects of platelet-rich plasma and guided tissue regeneration on bone regeneration in the case of bone defects in early dental implant insertion.

*Materials and Methods.* This experimental study was conducted on 10 study dogs that received 40 BCT implants, i.e., 4 implants per dog. The study included early dental implant placement in the sites of the extracted premolars. Artificial bone defects, resembling peri-implantitis defects, were made on the mesial side of each site, and the defects were filled using suitable guided tissue regeneration protocols with platelet-rich plasma derived from each experimental animal an hour before surgery. Histopathologic and histomorphometric evaluations were performed 10 months following the implantation.

*Results and Conclusion.* The applied protocols had different effects on bone healing. According to the results obtained, the use of platelet-rich plasma combined with

---

\*Corresponding author – e-mail: milosvduka@gmail.com

deproteinized bovine bone and bovine-derived resorptive membrane provided superior bone defect ossification.

**Key words:** dogs, dental implant, early implant insertion, guided tissue regeneration, PRP

## INTRODUCTION

A clear definition of dental implant placement following extraction has to be based on morphological and histological bone changes following tooth extraction. There are a few classifications of dental implant placement into an alveolus after extraction (Hammerle & Lang, 2001):

- Dental implant placement immediately after tooth extraction – immediate post-extraction implant placement.
- Dental implant placement after covering an alveolus with soft tissue – usually in a 4-8-week period following extraction.
- Dental implant placement after an alveolus fill with bone tissue – usually in a 12-16-week period following extraction.
- Dental implant placement after complete healing of both soft and bone tissues – usually in a 16-week period following extraction.

The basic requirements for successful bone healing in immediate and delayed dental implant placement are the same as in the already healed alveolar ridge. Osseointegration depends on the stability of initially formed coagulum at this site. Experiments on animals have suggested bone-to-implant distance and its surface characteristics as critical factors for coagulum stabilization (Botticelli et al., 2003; Akimoto et al., 1999; Stentz et al., 1997). However, the lack of intact alveolar walls could produce unfavorable effects on blood coagulum stability and bone formation. Under such conditions, it is appropriate to apply the technique of guided tissue regeneration in order to provide bone regeneration and implant osseointegration (Botticelli et al., 2003; Akimoto et al., 1999; Gher et al., 1994).

Guided tissue regeneration in implantology is a method based on the principle of bone separation from soft tissue by the use of a membrane, thus providing space for newly formed bone to grow into it ( Dahlin et al., 1995; Jovanovic et al., 1992; Dahlin et al., 1991; Buser et al., 1990).

Platelet-rich plasma (PRP), concentrated platelets in a small volume of blood, can be isolated by centrifugation of patient's blood in a blood bank, or preoperatively at the dentist's office. Growth factors found in platelet granules are also a constituent part of PRP and are released during platelet activation, thus initiating bone healing (Sonnleitner et al., 2000; Anitua, 1999; Marx et al., 1998). For the last two years, the ease of application and its availability have made PRP the most commonly applied source of growth factors in implantology for the purpose of obtaining the highest possible

percentage of implant surface-bone contact. This contact provides higher implant stability and sooner functional implant loading. The two growth factors significant for bone regeneration found in PRP are platelet-derived growth factor (PDGF) and transforming growth factor beta (TGF-beta).

The aim of this study was to determine the effect of PRP and guided tissue regeneration on bone healing in early dental implant placement.

## **MATERIALS AND METHODS**

This experimental study was performed in the Dental Implant Department, Clinic of Dentistry, Military Medical Academy and the Medical Research Institute, Military Medical Academy, Belgrade, Serbia. This 3-stage study on 10 adult German shepherd dogs met the ethical requirements of the MMA (VMA) No. 282-12 Regulations. The animals were 3.8 years old on average, and an average weight of 25.3 kg.

### **Stage I**

Combelen 0.03 ml/kg *i.v.* and 0.01 mg/kg atropine percutaneously were used for premedication. Fifteen minutes following premedication 5% ketamine chloride (ketamine chloride 0.3 ml/kg) was applied intramuscularly.

Extractions of the second and third premolar of the lower jaw bilaterally, were performed in order to place dental implants, following extraction wound healing. Extraction sockets were closed by the use of surgical suture (Dexon 3.0, Davis & Gack). Antibiotic (Jugocilin, 600000 I.U.) was administered to the experimental animals, and 12 h following the intervention, the dogs received food and water. The dogs were fed with mushy food and kept in specially designed boxes made of prochrome, providing easy cleaning and disinfecting. These boxes were under regulated humidity and temperature (21°C) conditions and situated in the Medical Research Institute, Military Medical Academy, Belgrade.

### **Stage II**

Eight weeks following the second and third premolar bilateral extractions in the lower jaw, as described above, blood samples were drawn from the dogs into three sterile test-tubes. Each test-tube was filled with 4.5 ml blood, with 0.5 ml Na citrate as an anticoagulant. The first and the third test-tubes were used to determine platelet counts. The first tube showed the platelet count immediately after blood was drawn, while the third tube showed platelet count after PRP preparation. Test-tubes were centrifuged in the ALC PK 110 centrifuge at 1,200 rpm (first centrifugation), resulting in two fractions: the lower fraction (blood cell components: erythrocytes, thrombocytes, leukocytes), and the upper fraction (plasma).

Within the lower fraction there were two levels, the upper level with the highest platelet concentration, and the lower level that contained other cell components of blood. The

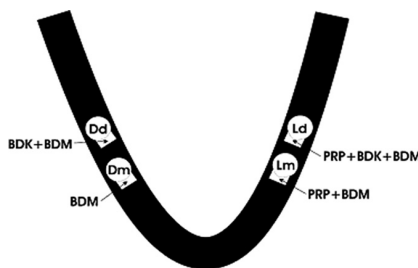
cut-off line was determined between the lower and the upper fraction, and 6 mm off it in the direction of the lower fraction, the border line was marked on the test-tube. The content above this border line was aspirated and centrifuged again, this time at 2,000 rpm (400 *g*) for 15 minutes.

Following the second centrifugation, the upper (plasma and the small thrombocytes), and the lower fractions of PRP were separated again. The upper fraction was removed by pipette, while the lower fraction was prepared for further use. In this PRP, the thrombocyte count was about 2000000/ $\mu$ L. This thrombocyte concentrate turns into gel within 15-20 min and can be used within the next 60 min. PRP was prepared according to the method of Sonnleitner (2000).

### Implant placement

The second stage of the study included early dental implant placement in the sites of the extracted premolars. Implant sites were prepared, and artificial bone defects, resembling peri-implantitis defects, were made on the mesial side of each site. The bone defects measured 2 mm horizontally and 4 mm deep. A cylindrical BCT 5-thread, SLA surface, implant was placed into each prepared site. The total implant neck and body length was 13.7 mm, the neck diameter was 4.5 mm, while the body diameter was 3 mm. The pitch was 1.75 mm.

Immediately after the implant insertion into the bone socket, for animals receiving two of the examined procedures, the mesial bone defect was filled, using a suitable protocol, with PRP derived from each experimental animal an hour before surgery. Figure 1 shows the disposition of dental implants and bone defect fills.



**Figure 1.** A schematic disposition of dental implant placement and bone defect fills; Dd – right distal; Dm – right mesial; Ld – left distal; Lm – left mesial; BDK – bovine deproteinized bone; BDM – bovine demineralized membrane; PRP – platelet-rich plasma.

Bone defects were filled using one of four guided tissue regeneration protocols:

- I. PRP combined with bovine deproteinized bone (BDK) and bovine-derived resorptive membrane (BDM) of 150  $\mu$  thickness to the left side of the lower jaw in the alveola after extraction of the third left distal premolar (Ld);
- II. BDK and BDM of 150  $\mu$  thickness to the right side of the lower jaw in the alveola after extraction of the third right distal premolar (Dd);
- III. PRP and BDM of 150  $\mu$  thickness to the left side of the lower jaw in the alveola after extraction of the second left mesial premolar (Lm);

IV. BDM of 150  $\mu$  thickness to the right side of the lower jaw in the alveola after extraction of the second right mesial premolar (Dm).

### **Stage III**

Samples for histopathologic evaluation were taken 10 weeks after implant placement by ostectomy of the parts of the lower jaw with implants inserted. Bone blocks were placed into glass pots with 10% neutral buffered formalin and adequately marked. These samples were submitted to the Institute of Pathology, Military Medical Academy for further evaluation, where the implants were removed mechanically out of bone sockets, and each sample cut into thin segments and submitted to decalcination.

After decalcination, the samples were paraffin embedded, cut on a microtome, and the obtained histopathologic preparations were stained using the methods of hematoxylin-eosin (HE), periodic acid-Schiff (PAS), Masson's Trichrome, PAF-Halmi and van Gieson. This histopathologic study was quantified and expressed in a numerical index 0-2.

### **Histomorphometry**

By analyzing the described histopathologic changes of the experimentally made defects and preserved bone tissue in each of the four experimental groups, the following histopathologic characteristics were selected to objectively evaluate the success of reparation of the created defects:

1. The extent of preserved compact bone tissue (CBT),
2. Borderline between the preserved bone tissue and newly-made connective tissue in the created defect (BL),
3. The central part of defect fill and maturity of newly-made connective tissue (CDPF) in the created defect (number of fibrocytes, fibroblasts and newly-made blood vessels),
4. The osteocyte count as an indication of positive osteoblastic reaction (OSC),
5. The osteon count and the percent ratio of the primary osteon count and matrix (FPO),
6. The presence/extent of necrosis-affected bone tissue (NECR).

Compact bone tissue preserving the extent, cut-off line between the preserved bone tissue and newly-made connective tissue in the created defect, the central part of the defect fill and the maturity of newly-made connective tissue (number of fibrocytes, fibroblasts and newly-made blood vessels), as well as the necrosis extent were evaluated according to a descriptive evaluation of histopathologic analysis of preparations with scores of 0, 1 and 2 as shown in Table 1.

**Table 1.** The criteria for evaluating histologic characteristics of the four studied guided tissue regeneration protocols

Histologic characteristics	Evaluation		
	0	1	2
Preserved compact bone tissue (CBT)	Very reduced width	Low to medium preserved width	Quite preserved compact bone tissue
Borderline between preserved bone tissue and newly-made connective tissue (BL)	Quite unclear borderline	Less clear borderline	Quite preserved borderline
Experimentally made bone defect fill with newly-made connective tissue and its maturity (CDPF)	Extremely reduced number of both cell populations & increase in newly-made blood vessels filled with newly-made connective tissue in more than ½ of experimentally made defect	Equally present number of both cell populations within the normal number of newly-made blood vessels filled with newly-made connective tissue in more than ½ of experimentally made defect surface	Mature fibrocytes prevalence & the presence of normal number of newly-made blood vessels filled with newly-made connective tissue in more than ½ of experimentally made defect central part only
Osteocyte count (OSC)	≤ 600/mm <sup>2</sup>	600-1000/mm <sup>2</sup>	≥ 1000/mm <sup>2</sup>
Osteon count & primary osteons and matrix percentage (FPO)	≤ 8%	8-10%	≥ 10
Necrosis extent (NECR)	Necrotic foci affecting most of the surface	Individual necrotic foci over small surface	No necrosis

The mean for all 10 evaluated dogs for each of the analyzed histopathologic changes in all the experimental groups was calculated. The sum of the means for all the analyzed histopathologic changes gave the score of success in bone fill with the bone restoration protocols. The score values in relation to outcome of bone defect fill were divided into three groups: 0-6 unfavorable; 6.1-9 favorable; 9.1-12 optimal.

Histomorphometric measurements were performed on digital images of the histologic preparations made by a digital microscope Nikon Coolscope at 100x magnification. Morphometric analysis was performed on an average of 15 visual fields from each preparation (25 x 10 x 4), which were enough to describe one cross-section through the whole preparation. Osteocyte counts were to evaluate the extent of positive osteoblast activity, i.e., to evaluate the effect of the percentage of the formed primary osteons and the matrix on the success of the created bone defect fill. Osteocyte counts were performed by the adjusted stereometric procedure on digital images of histopathologic preparations made by a digital microscope Nikon Coolscope at 400x magnification and the use of the program CAMIA at the Center of Pathology and Forensic Medicine.

## Statistical analyses

Mean values, standard deviation, median and interquartile ranges were used for the descriptive statistics parameters. The Kolmogorov-Smirnov Test was used to check the normality of data distribution. The Kruskal-Wallis Test was used to determine eventual statistically significant differences between the groups, and the Mann-Whitney test to compare the differences between the two independent groups. Statistical significance was set at  $p < 0.05$ .

Complete statistical analysis was performed using the commercial statistical software SPSS Statistics 18.

## RESULTS

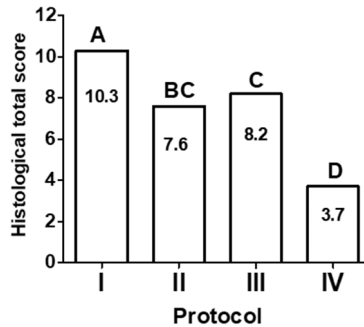
Histopathologic changes in the created defects and the preserved bone tissue in all four experimental groups were analyzed regarding the major histopathologic characteristics, to objectively evaluate the success in reparation of the defects created. The extent of compact bone tissue preservation, the cut-off line between the preserved bone tissue and newly-made connective tissue in the created defects, the central part of defect fill and the maturity of newly-made connective tissue (the number of fibrocytes, fibroblasts and newly-made blood vessels), as well as the extent of necrosis were evaluated according to descriptive evaluation of histopathologic analysis of preparations with scores 0, 1 and 2 as shown in Table 1. The score values reflecting the outcomes of bone fill were grouped as shown in Table 2.

**Table 2.** Comparison between protocols regarding histomorphometric characteristics evaluation

Histomorphometric characteristics	Evaluation, median (interquartile range)					
	Protocol I	Protocol II	p value	Protocol III	Protocol IV	p value
CBT	2.00 (2.00-2.00)	1.00 (1.00-2.00)	$p = 0.022$	2.00 (1.75-2.00)	0.00 (0.00-1.00)	$p < 0.001$
BL	2.00 (1.00-2.00)	1.00 (0.75-1.00)	$p = 0.006$	1.00 (1.00-2.00)	0.00 (0.00-0.00)	$p < 0.001$
CDPF	2.00 (1.00-2.00)	1.00 (1.00-2.00)	$p = 0.067$	1.00 (1.00-1.25)	1.00 (1.00-1.25)	$p = 1.000$
OSC	2.00 (1.75-2.00)	1.00 (1.00-2.00)	$p = 0.025$	1.00 (0.75-2.00)	1.00 (0.75-1.00)	$p = 0.491$
FPO	1.50 (1.00-2.00)	1.00 (1.00-2.00)	$p = 0.707$	1.00 (1.00-2.00)	1.00 (1.00-2.00)	$p = 1.000$
NECR	2.00 (1.75-2.00)	2.00 (1.00-2.00)	$p = 0.342$	2.00 (1.75-2.00)	0.00 (0.00-0.25)	$p < 0.001$

Our results presented in Table 2 show that protocol IV scored the lowest values in three important histopathologic characteristics: CBT, BL and NECR. There was extremely reduced width of compact bone tissue (CBT) and quite an unclear borderline between preserved bone tissue and newly-made connective tissue (BL) in protocol IV.

Comparisons between the protocols are shown in Figure 2.



**Figure 2.** Summed means of evaluated histomorphometric characteristics of the protocols; bars marked with different letters are significantly different ( $p < 0.05$ ).

There were significant differences between the bone regeneration in all the protocols except between protocols II and III. However, protocol I, using PRP combined with BDK and BDM, produced the highest sum of mean values for histomorphologic assessment of the bone defect fills (Figure 2; 10.3). There was a significant difference between the optimal protocol I compared to all other three protocols. A slightly lower total histomorphologic score was evident in protocol III (Figure 2; 8.2). Both protocols using PRP had high sums of mean values for histomorphologic assessment of the bone defect fills. Protocol IV, using only BDM, achieved the lowest summed mean of the histomorphologic assessments (Figure 2; 3.7).

## DISCUSSION

To characterize modern implantology with just one word, it should certainly be the word 'osseointegration'. The clinical success of endosteal implants, or as they were referred to recently, osseointegrated implants, mostly depends on the condition, formation, and immediate preservation of the optimal bone-to-implant contact.

Application of resorptive BDM by the protocol of guided bone regeneration in our investigation was inferior to the combination of BDM with other elements (bone replacement and/or PRP), so it was unfavorable for use alone, and should be ruled out as a bone defect fill procedure. Probably the most important factor contributing to the unfavorable effect of BDM alone was the high number of necrotic foci affecting



the surface between newly-made connective tissue and remaining bone. This finding does not agree with one study (Becker et al., 1992), but it agrees with results obtained by Kohal et al. and somewhat with the results of de Vicente et al. (Kohal et al., 1999; de Vicente et al., 2006).

Studying the effects of PRP application in oral and periodontal surgery has three directions today: PRP application in combination with dental implants; PRP application in combination with bone grafts, and; PRP application in reconstructive periodontal surgery. To date, PRP application in combination with bone grafts has been studied the most, and the results obtained vary to a great extent. In a controlled clinical study on 88 patients with continual lower jaw defect of minimum 5 cm replaced with autologous spongy bone, or with autologous spongy bone combined with PRP, a radiographically measured increase in bone density by 1.62 to 2.16 times, as well as a histological and histomorphometrical increase in bone density was determined in the PRP application (Marx et al., 1998). Six months following the beginning of the research, the bone hardness in the group treated with PRP was 25% higher than that of the control group. In our study, the histomorphometric results showed the highest mean value of bone defect fill was obtained with our protocol I, using PRP together with deproteinized bovine bone and BDM, so it was the most optimal procedure for bone regeneration around dental implants. Our protocol III, using PRP and BDM, was also a relatively favorable procedure for bone regeneration. Noticeably, these two protocols both utilized PRP, indicating that PRP is an important factor contributing to the process of bone regeneration.

The results obtained by Weibrich et al. (2002) are considered very interesting due to the fact that they tested the two PRP production systems: a Curasan-type PRP kit versus the PCCS PRP system. The final products of these methods differ, and this can affect the final results (Weibrich et al., 2002). These authors preferred the PCCS method, not only because of the results but also because of the ease in clinical application. Of the numerous advantages of this method, we point out the higher thrombocyte counts in the end product and the good quantity of PRP obtained. Further research by Weibrich et al. included the influence of thrombocyte count on the biological effect of PRP using histomorphometric analysis of bone regeneration in the area of bone-implant contact (Weibrich et al., 2002). They obtained a statistically significant improvement in the increase of bone regeneration when they used PRP with a higher mean thrombocyte concentration. The results of these studies indicate that thrombocyte concentration in PRP could affect the biological effect, but also that the optimal effect can be obtained within a relatively narrow range. Our results, however, achieved with a somewhat higher average number of thrombocytes, suggest that a combination of PRP, deproteinized bovine bone and a membrane could give a statistically better effect on bone regeneration and peri-implant bone defect fill.

On the other hand, the role of PRP in cranial defect reconstruction was studied by filling them with: autogenous bone graft; PRP only, or; a combination of autogenous

bone graft and PRP (Aghaloo et al., 2002). The results of that study showed a significant increase in both the bone area, and radiographic bone density in the group with the application of bone autograft, regardless of the PRP. Although the authors noticed that bone regeneration was highest in the first month in the group with PRP combined with bone graft, they concluded that the application of PRP combined with bone autograft has no significant justification. Our study, however, determined a statistically significant difference in bone tissue density between our protocols I (higher density) and II (lower density). This fact indicates that PRP provides better conditions for bone regeneration in the area of peri-implant defects when applied in combination with deproteinized bovine bone. The question remains about the type of changes that could be seen if the bone defects were filled with autogenous bone graft instead of deproteinized bovine bone as was done previously (Aghaloo et al., 2002).

Froum et al. tested the effects of PRP combined with deproteinized bovine bone (Bio-Oss) on bone regeneration (Froum et al., 2002). Histomorphometric analysis showed no significant difference between their control, regenerated with no PRP, and the bone regenerated with Bio-Oss and PRP. Continuing their investigation of PRP significance as an adjuvant agent in transplantation and implantation of both allograft and xenograft, however, Aghaloo et al. (2004) found a significant impact of PRP addition to Bio-Oss on bone regeneration. Histomorphometric analysis showed a significant increase in bone density of defects filled with autogenous bone, Bio-Oss and a combination of Bio-Oss and PRP in all stages of testing, when the highest regeneration degree was noticed in the group with PRP application. The results of our current study comply with these findings.

By studying the problem of bone regeneration, numerous researchers concluded that the optimal effect of PRP-derived growth factor application is obtained in combination with bone morphogenetic protein – BMP. After reviewing numerous papers, Anusaksathien and Giannobile gave their opinion about the effects of growth factors on periodontal tissue restitution (Anusaksathien and Giannobile., 2002). A similar review of numerous studies focused on bone growth factors review in maxillofacial skeletal reconstruction (Schliephake., 2002). Based on data from 231 references, this author characterized the biological and developmental nature of growth factors, referring to their molecular activity and osteogenic potential in maxillofacial regeneration and reconstruction. Apart from the conclusion that BMP has the highest effect on bone regeneration and reconstruction, the author paid special attention to the combination of PDGF and IGF in dental implantology, pointing out that this combination promises better bone regeneration in dentoalveolar defects around the implant. This activation happens in the initial stage of bone regeneration, when growth factors are released after degranulation of thrombocytes that takes place in 3-5 days following the application. The effect of growth factors is expected between days 7 and 10 following the implant.

Favorable effects of PRP application are seen in two aspects: firstly, the production of PDGF and TGF during thrombocyte degranulation, and; secondly, the impact of

PDGF and TGF in the early stages of regeneration before the other growth factors take a leading role. PRP application is indicated especially in cases of increased risk for implantation failure such as bone graft application, pronounced atrophy of the jaw, and patients with osteoporosis.

The results of our histomorphometric study show that the PRP application in protocol I provided the best effects on the histologic characteristics of the defect fills, and that speaks in favor of the positive impact of growth factor present in the platelets. Further studies should certainly focus on growth factor isolation and their individual application in every particular clinical case.

Numerous studies have already shown that PRP applied in combination with autogenous bone graft increases bone maturation and bone density (Messora et al., 2013; Guerra et al., 2011). The results of PRP applied in combination with a freeze-dried bone allograft in the treatment of atrophy of the alveolar ridge and maxillary sinus augmentation (treatment of peri-implantitis) showed the success of implants placed into treated areas was 89% within the studied 12-month period (Kassolis et al., 2000).

The results of research on stem cells have been recently successfully applied to the field of implantology. This kind of research has been especially performed in Japan. The extent of the importance of a combination of PRP with mesenchymal stem cells has been reported in the treatment of human bone defects in both lower and upper jaws followed by implant placement (Yamada et al., 2004). The combination of PRP mesenchymal stem cells and fibrin could provide excellent results in bone defect regeneration around alveoli during implant placement (Ito et al., 2006). The inserted implant-bone contact 8 months after insertion was 53% in dogs treated with PRP, and 29% in the control dogs (without PRP). It might be speculated that PRP utilized with BDK (not examined in the current study) might be the best combination for optimal bone defect fill procedure, since this procedure would not include BDM, which proved very unfavorable for bone defect fill when used alone. However, our study confirms the effectiveness of using PRP in guided tissue regeneration, both with bovine demineralized membrane, or with the membrane and deproteinized bovine bone.

## **CONCLUSION**

The results of the present study show that the highest degree of dental implant osseointegration is obtained using PRP combined with BDK and BDM. The pathohistological results show more pronounced osteoblastic activity in the protocol with PRP in combination with BDK and BDM. Thus, future studies should be directed to separating specific growth factors from plasma, researching their impact, and defining their optimal concentration in various dental implant placement protocols.

## REFERENCES

- Aghaloo T. L., Moy P. K., Freymiller E. G. 2004. Evaluation of platelet-rich plasma in combination with anorganic bovine bone in the rabbit cranium: a pilot study. *The International Journal of Oral & Maxillofacial Implants*, 19:59–65.
- Aghaloo T. L., Moy P. K., Freymiller E. G. 2002. Investigation of platelet-rich plasma in rabbit cranial defects: A pilot study. *Journal of Oral and Maxillofacial Surgery: Official Journal of the American Association of Oral and Maxillofacial Surgeons*, 60:1176–81. <https://doi.org/10.1053/JOMS.2002.34994>.
- Akimoto K., Becker W., Donath K., Becker B. E., Sanchez R. 1999. Formation of bone around titanium implants placed into zero wall defects: Pilot project using reinforced e-PTFE membrane and autogenous bone grafts. *Clinical Implant Dentistry and Related Research*, 1:98–104. <https://doi.org/10.1111/j.1708-8208.1999.tb00098.x>.
- Anitua E. 1999. Plasma rich in growth factors: preliminary results of use in the preparation of future sites for implants. *The International Journal of Oral & Maxillofacial Implants*, 14:529–35.
- Anusaksathien O., Giannobile W. 2002. Growth factor delivery to re-engineer periodontal tissues. *Current Pharmaceutical Biotechnology*, 3:129–139. <https://doi.org/10.2174/1389201023378391>.
- Becker W., Lynch S. E., Lekholm U., Becker B. E., Caffesse R., Donath K., Sanchez R. 1992. A Comparison of ePTFE membranes alone or in combination with platelet-derived growth factors and insulin-like growth factor-i or demineralized freeze-dried bone in promoting bone formation around immediate extraction socket implants. *Journal of Periodontology*, 63:929–940. <https://doi.org/10.1902/jop.1992.63.11.929>.
- Botticelli D., Berglundh T., Buser D., Lindhe J. 2003. The jumping distance revisited. An experimental study in the dog. *Clinical Oral Implants Research*, 14:35–42. <https://doi.org/10.1034/j.1600-0501.2003.140105.x>.
- Buser D., Bragger U., Lang N. P., Nyman S. 1990. Regeneration and enlargement of jaw bone using guided tissue regeneration. *Clinical Oral Implants Research*, 1:22–32. <https://doi.org/10.1034/j.1600-0501.1990.010104.x>.
- Dahlin C., Lekholm U., Becker W., Becker B., Higuchi K., Callens A., van Steenberghe D. 1995. Treatment of fenestration and dehiscence bone defects around oral implants using the guided tissue regeneration technique: a prospective multicenter study. *The International Journal of Oral & Maxillofacial Implants*, 10:312–8.
- Dahlin C., Lekholm U., Linde A. 1991. Membrane-induced bone augmentation at titanium implants. A report on ten fixtures followed from 1 to 3 years after loading. *The International Journal of Periodontics & Restorative Dentistry*, 11:273–81.
- Froum S. J., Wallace S. S., Tarnow D. P., Cho S.-C. 2002. Effect of platelet-rich plasma on bone growth and osseointegration in human maxillary sinus grafts: three bilateral case reports. *The International Journal of Periodontics & Restorative Dentistry*, 22:45–53.
- Gher M. E., Quintero G., Assad D., Monaco E., Richardson A. C. 1994. Bone grafting and guided bone regeneration for immediate dental implants in humans. *Journal of Periodontology*, 65:881–891. <https://doi.org/10.1902/jop.1994.65.9.881>.
- Guerra I., Morais Branco F., Vasconcelos M., Afonso A., Figueiral H., Zita R. 2011. Evaluation of implant osseointegration with different regeneration techniques in the treatment of bone defects around implants: an experimental study in a rabbit model. *Clinical Oral Implants Research*, 22:314–322. <https://doi.org/10.1111/j.1600-0501.2010.02002.x>.

- Hammerle C. H. F., Lang N. P. 2001. Single stage surgery combining transmucosal implant placement with guided bone regeneration and bioresorbable materials. *Clinical Oral Implants Research*, 12:9–18. <https://doi.org/10.1034/j.1600-0501.2001.012001009.x>.
- Ito K., Yamada Y., Nagasaka T., Baba S., Ueda M. 2005. Osteogenic potential of injectable tissue-engineered bone: A comparison among autogenous bone, bone substitute (Bio-Oss®), platelet-rich plasma, and tissue-engineered bone with respect to their mechanical properties and histological findings. *Journal of Biomedical Materials Research Part A*, 73A:63–72. <https://doi.org/10.1002/jbm.a.30248>.
- Ito K., Yamada Y., Naiki T., Ueda M. 2006. Simultaneous implant placement and bone regeneration around dental implants using tissue-engineered bone with fibrin glue, mesenchymal stem cells and platelet-rich plasma. *Clinical Oral Implants Research*, 17:579–586. <https://doi.org/10.1111/j.1600-0501.2006.01246.x>.
- Jovanovic S. A., Spiekermann H., Richter E. J. 1992. Bone regeneration around titanium dental implants in dehiscence defect sites: a clinical study. *The International journal of oral & maxillofacial implants*, 7:233–45.
- Kassolis J. D., Rosen P. S., Reynolds M. A. 2000. Alveolar ridge and sinus augmentation utilizing platelet-rich plasma in combination with freeze-dried bone allograft: Case series. *Journal of Periodontology*, 71:1654–1661. <https://doi.org/10.1902/jop.2000.71.10.1654>.
- Kohal R.-J., Trejo P. M., Wirsching C., Hurzeler M. B. 1999. Comparison of bioabsorbable and bioinert membranes for guided bone regeneration around non-submerged implants. An experimental study in the mongrel dog. *Clinical Oral Implants Research*, 10:226–237. <https://doi.org/10.1034/j.1600-0501.1999.100306.x>.
- Marx R. E., Carlson E. R., Eichstaedt R. M., Schimmele S. R., Strauss J. E., Georgeff K. R. 1998. Platelet-rich plasma: Growth factor enhancement for bone grafts. *Oral Surgery, Oral Medicine, Oral Pathology, Oral Radiology, and Endodontology*, 85:638–646. [https://doi.org/10.1016/S1079-2104\(98\)90029-4](https://doi.org/10.1016/S1079-2104(98)90029-4).
- Messori M. R., Nagata M. J. H., Pola N. M., de Campos N., Fucini S. E., Furlaneto F. A. C. 2013. Effect of platelet-rich plasma on bone healing of fresh frozen bone allograft in mandibular defects: a histomorphometric study in dogs. *Clinical Oral Implants Research*, 24:1347–1353. <https://doi.org/10.1111/clr.12008>.
- Schilephake H. 2002. Bone growth factors in maxillofacial skeletal reconstruction. *International journal of oral and maxillofacial surgery*, 31:469–84. <https://doi.org/10.1054/IJOM.2002.0244>.
- Sonnleitner D., Huemer P., Sullivan D. Y. 2000. A simplified technique for producing platelet-rich plasma and platelet concentrate for intraoral bone grafting techniques: a technical note. *The International journal of oral & maxillofacial implants*, 15:879–82.
- Stentz W. C., Mealey B. L., Gunsolley J. C., Waldrop T. C. 1997. Effects of guided bone regeneration around commercially pure titanium and hydroxyapatite-coated dental implants. II. Histologic analysis. *Journal of Periodontology*, 68:933–949. <https://doi.org/10.1902/jop.1997.68.10.933>.
- de Vicente J. C., Recio O., Martín-Villa L., Junquera L. M., López-Arranz J. S. 2006. Histomorphometric evaluation of guided bone regeneration around implants with SLA surface: an experimental study in beagle dogs. *International journal of oral and maxillofacial surgery*, 35:1047–53. <https://doi.org/10.1016/j.ijom.2006.06.008>.
- Weibrich G., Kleis W. K. G. 2002. Curasan PRP kit vs. PCCS PRP system. Collection efficiency and platelet counts of two different methods for the preparation of platelet-rich plasma. *Clinical Oral Implants Research*, 13:437–443. <https://doi.org/10.1034/j.1600-0501.2002.130413.x>.

Yamada Y., Ueda M., Hibi H., Nagasaka T. 2004. Translational research for injectable tissue-engineered bone regeneration using mesenchymal stem cells and platelet-rich plasma: from basic research to clinical case study. *Cell Transplantation*, 13:343–356. <https://doi.org/10.3727/000000004783983909>.

## **EFEKAT LOKALNE PRIMENE PLAZME BOGATE TROMBOCITIMA I VOĐENE REGENERACIJE TKIVA NA ZARASTANJE KOSTI KOD RANE UGRADNJE DENTALNIH IMPLANTATA – HISTOMORFOMETRIJSKA ANALIZA**

DUKA Miloš, LAZIĆ Zoran, BUBALO Marija, MIHAILOVIĆ Branko, MILADINOVIĆ Milan, Gvozdic Dragan

### **Kratak sadržaj**

*Uvod.* Potreba da se stvore što bolji uslovi za koštano zarastanje nakon ugradnje implantata poslednjih par godina uticala je na primenu faktora rasta koji direktno ili indirektno regulišu rast ćelija i tkiva. Jednostavnost dobijanja koncentrovanih trombocita izdvojenih iz plazme bogate trombocitima, dovela je do sve šire primene faktora rasta poreklom iz trombocita poput PDGF, TGF- $\beta$ , IGF, VEGF i mnogih drugih, sa ciljem postizanja što većeg procenta kontakta površine implantata sa kosti, što obezbeđuje povećanu stabilnost implantata i brže funkcionalno opterećenje. Cilj rada bio je da se ispita uticaj plazme bogate trombocitima i vođene tkivne regeneracije tkiva u koštanim defektima kod rane ugradnje dentalnih implantata na koštanu regeneraciju.

*Materijal i metode.* Eksperimentalna studija sprovedena je na 10 eksperimentalnih pasa kod kojih je ugrađeno 40 BCT implantata i to po četiri svakom. Eksperiment se sastojao od rane ugradnje implantata na mestima izvađenih premolara. Veštački koštani defekti, nalik periimplantatnim defektima, napravljeni su na mezijalnoj strani svake preparacije. Ti defekti su popunjeni prateći odgovarajuće postupke vodjene tkivne regeneracije, uz korišćenje plazme bogate trombocitima, dobijene iz krvi eksperimentalnih životinja sat vremena pre intervencije. Histopatološke i histomorfometrijske analize rađene su 10 meseci nakon ugradnje implantata.

*Rezultati i zaključak.* Primenjeni protokoli različito utiču na ispunjenost koštanih defekata i koštano zarastanje. Na osnovu dobijenih rezultata došli smo do zaključka da je osifikacija koštanih defekata najveća u protokolu prema kome se primenjuje plazma bogata trombocitima u kombinaciji sa bovinom deproteinizovanom kosti i resorptivnom membranom bovinog porekla.

**Ključne reči:** dentalni implantati, psi, PRP, vođena koštana regeneracija, rana ugradnja implantata