

Case Report

<https://doi.org/10.2298/VETGL190717002S>

SEVERE HEARTWORM DISEASE IN TWO DOGS CURED BY AN ALTERNATIVE THERAPY

SPASOJEVIĆ KOSIĆ Ljubica^{1*}, LALOŠEVIĆ Vesna¹, POTKONJAK Aleksandar¹,
SIMIN Stanislav¹, KURUCA Ljiljana¹, VRAČAR Vuk¹

¹University of Novi Sad, Faculty of Agriculture, Department of Veterinary Medicine, Novi Sad, Serbia

Received 17 July 2019; Accepted 13 January 2020

Published online: 21 February 2020

Copyright © 2020 Spasojević Kosić et al. This is an open-access article distributed under the Creative Commons Attribution License, which permits unrestricted use, distribution, and reproduction in any medium, provided the original work is properly cited

How to cite: Spasojević Kosić Ljubica, Lalošević Vesna, Potkonjak Aleksandar, Simin Stanislav, Kuruca Ljiljana, Vračar Vuk. Severe heartworm disease in two dogs cured by an alternative therapy. *Veterinarski Glasnik*, 2020. 74 (2), 202-210. <https://doi.org/10.2298/VETGL190717002S>

Abstract

The objective of this paper is to describe two cases of heartworm disease in dogs presented with ascites and dyspnea. A diagnosis of mixed infection with both *Dirofilaria immitis* (*D. immitis*) and *Dirofilaria repens* (*D. repens*) was established in the first case, while *D. immitis* was detected in the other dog. Based on clinical, parasitological, laboratory and radiographic examinations, the diagnosis of severe stage heartworm disease (HWD) was established because both dogs were in heart failure due to HWD. An alternative therapeutic protocol with combined doxycycline and ivermectin was used as an antiparasitic treatment in both cases. No microfilariae were detected after 30 and 60 days, and no antigen to *D. immitis* was detected after 8 and 12 months in the first and second case, respectively. Based on the clinical examinations and parasitological testing performed, the two dogs were considered cured of HWD by this alternative therapy.

Key Words: alternative therapy, heartworm, heart failure

CASE PRESENTATION

The first case (dog 1) was a 4-year-old male Staffordshire terrier who presented with dyspnea and ascites of three days' duration. The owner disclaimed any previous problems, only sporadic coughing. The dog had a normal temperature, shallow

*Corresponding author – e-mail: ljubica.spasojevic@gmail.com, ljubicask@polj.uns.ac.rs

respirations, and both respiratory and heart rates were increased. Harsh breath sounds were audible, with crackles and wheezes heard in the dorsal and cranial parts of the lung field. Normal heart sounds (S1, S2) with no murmurs or arrhythmia were heard on cardiac auscultation. Abdominal ballottement revealed the existence of free fluid.

The second case (dog 2) was a 4-year-old male Cane Corso, scheduled for examination because of a history of several weeks of coughing, syncope and fatigue. Upon clinical examination, the temperature was normal, but respirations were shallow and the pulse was weak. Harsh respiratory sounds were heard in the cranial lung field. Cardiac auscultation revealed S1 and S2 sounds, without heart murmurs, and prominent respiratory arrhythmia. Abdominal ballottement confirmed the existence of free fluid. In addition, subcutaneous edema existed, particularly in the cervical and thoracic areas.

In both cases, venous blood was taken for hematological, biochemical and parasitological examinations. Also, chest radiographic examinations in two projections were recorded (Fig. 2, 3, 4a, b). Blood analyses revealed the presence of anemia, microcytosis, hypochromemia, hypoproteinemia and hypoalbuminemia in both dogs, mildly increased urea nitrogen and potassium in dog 1, and mild leukocytosis and neutrophilia, eosinophilia, azotemia and increased total bilirubin in dog 2 (Table 1). Low antigen levels towards *D. immitis* were detected in both dogs (SNAP Heartworm RT Test, Idexx Laboratories). Microfilariae of both *D. immitis* and *D. repens* were detected in the first dog's blood (Fig. 1), while microfilariae of *D. immitis* were detected in the second dog by a modified Knott test (Genchi et al., 2007; Bazzocchi et al., 2008). Based on results of the performed examinations, a diagnosis of heart failure due to HWD, and thus, severe stage HWD (stage 3) was established in both cases (Kittleson, 1998; Ware, 2011; American Heartworm Society, 2018), with subclinical *D. repens* infection in the first dog.

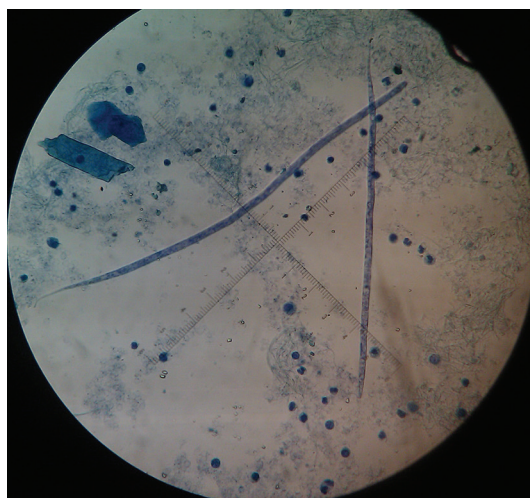


Figure 1. *D. immitis* and *D. repens* microfilariae in a blood sample from dog 1

Table 1. Selected parameters of complete blood counts and chemistry analyses in the dogs at the moment of HWD diagnosis

Hematological parameters	Dog 1	Dog 2	Biochemical parameters	Dog 1	Dog 2
Red blood cells ($\times 10^{12}/L$)	4.86	4.2	Albumin (g/L)	28.0	20.2
Hemoglobin (g/L)	107	91.0	Globulin (g/L)	21.0	26.7
White blood cell ($\times 10^9/L$)	12.94	19.4	Total protein (g/L)	49.0	47.2
Neutrophils ($\times 10^9/L$)	9.60	12.3	Blood urea nitrogen (mmol/L)	11.7	11.0
Eosinophils ($\times 10^9/L$)	0.38	1.9	Creatinine ($\mu\text{mol}/L$)	94.4	106.7
PCV (%)	29.1	28.5	AST (IU/L)	45.3	39.4
MCV (fL)	59.8	68.4	ALT (IU/L)	33.0	20.9
MCH (pg)	22.0	21.9	Bilirubin ($\mu\text{mol}/L$)	2.9	12.4
MCHC (g/dL)	36.8	32.0	Sodium (mmol/L)	151.2	142.5
Red cell width (%)	16.6	16.7	Potassium (mmol/L)	6.6	5.5
Platelets ($\times 10^9/L$)	172.0	297.0	Calcium (mmol/L)	2.6	2.5
Mean platelet volume (fL)	10.3	12.3	Phosphorus (mmol/L)	1.2	1.5

Legend: PCV – Pack cell volume; MCH – Mean corpuscular hemoglobin; MCHC – Mean corpuscular hemoglobin concentration; AST – Aspartate aminotransferase; ALT – Alanine aminotransferase.

Primarily, the first patient was stabilized with furosemide (Lasix[®], Sanofi) 3 mg/kg b.w. perorally, TID, aminophylline (Aminofilin, Hemofarm AD) 4 mg/kg b.w. perorally, TID, and prednisone (Prednizon, Bosnalijek) 0.5 mg/kg b.w. perorally, SID. In the first week, the dog's breathing was much better and abdominal distension was decreased. Hence, the therapy was adjusted (furosemide 2 mg/kg b.w. perorally, BID or TID, as needed, aminophylline 4 mg/kg b.w. perorally, TID, and prednisone 0.5mg/kg b.w. perorally, every other day) and added to with enalapril (Enalapril, Zdravlje Actavis) 0.5 mg/kg b.w. perorally, SID. At that time, we started the alternative therapy for HWD. In order to reduce the cardiac congestion in the second dog we used only furosemide (Lasix[®], Sanofi) 2 mg/kg b.w. perorally, BID or TID, and upon stabilization of the patient, the therapeutic protocol for HWD was started. The dog's condition started to improve, and on control examination he was bright and alert with a good appetite.

The therapeutic protocol for HWD in both cases consisted of doxycycline (Doksiciklin, Hemofarm AD) 10 mg/kg b.w. perorally, SID for six weeks, then alternately four weeks without and two weeks with the medication, and ivermectin (Ivermectin, Veterinarski zavod Subotica) 6-14 $\mu\text{g}/\text{kg}$ b.w. perorally every two weeks, until negative results were reported for antigenemia, but not longer than nine months. Also, the owners were advised not to subject the dogs to physical activity and to implement a cardiac diet.

As the dogs' clinical conditions improved, the dosage of furosemide was gradually decreased, and in the case of the first dog, prednisone was ceased after three weeks. After three months there were no ascites in either dog, although they had occasional

sporadic coughing, and the only drugs prescribed were doxycycline and ivermectin. No adverse effects of doxycycline and ivermectin were registered in either case. Therapy with doxycycline and ivermectin was ceased after nine months. One year after diagnosis, parasitological examination did not detect any microfilariae or antigen to *D. immitis* in either dog. At that time, control radiographic examination was performed in dog 2 (Fig. 4c, d). After therapy, the prophylactic treatment (Advocate[®], Bayer) was recommended to the owners in both cases.

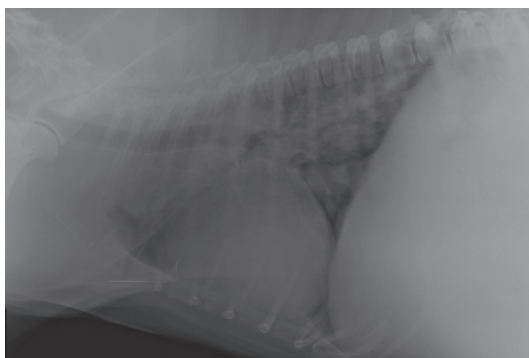


Figure 2. Lateral thoracic radiograph (dog 1) shows consolidations in the part of the cranial and middle lung lobe, the vascular pattern in the caudodorsal area of the lung field, and trachea converging to the spine.

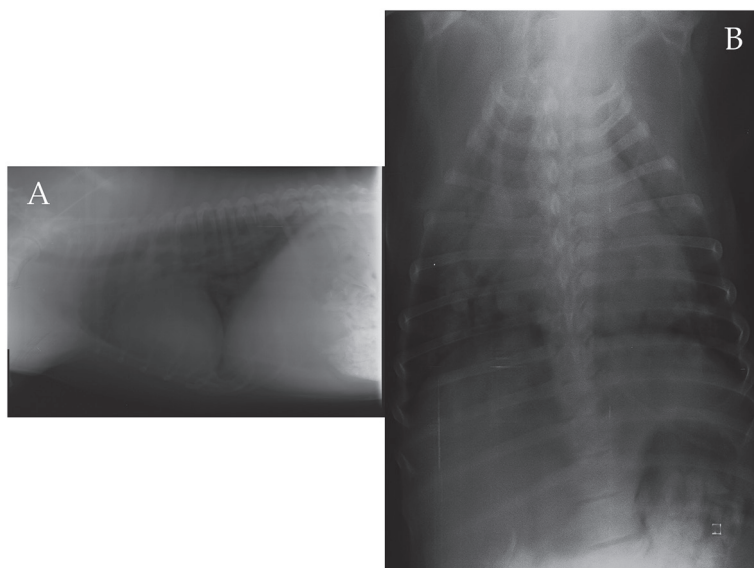


Figure 3. Lateral (a) and dorsoventral (b) thoracic radiographs (dog 1) taken one month after the beginning of therapy. The cranial heart border, increased lucency of lung field and loss of margination of caudal pulmonary vessels are seen on lateral view. There is an area of increased opacity in the cranial lung lobe, vascular pattern of caudal pulmonary vessels, and the reverse D-shape of the cardiac outline on dorsoventral view.

Table 2. Microfilaremia and antigenemia in the dogs during the alternative therapy for heartworm disease

Days	Dog 1			Dog 2	
	<i>D. immitis</i> (mf/ml)	<i>D. repens</i> (mf/ml)	Ag <i>D. immitis</i>	<i>D. immitis</i> (mf/ml)	Ag <i>D. immitis</i>
0	2400	160	+	1920	+
30	0	0	+	340	+
60	0	0	+	0	+
90	0	0	+	0	++
120	0	0	+	0	+
150	0	0	+	0	+
180	0	0	+	0	+
210	0	0	+	0	+
240	0	0	-	0	++
270	0	0	+	0	++
360	0	0	-	0	-

Legend: mf/ml microfilariae per mililiter, Ag antigen, + antigen detected, - no antigen detected

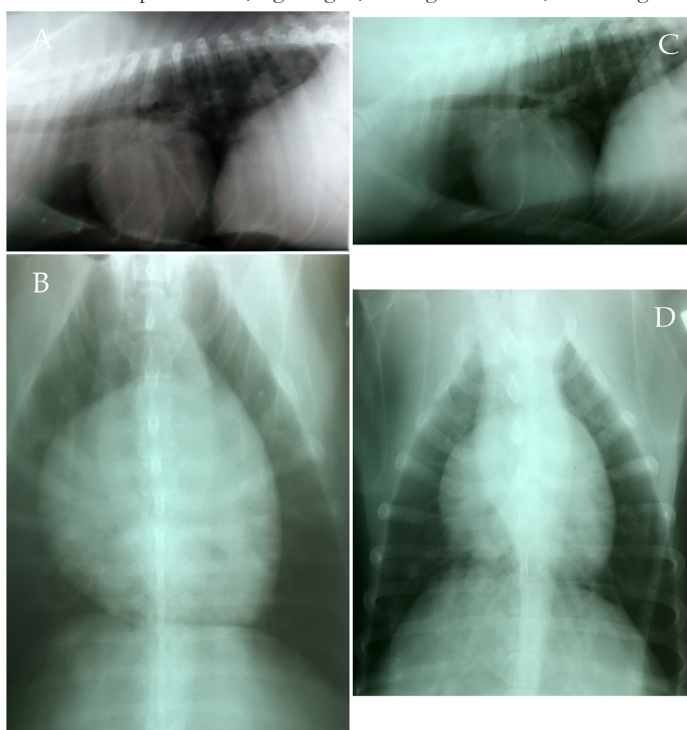


Figure 4. Lateral (a and c) and dorsoventral (b and d) thoracic radiographs of dog 2 taken at the moment of diagnosis (a, b) and one year later (c, d). The consolidation in the cranial lung lobe and the alveolar pattern that presented at the beginning was resolved. There is right-sided cardiomegaly.

DISCUSSION

Most commonly, HWD is a chronic infection manifested as chronic cough, although it can cause serious pathological alterations (pulmonary artery damage, pulmonary thromboembolism, cor pulmonale, right-sided congestive heart failure, caval syndrome, reactive polyarthritis and glomerulonephritis) (Kittleson, 1998; Ware, 2011).

The goals of heartworm treatment are to improve the clinical condition of an animal and to eliminate all life stages of heartworms with minimal post-treatment complications. Melarsomine dihydrochloride is the only effective drug available for treating adult heartworm infections (ESCCAP 2012; American Heartworm Society, 2018). Standard treatment based on the usage of melarsomine and prednisone commences with macrocyclic lactones and doxycycline. Alternatively, the use of a monthly oral ivermectin or topical moxidectin heartworm preventive with doxycycline at 10 mg/kg BID for a 4-week period might be considered as a salvage procedure. Continuous monthly administration of prophylactic doses of any macrocyclic lactone alone up to two years is a possible but not recommended alternative therapy for HWD (American Heartworm Society, 2018). Thus, when melarsomine is unavailable, contraindicated or declined by an owner due to its high cost or potential side effects, the clinician is faced with a challenge, particularly in cases with severe heartworm disease or concurrent disease. Although therapy for severe HWD in these dogs was alternative, using doxycycline and ivermectin, this protocol achieved the therapy goals. The clinical condition of both patients improved. Based on parasitological examination, the adult parasites and microfilariae were eliminated (Table 2), and there were no clinical complications during the therapeutic protocols.

In spite of the reported prevalence of canine dirofilariasis in Serbia (Spasojević Kosić et al., 2016), there is no approved drug indicated for treatment of HWD. Therefore, alternative therapy for HWD in dogs, consisting of either doxycycline and ivermectin or doxycycline and moxidectin, is widely used in Serbia. Doxycycline reduces infection of the bacterial endosymbiont *Wolbachia* in all stages of heartworms, and *Wolbachia* has been shown to be essential for worm development, fecundity and survival, as well as for the pathogenesis of filarial disease (Bazzocchi et al., 2003; Kramer et al., 2005; Bouchery et al., 2013). The presence of *Wolbachia* spp. has also been detected in dogs naturally infected with *Dirofilaria* spp. in dogs in Serbia (Kosic et al., 2018).

Although the level of detected *D. immitis* antigen was low, the clinical signs of dyspnea and ascites, present in both dogs, indicated right heart failure. The prognosis for patients with severe HWD is generally not good, due to the high risk of pulmonary thromboembolism during adulticide treatment. At the beginning of the treatment, we had to use additional drugs in order to treat heart failure. Kittleson (1998) observed that dogs with right heart failure that are successfully treated with an adulticide treatment generally improve clinically within two to three months, to the point that they no longer require diuretic administration to control their heart failure. The same happened in our cases.

We decided to use the presented antiparasitic protocol according to the result of therapy with doxycycline and ivermectin in experimentally infected dogs (Bazzocchi et al., 2008). In that study, the adulticide effect of doxycycline and ivermectin was 78.26%, histology revealed complete loss of uterine content in female worms, and immunohistochemistry for *Wolbachia* was negative.

Our combined doxycycline-ivermectin treatment was microfilaricidal and adulticidal in the presented cases. The transient increase in antigenemia during the treatment was probably a consequence of antigen release due to female worm death. According to previous studies, 100% of dogs infected with *D. immitis* became negative for circulating microfilariae within 90 days (Grandi et al., 2010; Spasojević Kosić et al., 2014). When the same protocol was used in dogs naturally infected with *D. immitis*, no antigen of *D. immitis* was detected after two to nine months in 63.64% (Spasojević Kosić et al., 2014) to 76% (unpublished data) of the dogs. A different doxycycline-ivermectin protocol has shown an effectiveness of 72.7% after 300 days (Grandi et al., 2010). Doxycycline used in combination with imidacloprid and moxidectin has shown 95.9% efficacy in eliminating adult heartworm in experimentally infected dogs (Savadelis et al., 2017). However, there are no studies that compare different alternative protocols in either naturally or experimentally infected dogs.

Concerning *D. repens* infection, our treatment was effective by clearing microfilariaemia in the dog after 30 days. The efficacy of doxycycline and ivermectin has been preliminarily reported in two dogs naturally infected with *D. repens* (Giannelli et al., 2013).

In order to diagnose HWD in these dogs, the minimum required diagnostic procedures were used (clinical, parasitological, laboratory and radiographic examinations). Diagnostic procedures such as echocardiographic examination and measurement of cardiopulmonary biomarkers were not performed due to disinterest of the owners. However, these procedures could be very important for estimation of heart failure, pulmonary hypertension and thromboembolism, and thus, for proper patient prognosis.

In conclusion, combined doxycycline and ivermectin is a possible therapeutic protocol even for severe HWD in dogs. Right heart failure, if present, should be treated at the same time using drugs indicated for this condition. A successful HWD therapy resolves heart failure. The dogs completely recovered clinically, and are considered cured of HWD by this alternative therapy.

Acknowledgements

This study was supported by grants provided by the Ministry of Education and Science Republic of Serbia (project TR 31084) and the Provincial Secretariat for Higher Education and Scientific Research, Autonomous Province of Vojvodina, Republic of Serbia (Grant numbers: 142-451-2803/2018-01/02).

Author contribution

SKLj performed all clinical examinations and diagnosis, antigen detections and treatment of the dogs, wrote the manuscript; LV performed parasitological examinations for microfilariae (Knott test) during the time period of dogs' observation; PA wrote the manuscript together with SKLj; SS performed parasitological examinations for microfilariae (Knott test) during the time period of dogs' observation, designed and formatted the figures of the manuscript; KLj performed parasitological examinations for microfilariae (Knott test) during the time period of dogs' observation; VV designed and formatted the figures of the manuscript.

Competing interest

The authors declare that they have no competing interests.

REFERENCES

- American Heartworm Society 2018. Current canine guidelines for the prevention, diagnosis and management of heartworm (*Dirofilaria immitis*) infection in dogs <https://d3ft8sckhnqm2.cloudfront.net/images/pdf/2018-AHS-Canine-Guidelines-181114.pdf?1542248135>
- Bazzocchi C., Genchi C., Paltrinieri S., Lecchi C., Mortarino M., Bandi C. 2003. Immunological role of the endosymbionts of *Dirofilaria immitis*: the *Wolbachia* surface protein activates canine neutrophils with production of IL-8. *Veterinary Parasitology*, 117(1-2):73-83. <https://doi.org/10.1016/j.vetpar.2003.07.013>.
- Bazzocchi C., Mortarino M., Grandi G., Kramer L.H., Genchi C., Bandi C., Genchi M., Sachhi L., McCall J.W. 2008. Combined ivermectin and doxycycline treatment has microfilaricidal and adulticidal activity against *Dirofilaria immitis* in experimentally infected dogs. *International Journal of Parasitology*, 38:1401-1410. <https://doi.org/10.1016/j.ijpara.2008.03.002>.
- Bouchery T., Lefoulon E., Karadjian G., Nieguitsila A., Martin C. 2013. The symbiotic role of *Wolbachia* in Onchocercidae and its impact on filariasis. *Clinical Microbiology and Infection*, 19:131-140. <https://doi.org/10.1111/1469-0691.12069>.
- ESCCAP, 2012. Control of vector-borne diseases in dogs and cats, <http://www.esccap.org/page/G5+Control+of+VectorBorne+Diseases+in+Dogs+and+Cats/29/#.VFNY8vnF98E>
- Genchi G., Venco L., Genchi M. 2007. Guideline for the laboratory diagnosis of canine and feline *Dirofilaria* infections. In: *Mappe Parasitologiche 8*. Naples, Veterinary Parasitology and Parasitic Diseases, pp 137-145.
- Giannelli A., Antonio R., Ramos N., Traversa D., Brianti E., Annoscia G., Bastelli F., Dantas-Torres F., Otranto D. 2013. Treatment of *Dirofilaria repens* microfilariaemia with combination of doxycycline hyclate and ivermectin. *Veterinary Parasitology*, 197(3-4):702-704. <https://doi.org/10.1016/j.vetpar.2013.05.012>.
- Grandi G., Quintavalla C., Mavropoulou A., Genchi M., Gnudi G., Bertoni G., Kramer L.A. 2010. Combination of doxycycline and ivermectin is adulticidal in dogs with naturally acquired heartworm disease (*Dirofilaria immitis*). *Veterinary Parasitology*, 169(3-4):347-351. <https://doi.org/10.1016/j.vetpar.2010.01.025>.
- Kittleson, M.D. 1998. Heartworm infestation and disease (dirofilariasis). In: *Small Animal Cardiovascular Medicine*. St. Louis: Mosby.

- Kosic L.S., Potkonjak A., Vidanovic D., Kozoderovic G., Vracar V., Lalošević V. (2018). The first report of *Wolbachia* spp. in dogs naturally infected with *Dirofilaria* spp. in Serbia – preliminary results. *Parasite & Vectors*, 11(Suppl 1):623.
- Kramer L., Simon F., Tamarozzi F., Genchi M., Bazzocchi C. 2005. Is *Wolbachia* complicating the pathological effects of *Dirofilaria immitis* infections? *Veterinary Parasitology*, 133(2-3):133-136. <https://doi.org/10.1016/j.vetpar.2005.04.011>.
- Savadelis M.D., Ohmes C.M., Hostetler J.A., Settje T.L., Zolynas R., Dzimiński M.T., Moorhead A.R. 2017. Assessment of parasitological findings in heartworm-infected beagles treated with Advantage Multi® for dogs (10% imidacloprid + 2.5% moxidectin) and doxycycline. *Parasite & Vectors*, 10:245, <https://doi.org/10.1186/s13071-017-2190-9>.
- Spasojević Kosić Lj., Lalošević V., Simin S., Kuruca Lj., Naglič A., Vasić I. 2014. Microfilaraemia and antigenemia in dogs with natural heartworm infection treated with combination of doxycycline and ivermectin-preliminary results. In: *Proceedings of the 4th European Dirofilaria and Angiostrongylus Days*, Budapest, Hungary, 62.
- Spasojević Kosić Lj., Lalošević V., Simin S., Kuruca Lj. 2016. Dirofilariosis and angiostrongylosis in pet and hunting dogs in Novi Sad, Vojvodina, Serbia. *Archives of Veterinary Medicine*, 9(2):53-62.
- Ware, W. 2011. Heartworm disease. In: *Cardiovascular Disease in Small Animal Medicine*. London: Manson Publishing/The Veterinary Press.

OZBILJAN STADIJUM BOLESTI IZAZVANE SRČANIM CRVOM KOD DVA PSA IZLEČENA ALTERNATIVNOM TERAPIJOM

SPASOJEVIĆ KOSIĆ Ljubica, LALOŠEVIĆ Vesna, POTKONJAK Aleksandar, SIMIN Stanislav, KURUCA Ljiljana, VRAČAR Vuk

Kratak sadržaj

Cilj ovog rada je da opiše dva klinička slučaja bolesti izazvane srčanim crvom kod pasa koji su ispoljavali simptome ascitesa i dispnoje. Dijagnoza mešane infekcije sa *Dirofilaria immitis* (*D. immitis*) i *Dirofilaria repens* (*D. repens*) je ustanovljena kod prvog slučaja, dok je kod drugog psa detektovana infekcija sa *D. immitis*. Na osnovu kliničkih, parazitoloških, laboratorijskih i radiografskih pregleda, oba psa su svrstana u ozbiljni stadijum bolesti izazvane srčanim crvom, jer su imala srčanu slabost. Alternativni protokol lečenja koji se sastojao od korišćenja kombinacije doksiciklina i ivermektina je korišćen u oba slučaja kao antiparazitski tretman. Nakon 30 dana u prvom slučaju, odnosno 60 dana u drugom slučaju mikrofilarije nisu otkrivene, dok antigen *D. immitis* nije detektovan nakon 8 meseci u prvom, odnosno nakon 12 meseci u drugom slučaju. Na osnovu kliničkih pregleda i parazitoloških ispitivanja utvrđeno je da su psi izlečeni od bolesti izazvane srčanim crvom korišćenjem alternativne terapije.

Ključne reči: alternativna terapija, srčani crv, srčana slabost