

DOI: 10.2478/afmnai-2014-0033

Scientific Journal of the Faculty of Medicine in Niš 2014;31(4):267-271

Case report ■

Osteomalacia or Osteoporosis - Case Report

Nela Živković, Sonja Stojanović

Institute for Treatment and Rehabilitation «Niška Banja», Serbia

SUMMARY

The aim of the paper was to show the diagnostic and therapeutic approaches to a patient suffering from osteomalacia, as well as differential diagnosis with osteoporosis.

Osteomalacia (OM) is a metabolic disease of bones which appears as a result of defective mineralization of newly formed bone matrix in adults. Diagnosis of disease may represent a big problem. A 67-year-old female patient from Pirot was examined in an outpatient unit by a rheumatologist in the Niška Banja Institute in December 2012. The patient reported pain along the vertebral column and inability to get out of bed. Radiography showed vertebral compression fractures and the patient had previously received surgical care at Orthopedics Ward of General Hospital Pirot due to the left femur fracture. Orthopedist, neurologist, physiatrist and practicing rheumatologist suspected osteoporosis. The diagnosis of osteomalacia was established in February, 2013. The treatment was initiated by introducing large doses of vitamin D and advising bisphosphonates. After eighth months, the patient's general condition was improved. This was demonstrated by her independent mobility.

Key words: osteomalacia, osteoporosis, diagnosis, treatment

Corresponding author:

Nela Živković •

phone: +381 63 88 54 566 •

e-mail: nelinazivkovic@gmail.com •

INTRODUCTION

Osteomalacia (OM) is a metabolic disease of bones, which appears as a result of defective mineralization of newly formed bone matrix in adults (1). The disease appears due to the lack of one of mineralization relevant factors and is thus divided into:

- Osteomalacia caused by vitamin D deficiency
- Osteomalacia in renal tubular acidosis type 1 (proximal)
- Osteomalacia in hypophosphatasia
- Osteomalacia in congenital disorders of bone metabolism
- Iatrogenic osteomalacia (2).

According to the definition of the World Health Organization, osteoporosis (OP) is a disease characterized by low bone mass and microarchitectural deterioration, which results in increased fragility of bones and risk of bone fractures (3). With regard to the cause, osteoporosis can be primary, secondary and congenital.

Differential diagnostic overview of the two diseases may represent a big problem. Both diseases are frequently asymptomatic, and OP is first suspected when patients experience height loss, strong back pain or walk hunched over. Contrary to OP, OM is characterized by typical proximal limb muscle weakness, followed by hypotony, hypotrophy and characteristic walk.

Laboratory analysis may be much more significant than clinical examination. In OP, laboratory results are mostly normal, while in OM different changes of the bone metabolism are verified: activity of alkaline phosphates (ALP) is increased, serum Calcium (Ca) is lower, serum Phosphorus is lower, Ca in urine is usually lower, and P in urine is higher (4). In OM, values of the parathyroid hormone (PTH) are elevated along with lower level of vitamin D (5).

Radiography results may be similar, as both OM and OP show compressive fractures in late stage of the diseases (6). Specific radiology change related to OM is pseudofracture, or Looser's zone (7). Additionally, osteodensitometry cannot offer significant help in differential diagnosis of these diseases as T score lower than 2,5 can be verified in OP as well as in OM (8). However, differential diagnosis of osteomalacia and osteoporosis is based on detailed medical history, physical examination, laboratory results, radiology and osteodensitometry findings.

Therapeutic approach to patients suffering from these two diseases is different. OP treatment aims at eliminating the risk factors, supplementing vitamin D and Ca and initiating antiresorptive therapy (9). The final goal of osteoporosis treatment is reducing the fracture risk, which is, among other things, achieved by bisphosphonates, antiresorptive drugs that represent the so called "gold standard" for treating osteoporosis (10). On the other hand, the treatment of osteomalacia focuses on

the cause of metabolic disorder (supplementation of vitamin D, treating kidney disorders, etc).

Similarities in clinical, laboratory, radiography and osteodensitometry overview of the two diseases often cause differential diagnostic dilemma during the procedure of examining patients in specialized outpatient units. Therefore, we have decided to present a case of the patient suffering from osteomalacia and point out the difficulties during the procedures of diagnosing and initiating the treatment.

CASE REPORT

A 67-year-old female patient from Pirot was examined in an outpatient unit by a rheumatologist in the Niška Banja Institute on December 5th 2012. The patient reported pain along the vertebral column and inability to get out of bed.

In July 2012, the patient received surgical care at Orthopedics Ward of General Hospital Pirot due to the left femur fracture (Figure 1). Medical history showed that pain along vertebral column and inability to get up and walk started in November 2012. On November 14th, the patient was examined by orthopedist. Diagnosis was: St. post fracturam transtrohantericam femoris lat. sin, Osteoporosis, Polydiscopathialumbalis and the patient was advised analgesic treatment. The same month, the patient was examined by neurologist who advised Ketoprofen and Tolperisone treatment for 10 days and relieving corset for three weeks. The prescribed analgesic treatment did not alleviate the problems. Neurologist required Rtg and MSCT LS of the spinal part. On November 29th 2012, radiography showed vertebral compression fractures (Figure 2), MSCT L-S also showed vertebral compression fractures, degenerative disk disease and facet joints.

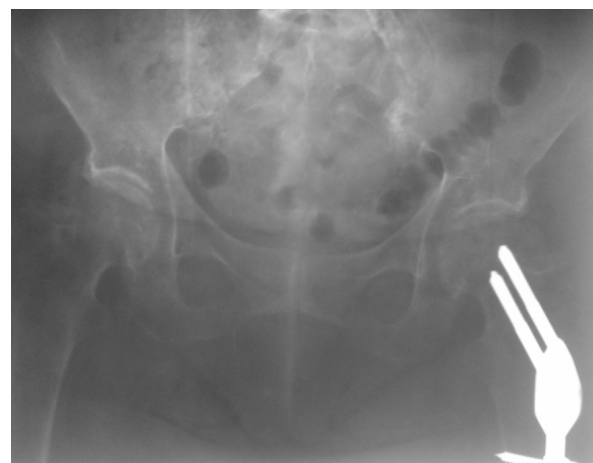


Figure 1. X-ray of pelvis and hips with implanted osteosynthesis material after left femoral fracture

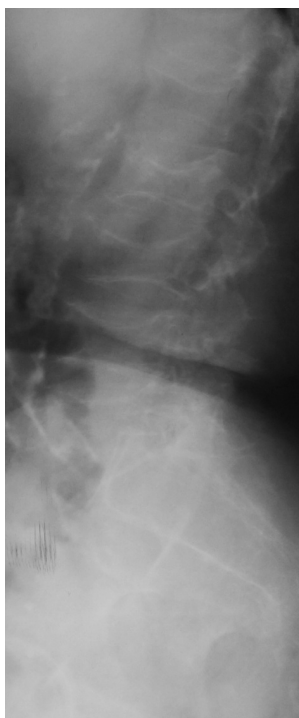

Figure 2. X-ray of lumbosacral spine with vertebral body compressive fracture

The physiatrist from the patient's place of residence asked the rheumatologist's opinion, due to suspected presence of OP.

On December 5th 2012, when the patient visited rheumatologist, bone densitometry showed significantly lower bone density of LS spine, BMD=0.497g/cm², T-score=-5, 0 as well as of left collifemoris BMD 0.415 g/cm², T-score=-4, 1. The patient was advised to test the level of Calcium (Ca), Phosphorus (P), Vitamin D, alkaline phosphatase (ALP) in serum and Acid phosphatase, Ca and P in 24 h urine.

Biochemical analysis recorded a lower value of vitamin D of 3,7 ng/mL (reference values: insufficient <10, deficient 10-30, optimal 30-100 ng/mL), low value of Ca in serum 1, 7 mol/L (2, 0-2,6 mmol/L), high value of alkaline phosphatase 274 U/L (50-136 U/L). Values of P in serum, Ca and P in urine, as well as Ca and P in 24h urine were within the limits of normal values.

On January 15th 2013, during the medical check-up, the rheumatologist of Niška Banja Institute diagnosed Osteoporosis cum fractura pathologica, but due to the increased level of ALP, the rheumatologist suspected OM and requested testing the parathyroid hormone (PTH) in serum.

On January 23th 2013, laboratory analysis demonstrated discretely high value of PTH: 76pg/ml (14-75 pg/ml). The results of the laboratory analysis also showed normal values of kidney function as well as preserved liver function. The patient did not show any other comorbidity (most importantly digestive problems, malabsorption syndrome was ruled out), nor did she take any drug which affects bone metabolism.

Having in mind the clinical symptoms and laboratory parameters, we concluded that the patient suffered from osteomalacia as a consequence of vitamin D deficiency and the treatment was started in that direction.

Next rheumatology checkup was on February 3rd 2013. Diagnosis was: Osteomalatio, Hyperparathyroidismus sec. and the doctor advised Holecalfiferol drops in the following order: I week 50 drops per week, II week without vitamin D, III week 50 drops per week, IV week without vitamin D. During the first month the patient was taking approximately 2500 IU of vitamin D per day. After that, the dose of vitamin D was reduced to 21 drops per week which equaled 2000IU of vitamin D per day. At the end of May 2013, both general condition of the patient and laboratory analysis were significantly improved. Laboratory analysis showed normal values of Ca and P in serum and urine, and still a higher value of ALP of 265 U/L, but this value was lower compared to that of the previous results (274 U/L). High dose of vitamin D substitution was continued, as well as Holecalfiferol 21 drops per week, and an Ibandronic acid treatment of 150 mg per month was advised. All the time, the patient was taking 500 mg of Ca per day.

Laboratory analysis performed on July 18th 2013, showed the following: Ca in serum 2,4 mmol/L, P in serum 1,1 mmol/L, ALP 134(do 136 U/L), Ca in urine 3,2 mmol/L, P in urine 10,4 mmol/L, vitamin D 24 ng/ml. The normalization of the values of ALP along with the elevation of the serum level 25(OH) D was noted. The previously prescribed treatment was continued.

After eight months, the patient had a check up. She was active and mobile, and her laboratory analysis indicated ALP 129 (50-136 U/L), normal levels of Ca and P in serum and in 24h urine, normal values of PTH 73,6 (14-75 pg/mL), as well as deficiency in vitamin D 25(OH)D 27 ng/mL. The treatment with Holecalfiferol was continued - 15 drops per week (on approximately 1200 IU of vitamin D per day), with Ibandronat- 150 mg per moth, and tbl of Ca, 500 mg per day. Further analysis of Ca, P, ALP in the blood and Ca and P in 24h urine was advised every two or three months.

In March 2014, during the last medical check-up, normal values of ALP, Ca and P in serum and of Ca and P in urine were registered. The level of serum 25 (OH)D was significantly increased, but was still within the limits of deficit (29 ng/ml being border, but closer to the normal level of vitamin D), which was why a high dose of vitamin D substitution was continued (20 drops per week).

DISCUSSION

During the presentation of the symptoms such as inability to move or get out of bed, osteomalacia is one of the less likely possible diagnoses. Even though literature shows that diagnosing the disease is rather simple, practice proves the opposite. The case of this patient shows that neurologist and orthopedist observation was

focused on osteoporosis, as compression fractures commonly accompany this disease. Additionally, osteodensitometry result, with low T score -5, pointed to OP. Even after the first rheumatologist's examination, the patient was monitored as if suffering from potential OP. After registering high values of PTH and verifying previously low values of vitamin D, hypocalcemia and high ALP values, the patient was diagnosed with osteomalacia.

In this case, laboratory parameters were crucial in diagnosing osteomalacia. Radiology and osteodensitometry diagnostics is usually non-specific for this disease. We were not been able to diagnose the presence of Looser's zones which are most readily seen on the collie femoris, and are a possible substrate for transtrochanteric fracture of the collie femoris, because the patient visited the rheumatologist after having received surgical care (hip endoprosthesis replacement where the previous radiography was not available). In order to make a definite diagnosis of osteomalacia it is necessary to do a bone biopsy using histomorphometrical techniques with the help of double tetracycline labeling (11). In this case, there was no a technological possibility for this kind of diagnostics.

Holecalciferol (1000 to 2000 IU per day or in the case of malabsorption, high dose of vitamin D, 50000 IU one to three times a week) with the addition of Ca, 1 to 2g per day (1, 12) is used for treating all forms of osteomalacia. In the case of the presented patient the dose of vitamin D was a bit higher than recommended, due to the significantly low starting value - 25(OH) D in serum. By giving high doses of vitamin D to the patient, in a relatively short period of 8 months, a positive thera-

peutic effect was achieved together with normalization of the parameter value of the bone metabolism and the correction of vitamin D deficiency. Is advising bisphosphonates to this patient justified? Based on the available documentation and performed diagnostics, we believe that osteomalacia, from which this patient suffers, has been caused by the vitamin D deficiency. Due to the significantly lower bone mineral density, after the normalization of the parameters of bone metabolism, we started a treatment with monthly bisphosphonates and started monitoring the patient more often, both in clinical and laboratory conditions. After a year of antiresorptive therapy, along with high doses of vitamin D and Ca supplementation, together with clinical improvement, we also verified an increase in bone mineral density of LS spine. (December 5, 2013, L1-L4 BMD=0.494 g/cm², T score=-5.0; March 19, 2014, BMD=0.599 g/cm², T score=-4.1). On the collie femoris, without any significant change in the bone mineral density (December 5th 2012 BMD=0.415 g/cm², T score=-4.3; March 19th 2014, BMD=0.428 g/cm², T score=-4.2).

CONCLUSION

To sum up, osteoporosis and many other possible causes are to be considered in cases of patients with x-ray verified compressive fracture of vertebral area. Detailed overview of clinical, x-ray, laboratory and densitometry results may reveal osteomalacia as another possible cause of the spontaneous fracture occurrences.

References

1. Delaney ME. Metabolic bone disease. U: Kelley textbook of rheumatology, 5thed. Ruddy Harris ED Jr, Sledge CB(eds), WB Saunders, Philadelphia, 2001; pp, 1635-52.
2. Prince LR and Glendenning P. Disorders of bone mineral other than osteoporosis. Clin Endocrinol Oxf 2004; 354-9.
3. Geusens PP, van Brussel MS, Lems BS. Osteoporosis and fracture risk: pathogenesis, epidemiology, clinical aspects and diagnosis. In: EULAR Compendium on Rheumatic Diseases, Edited by JWJ Bijlsma 2009.
4. Lee J, Vasikaran S. Current recommendations for laboratory testing and use of bone turnover markers in management of osteoporosis. Ann Lab Med 2012; 32: 105-12.
<http://dx.doi.org/10.3343/alm.2012.32.2.105>
5. Bellido T, Saini V, Pajević P. Effects of PTH on osteocyte function. Bone 2013; 54(2): 250-7.
<http://dx.doi.org/10.1016/j.bone.2012.09.016>
6. Guglielmi G, Muscarella S, Bazzocchi A. Integrated imaging approach to osteoporosis: state-of-the-art review and update. RadioGraphics 2011; 31(5): 1343-64.
<http://dx.doi.org/10.1148/rg.315105712>
7. Stefanović D, Petronijević M. Diferencijalna dijagnoza osteoporoze i osteomalacije. Balneoclimatologija 2007;31:71-8.
8. Arti B, Rao AD, Sudhaker RD. Osteomalacia as a result of vitamin D deficiency. Endocrinol Metab Clin 2010; 39: 321-31.
<http://dx.doi.org/10.1016/j.ecl.2010.02.001>
9. Favus MJ. Bisphosphonates for osteoporosis. N Eng J Med 2010; 363: 2027-35.
<http://dx.doi.org/10.1056/NEJMc1004903>
10. Suresh E, Pazianas M, Abrahamsen B. Safety issues with bisphosphonate therapy for osteoporosis. Rheumatology 2014; 53(1): 19-31.
<http://dx.doi.org/10.1093/rheumatology/ket236>
11. Harris ED Jr, Genovese MC (eds). Practical rheumatology. Mosby, London 1997.
12. Moyer VA. Vitamin D and calcium supplementation to prevent fractures in adults: U.S. Preventive services task force recommendation statement. Ann Intern Med 2013; 158: 691.

OSTEOMALACIJA ILI OSTEOPOROZA - PRIKAZ SLUČAJA

Nela Živković, Sonja Stojanović

Institut za lečenje i rehabilitaciju "Niška Banja", Srbija

Sažetak

Cij rada bio je prikaz dijagnostičkog i terapijskog pristupa bolesniku sa osteomalacijom, kao i diferencijalne dijagnoze sa osteoporozom.

Osteomalacija je metabolička bolest kostiju koja nastaje usled poremećene mineralizacije novoformiranog koštanog matriksa kod odraslih osoba. Postavljanje dijagnoze osteomalacije može predstavljati veliki problem. Bolesnica starosti 67 godina, iz Pirota, na pregled reumatologa je došla početkom decembra 2012. godine zbog bolova duž kičmenog stuba i nemogućnosti ustajanja iz kreveta. Radiografski su verifikovane kompresivne frakture lumbalnih pršljenova, a prethodno je operisana zbog preloma leve butne kosti. Ortoped, neurolog, fizijatar, kao i ordinirajući reumatolog posumnjali su na osteoporozu. Dijagnoza osteomalacije je postavljena februara 2013. godine, započeto je lečenje visokim dozama vitamina D (Vit D) i savetovana je terapija bisfosfonatima. Nakon osam meseci uočeno je značajno poboljšanje opšteg stanja, bolesnica je bila samostalno pokretna.

Ključne reči: osteomalacija, osteoporozu, dijagnoza, terapija