



Necrotizing Fasciitis of the Cheek: A Case Report

Vojkan Lazić¹, Dragan Krasić^{2,4}, Miloš Trajković², Miloš Stojanović²,
Nikola Živković^{3,4}, Milan Spasić⁵

¹University in Priština, Faculty of Medicine temporarily seated in Kosovska Mitrovica, Serbia

²Clinic of Dentistry, Department of Maxillofacial Surgery, Niš, Serbia

³Center for Pathology and Pathological Anatomy, Clinical Center Niš, Niš, Serbia

⁴University of Niš, Faculty of Medicine, Niš, Serbia

⁵Clinic of Dentistry, Department of Oral Surgery, Niš, Serbia

SUMMARY

The term necrotizing fasciitis (NF) was first used by Wilson in 1952, who described this rare, however, progressive infection that primarily affects the fascia and subcutaneous tissues. Necrotizing fasciitis may affect any part of the body; however, it usually appears on the extremities. The most common microorganisms isolated in NF are *Staphylococcus aureus*, group A *Streptococci*, and *Escherichia Coli*.

We are presenting the case of a sixty-seven-year old woman, who was admitted for the perforation of painful edema of the left cheek. Clinical examination of the anterior two-thirds of the left cheek revealed a defect of the full thickness of the skin, 3x4 cm in size. During the patient's hospitalization she was treated by parenterally administered broad-spectrum antibiotics, necrotomy, fasciotomy of the cheek and the extraction of the remaining roots in the 3rd and 4th quadrant.

Necrotic fasciitis is a rare, rapidly progressive infection of soft tissues, which, if untimely diagnosed and treated, may be life-threatening. The prognosis of treatment depends on the early recognition of the disease. It is treated with aggressive surgical debridement followed by antibiotic therapy.

Key words: necrotizing fasciitis, surgical and antibiotic treatment, secondary reconstruction

Corresponding author:

Miloš Trajković

Email:dr.mtrajkovic@yahoo.com

INTRODUCTION

The term necrotizing fasciitis (NF) was first used by Wilson in 1952, who described this rare, however, progressive infection that primarily affects the fascia and subcutaneous tissues. Besides the aforementioned term, this infection has also been referred to as hospital gangrene, necrotizing erysipelas, acute hemolytic streptococcal gangrene, progressive synergistic gangrene, and acute necrotizing cellulitis (1).

Necrosis of the fascia and connective tissue as well as the spread of the disease to the surrounding skin and muscles is the basic feature of this disease. Necrotizing fasciitis may affect any part of the body; however, it usually appears on the extremities (2). If the infection spreads and affects the major blood vessels, then it can cause sepsis, systemic toxic reaction, and compromise the functioning of the vital organs as well as the patient's life (3).

The occurrence of NF in the maxillofacial region is extremely rare and can be seen in 2.5% to 5% of all cases, when it is usually associated with some other systemic disease (1, 2).

Necrotizing fasciitis of the maxillofacial region is commonly preceded by an odontogenic infection, tonsillopharyngitis (4), or an infection of the salivary glands (5).

Immunosuppression, diabetes mellitus, chronic diseases, malnutrition, age over 60 years, renal insufficiency, malignant diseases, and burns stand for the predisposing factors for the occurrence of necrotizing fasciitis (4).

The most common microorganisms isolated in NF are *Staphylococcus aureus*, group A *Streptococci*, and *Escherichia Coli* (6).

CASE REPORT

Here, we present a case of a sixty-seven-year old woman, who was admitted to the Clinic of Maxillofacial surgery in Niš for the perforation of painful edema of the left cheek.

Before admission, the patient was treated with antibiotics in the relevant healthcare institution (amp. gentamycin 240 mg per day). On admission, the patient was febrile (39 °C), tachycardic, hypotensive, adynamic, and generally in a bad condition.

Clinical examination of the anterior two-thirds of the left cheek revealed a defect of the full thickness of the skin, 3x4 cm in size. The defect was of irregular shape and uneven edges, with the signs of hyperemia and edema of the surrounding skin up to 2 cm in diameter. The walls of the defect were uneven, predominantly covered with necrotic material (Figure 1).

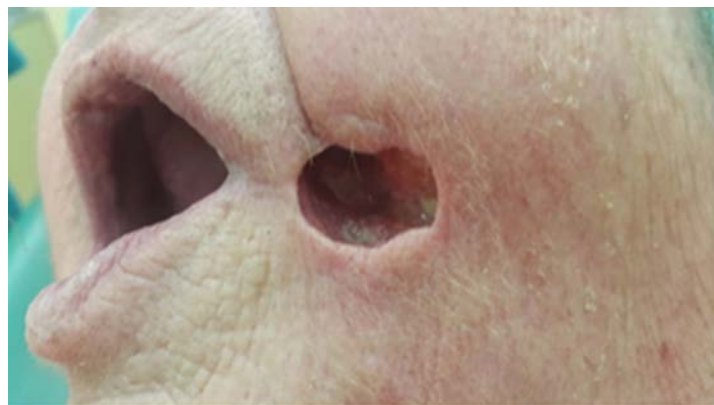


Figure 1. Necrotizing fasciitis with a defect of the cheek skin, 3x4 cm in size

In addition, in the most caudal parts of the defect, the signs of purulent exudation were noticed. The aforementioned region was painful on palpation, with the signs of reactive lymphadenitis, affecting the levels I and II of the neck. Intraoral inspection revealed a large number of decayed teeth and the remaining tooth roots. In the personal anamnesis, the patient mentioned a long-

term treatment of diabetes mellitus, chronic obstructive pulmonary disease, and arterial hypertension.

On admission, the patient was parenterally administered broad-spectrum antibiotics (Longaceph 2 g per 24h and Orvagil 500 mg per 8h) as well as electrolytes and rehydration therapy to maintain the hemodynamic status of the patient. A swab of the defect and a blood

sample were taken for the basic laboratory and biochemical analyses.

Laboratory finding showed the existence of leukocytosis, neutrophilia (87.7%), increased sedimentation rate, and increased levels of C-reactive protein (280 mg/l).

During the patient's hospitalization, we performed necrotomy, fasciotomy of the cheek, and the extraction of the remaining roots in the 3rd and 4th quadrant. Part of the tissue removed during surgical debridement was sent to pathohistological analysis. The pathohistological finding showed the presence of necrotizing fibrous tissue, with the signs of inflammatory infiltrate

composed of polymorphonuclears, liquefactive necrosis of the subcutaneous tissue, and vascular thrombosis.

In the microbiological analysis of the wound swab, *Klebsiellaspiroheta* (*Klebsiella spp.*) was isolated, when antibiotic therapy was changed and Cloxacillin 500 mg per 6h was administered for the next twenty days. Ten days after the aforementioned procedures were performed, regression of clinical and laboratory signs of the infection was noticed, and secondary wound closure was performed under the local anesthesia. On the tenth day after surgery, the stitches were removed. The patient was discharged from the clinic, without the clinical and laboratory signs of infection (Figure 2 and 3).

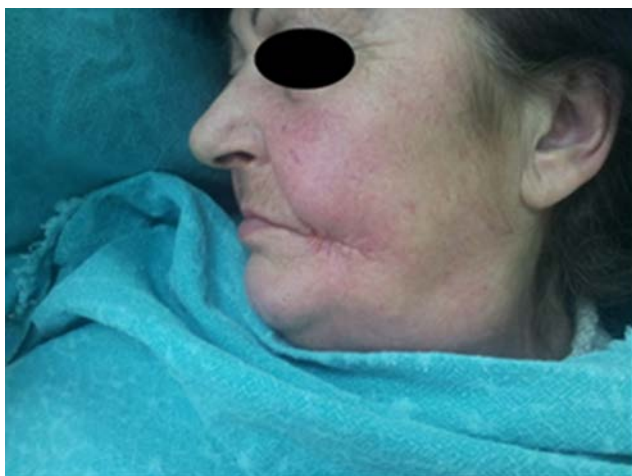


Figure 2.

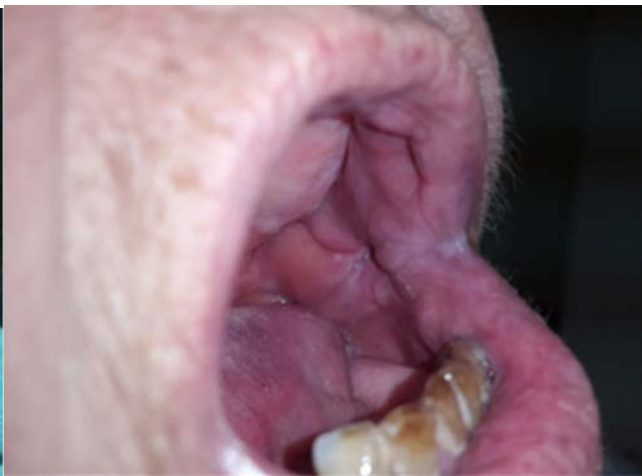

Figure 3.

Figure 2 and 3. The patient's appearance after the treatment of the infection and defect reconstruction

DISCUSSION

Necrotizing fasciitis of the maxillofacial region is a rare disease that commonly occurs as a complication of primary infection in immunocompromised patients. This aggressive soft-tissue infection easily affects the superficial fasciae, connective tissue, the surrounding skin and muscles, causing their necrosis (7). The presented case of necrotizing fasciitis of the cheek belongs to the group of rare localizations, as fasciitis usually involves the extremities, abdomen, and peritoneum. The incidence of NF of the maxillofacial region does not go beyond 5% (1, 2, 6).

In the eight-year study conducted by Wang and Lin (2) out of 115 patients in total, they reported only four cases with NF of the head and neck (3%).

The cause of NF in this patient was the remaining roots of the 3rd quadrant. A review of the reference literature

showed that necrotizing fasciitis of the head and neck is preceded by infections of the orofacial region, usually of the teeth, then throat and tonsil infections, injuries, insect bites, acne, furuncles, infections of the salivary glands (7). A long-term treatment of diabetes mellitus classified this patient in the group of patients with the predisposing factors for the onset of this disease. It is commonly accepted that besides diabetes mellitus, the predisposing factors include alcoholism, tobacco smoking, immunosuppression, malnutrition, age, malignant diseases, and liver cirrhosis (8).

Clinical finding is usually accompanied by painful edema, erythema, and stretching of the skin that is smooth and shiny. As the disease advances, bullae filled with the dark content arise, which is followed by the appearance of purple skin color and gangrenous and necrotic masses. The absence of bleeding, the appearance of greenish fluid content, offensive odor, easy dissection of the surrounding structures by finger stand for the pathognomonic signs of necrotizing

fasciitis (9-11). For the most part, the clinical picture corresponds to the one observed in our patient.

Early and appropriate diagnostics, aggressive surgical treatment, debridement, necrotomy, and the application of broad-spectrum antibiotics are of key importance for the management of this disease. The polymicrobial nature emphasizes the importance of a multidisciplinary approach, which besides surgery involves microbiology and infectology. If inadequately treated, this condition may lead to sepsis, respiratory and renal insufficiency that can ultimately cause the fetal outcome (12, 13). The majority of authors consider that antibiotic therapy should be started without delay, including antibiotics against gram-positive, gram-negative and anaerobic bacteria until antibiogram results are obtained, when specific therapy should be initiated. In practice, the most commonly used antibiotics are penicillins and cephalosporins in combination with aminoglycosides and Orvagal and clindamycin (14-16).

In this case, we prescribed the third-generation cephalosporins in combination with metranidazole.

In addition to antibiotic and surgical treatment, hyperbaric oxygen therapy is used to improve the circulation of tissues affected with infection and to exert effects on anaerobic bacteria.

CONCLUSION

Necrotic fasciitis is a rare, rapidly progressive infection of soft tissues, which, if untimely diagnosed and treated, may be life-threatening. It is characterized by necrosis of fasciae and subcutaneous tissues, spreading to the surrounding skin and muscles. In this article, a rare localization of necrotizing fasciitis was described. The prognosis of treatment depends on the early recognition of the disease. Treatment is based on the surgical debridement and use of antibiotic therapy.

References

1. McAndrew P, Davies S, Griffiths R. Necrotising fasciitis caused by dental infection. *Bri J Oral Maxillofac Surg* 1987; 25:314-22
[https://doi.org/10.1016/0266-4356\(87\)90071-4](https://doi.org/10.1016/0266-4356(87)90071-4)
2. Jinn-Ming W, Hwee-Kheng L. Necrotizing fasciitis: Eight-year experience and literature review. *Braz J Infect Dis* 2014;18:137-43
3. Navarro-Cano E, Noriego-Munoz D. Multifocal necrotizing fasciitis. Presentation of a case: *Rev Esp Cir OrtopTraumatol*. 2014;58:60-3 (in Spanish)
4. Boninsegna M, Marioni G, Stramare R, et al. Cervical necrotizing fasciitis: an unusual complication of genuineperitonsillar abscess. *J Otolaryngol*. 2005; 34:258-61.
5. Marioni G, Bottin R, Tregnaghi A, et al. Cranio-cervical necrotizing fasciitis secondary to parotid gland abscess. *ActaOtolaryngol* 2003;123:737-40.
6. Morgan M.S. Diagnosis and management of necrotizing fasciitis: a multiparametric approach *J Hosp Infect* 2010; 75:249-57
7. Marioni G, Rinaldi R, Ottaviano G, et al. Cervical necrotizing fasciitis: A novel clinical presentation of Burkholderiacepacia infection. *J Infect*. 2006;53:e219-22
8. Fliss D, Tovi F, Zirkin H. Necrotizing Soft-Tissue Infections of Dental origin: *J Oral Marillofac Surg*. 1990; 48:1104-8
9. Krishnan V, Johnson J, Helfrick J. Management of Maxillofacial Infections: A Review of 50 Cases: *J Oral MaxillofacSurg*. 1993; 51:868-873
[https://doi.org/10.1016/S0278-2391\(10\)80105-3](https://doi.org/10.1016/S0278-2391(10)80105-3)
10. Lee JW, Immerman SB, Morris LG. Techniques for early diagnosis and management of cervicofacial necrotising fasciitis. *J Laryngol Otol*. 2010;124:759-64.
<https://doi.org/10.1017/S0022215110000514>
11. Anderasen TJ, Green SC, Childers BJ. Massive Infectious Soft-Tissue Injury: Diagnosis and management of necrotizing fasciitis and purpurafulminans. *PlastReconstrSurg* 2001; 107: 1025-34.
<https://doi.org/10.1097/00006534-200104010-00019>
12. Chin-Ho W, Yi-Shi W. The diagnosis of necrotizing fasciitis. *CurrOpin Infect Dis* 2005; 18: 101-6.
<https://doi.org/10.1097/01.qco.0000160896.74492.ea>
13. Green RJ, Dafoe DC, Raffin TA. Necrotizing fasciitis. *Chest*. 1996;110:219-29.
<https://doi.org/10.1378/chest.110.1.219>
14. Quereshy FA, Baskin J, Barbu AM, Zechel MA. Report of a case of cervicothoracic necrotizing fasciitis along with a current review of reported cases. *J Oral Maxillofac Surg*. 2009;67:419-23.
<https://doi.org/10.1016/j.joms.2008.07.017>
15. Abass K, Saad H, Abd-Elsayed AA. Necrotizing fasciitis with toxic shock syndrome in a child: a case report and review of literature. *Cases J*. 2008; 1:228-32.
<https://doi.org/10.1186/1757-1626-1-228>
16. Weiss A, Nelson P, Movahed R, et al. Necrotizing fasciitis: review of the literature and case report. *J Oral Maxillofac Surg*. 2011;69:2786-94.
<https://doi.org/10.1016/j.joms.2010.11.043>

Nekrotizujući fasciitis obraza: prikaz slučaja

Vojkan Lazić¹, Dragan Krasić^{2,4}, Miloš Trajković², Miloš Stojanović²,
Nikola Živković^{3,4}, Milan Spasić⁵

¹Univerzitet u Prištini, Medicinski fakultet sa privremenim sedištem u Kosovskoj Mitrovici, Srbija

²Klinika za stomatologiju, Odsek za maksilofacijalnu hirurgiju, Niš, Srbija

³Centar za patologiju I patološku anatomiju, Klinički centar Niš, Niš, Srbija

⁴Univerzitet u Nišu, Medicinski fakultet, Niš, Srbija

⁵Klinika za stomatologiju, Odeljenje za oralnu hirurgiju, Niš, Srbija

SAŽETAK

Termin nekrotizujući fasciitis (NF) prvi put je koristio Vilson 1952. godine, koji je opisao ovu retku progresivnu infekciju koja prvenstveno utiče na fasciju i potkožna tkiva. Nekrotizujući fasciitis može uticati na bilo koji deo tela; međutim, obično se pojavljuje na ekstremitetima. Najčešći mikroorganizmi izolovani u NF su *Staphylococcus aureus*, *Streptococci* grupe A i *Escherichia Coli*.

Predstavljamo slučaj žene stare šezdeset i sedam godina, koja je primljena zbog perforacije bolnog edema levog obraza. Kliničkim pregledom prednje dve trećine levog obraza otkriven je nedostatak punih debljina, kože veličine 3x4 cm. Tokom hospitalizacije lečena je parenteralno administriranim antibioticima širokog spektra, nekrotomijom, fasciotomijom obraza i ekstrakcijom preostalih korena u III i IV kvadrantu.

Nekrotični fasciitis je retka, brza, progresivna infekcija mekih tkiva, koja, ako se blagovremeno ne dijagnostikuje i leči, može biti opasna po život. Prognoza lečenja zavisi od ranog prepoznavanja bolesti. Leči se agresivnim hirurškim debridmanom praćenim antibiotskom terapijom

Ključne reči: nekrotizujući fasciitis, hirurški i antibiotski tretman, sekundarna rekonstrukcija