

*Original article*

## **Common Mistakes in the Choice of Topical Agents for Emergency Care of Burns (Experimental Study)**

Roman Chornopyschuk<sup>1</sup>, Vasy Nagaichuk<sup>1</sup>, Oleksandr Nazarchuk<sup>2</sup>,  
Svetlana Sidorenko<sup>3</sup>, Olena Urvan<sup>4</sup>

<sup>1</sup>*Department of General Surgery, National Pirogov Memorial Medical University, Vinnytsya, Ukraine*

<sup>2</sup>*Department of Microbiology, National Pirogov Memorial Medical University, Vinnytsya, Ukraine*

<sup>3</sup>*Department of Neurological, Musculoskeletal and Oncologic Rehabilitation, Rehabilitation Center,  
Bad Ragaz, Switzerland*

<sup>4</sup>*Main Department of General Pathology with Histological Researches, Municipal Non-profit Enterprise  
"Vinnytsya Regional Pathological and Anatomical Bureau Vinnytsya Regional Council", Vinnytsya, Ukraine*

### **SUMMARY**

The aim of the research was a histological study of the tissue structure of experimental animals with burns in dynamics using various topical agents after the injury.

Experimental simulation of burn injuries was performed on 40 rats, which were divided into the main and control groups. Depending on the nature of care provided, the animals of the main group were divided into subgroups: in the 1<sup>st</sup> subgroup a uniform layer of sunflower oil was applied, in the 2<sup>nd</sup> subgroup dexpanthenol was sprayed, in the 3<sup>rd</sup> subgroup prompt neutralization of traumatic action was performed with a gauze napkin soaked in water. Animals from the control group were not treated. The examination involved a histological study.

The results confirmed the negative impact of applying oil to the burnt area as a means of first aid, which caused more pronounced degenerative changes of the dermis and its structures with the involvement of hypodermis in the pathological process, prolonging the duration of healing. As for the use of dexpanthenol spray for burn injuries, the histological changes of tissues did not differ much from those in animals of the control group, which did not receive any care. At the same time, histological findings of the tissues of animals treated with moistened wipes was characterized by less pronounced pathological changes.

Histological analysis of tissue changes of the burnt area in dynamics objectively proved the effectiveness of water as the main pathogenetic element of emergency care in an experiment.

**Key words:** burn injuries, first aid, heat removal, warm water

Corresponding author:

**Roman Chornopyschuk**

e-mail: r.chornopyschuk@gmail.com

## INTRODUCTION

Burn injuries remain a serious medical issue with a high level of disability and mortality among victims (1). Despite numerous differences in the statistics of burn injuries and their change tendencies in different countries, social and economic components remain common, which is often a burden to the patient, their family and the state as a whole (2, 3). This is especially true in low-income countries, where principles of insurance medicine are not fully developed and state guarantees are not able to compensate for long-term, costly treatment of such patients with subsequent rehabilitation (4, 5). This is also true about innovative technologies and materials, the use of which in the practical health care system is severely limited due to their price. Thus, the analysis of financial costs conducted at the Burn Centre of Maastad Hospital in Rotterdam (Netherlands) found that the cost per patient with burn injuries of 8% is about 26,540 € (from 742 to 235,557 €), of which 62% is for hospital stay, 5 % for surgery and 20% for absence from work (6). Moreover, deterioration of the economic climate of many countries and Ukraine in particular leads to a decrease in the number of specialized burn hospitals or the corresponding beds. Therefore, adequate self-help, mutual assistance and first aid become especially important, which will prevent the progression of the pathological process and, accordingly, accelerate the recovery of the victim (7). For this purpose, it is essential to apply water at room temperature to the injured area for a certain period of time (8). Despite numerous experimental justifications for the feasibility of this simple, affordable method, significant positive experience of its practical use, the level of prehospital use still remains low and is, according to the literature, 70% of cases, 20 - 30% of which is ice water or ice (9).

According to some studies, 47% of patients were hospitalized with burn injuries which were treated with folk remedies (10). The choice of such means depends on territorial and ethnic features, but in general sunflower oil and animal fats, which are found in 28.9% of hospitalized patients, occupy the leading positions. Not least among them is the irrational use of drugs, especially antibacterial drugs and stimulants of reparative processes in the form of ointments, sprays, which are actively promoted by the media without detailing clear indications or features of application.

Research objective: histological study of the tissue structure of experimental animals with burns in dynamics using various topical agents after the injury.

## MATERIALS AND METHODS

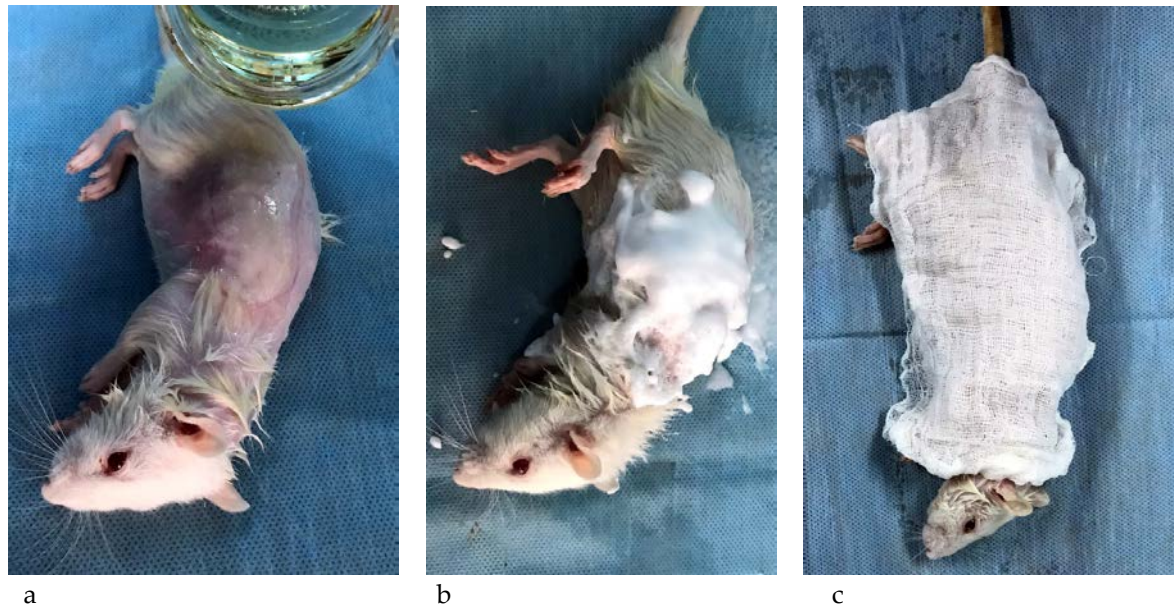
The experimental study was performed on 40 sexually mature Wistar rats, which were on a normal diet weighing 150 - 160 g. The study followed the international rules and principles of the «The European Convention for the Protection of Vertebrate Animals used for Experimental and other Scientific Purposes» (Strasbourg, 18.03.1986), directives of the Council of the European Economic Association for the protection of vertebrate animals (Strasbourg, 24.11.1986), Directive 2010/63/EU of European Parliament and Council on the protections of animals used for scientific purposes, «General ethical guidelines for experiments on animals» (Kyiv, 2011).

Experimental animals were divided into the main and control groups. Simulation of IIb degree burn injuries with boiling water was performed on the rats of both groups according to the method suggested by Pfurtscheller et al. (11). Depending on the nature of care provided, which began immediately after receiving burns, the animals of the main group were divided into subgroups: in the 1<sup>st</sup> subgroup a uniform layer of sunflower oil was applied on the affected area (Figure 1a); in the 2<sup>nd</sup> subgroup dexpanthenol was sprayed on the burnt surface area (Figure 1b); in the 3<sup>rd</sup> subgroup prompt neutralization of hyperthermic traumatic factors was performed with a gauze napkin soaked in water at a temperature of 18 - 20°C, which was changed when heated to 34°C (Figure 1c). Animals of the control group were not treated.

The study involved histological examination of tissues, the collection of which was carried out immediately after modeling the pathological process, as well as on the 3<sup>rd</sup>, 7<sup>th</sup>, 14<sup>th</sup> day from visible parts of the lesion and adjacent tissues up to 5 mm thick. The obtained tissue array was fixed in a 10% solution of neutral formalin, then washed, dehydrated, embedded in paraffin and sections 7 µm thick were prepared on a microtome. The prepared histological specimens were stained with hematoxylin and eosin (12). Stained sections were examined using OLYMPUS BX-41 light microscope (Ministry of

Health of Ukraine, State Registration Certificate № 8120/2008, code 9011800000) at a magnification of 40, 100 and 200 times. Image visualization was per-

formed using Quickphoto micro 2.3 (license agreement № 925113924).



**Figure 1.** Appearance of experimental animals with burn injuries at the stage of first aid with sunflower oil (a), dexpanthenol based spray (b), and soaked napkin (c)

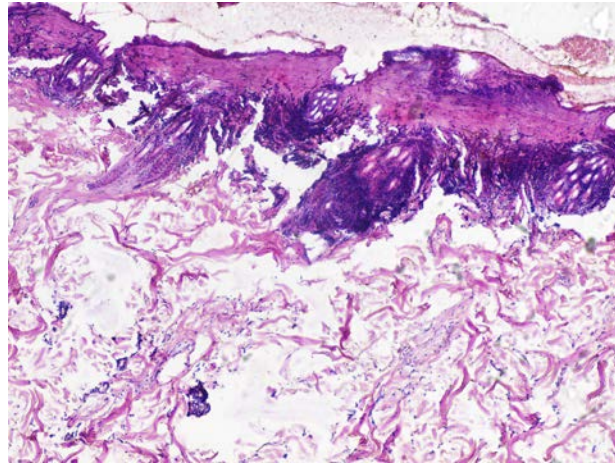
## RESULTS

Immediately after simulating boiling water burns in all animals, the injured area was defined without clear borders with the formation of necrosis in its center and pronounced perifocal reactive changes in the form of focal perivascular lymphocytic infiltration and signs of significant hemomicrocirculation disorders. Desquamation of epidermis with pronounced coagulation changes was determined, and the dermis consisted of bundles of collagen and elastic fibers with different directions, which in some places showed the signs of necrosis. The vessels in the dermis around the immediate area of the lesion were paretically dilated with pronounced dystrophic changes in the endothelium, plethora and marginal leukocytes. Small clusters of lymphocytes, monocytes and isolated leukocytes were detected around the skin appendages and perivascularly. The structure of hypodermis was disrupted due to degenerative changes with signs of accumulation of oedematous fluid, where there were single mononuclear cells such as blood monocytes, lymphocytes, segmental leukocytes (Figure 2).

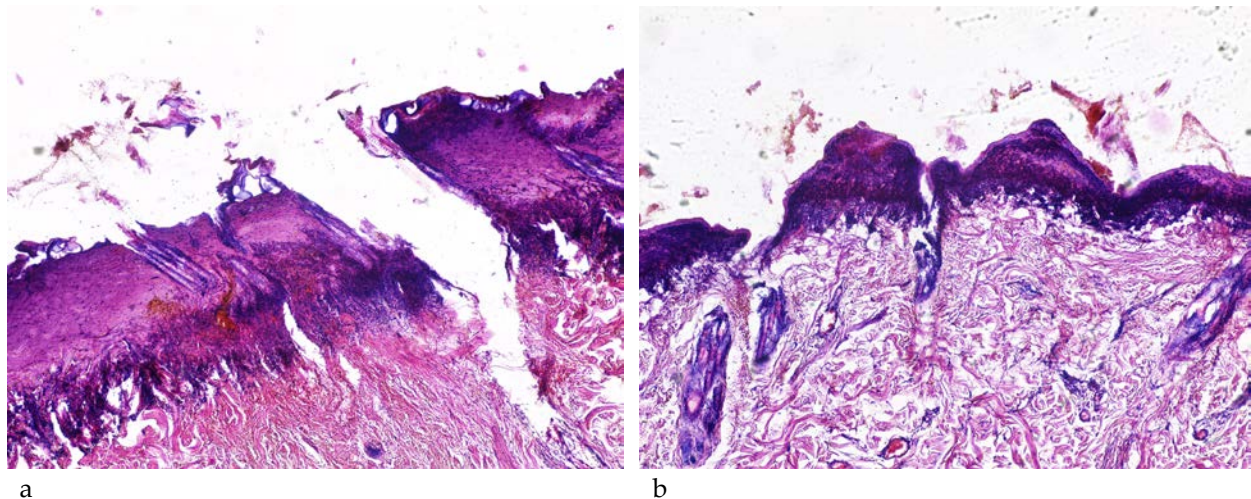
On the 3<sup>rd</sup> day of observation, the signs of a fairly deep thermal burn injury with significant coagulation changes in the epidermis, adjacent dermis and skin appendages in animals of the main group 1 were noted. Expressed oedema, stratification and fragmentation of collagen and elastin fibers of deep layers of dermis, hemomicrocirculation disorder with perivascular infiltration of lymphocytes and leukocytes were defined (Figure 3a).

Animals of the main group 2 in the same period had a more favorable histological picture: signs of less deep thermal burns with much smaller coagulation changes of skin structures were determined. In the adjacent dermis and its deeper layers, a moderate edema, pronounced erythrocytosis in the vessels, and preserved skin appendages with degenerative changes were observed. The intensity of inflammatory infiltration, represented mainly by segmental neutrophils, lymphocytes and cells of the monocyte series, was less pronounced (Figure 3b).

Histological signs of thermal injury in the tissues of animals of the main group 3 were the least pronounced in comparison with the previous ones. They were characterized by a reduction in area, depth



**Figure 2.** Microscopic skin changes of the studied animals immediately after the simulation of experimental burns. Hematoxylin-eosin staining x100.



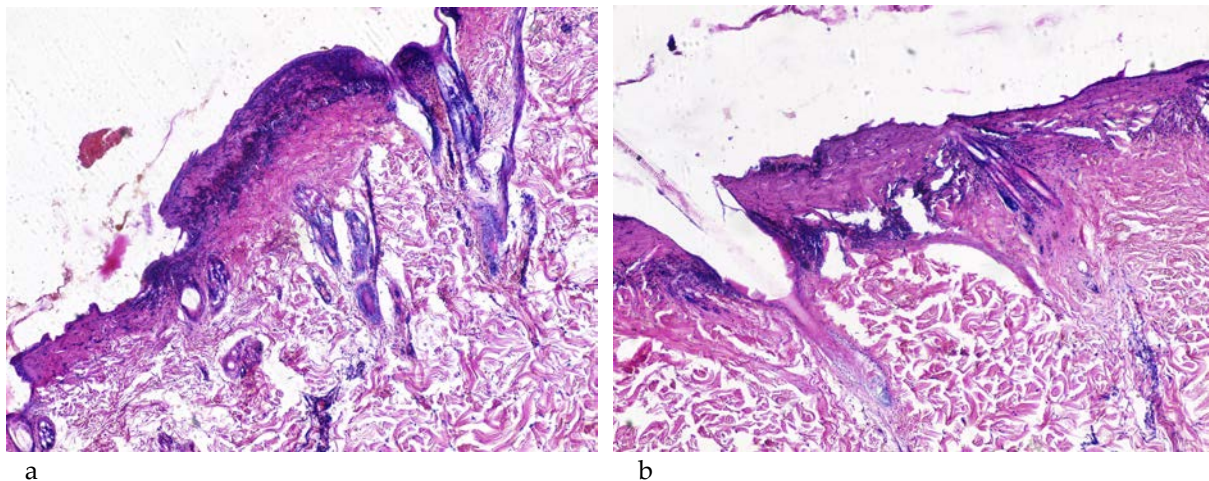
**Figure 3.** Microscopic changes in the skin of animals of the main group 1 (a) and the main group 2 (b) on the 3<sup>rd</sup> day after modeling of experimental burns. Hematoxylin and eosin staining x100.

of coagulated tissues, which was mainly limited to the epidermal layer and corresponded to changes characteristic of superficial damage (minor coagulation changes in the epidermis, adjacent dermis, skin appendages, moderate oedema of collagen and elastin fibers of deep layers of dermis, small focal inflammation with a predominance of lymphocytes, mononuclear tissues). The obtained results indicated the ability of prompt neutralization of traumatic action of thermal agents not only to prevent the progression of the process, but also to positively affect the cells in the state of parabiosis with the restoration of their structure and function in the first days after the injury (Figure 4a).

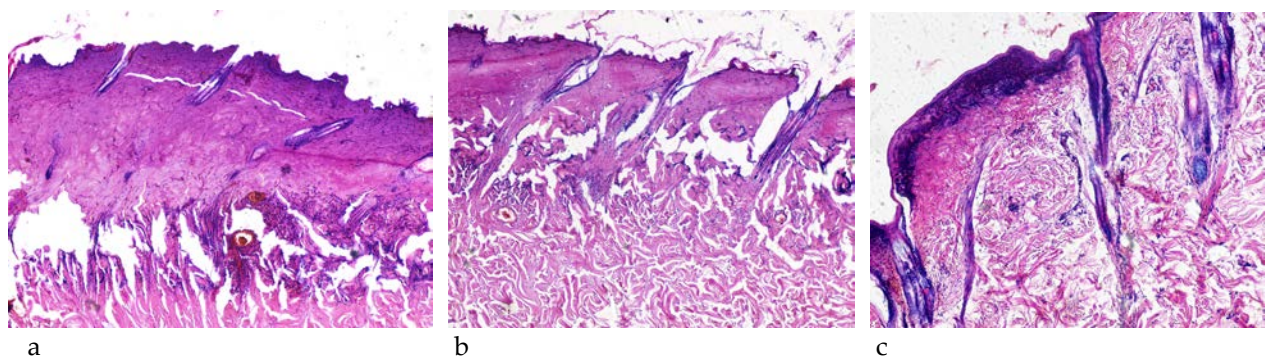
Histological structure of tissues of animals in the control group, which were not provided first aid at all, was characterized by a slight reduction in the area of coagulation damage, without clear borders, which was due to compaction and thinning of the coagulated tissue in the centre of which necrosis was determined. Signs of expressed perivascular infiltration of lymphocytes and leukocytes with micro-circulatory disorders persisted. The adjacent dermis was coagulated. Signs of moderate oedema were detected in the deeper layers of the dermis (Figure 4b).

On the 7<sup>th</sup> day of observation, the animals of the main group 1 and the control group showed complete rejection of the coagulated dead epidermis





**Figure 4.** Microscopic skin changes of animals of the main group 3 (a) and control group (b) on the 3<sup>rd</sup> day after modeling experimental burns. Hematoxylin and eosin staining x100.



**Figure 5.** Microscopic skin changes of animals of the main group 1 (a), the main group 2 (b) and the main group 3 (c) on the 7<sup>th</sup> day after modeling experimental burns. Hematoxylin and eosin staining x100.

and the initial marginal growth of new epithelium on the granulation tissue. Signs of an inflammatory reaction that spread to the hypodermis persisted. Among the inflammatory cells isolated, new fibroblasts were observed. Vascular reaction in the form of plethora, dermal oedema, erythrostatics in the vessels of its deep layers continued to be determined (Figure 5a).

In animals of the main group 2 on day 7, the activity of proliferative manifestations was higher, which was manifested by more active closure of granulation tissue with new epithelium on the background of rejection of necrotic tissues from the wound surface. Manifestations of the inflammatory reaction were moderate and, as in the previous

group, they not only spread to the subcutaneous tissue, but were accompanied by active appearance of new forms of fibroblasts. Erythrostatics in the dermal vessels as well as oedema of single bundles of collagen fibers persisted (Figure 5b).

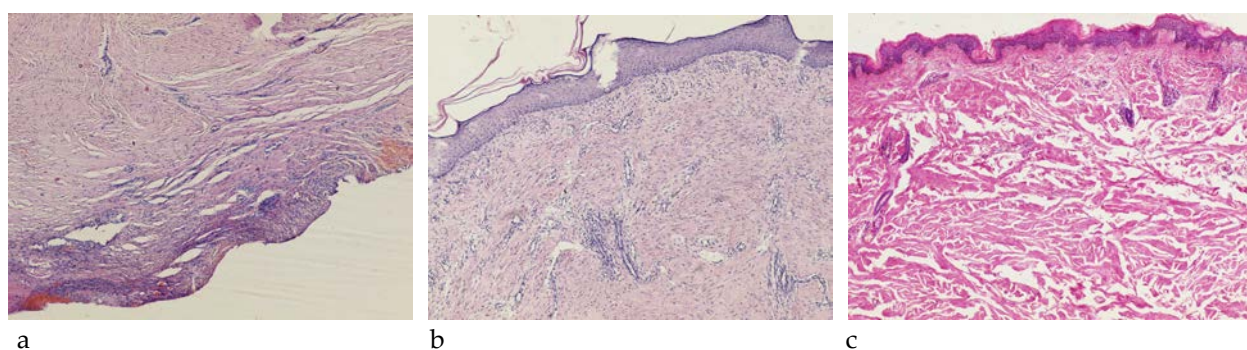
In animals of the main group 3, which immediately after the burn were treated with wipes soaked with water, healing of the burn injury was histologically confirmed, with formation of new epithelium and connective tissue scar under it. The connective tissue had vascular reduction, as well as a significant number of fibrocytes and collagen fibers. In some places, skin appendages (hair follicles, sebaceous and sweat glands) were identified. Minor manifestations of the inflammatory reaction in the

form of lymphohistiocytic infiltration and microcirculatory disorders in the area of scar formation persisted (Figure 5c).

On the 14<sup>th</sup> day, the signs of wound healing on the background of burns and the formation of scar tissue in these areas with some differences depending on the characteristics of first aid provided were determined in all the observed groups. In particular, in animals of the main group 1, where sunflower oil was immediately applied to the burnt area, a new cell scar was determined, which consisted of a large number of fibroblasts, fibrocytes, collagen fibers and partially replaced the structural elements of intact skin. A layer of fibrous tissue and hypodermis was determined under the scar, where signs of lymphohistiocytic infiltrative inflammation persisted. Significant inhibition of epithelization processes was noted (Figure 6a).

Oddly enough, epithelization processes in the animals of the control group, which were not provided any treatment, were more active and on the 14<sup>th</sup> day almost the entire wound defect was closed. The formation of a new cell scar was also accompanied with focal inflammatory cell infiltration. Reduction of blood vessels and absence of skin appendages (hair follicles, sebaceous and sweat glands) were observed (Figure 6b).

Histological examination of animal tissues of the main group 2 and 3 on the 14<sup>th</sup> day after the injury established complete healing of the burn without inflammatory changes with the formation of a complete connective tissue scar with its total epithelization. A layer of shaped fibrous tissue, as well as hair follicles, sebaceous and sweat glands, were determined under the scar tissue (Figure 6c).



**Figure 6.** Microscopic skin changes of animals of the main group 1 (a), control group (b) and the main group 3 (c) on the 14<sup>th</sup> day after modeling experimental burns. Hematoxylin and eosin staining x100.

## DISCUSSION

The existing literature sources indicate the undeniable positive effect of hypothermia ("cooling") on the affected areas in terms of self-help, mutual assistance and first aid (13). Moreover, the principles of neutralization of traumatic thermal agents using water and applying a clean dressing to the wound have become the basis of most modern clinical guidelines (14). Nevertheless, empirically, patients with burn injuries continue to use alternative folk remedies (oil, butter, eggs, honey, toothpaste, products of vital functions, vegetables, fruit, etc.) or drugs for other purposes. Such substances are not only ineffective but can lead to burn deepening, their infection with further deterioration of the general condition and increased risk of mortality (15). With

this in mind, a similar experimental study was conducted with simulation of IIb degree boiling water burns and the use of various first aid means, which began immediately after the injury and involved the study of histological structure of tissues in the area of injury at different stages of the wound process. The obtained results naturally confirmed the negative impact of applying oil to the burnt area as first aid, which caused more pronounced degenerative changes in the dermis and its structures with the involvement of even the hypodermis in the pathological process. In general, the nature of changes contributed to the prolongation of wound healing, delay of epithelization, which did not completely occur even on the 14<sup>th</sup> day of observation. The obtained histological findings were worse than in animals, which were not treated at all. At the same

time, histological findings of animal tissues treated with wet wipes were characterized by less pronounced pathological changes during the entire observation period with a decrease in inflammatory activity on the 3<sup>rd</sup> day, which was manifested by small focal infiltration of cellular elements, oedema, and vascular plethora with the preservation of the structure of skin appendages. Concerning the use of dexpanthenol-based spray for burn injuries, histological changes of the tissues, especially during the first days, did not differ much from those in the animals of the control group, which did not receive any treatment.

### CONCLUSION

Histological analysis of tissue changes of the burn area in dynamics objectively proved the effectiveness of water as the main element of emergency care in an experiment, which pathogenetically con-

firms the need for further neutralization of traumatic endogenous factor in the paranecrotic area. The use of folk remedies or wound healing agents at this stage of development of thermal trauma is inexpensive and ineffective.

### Conflict of interest

The authors declares that there is no conflict of interest.

### Acknowledgment

We express our gratitude to the administration of Vinnytsya National Pirogov Medical University headed by the rector, academician of the National Academy of Medical Sciences of Ukraine, professor Moroz Vasyl in supporting and facilitating the study.

## References

1. Cinal H, Barın E. Five years of experience in a burn care unit: Analysis of burn injuries in 667 patients. *Van Med J*. 2020;27(1):56-62. <https://doi.org/10.5505/vtd.2020.60343>
2. Wasiak J, Lee SJ, Paul E, et al. Predictors of health status and health-related quality of life 12 months after severe burn. *Burns*. 2014; 40(4):568-74. <https://doi.org/10.1016/j.burns.2014.01.021>
3. Mistry RM, Pasisi L, Chong S, Stewart J, She RB. Socioeconomic deprivation and burns. *Burns*. 2010; 36(3):403-8. <https://doi.org/10.1016/j.burns.2009.05.021>
4. Smolle C, Cambiaso-Daniel J, Forbes AA, et al. Recent trends in burn epidemiology worldwide: A systematic review. *Burns*. 2017; 43(2):249-57. <https://doi.org/10.1016/j.burns.2016.08.013>
5. Stander M, Wallis LA. The emergency management and treatment of severe burns. *Emerg Med Int*. 2011;2011:161375. <https://doi.org/10.1155/2011/161375>
6. Hop MJ, Wijnen BF, Nieuwenhuis MK, et al. Economic burden of burn injuries in the Netherlands: A 3 months follow-up study. *Injury*. 2016 ; 47(1):203-10. <https://doi.org/10.1016/j.injury.2015.09.009>

7. Baartmans MG, de Jong AE, van Baar ME, et al. Early management in children with burns: Cooling, wound care and pain management. *Burns*. 2016; 42(4):777-82.  
<https://doi.org/10.1016/j.burns.2016.03.003>
8. Fiandeiro D, Govindsamy J, Maharaj RC. Prehospital cooling of severe burns: Experience of the Emergency Department at Edendale Hospital, KwaZulu-Natal, South Africa. *S Afr Med J*. 2015; 105(6):457-60.  
<https://doi.org/10.7196/SAMJ.8705>
9. Taira BR, Singer AJ, Cassara G, et al. Rates of compliance with first aid recommendations in burn patients. *J Burn Care Res*. 2010; 31(1): 121-4.  
<https://doi.org/10.1097/BCR.0b013e3181cb8cd9>
10. Cheng W, Shen C, Zhao D, et al. The epidemiology and prognosis of patients with massive burns: A multicenter study of 2483 cases. *Burns*. 2019 ; 45(3):705-16.  
<https://doi.org/10.1016/j.burns.2018.08.008>
11. Pfurtscheller K, Petnehazy T, Goessler W, et al. Innovative scald burn model and long-term dressing protector for studies in rats. *J Trauma Acute Care Surg*. 2013 Mar;74(3):932-5.  
<https://doi.org/10.1097/TA.0b013e31827d0fc3>
12. Suvarna SK, Layton C, Bancroft JD. *Bancroft's Theory and Practice of Histological Techniques (Eighth Edition)*, Elsevier, 2019.
13. Frear CC, Griffin B, Kimble R. Adequacy of cool running water first aid by healthcare professionals in the treatment of paediatric burns: A cross-sectional study of 4537 children. *Emerg Med Australas*. 2021; 33(4):615-22.  
<https://doi.org/10.1111/1742-6723.13686>
14. Ashman H, Rigg D, Moore F. The assessment and management of thermal burn injuries in a UK ambulance service: a clinical audit. *Br Paramed J*. 2020 ; 5(3):52-8.  
<https://doi.org/10.29045/14784726.2020.12.5.3.52>
15. Kattan AE, AlShomer F, Alhujayri AK, et al. Current knowledge of burn injury first aid practices and applied traditional remedies: a nationwide survey. *Burns Trauma*. 2016; 4:37.  
<https://doi.org/10.1186/s41038-016-0063-7>



## Česte greške u izboru lokalnih agenasa za hitno zbrinjavanje opekotina (eksperimentalna studija)

Roman Chornopyshchuk<sup>1</sup>, Vasył Nagaichuk<sup>1</sup>, Oleksandr Nazarchuk<sup>2</sup>, Svetlana Sidorenko<sup>3</sup>, Olena Urvan<sup>4</sup>

<sup>1</sup>Departman za opštu hirurgiju, Nacionalni memorijalni medicinski univerzitet Pirogov, Vinica, Ukrajina

<sup>2</sup>Departman za mikrobiologiju, Nacionalni memorijalni medicinski univerzitet Pirogov, Vinica, Ukrajina

<sup>3</sup>Departman za neurološku, muskuloskeletalnu i onkološku rehabilitaciju, Rehabilitacioni centar, Banja Ragaz, Švajcarska

<sup>4</sup>Glavni departman za opštu patologiju sa histološkim istraživanjima, Gradska neprofitna organizacija "Vinica regionalni patološki i anatomski biro Vinica regionalnog saveta" Vinica, Ukrajina

### SAŽETAK

Cilj istraživanja bilo je histološko ispitivanje strukture tkiva eksperimentalnih životinja sa opekotinama korišćenjem različitih lokalnih agenasa nakon povrede.

Eksperimentalna simulacija nanošenja povreda sprovedena je na 40 pacova, koji su bili podeljeni u glavnu i eksperimentalne grupe. U zavisnosti od vrste pružene nege, životinje iz glavne grupe bile su podeljene u podgrupe: u prvoj podgrupi nanešen je uniformni sloj suncokretovog ulja; u drugoj podgrupi naprskan je dekspantenol; u trećoj podgrupi urađena je hitna neutralizacija traumatskog postupka korišćenjem gaze natopljene u vodu. Životinje iz kontrolne grupe nisu tretirane. Pregled je uključivao histološku studiju.

Rezultat je potvrdio negativni uticaj nanošenja ulja na opekotinu kao sredstva prve pomoći, što je izazvalo naglašenije degenerativne promene dermisa i njegovih struktura, sa zahvatanjem hipodermisa u patološkom procesu i produženjem zarastanja. Što se tiče upotrebe dekspantenola u spreju za tretiranje opekotina, histološke promene tkiva nisu se mnogo razlikovale od promena kod životinja kontrolne grupe koje nisu dobile nikakvu negu. U isto vreme, histološki nalazi tkiva životinja tretiranih nakvašenim trakama odlikovali su se manje izraženim patološkim promenama.

Histološka analiza promene tkiva opekotine objektivno je dokazala efikasnost vode kao glavnog patogenetskog elementa hitnog zbrinjavanja u eksperimentu.

**Ključne reči:** opekotine, prva pomoć, uklanjanje toplote, topla voda