

Case report

Chronic Granulomatous Invasive Fungal Sinusitis: A Review of the Literature and Report of a Case Atypical of the Balkan Region

Milica Labus¹, Jelena Sotirović², Biserka Vukomanović Đurđević³, Aleksandar Perić²

¹Department of Otorhinolaryngology, Military Medical Academy, Belgrade, Serbia

²University of Defence, Faculty of Medicine of the Military Medical Academy,
Department of Otorhinolaryngology, Belgrade, Serbia

³University of Defence, Faculty of Medicine of the Military Medical Academy,
Institute for Pathology, Belgrade, Serbia

SUMMARY

Introduction. Chronic granulomatous invasive fungal rhinosinusitis (CGIFRS) is an extremely rare form of invasive fungal sinusitis. The disease has a long-lasting and indolent course, so the invasion and destruction in the sinonasal and adjacent regions is progressing slowly. This disease has been reported primarily in Middle East, North Africa, India and Pakistan; however, it is very rare in western countries. It is primarily caused by *Aspergillus flavus*.

Case Report. A 40-year-old man, who was repeatedly surgically treated for chronic rhinosinusitis with nasal polyps, was presented to our Otorhinolaryngology Department with a progressive, sudden right-sided proptosis. Contrast-enhanced paranasal sinus computed tomography (CT) showed almost complete soft tissue opacification of the sinonasal region, eroded bone structures and expansion into the right orbit. Erosion of the walls of the right frontal sinus was also seen but without intracranial propagation. Histopathological examination was necessary for the final diagnosis. The finding of granulomatous response along with fibrosis and strong inflammatory infiltrate was typical for chronic granulomatous invasive fungal sinusitis. The patient was successfully treated with a combination of surgery and postoperative medical therapy with voriconazole. To our knowledge, this is the first case of CGIFRS presented in Serbia. In addition, we reviewed the literature concerning this rare form of fungal sinusitis, especially for the Balkan region.

Conclusion. Although we reported an extremely rare case of fungal sinusitis for the Balkan region, it is important to suspect on it in all cases where chronic inflammation of the paranasal sinuses does not respond to conventional treatment.

Keywords: granuloma, inflammation, mycoses, nasal surgical procedures, sinusitis, voriconazole

Corresponding author:

Milica Labus

e-mail: krstic.milica@yahoo.com

INTRODUCTION

Fungal infections of the paranasal sinuses are a spectrum of diseases rather than one distinct entity with increasing frequency in recent years. A generally accepted classification system divides fungal rhinosinusitis (FRS) into two wide groups: invasive and non-invasive, based on the ability of the fungal hyphae to penetrate the tissues through the epithelium, while both are later subdivided into acute and chronic form, given the duration of the disease (1, 2). Although invasive FRS is rare, it is significant because of its aggressive course and dramatic tissue invasion resulting in excessive morbidity. Acute invasive fungal rhinosinusitis (AIFRS) has fulminant course and high mortality rates (50-80%) (3). Chronic forms of invasive FRS are pathologically similar to AIFRS, but very different when it comes to the incidence, population of patients that are prone to it, clinical presentation, duration of the disease, morbidity and mortality (1 - 3).

Chronic granulomatous invasive fungal rhinosinusitis (CGIFRS) is a rare disease, with several cases a year reported mainly in subtropical areas of India, Sudan, Pakistan and Saudi Arabia (1 - 4). It is endemic in some parts of the USA, otherwise very infrequently seen in the western countries (1 - 4). It typically occurs in immunocompetent patients and the main cause is *Aspergillus flavus* (1 - 4). The disease is slowly progressive, with an indolent course and not uncommonly manifests with the symptoms that are atypical for the sinonasal region (1 - 4). Although distinctive radiological imaging can be highly suggestive for the diagnosis, crucial for the definitive confirmation is a unique histopathological finding of submucosal granulomatous inflammation (3 - 7).

Despite the chronic nature and slower progression of CGIFRS compared to AIFRS, it requires intensive treatment - a combination of endoscopic sinus surgery and early administration of systemic antifungal therapy (4 - 10). Open and radical approaches such as Caldwell-Luc, external orbitotomy, orbital exenteration, maxillectomy and craniotomy are still performed in patients with extensive disease (10 - 15). In this study, we report the first case of CGIFRS in Serbia and in addition, we present a review of the literature concerning this rare clinical entity.

CASE REPORT

An otherwise healthy 40-year-old male complained of persistent nasal obstruction and sticky mucus discharge from the nose, reduced sense of smell and facial pressure for the last five years. During that period, he was treated as nasal polyposis and underwent three non-endoscopic polypectomy procedures. The removed masses were not thoroughly microbiologically or histologically examined. After the last operation, his condition deteriorated rapidly. The patient was presented to our ENT Department with a progressive right proptosis, but without visual disturbances. His eyeball was displaced forward, downward and laterally. Nasal endoscopy showed complete obstruction of the nasal cavity with polyps and thick, sticky yellow mucus.

Fungal culture of the mucus detected the presence of *Aspergillus flavus*. Serology testing for human immunodeficiency virus, herpes simplex virus, cytomegalovirus and varicella zoster virus were negative. Galactomannan antigen enzyme-linked immunosorbent assay was also performed, and the result was higher than 0.5 (cut off 0.7). Contrast-enhanced paranasal sinus computed tomography (CT) showed soft tissue density within the nasal cavity and all paranasal sinuses, except for the left maxillary sinus which was partially pneumatized. The right ethmoid cavity mass was eroding the bones, extending into the right orbit. Also, the bone of the anterior and posterior wall of the right frontal sinus was eroded, without intracranial propagation of disease (Figures 1, 2, 3). Endoscopic sinus surgery (ESS) was performed with removal of the pale and firm tissue surrounded with mucinous discharge from the nasal cavity and paranasal sinuses. These endoscopic procedures were combined with external approach to the frontal sinuses. The mass was debrided from the frontal sinuses, skull base and orbital wall on the right side with meticulous care, without violation of the periorbita or dura. During the surgery, grumous, friable, grayish mass was revealed in the right ethmoidal cells and both frontal sinuses (Figure 4 a, b). The removed tissue was sent to histological and mycological analysis. Fungal culture of *Aspergillus flavus* was confirmed. The findings of granulomas along with fibrosis and strong inflammatory infiltrate in the lamina propria and submucosa (Fig-

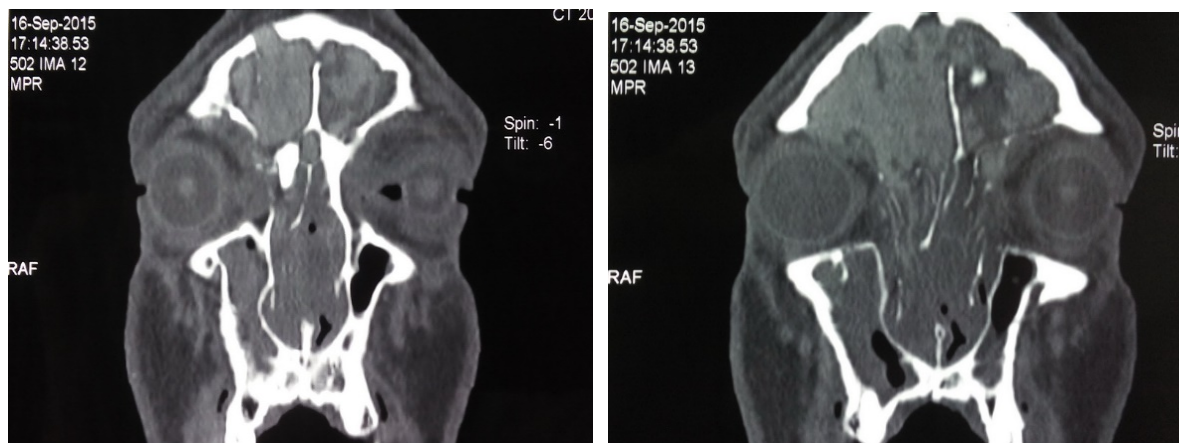


Figure 1. Enhanced CT scan in the coronal plane showing homogenous, isodense to muscle tissue opacity of the nasal cavity, ethmoid cells, frontal, right maxillary and partially left maxillary sinuses. Lamina papyracea on the right side is eroded, so the mass extends into the extraconal fat of the right orbit. Nasal septum is eroded but not destroyed. Right maxillary sinus is slightly expanded

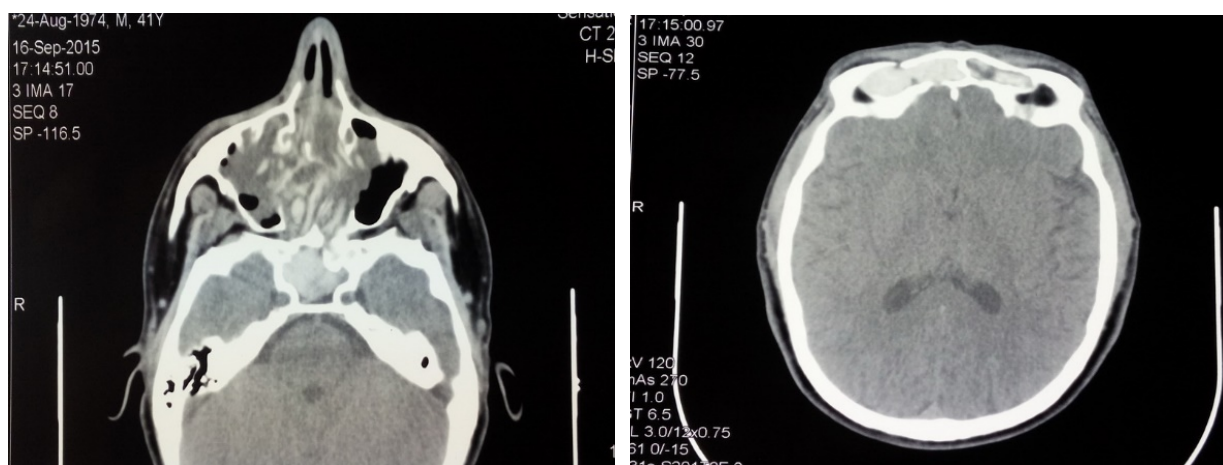


Figure 2. Enhanced CT scan in coronal plane showing heterogenous opacity with hyperattenuation areas in multiple sinuses. Medial walls of both maxillary sinuses and anterior and posterior wall of the right frontal sinus are eroded

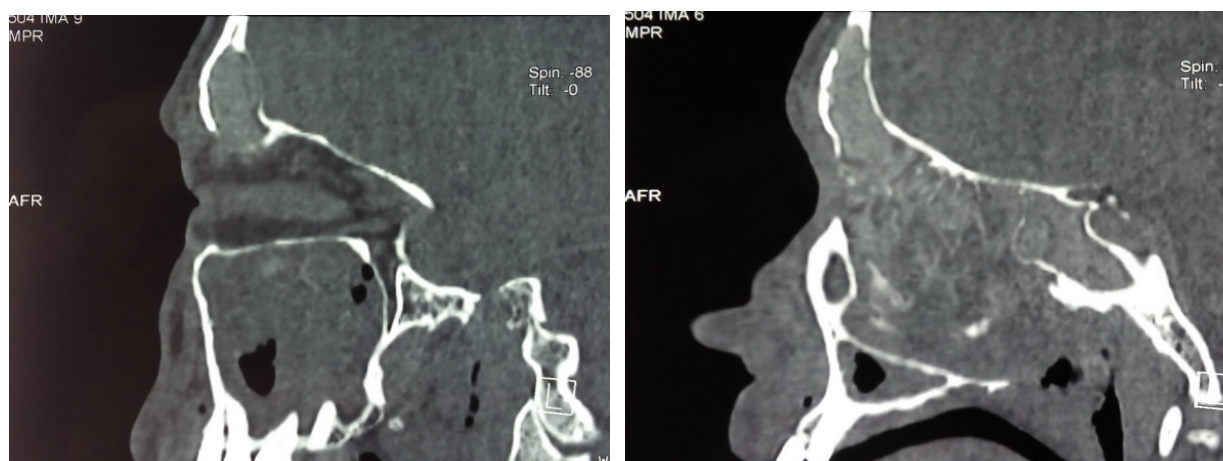


Figure 3. Enhanced CT scan in the sagittal plane showing that soft-tissue mass is filling the nasal cavity as well as all the surrounding paranasal sinuses. Bone erosion of the anterior and posterior wall of the right frontal sinus is clearly visible

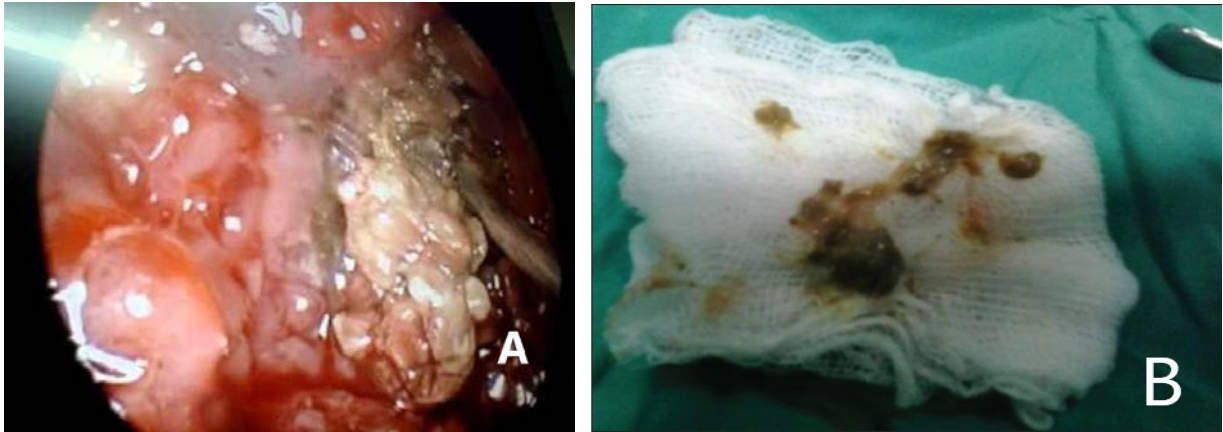


Figure 4. A- intraoperative endoscopic appearance of the disease showing the mass occupying the right ethmoid sinus. B – black-and-greyish brittle mass in sticky, thick fungal debris

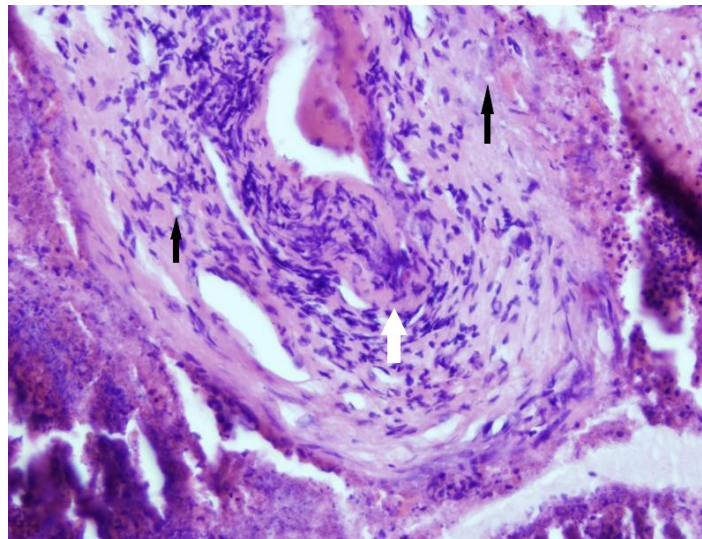


Figure 5. Photomicrograph, showing giant cell granulomas (white arrows) with grey fungal spores (black arrows) (hematoxylin and eosin staining, original magnification x 40)

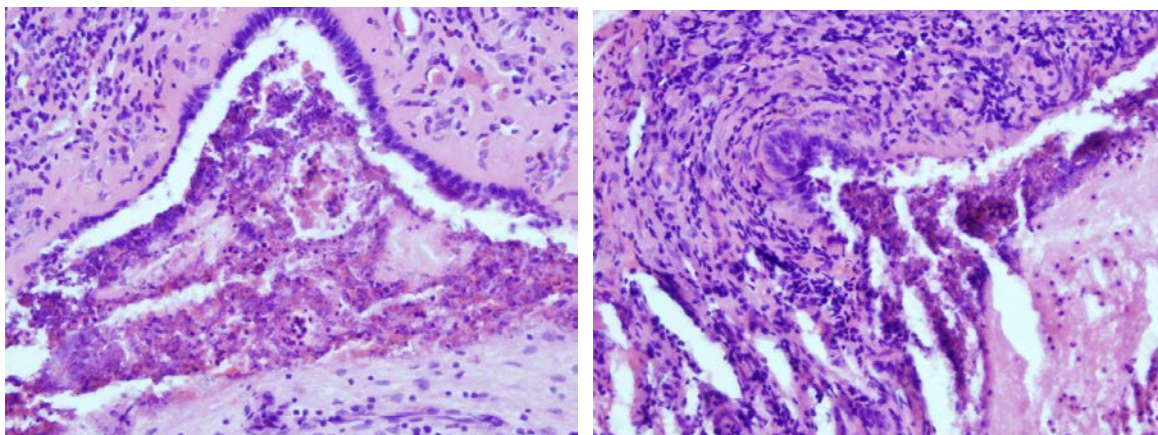


Figure 6. Granulomatous reaction toward *Aspergillus flavus* (Hematoxylin and eosin staining, original magnification x 25)

ures 5 and 6) were typical for the diagnosis of CGIFRS. Postoperatively, oral voriconazole in the dose of 200 mg/day was administered for nine months. During outpatient follow-up, several nasal endoscopies were performed. The patient remained asymptomatic and disease-free one year after the initial presentation to date.

DISCUSSION

Non-invasive fungal disease clinically behaves like chronic sinusitis, while the invasive one, in which the infection is spreading into mucosa, blood vessels and bones, results in a mass that behaves like malignant neoplasm (7, 10). Compared with an acute invasive form, chronic invasive fungal rhinosinusitis (CIFRS) and CGIFRS are rare (8, 9). A common characteristic of both chronic forms is a long and indolent clinical course, usually slowly progressing over months or years (3, 5, 10). Severe complications can be found in both forms as early manifestations, including cranial infections, blindness and even death (5). Although these forms share a significant number of common features, a consensus was reached in 2009 when the CIFRS and CGIFRS forms had enough clinical and pathological differences to be categorized as distinct entities (3-10). The differences between CGIFRS and CIFRS are presented in Table 1.

CGIFRS represents an important diagnostic and therapeutic challenge for the clinician because of its rarity, atypical clinical signs and symptoms, unclear pathogenesis and lack of defined treatment guidelines. By literature review, we have noticed that it took months or rather years for physicians to establish the diagnosis of CGIFRS. Several articles analyzed case series and revealed that the duration of symptoms ranged from 4 to 30.6 months (5, 10, 15). In our case, the patient had complained for five years before he got an adequate diagnosis and treatment. There are several possible reasons for the delay in identifying the disease. The fact that infection is commonly presented in middle-aged immunocompetent patients is what finds physicians unprepared for the diagnosis of invasive fungal infection. We suspect of fungi when we know that we have a patient with suppression of the immune system (diabetes mellitus, malignancy, during chemotherapy or corticosteroid treatment) as a predisposition to invasive disease. It was believed that immune system dysfunction is what allows fungi to

penetrate normal mucosal barriers and to invade host tissues. That outdated belief is one of the reasons why the diagnosis is delayed worldwide. Our patient had no medical history. Laboratory findings and serological analysis showed no immunodeficiency.

Most affected are people from Sudan, India and Middle East where the prevalence among fungal sinusitis is somewhat high (20%), and that to the certain extent is rising the awareness of CGIFRS compared to the western countries where the prevalence of 0.5% rarely prompts the clinician to think of it (8, 9). For the long time it was considered as a geographical or ethnicity-related entity, but some articles revealed its scarce presence in western countries and the Far East as well (5, 12, 13).

The disease mainly involves the maxillary and ethmoid sinuses, nasal cavity and orbit (4, 7, 15). Clinically, a patient with CGIFRS might have all the symptoms of chronic rhinosinusitis (nasal congestion, mucus discharge and postnasal drip, reduced sense of smell, facial pain or pressure). Because of this deceptive nasal symptoms and signs, it is often mistaken for "usual" chronic rhinosinusitis (8 - 10). Similar to that finding, our patient had complained of nasal obstruction, discharge, crusting and nasal polyps for five years and he had been treated for having nasal polyposis before he was referred to our institution.

Another frequent observation in the available data is also the relative lack of nasal symptoms in this atypical sinonasal disease. The commonest presenting symptoms in the literature were manifestations of orbital and intracranial involvement - proptosis, visual deterioration, infraorbital swelling, severe headache, facial pain, seizures, cranial nerve palsy and focal neurologic deficits which led the patients to the ophthalmologist or neurosurgeon and additionally delayed the diagnosis (10, 14, 15). It is not uncommon that patients with CGIFRS are misdiagnosed as having paranasal, orbital or intracranial malignancy. Adulkar et al. (14) in their case series of 21 patients with CGIFRS reported that differential diagnosis, besides malignancy, included temporal arteritis, optic neuritis, idiopathic orbital inflammatory syndrome, orbital apex syndrome and typical bacterial cellulitis/orbital abscess. About 40% of their patients received corticosteroids for presumed chronic nonspecific inflammatory disease, which only led to worsening of the condition (14, 15). Our patient's rapidly developed proptosis, and

considering the symptomatology and previous treatment, it was interpreted as a complication of chronic sinusitis.

Physicians should be aware of atypical manifestations of this rare disease for a well-timed diagnosis.

Typical radiological finding in CGIFRS is homogenous opacity that is isodense or slightly hyperdense as compared to muscle on CT enhanced with contrast and intermediate signal intensity on T1-weighted and low signal intensity on T2-weighted contrast MR images. Hyperattenuation areas are rare. Involvement is limited to one or two sinuses which are not expanded and bone erosion is localized next to the area of extra-sinus extension. It is not uncommon that the extra-sinus component of the disease is greater than the intra-sinus component (7).

Rupa et al. (4) have categorized patients with CGIFRS into three groups, based on the radiological extent of the disease. Patients in stage 1 are those with completely resectable disease confined to the nose and paranasal sinuses; stage 2 refers to patients with completely resectable disease with extension to the adjacent areas (orbit, palate, oral cavity), while stage 3 relates to patients with partially resectable disease that extends to the cheek, pterygopalatine fossa, periorbital area, cavernous sinus, or brain (4).

Radiological images of our patient showed involvement of almost all paranasal cavities, significant bone erosion and expansion into the right orbit. These findings can be explained with possible simultaneous coexistence with other types of fungal sinusitis, particularly allergic fungal sinusitis, which is well documented in the literature (2, 13, 15).

Definitive confirmation of CGIFRS should be done by both microbiological and histopathological methods (1, 2, 15). The causative agent is typically *Aspergillus flavus*, which was isolated from our patient's nasal mucus swab. Some authors emphasize that CGIFRS is the histopathological diagnosis (5, 11). Distinctive is the presence of non-caseating granulomas that consists of numerous multinucleated foreign bodies or Langhans-type giant cells and fewer epithelioid cells, lymphocytes, plasma cells, eosinophils, and neutrophils. There are always considerable fibrosis and vascular proliferation. Fungal hyphae invading the tissue are usually sparse (1, 2, 6, 15). Discovery of granulomatous response and fibrosis in surgically removed sinus specimen of our patient played a crucial role in the decision on further treatment.

Immunologic basis for the development of CGIFRS is unclear. It was believed that Th-17 cells are responsible for the mucosal fungal immunity. However, some studies have shown that T-cell dysregulation - failure to reduce Th-17 cells in favor of a Th-1 response, results in increased localized inflammation that is greater than that required for successful removal of a fungal pathogen (6). Consequential excessive chemoattraction of polymorphic cells causes localized mucosal inflammation and failure to clear an invasive fungal infection (6).

The ideal therapy approach depends on several influencing factors such as the degree of tissue invasion and patient comorbidities, thus every delay in the diagnosis leads to radical and disfiguring surgery. Rupa et al. (4) recommended antifungal and surgical therapy according to the disease stage. For stage 1 and stage 2, they recommended surgery followed by azole derivatives (6 - 9 months). For patients in the third stage, a combination of ESS and open approach and/or craniofacial resection, followed by oral/parenteral antifungal therapy (6 - 9 months) are adequate. Topical antifungal therapy has been introduced by some authors as an adjuvant therapy with excellent outcomes (10). According to this categorization, our patient was in stage 2 when he was admitted to our clinic. Applied therapy, ESS surgery and oral administration of voriconazole led to complete resolution of the disease.

Although Rupa et al. (15) reported complete disease regression or clinical improvement in the majority of patients in reviewed case series (91.3%), it is important to indicate that progressive disease despite therapy was seen in 8.6% of patients. In six studies they reviewed, mortality ranged from 5.7% to 22.2%. Recurrence was verified in three studies, with a mean rate of 14.3% (15). To date, we have not found a recurrence of the disease in our patient.

CONCLUSION

CGIFRS presents a serious diagnostic and therapeutic challenge. It is primarily caused by *Aspergillus flavus* and is mainly found in Africa and Southeast Asia. Often, CGIFRS presents with mass involving the nose and paranasal sinuses, while orbital and endocranial extension are mimicking malignancy. Histological examination is necessary for the final diagnosis. The finding of granulomatous response along with fibrosis and strong inflammatory infiltrate is typical for the CGIFRS. Delayed

diagnosis is typical for this clinical entity. Although we reported the first case of CGIFRS in Serbia, it is important to suspect it in all cases where chronic inflammation of the paranasal sinuses does not respond to conventional treatment.

Conflict of Interest

The authors declare no conflict of interest regarding the content of this paper.

References

1. DeShazo RD, Chapin K, Swain RE. Fungal sinusitis. *N Eng J Med* 1997; 337: 254-9. [NEJM] <https://doi.org/10.1056/NEJM199707243370407>
2. Chakrabarti A, Denning DW, Ferguson BJ, et al. Fungal rhinosinusitis: a categorization and definitional schema addressing current controversies. *Laryngoscope* 2009;119(9):1809-18. <https://doi.org/10.1002/lary.20520>
3. Deutsch PG, Whittaker J, Prasad S. Invasive and Non-Invasive Fungal Rhinosinusitis-A Review and Update of the Evidence. *Medicina (Kaunas)* 2019;55(7):319. <https://doi.org/10.3390/medicina55070319>
4. Rupa V, Maheswaran S, Ebenezer J, Mathew SS. Current therapeutic protocols for chronic granulomatous fungal sinusitis. *Rhinology* 2015;53(2):181-6. <https://doi.org/10.4193/Rhino14.183>
5. Zhou LH, Wang X, Wang RY, et al. Entities of Chronic and Granulomatous Invasive Fungal Rhinosinusitis: Separate or Not? *Open Forum Infect Dis* 2018;5(10):ofy228. <https://doi.org/10.1093/ofid/ofy228>
6. Rae W, Doffinger R, Shelton F, et al. A novel insight into the immunologic basis of chronic granulomatous invasive fungal rhinosinusitis. *Allergy Rhinol (Providence)* 2016; 7(2):102-6 <https://doi.org/10.2500/ar.2016.7.0162>
7. Reddy CEE, Gupta AK, Singh P, Mann SBS. Imaging of granulomatous and chronic invasive fungal sinusitis: Comparison with allergic fungal sinusitis. *Otolaryngol-Head Neck Surg* 2010;143:294-300. <https://doi.org/10.1016/j.otohns.2010.02.027>
8. Montone KT, Livolsi VA, Feldman MD, et al. Fungal Rhinosinusitis: A Retrospective Microbiologic and Pathologic Review of 400 Patients at a Single University Medical Center. *Int J Otolaryngol* 2012; <https://doi.org/10.1155/2012/684835>
9. Sharif MS, Ali S, Nisar H. Frequency of Granulomatous Invasive Fungal Sinusitis in Patients with Clinical Suspicion of Chronic Fungal Rhinosinusitis. *Cureus* 2019;11(5):e4757. <https://doi.org/10.7759/cureus.4757>
10. Alarifi I, Alsaleh S, Alqaryan S, et al. Chronic Granulomatous Invasive Fungal Sinusitis: A Case Series and Literature Review. *Ear Nose Throat J* 2021;100(5_Suppl):720S-727S. <https://doi.org/10.1177/0145561320904620>

11. Singh AK, Gupta P, Verma N, et al. Fungal rhinosinusitis: microbiological and histopathological perspective. *J Clin Diagn Res* 2017;11(7):DC10-DC12.
<https://doi.org/10.7860/JCDR/2017/25842.10167>
12. Busaba NY, Colden DG, Faquin WC, Salman SD. Chronic invasive fungal sinusitis: a report of two atypical cases. *Ear Nose Throat J* 2002; 81:462-6.
<https://doi.org/10.1177/014556130208100713>
13. Currens J, Hutcheson PS, Slavin RG, Citardi MJ. Primary paranasal *Aspergillus* granuloma: case report and review of the literature. *Am J Rhinol* 2002;16:165-8.
<https://doi.org/10.1177/194589240201600308>
14. Adulkar NG, Radhakrishnan S, Vidhya N, Kim U. Invasive sinoorbital fungal infections in immunocompetent patients: a clinico-pathological study. *Eye* 2019;33:988-94.
<https://doi.org/10.1038/s41433-019-0358-6>
15. Rupa V, Peter, Michael JS, Thomas M, Irodi A, Rajshekhar V. Chronic granulomatous invasive fungal sinusitis in patients with immunocompetence: A Review. *Otolaryngol Head Neck Surg* 2023;168(4):669-80
doi: 10.1177/01945998221097006. Online ahead of print.
<https://doi.org/10.1177/01945998221097006>

Article info

Received: May 15, 2022

Revised: August 29, 2022

Accepted: September 20, 2022

Online first: April 24, 2023

Hronični granulomatozni invazivni gljivični sinusitis: pregled literature i prikaz slučaja netipičnog za balkansku regiju

Milica Labus¹, Jelena Sotirović², Biserka Vukomanović Đurđević³, Aleksandar Perić²

¹Vojnomedicinska akademija, Departman za otorinolaringologiju, Beograd, Srbija

²Univerzitet odbrane, Medicinski fakultet Vojnomedicinske akademije, Departman za otorinolaringologiju, Beograd, Srbija

^{2,3}Univerzitet odbrane, Medicinski fakultet Vojnomedicinske akademije, Institut za patologiju, Beograd, Srbija

SAŽETAK

Uvod. Hronični granulomatozni invazivni gljivični rinosinusitis (HGIGRS) je izuzetno redak oblik invazivnog gljivičnog sinusitisa. Bolest ima hroničan i podmukao tok, te invazija i destrukcija u sinonazalnom regionu i susednim regionima sporo napreduju. Oboljenje se obično javlja u regionu Bliskog istoka, severne Afrike, Indije i Pakistana; veoma se retko verifikuje u zapadnim zemljama. Najčešće ga izaziva *Aspergillus flavus*.

Prikaz slučaja. Četrdesetogodišnji muškarac, koji je u više navrata hirurški lečen zbog hroničnog polipoznog rinosinusitisa, javio se na našu Klinku za otorinolaringologiju sa progresivnom, naglo nastalom desnostranom proptozom. Kompjuterizovana tomografija (CT) paranazalnih šupljina sa kontrastom pokazala je sadržaj denziteta mekog tkiva, koji je gotovo u potpunosti ispunio sinonazalnu regiju, erodirao koštane strukture i proširio se u desnu orbitu. Viđena je i erozija zidova desnog frontalnog sinusa, bez intrakranijalne propagacije. Za postavljanje definitivne dijagnoze bio je neophodan histopatološki pregled. Nalaz granulomatoznog odgovora sa fibrozom i izraženim inflamatornim infiltratom bio je tipičan za hronični granulomatozni invazivni gljivični sinusitis. Bolesnik je uspešno izlečen kombinacijom operativnog lečenja i postoperativno ordiniranog vorikonazola.

Prema našim saznanjima, ovo je prvi slučaj HGIGRS evidentiran u Srbiji.

U radu smo se osvrnuli i na literaturu o ovom retkom obliku invazivnog gljivičnog sinusitisa, posebno za region Balkana.

Zaključak. Iako je opisani slučaj gljivičnog sinusitisa izuzetno redak za region Balkana, važno je posumnjati na njega u svim slučajevima u kojima hronična inflamacija paranazalnih sinusa ne reaguje na konvencionalno lečenje.

Ključne reči: granuloma, inflamacija, mikoze, rinohirurške procedure, sinusitis, vorikonazol