

Case report

Perimandibular Metastasis of Rectal Cancer: A Case Report

Miljana Džunić¹, Ana Cvetanović^{1,2}, Ivan Petković^{1,2}

¹University Clinical Centre Niš, Clinic of Oncology, Niš, Serbia

²University of Niš, Faculty of Medicine, Niš, Serbia

SUMMARY

Introduction. Colorectal cancer is the third most common cancer and metastatic disease is an important and frequent clinical problem. Metastases in the oral and maxillofacial region are rare, comprising 1 - 2% of all malignant lesions, and clinically resemble common benign conditions.

Case report. A 59-year-old woman diagnosed with rectal cancer developed perimandibular lesion as a first sign of metastatic process. Metastasis manifested clinically during the curative intent treatment of rectal cancer (preoperative chemo-irradiation) as a rapidly growing tumefaction close to the mandible angle. After the biopsy and histopathological examination of the lesion that clinically resembled abscess, metastasis of rectal cancer was diagnosed. Incidentally, a cerebral metastasis was diagnosed as well. Although it was oligometastatic rectal cancer, surgical treatment was not indicated due to extensive infiltrative characteristics of the perimandibular lesion. The patient was treated with chemotherapy, with good clinical response. Biological therapy was not available at that moment. Cerebral metastasis was treated with stereotactic neuroradiosurgery with gamma knife. Unfortunately, the patient died from cerebrovascular insult.

Conclusion. Lesions in the oral and maxillofacial region may be the first manifestation of metastatic disease. Since early diagnosis of metastatic process has prognostic implications, any new formation in the oral and maxillofacial region in a patient with colorectal cancer requires cautious observation and histological examination.

Keywords: colorectal cancer, perimandibular metastasis, cerebral metastasis

Corresponding author:

Miljana Džunić

e-mail: drmdzunic@gmail.com

INTRODUCTION

Colorectal cancer (CRC) is the third most common cancer, diagnosed in 11% of cancer patients worldwide. Metastatic disease develops in more than a half of patients, with 20% being in stage IV at the time of diagnosis (1). The most frequent sites of CRC metastases are the liver and lungs. Metastatic disease is commonly treated with systemic therapy (chemotherapy, biological therapy). However, loco-regional treatment modalities, such as surgery and radiotherapy, may be added as well in order to improve prognosis, and sometimes even cure the patient (2).

Maxillofacial and oral region are uncommon sites for metastatic cancer, comprising 1 - 2% of all cancerous lesions. The most frequent are metastases from breast, lung and kidney cancer, commonly affecting posterior mandible and gingiva (3). Metastases in the oral and maxillofacial region can have various clinical presentations, often mimicking inflammatory benign processes that are common in

this area (4). The only way to make accurate diagnosis of the lesion in this region is histopathology with immunohistochemistry of the biopsied material.

This report presents the patient with perimandibular metastasis of rectal cancer and reviews the literature about CRC metastases in the oral and maxillofacial region.

CASE REPORT

A 59-year-old woman was diagnosed with adenocarcinoma of the rectum, 6 cm from the anal verge. Her daughter died from cancer of the ascending colon at the age of 30, however, Lynch syndrome was not proved by genetic testing. Magnetic resonance imaging (MRI) of the pelvis revealed that the tumor propagated up to the sigmoid colon, with circularly luminal spread, without perirectal adipose tissue infiltration and without affection of the mesorectal fascia. The tumor was staged cT3N1b. Multi-slice computed tomography (MSCT) of the

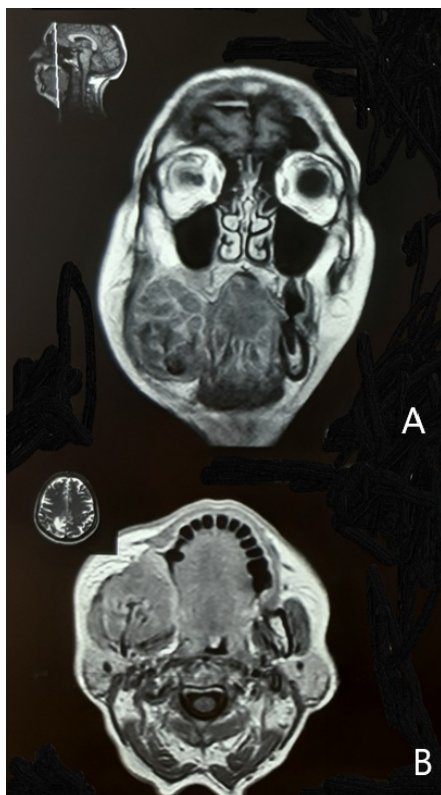


Figure 1. MRI of the head, showing perimandibular metastasis in the coronal (A) and axial (B) plane

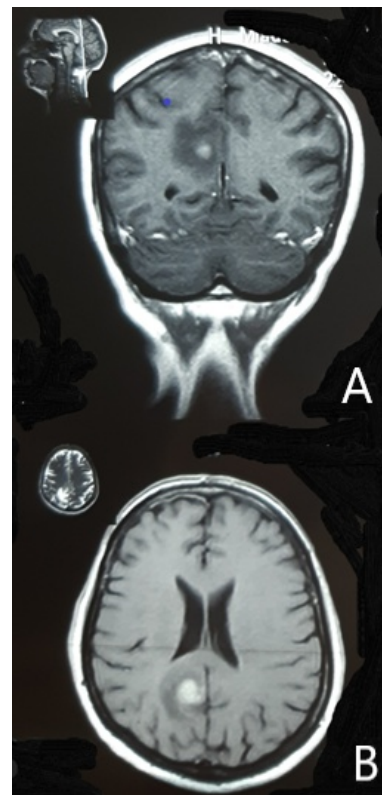


Figure 2. MRI of the endocranium, showing cerebral metastasis in the coronal (A) and axial (B) plane

thorax and abdomen showed no metastatic deposits.

After sigmoidostomy due to obstructive symptoms, she started preoperative long-course concomitant chemoradiotherapy. The patient was prescribed 50,4 grays in 28 fractions together with two courses of 5-fluorouracyl/leucovorin chemotherapy. During the treatment, the patient felt pain and noticed swelling and induration in the area of the right mandible angle. After the dental examination, an abscess was diagnosed and treated with incision and antibiotic. Even though a short improvement was achieved, eventually pain worsened, numbness of the chin appeared, the swelling enlarged and become visible on the face. The patient had difficulties in eating because of trismus. MRI of the head presented the tumor 60 mm in diameter that surrounded and infiltrated the right mandible, laterally infiltrated the muscles of the lateral mandible margin, medially propagated up to the muscles of the base of the oral cavity and the tongue, caudally infiltrated the parapharyngeal muscles, posterior came up to the parotid gland and cranially infiltrated the maxilla (Figure 1). An incidental finding was a solitary cerebral metastasis in the parietal lobe, of 13 mm in diameter, with perilesional edema (Figure 2), which was asymptomatic.

The biopsy of perimandibular tumefaction was performed. Histopathology revealed atypical glandular formations in cribriform arrangement, necrosis and hemorrhage. Immunohistochemistry (CDX2 positive, CK20 focally positive and CK7 negative) was suggestive of colorectal origin.

The patient started four cycles of FOLFOX4 chemotherapy (oxaliplatin, leucovorine and 5-fluorouracyl in bolus and continuous iv infusion), after which the symptoms of pain and difficulties in chewing disappeared. Biological treatment (bevacizumab, cetuximab) which could improve response and improve prognosis was not available in that moment. Stereotactic radio-neurosurgical intervention with gamma-knife was performed for cerebral metastasis. We proposed the FOLFOX4 treatment continuation. Unfortunately, the patient had neurological symptoms and died from cerebrovascular insult six months after being diagnosed with metastatic disease.

DISCUSSION

Despite the improvement in early diagnosis and treatment of CRC, metastatic disease remains challenging. Even though metastases are common, metastatic process itself is not completely elucidated. Well known rough anatomical-mechanical and the seed-and-the-soil hypotheses are replaced by the theories of complex genetic alterations of tumor cells and their interaction with the tumor microenvironment. Newer insights in metastatic process offer evidence for early metastatic seeding in colorectal cancer, while the primary tumor is still clinically undetectable (5).

Oral and maxillofacial metastases are rather late manifestation of malignant disease, associated with multiple metastatic sites. Clinical appearance resembles common benign conditions in the oral cavity, such as granulomas or odontogenic infections. Common clinical symptoms include swelling, pain, ulceration, tooth extraction, trismus, chewing and swallowing difficulties. „Mental nerve neuropathy“ or „numb chin syndrome“ are the signs of mandible affection and infiltration of mental or inferior dental nerves, described in cancer patients (3, 4). However, neither clinical appearance nor symptoms are specific for the metastatic process.

Although traditionally considered as one disease, rectal cancer shows characteristic metastatic pattern compared to colon cancer. Rectal cancer spreads more frequently to the thoracic organs (odds ratio 2,5) and to the nervous system (odds ratio 1,5), and less frequently to the peritoneum, compared to colon cancer. Central nervous system metastases are present in 5% of patients with rectal cancer, commonly associated with lung metastases and with poor prognosis (6).

The patient from this report developed unusual fast-growing tumefaction in the perimandibular region, initially misdiagnosed as abscess, and treated accordingly. When the dental treatment failed, an MRI finding pointed to the advanced infiltrative lesion, and pathology proved metastasis. This was the first manifestation of metastatic disease, which appeared during curative intent treatment of primary rectal cancer. The brain metastasis was diagnosed incidentally, while it was asymptomatic.

The diagnosis of metastases changes the therapeutic approach from locoregional (primary tumor-directed) to systemic treatment. In the case of oligometastatic disease, where a few organs are affected with a limited number of metastatic deposits, the treatment goal should be complete surgical removal of all metastatic sites whenever possible (2), since it proved to improve the prognosis for patients. Therefore, early diagnosis of metastatic disease, while still resectable, is of great importance. The presented case was very unusual oligometastatic rectal cancer, since maxillofacial lesion and solitary cerebral metastasis may be treated with curative intent. However, aggressive biologic characteristics of the disease and advanced perimandibular metastatic process required systemic treatment from the start. If the diagnostic process of metastatic lesion had been faster, maybe there would be more curative treatment possibilities.

A literature review found 25 case reports of oral and maxillofacial metastases of CRC (Table 1). Metastases of CRC could be found in different facial bones and different parts of the oral soft tissue. The most frequent bone localization is the mandible, and the most common affected soft tissue is gingival (7, 8). In the majority of patients the primary cancer was colon cancer (9, 10). Orofacial metastases appeared

from 9 months to 15 years after the primary tumor diagnosis, and in 9 cases metastases appeared simultaneously with primary cancer, frequently together at other metastatic sites. However, in 4 patients, the oral/maxillofacial lesion was the only metastatic site. Metastases to the oral and maxillofacial region could sometimes be the first sign of colorectal cancer (11). Treatment of oral and maxillofacial metastatic disease was multidisciplinary, consisting of chemotherapy, radiotherapy and surgery as well (5 cases) (4), unfortunately without long-term success.

CONCLUSION

Metastases to the oral and maxillofacial region could be the first sign of metastatic rectal cancer. Due to clinical similarity with common inflammatory processes, they are often underdiagnosed. Since the early diagnosis of metastases interferes with prognosis of colorectal cancer patients, any new forming lesion in the oral and maxillofacial region in a patient with CRC should be cautiously examined and biopsy should be performed.

Conflict of interest

The author declares no conflict of interest.

References

1. Bray F, Ferlay J, Soerjomataram I et al. Global cancer statistics 2018: GLOBOCAN estimates of incidence and mortality worldwide for 36 cancers in 185 countries. *CA Cancer J Clin* 2018; 68(6):394-424.
<https://doi.org/10.3322/caac.21492>
2. Yoshino T, Arnold D, Taniguchi H et al. Pan-Asian adapted ESMO consensus guidelines for the management of patients with metastatic colorectal cancer: a JSMO-ESMO initiative endorsed by CSCO, KACO, MOS, SSO and TOS. *Ann Oncol* 2018; 29(1):44-70.
<https://doi.org/10.1093/annonc/mdx738>
3. Kirschnick LB, Schuch LF, Cademartori MG et al. Metastasis to the oral and maxillofacial region: A systematic review. *Oral Dis* 2022; 28(1):23-32.
<https://doi.org/10.1111/odi.13611>
4. Neumann ED, León Vintró X, Vega García C et al. Oral cavity colon adenocarcinoma metastases: case report with surgical approach and review of more than 30 years literature. *Oral Maxillofac Surg* 2021; 25(1):99-101.
<https://doi.org/10.1007/s10006-020-00887-y>
5. Hu Z, Ding J, Ma Z et al. Quantitative evidence for early metastatic seeding in colorectal cancer. *Nat Genet* 2019; 51(7):1113-22.
<https://doi.org/10.1038/s41588-019-0423-x>
6. Brouwer NPM, van der Kruijssen DEW, Huguen N et al. The impact of primary tumor location in synchronous metastatic colorectal cancer: differences in metastatic sites and survival. *Ann Surg Oncol* 2020; 27(5):1580-8.
<https://doi.org/10.1245/s10434-019-08100-5>
7. Baranović M, Vidaković B, Sauerborn D et al. Colorectal Adenocarcinoma Metastasizing to the Oral Mucosa of the Upper Jaw. *Srp Arh Celok Lek* 2015;143(5-6):314-6.
<https://doi.org/10.2298/SARH1506314B>
8. Hadhri A, Abidi R, Ben Rejeb M et al. Metastasis of colon adenocarcinoma to the mandible: A case report. *Tunis Med* 2020;98(6):518-21.
9. Romanet I, Lan R, Ordioni U et al. A rare case of oral metastasis of colon adenocarcinoma. *J Stomatol Oral Maxillofac Surg* 2018;119(3):229-31.
<https://doi.org/10.1016/j.jormas.2018.02.003>
10. Dalirsani Z, Mohtasham N, Samiee N. Metastasis of Colon Adenocarcinoma to Maxillary Gingiva and Palate. *Iran J Otorhinolaryngol* 2020;32(112):327-31.
<https://doi.org/10.22038/ijorl.2020.42693.2394>
11. Salvador JC, Rosa D, Rito M et al. Atypical mandibular metastasis as the first presentation of a colorectal cancer. *BMJ Case Rep* 2018;2018:bcr2018225094.
<https://doi.org/10.1136/bcr-2018-225094>

Article info

Received: June 19, 2022

Accepted: February 11, 2023

Online first: October 30, 2023

Perimandibularna metastaza karcinoma rektuma: prikaz slučaja

Miljana Džunić¹, Ana Cvetanović^{1,2}, Ivan Petković^{1,2}

¹Univerzitetski klinički centar Niš, Klinika za onkologiju, Niš, Srbija

²Univerzitet u Nišu, Medicinski fakultet, Niš, Srbija

SAŽETAK

Uvod. Kolorektalni karcinom je treći malignitet po učestalosti, a metastatska bolest predstavlja značajan i čest klinički problem. Metastatski tumori oralne i maksilofacijalne regije su retki – čine 1–2% svih malignih lezija – i klinički nalikuju uobičajenim benignim stanjima.

Prikaz slučaja. Žena stara 59 godina, sa dijagnozom karcinoma rektuma, razvija perimandibularnu leziju kao prvi znak metastatskog procesa. Metastaza se klinički manifestovala u toku tretmana sa ciljem izlečenja karcinoma rektuma (preoperativna hemioiradijacija) u vidu brzorastućeg tumefakta blizu mandibularnog ugla. Nakon biopsije i patohistološke verifikacije lezije koja je klinički nalikovala apscesu, dijagnostikovana je metastaza karcinoma rektuma. Uzgred je otkrivena i solitarna metastaza u mozgu. Iako je ovo slučaj oligometastatskog karcinoma rektuma, hirurški tretman nije bio indikovano zbog ekstenzivnosti perimandibularnog metastatskog procesa. Bolesnica je lečena hemioterapijom, sa dobrim kliničkim odgovorom. Biološka terapija u tom momentu nije bila dostupna. Cerebralna metastaza tretirana je stereotaktičkom neuroradihirurgijom korišćenjem gama noža. Nažalost, bolesnica je umrla od posledica cerebrovaskularnog insulta.

Zaključak. Lezije u oralnoj i maksilofacijalnoj regiji mogu biti prvi znak metastatske bolesti. S obzirom na to da rana dijagnoza metastatskog procesa ima prognostičke implikacije, svaka nova formacija u oralnoj i maksilofacijalnoj regiji kod bolesnika sa kolorektalnim karcinomom zahteva pažljivu opservaciju i histološko ispitivanje.

Ključne reči: kolorektalni karcinom, perimandibularna metastaza, cerebralna metastaza