

Primljen/ Received on 20.11.2012.
Revidiran/ Revised on 27.11.2012
Prihvaćen/ Accepted on 1.12.2012

KLINIČKI RAD
CLINICAL ARTICLE
doi:10.5937/asn1266191B

ASIMETRIJA U RAZVOJU (MINERALIZACIJE) KORENOVA MANDIBULARNIH STALNIH OČNJAKA

ASYMMETRY IN DEVELOPMENT (MINERALISATION) OF PERMANENT MANDIBULAR CANINE ROOTS

Mirjana V. Burić¹, Ljiljana D. Tijanić², Predrag M. Janošević²,
Gordana Lj. Filipović², Donka K. Stojanović¹

¹KLINIKA ZA STOMATOLOGIJU NIŠ, ODELJENJE ZA ORTOPEDIJU VILICA,
²UNIVERZITET U NIŠU, MEDICINSKI FAKULTET, NIŠ, SRBIJA

¹CLINIC OF DENTISTRY NIŠ, DEPARTMENT OF ORTHODONTICS, ²UNIVERSITY OF NIŠ FACULTY OF MEDICINE, NIŠ, SERBIA

Sažetak

Uvod. Razvoj zuba usko je povezan sa pravilnim i neometanim telesnim i psihičkim razvojem deteta.

Cilj. Utvrđivanje postojanja asimetrija u razvoju korena donjih stalnih očnjaka u različitim uzrastima dece oba pola.

Materijal i metode. Istraživanje je obavljeno na ortopantomografskim snimcima 523 deteta (253 dečaka i 270 devojčica) uzrasta od 6 do 14 godina, ortodontskih pacijenata Klinike za stomatologiju u Nišu. Analizirana je asimetričnost u razvoju korena donjih stalnih očnjaka metodom po Gleiser-u i Hunt-u, odnosno modifikacijom po Tijaniću (1981).

Rezultati. Utvrđeno je da je asimetrija u razvoju korena donjih očnjaka kod oba pola prisutna kod 20 ispitanika (3,82%), kod 10 dečaka (3,95%) i 10 devojčica (3,70%). Razlika se kreće u granicama jednog stadijuma. Asimetričan razvoj korena donjih očnjaka kod devojčica i dečaka najčešće je prisutan u 7. i 8. stadijumu (kod devojčica 60%, a kod dečaka 50%). Kod 90% devojčica asimetrija u razvoju korena donjeg očnjaka prisutna je u okviru jednog stadijuma, a kod 10% devojčica prisutna je u okviru tri stadijuma. Asimetričan razvoj korena donjeg očnjaka najčešći je u 7. i 8. stadijumu razvoja (55%).

Zaključak. Asimetričan razvoj korena donjeg stalnog očnjaka utvrđen je kod 3,82% ispitanika. Više od polovine ispitanika (55%) imalo je asimetričan razvoj korena očnjaka u stadijumu polovine i tri četvrtine ukupne dužine korena. Rezultati ove studije ukazuju da je očnjak zub sa veoma malo varijacija u svom razvoju.

Ključne reči: donji očnjak, razvoj korena, mineralizacija, asimetrija

Abstract

Introduction. The development of the teeth is closely associated with the proper and unobstructed physical and psychological development of the child.

Aim. To determine the existence of asymmetry in the development of the roots of the lower permanent canine teeth in different age groups of children of both sexes.

Material and methods. The study was conducted on 523 orthopantomograms (253 boys and 270 girls) of orthodontic patients aged 6 to 14 years of the Dental Clinic in Niš. We analyzed the development of asymmetry in the lower permanent canine root, using the method of Gleiser and Hunt, or the modification by Tijanić (1981).

Results. It was found that asymmetry in the development of the root in both sexes of the lower canine teeth was present in 20 patients (3.82%), 10 boys (3.95%) and 10 girls (3.70%). The difference is in the range of one stage. Asymmetric development of the roots of the lower incisors in girls and boys usually present in the 7th and 8th stages (60% in girls and in 50% in boys). In 90% of girls in developing asymmetry the root of the lower canine is present in a single stage, and in 10% of girls it presents within three stages. Asymmetric development of the root of the lower canine is the most common in the 7th and 8th stages of development (55%).

Conclusion. Asymmetric root development of permanent lower canines was found in 3.82% of patients. More than half of respondents (55%) had asymmetrical canine root development stage in half and three quarters of the total root length. The results of this study indicate that the canine is the tooth with very little variations in its development.

Key words: lower canine, root development, mineralization, asymmetry

Uvod

Razvoj zuba je usko povezan sa pravilnim i neometanim telesnim i psihičkim razvojem deteta. Rast ljudskog organizma karakteriše se značajnom varijabilnošću, kako u stepenu rasta

Introduction

Tooth development is closely connected with the proper and unobstructed physical and psychological development of the child. The

Address for correspondence:

Mirjana V. Burić, DDS
Clinic of Dentistry Niš, Department of Orthodontics
Bulevar Dr Zoran Đinđić 52
18000 Niš, Serbia
e-mail: nburic@yahoo.com

© 2011 Faculty of Medicine in Niš. Clinic of Dentistry in Niš. All rights reserved / © 2011 Medicinski fakultet Niš. Klinika za stomatologiju Niš. Sva prava zadržana

tako i u napredovanju različitih osoba ka biološkoj zrelosti^{1,2}. Gleiser i Hunt³, svojim rendgen ispitivanjima mandibularnog prvog molara sugeriraju da je napredniji razvoj devojčica u odnosu na dečake, potvrđujući razliku između polova u dužini formiranja pojedinih stadijuma kod većine zuba. Najveću procentualnu razliku pokazali su mandibularni očnjaci, a što je veća udaljenost zuba od očnjaka, to je manja polna razlika. Garn i saradnici⁴, takođe, govore u prilog naprednijeg razvoja devojčica, u proseku za 3% u odnosu na dečake.

Mali broj studija se bavi ispitivanjem asimetrija u razvoju korena zuba, što podrazumeva bilateralno ispitivanje u oba kvadranta donje vilice.

Još su Hotz i saradnici⁵ utvrdili visoku simetričnost u razvoju homolognih zuba leve i desne strane u 90% slučajeva za sve zube, dok je za premolare, simetrija nađena u nešto nižem procentu (82-88%). Nolla je objavio⁶ da je razvoj zuba leve i desne strane skoro identičan. Burić i saradnici⁷ su publikovali asimetričan razvoj donjih očnjaka češće kod dečaka (4,2%) u odnosu na devojčice (2,1%).

Cilj rada

Cilj ovog rada bio je utvrditi postojanje asimetrije u razvoju korena stalnih zuba prema uzrastu i polu, kao i stadijum razvoja u kome su asimetrije najzastupljenije.

Materijal i metode

Istraživanje je obavljeno na ortopantomografskim snimcima koji su urađeni pod standardizovanim uslovima snimanja, kod 523 ortodontskih pacijenata (253 dečaka i 270 devojčica) uzrasta od 6 do 14 godina.

Analizirani su stadijumi razvoja korena donjih stalnih očnjaka, kao i asimetričnost njihovog razvoja na levoj i desnoj strani vilice.

Za procenu stadijuma razvoja korena očnjaka korišćena je šema mineralizacije zuba po Gleiser-u i Hunt-u, modifikovana po Tijaniću⁸. Šema sadrži 11 stadijuma razvoja stalnih zuba. Prvih pet stadijuma od 0 do 4 odnosi se na razvoj krunice zuba, dok se ostalih šest stadijuma od 5 do 10, odnosi na procenu stadijuma (mineralizacije) u toku razvoja korena (Slika 1).

growth of the human body is characterized by significant variability in both the level of growth as well as progress towards persons of different biological maturity^{1,2}. Gleiser and Hunt³, in their X-ray studies suggest mandibular first molar advanced development in girls compared with boys, confirming the sex difference in the length of some stages of the formation of most of the teeth. The greatest percentage difference was shown by mandibular canines, and the greater the distance from the canine teeth, the smaller the gender difference. Garn et al.⁴, also speak in favor of more advanced development of girls, an average of 3% as compared to boys. A small number of studies examines the asymmetry in the development of the root, which means testing bilaterally in both quadrants of the mandible.

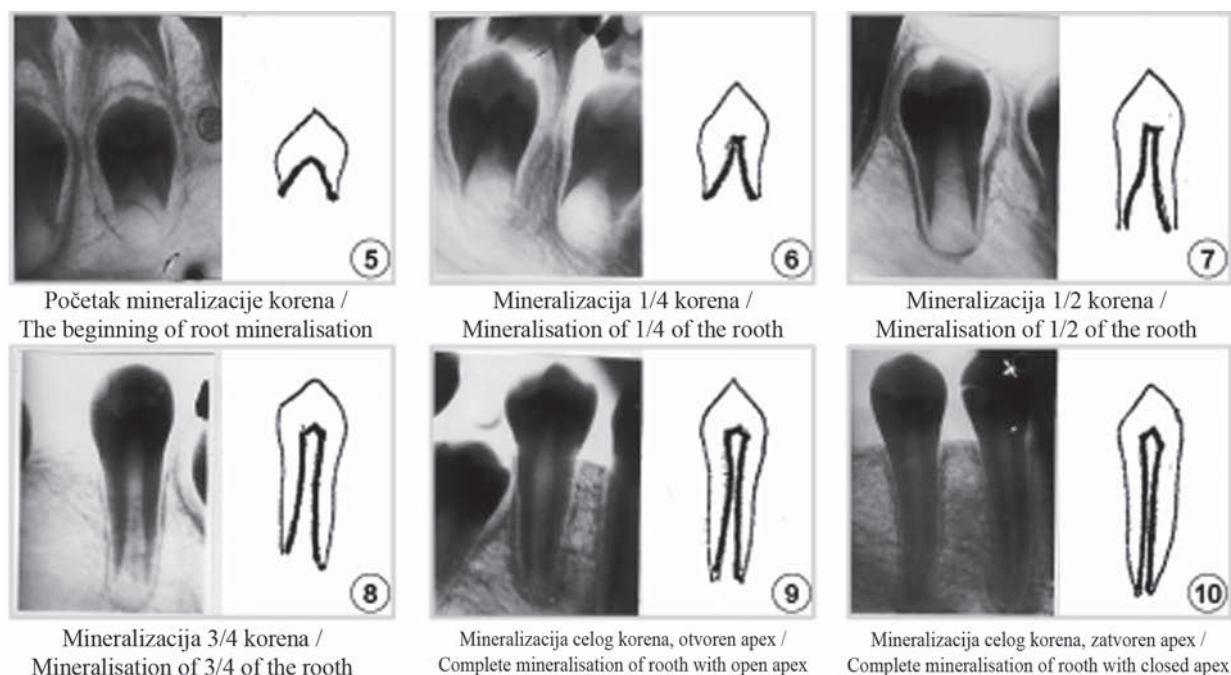
Hotz et al.⁵ found a high symmetry in the development of homologous teeth on the left and right sides in 90% of cases for all the teeth, while in the premolars the symmetry was found in a smaller percentage (82-88%). Nolla⁶ reported that the development of teeth on the left and right sides are almost identical. Buric et al.⁷, have published an asymmetrical development of the lower incisal teeth more often in boys (4.2%) than in girls (2.1%).

Aim

Aim of this study was to determine the existence of asymmetry in the development of lower permanent canine roots by age and sex, as well as the stage of development of the most common asymmetries.

Material and methods

The research was conducted on the orthopantomograms that were made under standardized conditions of x-ray recording, on 523 orthodontic patients (253 boys and 270 girls) aged from 6 to 14 years. We analyzed the stages of root development of permanent lower canines and their development of asymmetry on the left and right sides of the jaw. To assess the stage of root development scheme, canine tooth mineralization was used by a Gleiser and Hunt, and modified by Tijanić⁸. Scheme consists of 11 stages of development of



Slika 1. Stadijumi razvitka korena očnjaka
Figure 1. Development stages of canine root

Pacijenti su raspoređeni na osnovu hronološke starosti od 6 do 14 godina. Na ortopantomografskim snimcima je u okviru svake grupe ocenjivan stepen razvoja korena donjih stalnih očnjaka i praćena simetričnost njihovog razvoja. Ispitivana je prisutnost asimetrije u različitim stadijumima razvoja korena očnjaka leve i desne strane donje vilice, procentualna zastupljenost po polu i ukupna zastupljenost, kao i zastupljenost u različitom uzrastu. Dobi-jeni podaci su statistički obrađeni i prikazani tabelarno i grafički.

Rezultati

Distribucija ispitanika po godištim od 6 do 14 godina, pokazuje da je najviše dečaka bilo u uzrastu od 9 (28,46%) i 8 (27,67%) godina a devojčica od 8 (30%) i 9 (25,19) godina (tabela 1).

Rezultati ispitivanja pokazuju da je kod oba pola asimetrija u razvoju korena donjeg očnjaka prisutna kod 3,82% ispitanika (3,95%dečaka i 3,70% devojčica) (grafikon 1).

Asimetričan razvoj korena očnjaka je najčešće je zastupljen u 7. (1/2 razvoja korena) i 8. (3/4 razvoja korena) stadijumu razvitka. Kod devojčica je asimetrija najčešće prisutna u 7. i u 8. stadijumu (60%), prisustvo asimetrije u 8. i 9. stadijumu (formiran koren bez zatvorenog

permanent teeth. The first five stages from 0 to 4 refer to the development of the tooth crown, while the remaining six stages from 5 to 10 are related to the evaluation stage (mineralization) during root development (Figure 1).

Patients were classified on the basis of chronological age from 6 to 14 years. On ortopantomograms, in each group assessed, the degree of root development of permanent lower canines and their development followed symmetry. We investigated the presence of asymmetry in different stages of canine root development on the left and right sides of the lower jaw, the percentage representation by gender and total participation and representation at different ages. The data were statistically analyzed and presented in tables and graphs.

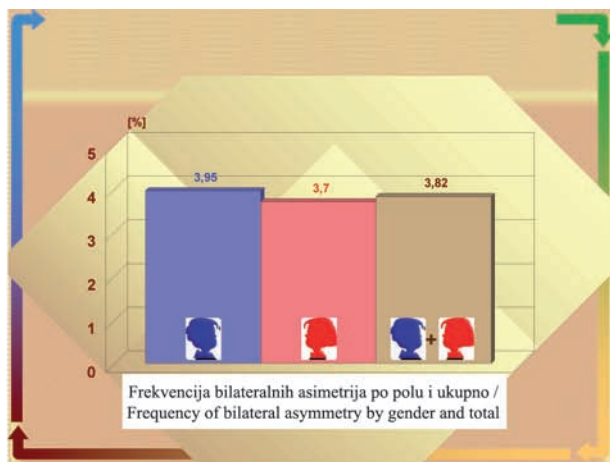
Results

Distribution of respondents by age from 6 to 14 years shows that the majority of boys were at the age of 9 (28.46%) and 8 (27.67%); the girls were aged 8 (30%) and 9 (25.19%) years (Table 1).

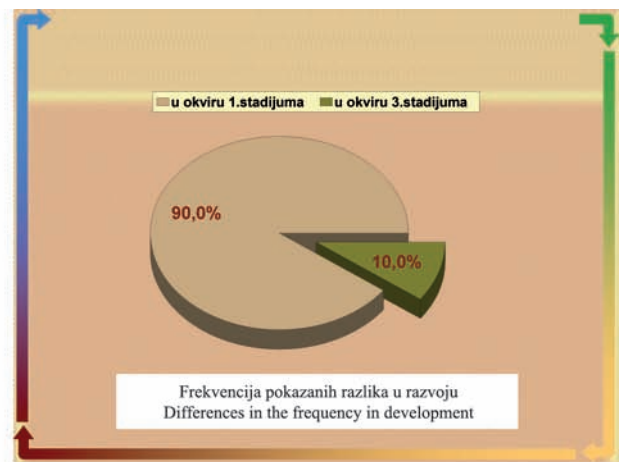Test results show that the asymmetry in both sexes in the development of the root of the lower canine teeth was present in 3.82% of the respondents (3.95% boys and 3.70% girls), (Figure 1). Asymmetric development of canine root usually

Tabela 1. *Frekvencija ispitanika po godinama i po polu*
Table 1. *Summary of cases by gender and age*

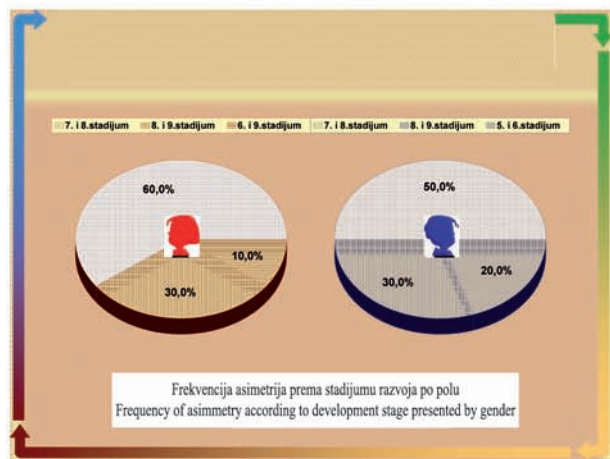
god./age	dečaci/boys		devojčice/girls		ukupno/ total	
	# (broj)	%	# (broj)	%	#	%
6	2	0,79	2	0,74	4	0,76
7	14	5,53	25	9,26	39	7,46
8	70	27,67	81	30	151	28,87
9	72	28,46	68	25,19	140	26,77
10	56	22,13	38	14,07	94	17,97
11	22	8,70	24	8,89	46	8,80
12	14	5,53	23	8,52	37	7,08
13	3	1,19	8	2,96	11	2,1
14			1	0,37	1	0,19
ukupno/ total	253	100%	270	100%	523	100%



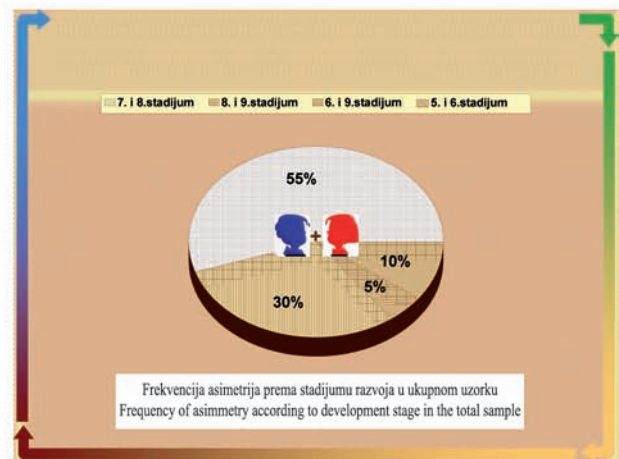
Grafikon 1 / Figure 2



Grafikon 2 / Figure 3



Grafikon 3 / Figure 4



Grafikon 4 / Figure 5

apeksa) nađeno je kod 3 devojčice (30%), dok je razlika od tri stadijuma (6 i 9 stadijum) nađena kod samo jedne devojčice (10%) (grafikon 3). Kod dečaka je asimetrija prisutna u 7. i 8. stadijumu razvitka korena očnjaka kod 5 (50%) ispitanika, u 8. i 9. stadijumu kod 3 (30%), dok je asimetričan razvoj u 5. stadijumu (početak razvoja korena) i 6. stadijumu (1/4 razvoja korena) prisutan kod 20% ispitanika (grafikon 3).

Asimetrija u razvoju korena očnjaka kod ukupnog broja ipitanika pronađena je u 7. i 8. stadijumu razvitka korena u 55% slučajeva, u 8. i 9. stadijumu u 30%, u 5. i 6. stadijumu u 10% i 6. i 9. stadijumu kod 5% (grafikon 4).

Diskusija

U ovoj studiji je utvrđeno da postoji asimetrija u razvoju korenova u ispitivanim grupama oba pola. Poznata je biološka činjenica da je korenu stalnog očnjaka potrebno 5-7 godina za definitivni rast i razvoj⁹. Činjenica da je prisutan veći broj devojčica u mlađim godinama, 30% kod uzrasta od 9 godina, u odnosu na 28,46% uzrasta od 8 godina kod dečaka, može se objasniti većom zainteresovanošću za terapiju, kao i bržim dentalnim razvojem kod devojčica. Naši nalazi pokazuju slične rezultate kao i prethodna istraživanja na drugoj generaciji ispitanika, gde je asimetrija pronađena kod 2,1% dečaka i 4,2% devojčica¹⁰. Razlika formiranja korenova, kod 90% pacijenata kreće se u okviru jednog stadijuma i 10% u okviru 3 stadijuma (grafikon 2). S druge strane, suprotno našim rezultatima, podaci Chertkova i Fattija¹¹ ukazuju da nema razlike u polovima u toku razvoja i mineralizacije korenova mandibularnih stalnih očnjaka, dok se podaci Basaran i sar. poklapaju sa našim rezultatima i ukazuju da postoji odloženi rast i razvitak korenova kod dečaka u odnosu na devojčice¹². Bez obzira na ovakva različita mišljenja, moguće je da ipak postoji polni dimorfizam u toku razvoja /mineralizacije korenova zuba donjih očnjaka koji je u korist 60% devojčica u 7. i u 8. stadijumu, što je utvrđeno našim istraživanjima.

presents in the 7th (1/2 of root development) and 8th (3/4 of root development) stage of development. In girls, asymmetry usually presents in the 7th and 8th stage (60%) of development; the presence of asymmetry in the 8th and 9th stages (without close-formed root apex) was found in 3 girls (30%), while the difference of three stages (6th and 9th stage) was found in only one girl (10%) (Figure 4). In boys, the asymmetry was present in 5 (50%) subjects in the 7th and 8th stage of canines root development; in the 8th and 9th stage in 3 (30%) examinees, while the asymmetrical development in the 5th (early root development) and 6th stages (1/4 of root development) was present in 20% of patients (Figure 4). Asymmetry in the development of root canines in total respondents was found in the 7th and 8th stages of root development in 55% of cases, in the 8th and 9th stages in 30%, in the 5th and 6th stage in 10%, and 6th and 9th stages in 5% (Figure 5).

Discussion

In this study it was determined that there is an asymmetry in the development of roots in the two groups of both sexes. It is a known fact that the biological roots of permanent canines need 5-7 years for definite growth and development⁹. The fact that there is an increasing number of girls at a younger age, 30% at the age of 9 years, compared to 28.46% between the ages of 8 years in boys, may be explained by greater interest in therapy, and faster dental development of girls. Our findings show similar results to previous research on the second-generation respondents, in the cases of which the asymmetry was found in 2.1% of boys and 4.2% of girls¹⁰. The difference in root development in 90% of patients varies within a single stage and 10% within three stages (Figure 3). On the other hand, contrary to our results, the data presented by Chertkow and Fatti¹¹ suggest no gender differences in the development and mineralization of roots of mandibular permanent canines, while data reported by Basaran et al.¹² are consistent with our results and suggest that there is a delayed growth and development of roots in boys compared to girls. Regardless of these differences in opinion, it is possible that there is dimorfism of sexes during development / mineralization of roots of the lower canines, which is determined by our research in 60% of girls during the 7th and the 8th stage.

Zaključak

1. Asimetričan razvoj korena donjeg stalnog očnjaka prisutan je kod malog broja ispitanika (3,82%), bez statistički značajnih polnih razlika.

2. Pokazane razlike u razvoju korena su, sa izuzetkom jednog slučaja, bile u okviru jednog stadijuma.

3. Preko polovine ispitanika (55%) imalo je asimetričan razvoj korena očnjaka u stadijumu polovine i tri četvrtine ukupne dužine korena.

4. Ovako niska asimetričnost u razvoju korena, kao i mali nivo pokazanih razlika, ide u prilog činjenici da je očnjak zub sa veoma malo varijacija u svom razvoju.

Conclusion

1. Asymmetric development of the roots of the lower permanent canine is present in a small number of respondents (3.82%), with no statistically significant gender differences.

2. Shown differences in the development of the root, with the exception of one case were reported within one stage.

3. Over half of respondents (55%) had asymmetrical canine root development staged in half and three quarters of the total root length.

4. Such a low asymmetry in the development of the root and a small demonstration level difference attest to the fact that the canine is the tooth with very little variation in their development.

LITERATURA / REFERENCES

1. Tanner J M. Growth in adolescence. 2nd Ed. Blackwell Scientific Publikations, Oxford. 1962.

2. Chertkow S. Tooth mineralization as an indicator of the pubertal growth spurt, Am J Orthod 1980; 79-91.

3. Gleiser and Hunt, cited in: Thommpson G, Popovich F, Luks E. Sexual dimorphism in hand and wrist ossification. Growth 1973;37:1-11.

4. Garn S, Lewis A, Koski K, Polacheck D. The sex difference in tooth calcification. J. Dent Res 1958; 7:561-567.

5. Hotz R, Boulanger G, Weisshaupt H. 1959. Calcification Time of Permanent Teeth in Relation to Chronological and Skeletal Age in Children. Helvet Odont Acta 3:4-9.

6. Nolla C.M. : The development of the ten permanent teth . J . Dent. Child 1960; 27: 254.

7. Burić M, Ljiljana Tijanić, Vesna Rusić-Tasić. Varijacije u broju kvržica donjih prvih molara M1 i M2. Acta Stomatologica Naissi 2011; 27(63):1059 – 1066.

8 . Tijanić Lj. Razvoj stalnih bočnih zuba kod dece sa normalnom okluzijom i malokluzijama, Doktorska disertacija, 1981.

9 . Schour I, Massler M. Studies in Tooth Development: The Growth Pattern of Human Teeth. J Am Dent Ass 1940;27:1778-1793.

10. Garn S, Lewis A, Koski K, Polacheck D. The sex difference in tooth calcification. J. Dent Res 1958; 7:561-567.

11. Chertkow S. , Fatti P. Relation between tooth mineralization and early radiographic evidence of ulnar sesamoid. Angle Orthod 1979;49:282-88.

12. Basaran G, Ozer T, Hamamci N. Cervical, vertebral and dental maturity in Turkish subjects. Am J Orthod Dentofac Orthop 2007;131:447.e 13-20.