

Primljen/ Received on: 18.08.2019
 Revidiran / Revised on: 10.09.2019
 Prihvaćen/ Accepted on :16.09.2019

PRIKAZ SLUČAJA
 CASE REPORT
 doi: 10.5937/asn1980970J

RANA PRIMENA PARCIJALNE AKRILATNE OPTURATOR PROTEZE U POSTOPERATIVNOM TRETMANU KOŠTANIH DEFEKATA NAKON MARSUPIJALIZACIJE VELIKIH VILIČNIH CISTI

EARLY USE OF PARTIAL ACRYLIC DENTURE OBTURATOR IN THE POSTOPERATIVE TREATMENT OF BONE DEFECTS AFTER MARSUPIALISATION OF LARGE JAW CYSTS

*Marija Jovanović¹, Simona Stojanović^{1,2}, Kosta Todorović^{1,2}, Radmila Obradović^{1,3}, Marko Igić^{1,4},
 Branislava Stojković^{1,5}, Nikola Gligorijević¹, Milan Spasić², Goran Jovanović^{1,2}*

¹ UNIVERZITET U NIŠU, MEDICINSKI FAKULTET, ODEK STOMATOLOGIJA, NIŠ, SRBIJA

² UNIVERZITET U NIŠU, MEDICINSKI FAKULTET, KLINIKA ZA STOMATOLOGIJU, ODELJENJE ORALNA HIRURGIJA, NIŠ, SRBIJA

³ UNIVERZITET U NIŠU, MEDICINSKI FAKULTET, KLINIKA ZA STOMATOLOGIJU, ODELJENJE ZA ORALNU MEDICINU I PARODONTOLOGIJU, NIŠ, SRBIJA

⁴ UNIVERZITET U NIŠU, MEDICINSKI FAKULTET, KLINIKA ZA STOMATOLOGIJU, ODELJENJE ZA PROTETIKU, NIŠ, SRBIJA

⁵ UNIVERZITET U NIŠU, MEDICINSKI FAKULTET, KLINIKA ZA STOMATOLOGIJU, ODELJENJE ZA DEČJU I PREVENTIVNU STOMATOLOGIJU, NIŠ, SRBIJA

¹ UNIVERSITY OF NIŠ, FACULTY OF MEDICINE, DEPARTMENT OF DENTISTRY, SERBIA

² UNIVERSITY OF NIŠ, CLINIC OF DENTISTRY, DEPARTMENT OF PROSTHODONTICS, NIŠ SERBIA

³ UNIVERSITY OF NIŠ, CLINIC OF DENTISTRY, DEPARTMENT OF ORAL MEDICINE AND PERIODONTOLOGY, NIŠ, SERBIA

⁴ UNIVERSITY OF NIŠ, FACULTY OF MEDICINE, DEPARTMENT OF PROSTHODONTICS, NIŠ, SERBIA

⁵ UNIVERSITY OF NIŠ, FACULTY OF MEDICINE, DEPARTMENT OF PEDIATRIC AND PREVENTIVE DENTISTRY, DENTAL CLINIC, NIŠ, SERBIA

Sažetak

Uvod: Posle marsupijalizacije velikih viličnih cisti nastaju koštani defekti koji ne garantuju stabilnost krvnog koaguluma i zbog toga se ispunjavaju jodoform gazom. Svaka zamena jodoform gaze, radi toaleta rane, prouzrokuje manje ili veće krvarenje, što usporava epitelizaciju i organizaciju rane. Zbog toga se, nekoliko nedelja od operativnog zahvata, preporučuje izrada parcijalne akrilatne opturator proteze.

Prikaz slučaja: U ovom radu prikazan je slučaj dva pacijenta kod kojih je izrađena parcijalna akrilatna opturator proteza desetog dana nakon operativnog zahvata. To je omogućilo značajno lakšu toaletu rane, bržu epitelizaciju i organizaciju rane, a samim tim i brže koštano zarastanje.

Zaključak: Obnovljene funkcije žvakanja, gutanja i govora, kao i estetski izgled ukazuju na značaj rane izrade akrilatne opturator proteze.

Cljučne reči: ciste, marsupijalizacija, opturator proteza, zarastanje rane

Corresponding author:

Marija Jovanović PhD, Student, Faculty of Medicine
 Nemanjića Blvd. 61/9 18000 Nis, Serbia
 Mobile: +381655214411
 E-mail: jovanovicmarija94@gmail.com

Abstract

Introduction: After marsupialisation of large jaw cysts, there comes to the formation of bone defects which do not guarantee the stability of the blood clot and therefore are filled with iodine gauze. Any replacement of iodine gauze, toilet of the wound, causes minor or major bleeding, which slows wound epithelialisation and organization. Therefore, making the partial acrylic denture obturator is recommended to be done a few weeks after the surgery.

Case report: This work presents two patients who had partial acrylic denture obturator made on the tenth day after the surgery. This allowed significantly easier toilet of the wounds, faster epithelialization and organization, and thus faster bone healing.

Conclusion: Restored function of chewing, swallowing and speech, as well as the aesthetic appearance suggest that early use of acrylic obturator prosthesis is very significant.

Keywords: cysts, marsupialisation, obturator prosthesis, wound healing

2019 Faculty of Medicine in Niš. Clinic of Dentistry in Niš. All rights reserved / © 2019. Medicinski fakultet Niš. Klinika za stomatologiju Niš. Sva prava zadržana.

Uvod

Hirurška terapija velikih viličnih cisti često podrazumeva delimično uklanjanje cističnog sakusa i dekompresiju ciste ili marsupijalizaciju (cistostomiju). Operaciju je opisao Partsch još 1892. godine. Intervencija se sprovodi u situacijama kada veličina koštanog defekta ne garantuje stabilnost krvnog koaguluma, ugrožava susedne strukture, pretili frakturi donje vilice, kod pacijenata starije životne dobi, koji su rizični za rad u opštoj anesteziji, i naročito kod dece, kada su u pitanju neagresivne cistične lezije¹.

Rez se vrši ivicom budućeg koštanog defekta, uklanja se površinski deo cističnog sakusa i prazni se (aspirira) sadržaj ciste. Mukoperiostalni režanj ubacuje se u nastali koštani defekt ili se obodno ekscidira i ušiva za ivicu koštanog defekta. Kavitet se ispunjava jodoform gazom, koja se menja na sedam dana uz prethodno ispiranje i dezinfekciju rane. Kasnije, posle nekoliko nedelja, preporučuje se izrada parcijalne akrilatne opturator proteze (PAOP). Najjednostavnije proteze mogu se napraviti bez zuba, mađa su estetski i funkcionalno daleko bolje one proteze koje uključuju zube, alveole i okolna tkiva².

Smanjenje inflamacije cističnog zida, redukcija zapremine i sekundarna dekompresija iniciraju okolnu osteoblastičnu aktivnost. Vremenom dolazi do perifernog stvaranja novog koštanog tkiva i postepenog smanjenja zapremine koštanog defekta. Proces stvaranja nove kosti traje, u zavisnosti od veličine i oblika defekta, nekoliko meseci, pa čak i više od godinu dana. Epilog marsupijalizacije je metaplazija cističnog epitela u pločastoslojevit epitel usne duplje ili perzistencija delova ili celog cističnog sakusa³. Naknadna enukleacija vezana je za agresivne kliničke lezije kakve su odontogene keratociste⁴. Odluka se donosi na osnovu histopatološkog nalaza.

Jodoform gaza u koštanom defektu, u vremenskom periodu od nekoliko nedelja, može stvarati znatne neugodnosti pacijentu, od kojih se najčešće apostrofiraju: bol prilikom njene zamene, jak miris i neprijatan zadah. Osim toga, svaka zamena jodoform gaze posle operacije uzrokuje uklanjanje površinskih slojeva krvnog koaguluma i krvarenje, što usporava epitelizaciju defekta.

Cilj rada je prikazati uspešnu ranu primenu parcijalne akrilatne opturator proteze (PAOP) u gornjoj i donjoj vilici kod dva pacijenta nakon marsupijalizacije velikih viličnih cisti.

Introduction

Surgical therapy of large jaw cysts often involves partially removing the sac of cysts and cysts decompression or marsupialisation (cystostomy). The operation was described by Partsch in 1892. The intervention is implemented when the size of the bone defect does not guarantee the stability of the blood clot, threatens neighbouring structures, and threatens to fracture of the lower jaw in older patients who are at risk for operation under general anesthesia, and especially in children when it comes to aggressive cystic lesions¹.

The cut goes along the edge of the future bone defect, removing the surface of the cystic sac and emptying (aspirating) the contents of the cyst. Width flap is inserted into the resulting bone defect or circumferentially excised and sutured to the edge of the bone defect. The cavity is filled with iodoform gauze that is changed in seven days with the previous washing and disinfecting the wound. Later, after a few weeks, making partial acrylic dentures obturator (PADO) is recommended. The simplest prosthesis can be made without teeth, although aesthetically and functionally far better are the ones that include teeth alveoli and the surrounding tissue².

Decrease of cystic wall inflammation, volume reduction and secondary decompression initiate the surrounding of osteoblast activity. Over time, there is a peripheral formation of new bone and gradual reduction in volume of the bone defect. The process of creating a new bone takes a few months or even more than a year depending on the size and shape of the defect. Epilogue of marsupialisation is metaplasia of cystic epithelia into layered epithelium of the oral cavity or the afterglow of the whole or parts of cystic sac³. Subsequent enucleation is associated with aggressive clinical lesions such as odontogenic keratocysts⁴. A decision is made based on histopathological findings.

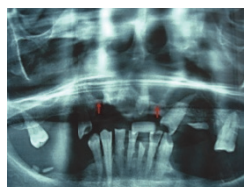
Iodine gauze in the bone defect within a period of several weeks can cause considerable inconvenience to the patient, one of which is usually pain during its replacement, a strong odour and bad breath. In addition, each substitute iodoform gauze after surgery causes removal of the surface layers of a blood clot and bleeding, which slows epithelialization of the defect.

The aim is to show the successful implementation of early partial acrylic dentures obturator (PADO) in the upper and lower jaw in two patients after marsupialisation large jaw cysts.

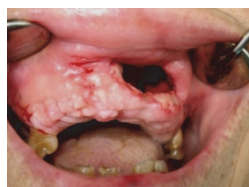Prikaz slučaja

Pacijenti su operisani u Službi za oralnu hirurgiju Klinike za stomatologiju Medicinskog fakulteta u Nišu na osnovu histopatoloških rezultata preoperativnih biopsija, koji su ukazali na prisustvo radikularnih cisti. Pre hirurške intervencije izvršena je detaljna parodontološka sanacija usne duplje u Službi za parodontologiju i oralnu medicinu Klinike za stomatologiju Medicinskog fakulteta u Nišu. Neposredno posle intervencije pacijenti su upućeni na Odeljenje za stomatološku protetiku Klinike za stomatologiju Medicinskog fakulteta u Nišu, gde im je izrađena PAOP. U oba slučaja histopatološki rezultati intraoperativnih biopsija potvrdili su dijagnozu radikularnih cisti.

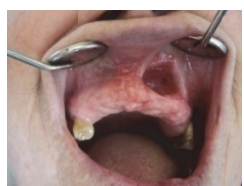Prvi pacijent P. S. ženskog je pola, starosti 85 godina, sa subtotalnom krezubošću i cističnom lezijom koja se pružala od centralnog sekutića do drugog premolara gornje vilice sa leve strane (slika 1). S obzirom na godine života i veličinu lezije urađena je marsupijalizacija ciste (slika 2,3). U postoperativnom periodu stvoreni defekt čvrsto je ispunjen jodoform gazom. Sedmog dana izvršena je toaleta rane, uzet je otisak alginatnom masom, ponovo je izvršena toaleta rane i zamenjeno je pakovanje jodoform gaze znatno mekšim (predlog: zamenjena je upotrebna jodoform gaza znatno mekšom). Uzimanje otiska neposredno posle operativnog zahvata nije predstavljalo veći problem. Alginatna masa pripremana je nešto ređe, kako bi njeno plasiranje bilo meko, što nije bilo praćeno bolom kod pacijenta, već strahom i neugodnošću. Radi preciznijeg otiska, prvo je otisna masa prstom nanošena u defekt, a zatim je preko nje uziman otisak standardnom kašikom napunjenom alginatom. Desetog dana izrađena je PAOP od tople polimerizujućeg akrilata i predata pacijentu (slika 4).



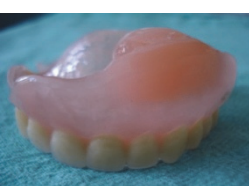Slika1 / Figure 1



Slika2/ Figure 2



Slika3/ Figure 3

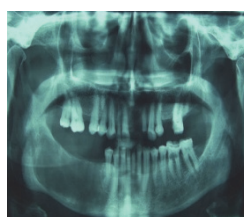


Slika4/ Figure 4

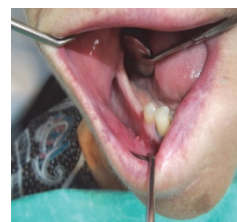
Case report

Patients were operated in the Department of Oral Surgery at Dental Clinic of the Faculty of Medicine based on histopathological results of preoperative biopsy, which indicated the presence of radicular cysts. Before surgery they performed a thorough periodontal rehabilitation of the oral cavity in the Department of Parodontology and Oral Medicine, Clinic of Dentistry Faculty of Medicine. Immediately after the procedure, patients were referred to the Department of Prosthetic Dentistry, Faculty of Medicine, where PADO was made. In both cases, the histopathological results of intraoperative biopsy confirmed the diagnosis of radicular cyst.

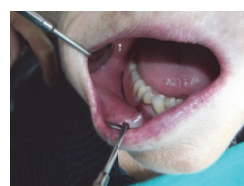The first patient was P. S., female, 85 years of age, with subtotal toothlessness and cystic lesion extended from the central incisors to the second premolar of the upper jaw on the left side (Figure 1). Due to the age and size of the lesion, marsupialisation of cysts was performed (Figure 2,3). In the postoperative period created defect was firmly filled with iodoform gauze. On the seventh day the toilet of the wound was made, the print was taken with alginate mass, then toilet of the wound was re-made and iodine gauze packing was replaced with considerably softer one. Taking impression immediately after surgery was not a problem. Alginate mass was prepared less thick, so that its placement was soft, not accompanied by pain, fear and discomfort of the patient. For a more precise fingerprint, the first mass fingerprint inflicted the defect, and then the fingerprint was taken over it with standard bucket filled with alginate. On the tenth day a hot-dip polymer acrylate PADO was made and delivered to the patient (Figure 4).



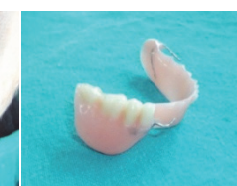Slika 5 / Figure 5



Slika 6, / Figure 6



Slika 7/Figure 7



Slika 8 / Figure8

Prilikom svakog narednog kontrolnog pregleda, koji je zakazivan na sedam dana, PAOP je obrađivana i delimično skraćivana uz istovremenu toaletu i dezinfekciju rane. Epitelizacija rane nastala je 25. dana posle operacije, što je pacijentu omogućilo komforniji život u smislu higijene, ishrane i estetike. Potpuno ispunjenje defekta novostvorenim koštanim tkivom nastupilo je 5 meseci nakon operacije, a pacijentkinja je nastavila da nosi PAOP kao definitivni protetski rad.

Drugi pacijent D. R, takođe je osoba ženskog pola, starosti 86 godina, sa jednostranom bezubošću i cističnom lezijom koja se pružala od prvog premolara do trigonuma retromolare donje vilice sa desne strane (slika 5). I u ovom slučaju urađena je marsupijalizacija ciste (slika 6.), plasirana je jodoform gaza, sedmog dana uzet je otisak alginatom i desetog dana postavljena je PAOP (slike 7. i 8.), koja je obrađivana na isti način kao u prethodnom slučaju. Epitelizacija rane nastala je 23. dana. Potpuno ispunjenje defekta novostvorenim koštanim tkivom nastupilo je 8 meseci nakon operacije. I u ovom slučaju PAOP je tako prilagođena da je nošena kao definitivna proteza.

U narednom periodu kod oba pacijenta nisu uočene nikakve smetnje i nepravilnosti, u smislu pojave komplikacija ili cističnih recidiva.

Diskusija

Velike koštane ciste u maksili i mandibuli tretiraju se otvorenim metodom, jer formiranje nestabilnog krvnog koaguluma predstavlja locus minoris resistentiae za nastanak akutne infekcije. Nastali koštani defekti velikog su morbiditeta. Ispunjavaju se jodoform gazom, čiji su zadaci prevencija sekundarnog krvarenja, antiseptički efekat, sprečavanje zapadanja hrane i stranih tela u ranu, kao i eliminisanje negativnog uticaja pljuvačke.

Međutim, jodoform gaza u dužem vremenskom periodu stvara brojne neugodnosti pacijentu, koje se ogledaju u njenom preterano jakom mirisu, bubrenju pod dejstvom pljuvačke i prominiranju iz defekta, što delimično onemogućava i otežava mastikaciju, kao i nakupljanju ostataka hrane, na površini gaze, koja se raspada i neprijatno miriše. Svaka nova zamena gaze prilično je bolna za pacijenta, jer se gaza lepi za periferiju i ivice defekta uklanjajući krvni koagulum, zbog čega rana dodatno krvari. Impregnacija gaze sterilnom

During each follow-up examination scheduled at seven day intervals, PADO was processed and partially shortened simultaneously with toilet and disinfection of wounds. Epithelization of the wound occurred 25 days after the operation which allowed the patient more comfortable life in terms of hygiene, nutrition and aesthetics. Complete filling of the defect with newly created bone tissue occurred 5 months after surgery, and patient continued to carry PADO as the definitive prosthesis.

The second patient, D. R. was also female, 86 years of age, with unilateral edentulous and cystic lesions that stretched from the first premolar to trigonum retromolar lower jaw on the right side (Figure 5). In this case, cysts marsupialisation was performed as well (figure 6.), iodine gas was placed, on the seventh day the alginate print was taken and on the tenth day PADO was set (Figures 7 and 8), which was treated in the same manner as in the previous case. Epithelization occurred on the 23rd day. Complete defect filling with the newly created bone tissue occurred 8 months after surgery. In this case, PADO was adjusted so that it is worn as a definitive prosthesis.

In the forthcoming period, both patients showed no disturbances and irregularities in terms of complications or recurrence of cyst.

Discussion

Large bone cysts in the maxilla and mandible are treated by the open method, because the formation of unstable blood coagulum represents the locus minoris resistentiae for the occurrence of acute infection. The resulting bone defects are major morbidity. They are filled with the iodoform gauze whose task is to prevent secondary bleeding, provide antiseptic effect, prevention of food falling and foreign bodies in the wound, as well as the elimination of the negative impact of the saliva.

However, the iodine gas in a longer time period creates a number of inconveniences to the patient which are reflected in its excessively strong smell, swelling under the action of saliva and prominiranju from the defect which partly prevents and hinders mastication, as well as the build-up of food residue on the surface of the gauze which decomposes and smells. Each new gauze replacement is quite painful for the patient, because the gauze sticks to the periphery and the edges of the defect

parafinskom pastom to delimično, ali nepotpuno onemogućava. Iz tih razloga, epitelizacija rane znatno je sporija i često traje duže od mesec dana.

Osnovni cilj protetske terapije, nakon većih operativnih zahvata u gornjoj i donjoj vilici, je rehabilitacija izgubljenih struktura uz što bržu obnovu funkcija žvakanja, gutanja i govora, kao i poboljšanje izgleda pacijenta⁵. PAOP čini mehaničku barijeru između operisanog dela i usne duplje. Svojom glatkom površinom onemogućava lepljenje koaguluma i sekundarno krvarenje prilikom toaleta i dezinfekcije rane. Sprečava nakupljanje tečnosti i hrane, kontaminaciju rane i prouzrokuje bržu epitelizaciju i organizaciju, a samim tim i (predlog: pospešuje) izlječenje rane povezane sa defektom kosti⁶. Shodno tome, brže je i koštano zarastanje, tj. ispunjenje defekta novonastalom kosti.

Rana izrada PAOP ima vrlo značajnu ulogu (predlog: u postoperativnoj nezi) i utiče na poboljšanje kvaliteta života operisanih pacijenata^{7,8}. Pri tom, pokazuje sledeće prednosti u odnosu na jodoform gazu: 1) manja trauma tkiva prilikom zamene; 2) odsustvo bola i krvarenja; 3) brža epitelizacija rane; 4) normalna mastikacija; 5) odsustvo mirisa jodoforma; 6) prihvatljiva estetika; 7) lako skidanje i postavljanje; 8) redukcija zadržavanja ostataka hrane i njenog raspadanja; 9) lako održavanje oralne higijene i 10) odsustvo neprijatnog zadaha. Postavljanje PAOP neposredno posle operacije čini pacijenta nesvesnim hirurške deformacije, što je vrlo bitno sa psihičke strane². (Predlog: PAOP skraćuje vreme) Skraćuje se vreme oporavka i omogućava pacijentu da se vrati u zajednicu kao funkcionalan član².

U toku procesa zarastanja rane potrebne su česte kontrole i obrade PAOP. Kako se defekt popunjava novostvorenim koštanim i mekim tkivom tako se redukuje površina PAOP koja ispunjava kavitet cističnog defekta. Osim idealnog uklapanja i prilagođavanja rani, ponekad se mogu uraditi i druge modifikacije, u smislu dodavanja zuba radi poboljšanja estetike, mastikacije i govora.

Kao što je već istaknuto, obe naše pacijentkinje nastavile su da nose PAOP kao definitivne proteze. Prethodnim korekcijama, tokom koštanog i mekotkivnog zarastanja, PAOP su dovedene u idealnu poziciju prema okolnim tkivima. Uz odsustvo dekubita, bolova i drugih smetnji, kao i uz naviku (predlog: naviknutost) pacijenta na njihovo nošenje, nije bilo potrebe za izradom novih definitivnih proteza. I drugi autori navode da u

The main goal of prosthetic treatment after major surgery in the upper and lower jaw is the rehabilitation of lost structures with advancing the restoration of function of chewing, swallowing and speaking, as well as the improvement in the patient's appearance⁵. PADO makes a mechanical barrier between the operated and part of the oral cavity. Its smooth surface prevents sticking of the clot and secondary bleeding when doing the toilets and disinfection of the wounds. It prevents the accumulation of fluids and food, contamination of wounds, and causes rapid epithelialization and organization, and consequently wound healing associated with a defect in the bone⁶. Eventually, there is a faster bone healing, i.e., filling of the newly created bone defect.

Early PADO production has a very important role and improves the quality of life of treated patients^{7,8}. At the same time, with respect to iodine gauze it shows the following advantages: 1) less trauma in tissue replacement, 2) absence of pain and bleeding, 3) faster wound epithelialization, 4) normal mastication, 5) a lack of odor iodophor 5) acceptable aesthetic, 6) easy to remove and install, 7) reduction of food residue and its decomposition, 8) ease of maintenance of oral hygiene and 9) absence of bad breath. Setting PADO immediately after surgery makes the patient unconscious of surgical deformities, which is very important regarding the psychological side². Recovery time is shorter and allows the patient to return to the community as a functional member².

During the healing process, frequent monitoring and processing of PADO is required. As the defect fills the newly created bone with soft tissue, the PADO surface that fills the cavity cystic defect reduces. In addition to an ideal fit and adjustments early, sometimes you can do other modifications in terms of adding teeth to improve aesthetics, mastication and speech⁹.

As it has already been pointed out, both our patients continued to wear PADO as definitive prosthesis. With corrections during the healing of bone and soft tissue, PADO is brought in the ideal position in relation to the surrounding tissues. With the absence of decubitus, pain and other disorders, as well as with the habit of the patient to their carrying, there was no need to create a new prosthesis. Other authors state that in certain situations PADO can serve as a definitive prosthesis¹⁰.

Regeneration of bone defects depends on their size. Defects of 3 teeth regenerate for up to 12 months and the damage to more than 3 teeth up to 20 months or more. Defects in the During the healing process, frequent

monitoring and processing of Paope is required. As the defect fills the newly created bone with soft tissue, the Paope surface that fills the cavity cystic defect određenim situacijama PAOP mogu poslužiti kao definitivne proteze¹⁰.

Regeneracija koštanih defekata zavisi od njihove veličine. Defekti (predlog: koji obuhvataju do 3) do 3 zuba regenerišu se za najviše 12 meseci, a defekti (predlog: koje čini) preko 3 zuba regenerišu se, nekada, za 20 i više meseci. Defekti u gornjoj vilici brže regenerišu nego oni u donjoj vilici, zbog bolje prokrvljenosti i obilne spongioze, što se pokazalo i u ovom slučaju¹¹. Pri tom, izduženi defekti brže regenerišu u odnosu na okrugle, gde je retrakcija koaguluma izraženija. Kod naših pacijentkinja koštana regeneracija trajala je pet meseci u maksili, odnosno osam meseci u mandibuli, što je s obzirom na njihove godine i veličinu defekta bilo prilično brzo. (predlog: „što je bio prilično kratak period oporavka“ ili „prilično brz oporavak“.)

Zaključak

Rana izrada PAOP pokazala se vrlo efikasnom, u smislu poboljšanja epitelizacije koštanih defekata posle marsupijalizacije velikih viličnih cisti. Komfornost koju pruža i odsustvo negativnih uticaja nekada dozvoljavaju njenu primenu kao definitivne proteze i posle ispunjenja defekta novim koštanim tkivom.

upper jaw regenerate faster than in the lower, due to a better blood circulation and abundant cancellous, as proven in this case¹¹. In addition, elongated defects quickly regenerate compared to round, where the clot retraction is pronounced. Bone regeneration lasted five months in the maxilla and eight months in the mandible, which was pretty fast due to their age and size of the defect.

Conclusion

Early PADO development proved to be very effective in terms of improving epithelialization of bone defects after marsupialisation of large jaw cysts. The comfort provided by the absence of the negative impacts sometimes allows its use as a definitive prosthesis, even after the defect is filled with the new bone tissue.

LITERATURA / REFERENCES

1. Pejović M, Stępić J, Marković A, Dragović M, Miličić B, Čolić S. Retrospektivna studija spontane regeneracije kosti posle dekompresije velikih odontogenih cističnih lezija kod dece. *Vojnosanitetski pregl*; 2016; (73) 2: 129-134.
2. Pravinkumar GP. Surgical obturator duplicating original tissue-form restores esthetics and function in oral cancer. *World J Stomatol*. 2013; 2(4): 97-102.
3. Gao L, Wang X, Li S, Liu C, Chen C, Li J, Zhi K. Decompression as a treatment for odontogenic cystic lesions of the jaw. *J Oral Maxillofac Surg*. 2014; 72(2): 327-33.
4. Marin S, Kirnbauer B, Rugani P, Mellacher A, Payer M, Jakse N. The effectiveness of decompression as initial treatment for jaw cysts: A 10-year retrospective study. *Med Oral Patol Oral Cir Bucal*. 2019; 24 (1): 47-52.
5. Singh M, Bhushan A, Kumar N, Chand S. Obturator prosthesis for hemimaxillectomy patients. *Natl J Maxillofac Surg*. 2013; 4(1): 117-120.
6. Ray S, Ray PK, Islam R, Chaudhari GR. Prosthetic Rehabilitation of Maxillo-mandibular defects: Case Series. *International Journal of Oral Health Dent*. 2016; 2(3): 200-205.
7. Brandão TB, Vechiato Filho AJ, Batista VE, de Oliveira MC, Santos-Silva AR. Obturator prostheses versus free tissue transfers: A systematic review of the optimal approach to improving the quality of life for patients with maxillary defects. *J Prosthet Dent*. 2016; 115(2): 247-253.
8. Loster JE, Ryniewicz W, Gala A, Wiczorek A. Prosthetic obturators used in the treatment of cystic jaw bones. *J Stomat*. 2015; 68 (5): 531-538.
9. Kamarudin KH, Hattori M, Sumita YI, Taniguchi H. A chairside technique to add customized anterior acrylic resin teeth to a surgical obturator. *The Journal of Prosthetic Dent*. 2018; 119 (5): 852-854.
10. Husein M, Hassan SI, Khan MY, Khan M, Tanveer W. Retention in Mandibular Obturator. *Professional Med J*. 2014; 21(4): 755-759.
11. Narwa A, Chugh A, Swami R. Immediate Prosthetic Rehabilitation of Surgically Enucleated Pinborg Tumour: A Case Report. *Annals of International Medical and Dental Research* 2016; 2 (6): 28-31.