

Massive Benign Lingual Tonsil Hyperplasia and Tracheostomy

Ognjen Cukic¹, Sanja Nikolic¹, Milan B. Jovanovic^{1,2}
¹Department of Otorhinolaryngology, Clinical Hospital Center Zemun, Belgrade, Serbia
²Medical Faculty, University of Belgrade, Serbia

Abstract

We describe a case of excessive lingual tonsil hyperplasia in adult despite previous tonsillectomy which required initial tracheostomy to complete removal of lymphoid tissue. We discuss intubation difficulties in evaluation of airway.

Key words: Aneurysm, left ventricle, cormatrix

Introduction

A hyperplastic lingual tonsil is rare condition and may compromise the upper airway, particularly in the retrolingual area, and it can lead to severe complications such as cardiac arrest, cerebral anoxia, and death, primarily because of the risk of an unexpected difficult tracheal intubation¹. Furthermore, lymphoid hyperplasia of the tongue closely resembles carcinoma and lymphoma, clinically or histopathologically².

Case report

We report the case of a 54-year old woman affected by progressively developed dysphagia for solid food but with no significant weight loss during the previous 2 years. The patient had had tonsillectomy when 5 years old because of recurrent episodes of tonsillar infection. Oropharyngeal examination revealed a smooth-surfaced, enormous overgrowth on the left side base of the tongue protruded toward the medial pharyngeal wall (Figure 1).

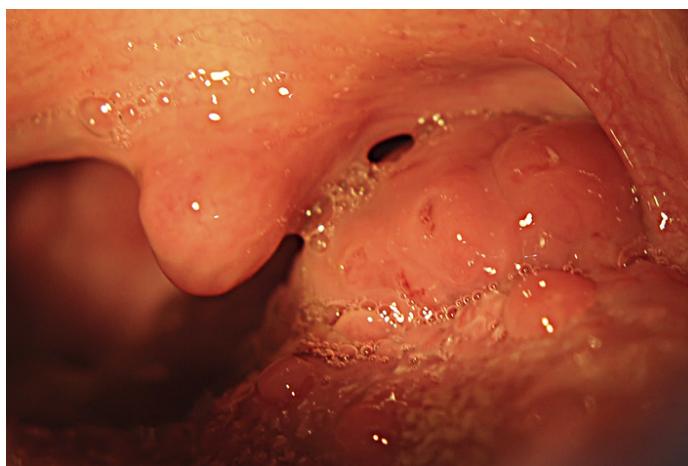

Figure 1. Oropharyngeal examination of the tongue base mass

Masivna benigna lingvalna tonzilarna hiperplazija i traheostomija

Ognjen Cukic¹, Sanja Nikolic¹, Milan B. Jovanovic^{1,2}
¹Department of Otorhinolaryngology, Clinical Hospital Center Zemun, Belgrade, Serbia
²Medicinski fakultet Univerziteta u Beogradu

Apstrakt

Opisujemo slučaj prekomerne hipersplazije lingvalne tonzila kod odraslih uprkos prethodnoj tonzilektomiji koja je zahtevala inicijalnu traheostomiju da bi se kompletno uklonilo limfoidno tkivo. Raspravljamo o poteškoćama u intubaciji u proceni disajnih puteva.

Ključne reči: Aneurizma, leva komora, Cormatrix

A computed tomography scan showed the lesion (53,3mmx38,8mm) had filled the entire vallecula and were causing the epiglottis to retroflex and approximate the posterior pharyngeal wall significantly narrowing airway and impeded the transit of the food (Figure 2.).

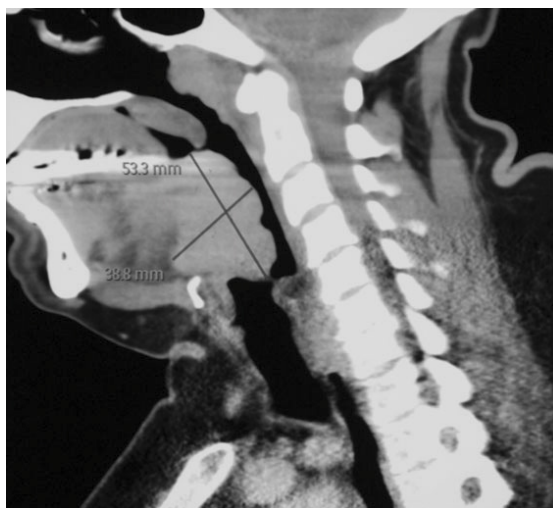


Figure 2. CT scan without contrast enhancement shows a bulky, expansive, oval mass with dimension

Because of intubation difficulties, a preoperative tracheostomy was performed. Tissue was removed via sharp dissection and electrocautery. Histopathologic examination showed that resected tissue consisted of reactive follicular hyperplasia. The operation totally resolved the open airway and swallowing disturbance. The Ethic Committee of Clinical Hospital Center “Zemun”, Faculty of Medicine, University of Belgrade approved this case report.

Discussion

To our knowledge, there are no previous reports of such massive benign lingual hyperplasia and impossible intubation which required preliminary tracheostomy. Lymphoid lingual hyperplasia in adults, particularly after tonsillectomy, are usually asymptomatic. When present, symptoms rise due to mechanical compression/obstruction and patients usually complain of non-specific symptoms such as tongue paraesthesia, dysphagia, and throat discomfort and dyspnea³. It is necessary to prepare a difficult airway management including laryngeal mask airway, fiberoptic bronchoscopy and transcutaneous tracheotomy set^{4,5}. Macintosh laryngoscopy failed to expose a glottis by two experienced anesthesiologists. Rigid laryngoscopy could not visualize the epiglottis because of hypertrophied tonsillar tissue, and mask ventilation became difficult when spontaneous breathing stopped. Also, fiberoptic bronchoscopy through the nasal cavity in combination with jet ventilation not allowed nasotracheal intubation to be accomplished. Due to the large size (> 5 cm in maximum diameter) and site of this lymphoid tissue, it was decided to proceed with tracheostomy in order to ensure complete removal of lesion.

Conclusion

Massive lingual tonsill hyperplasia is one risk factor for an unanticipated failed intubation not detectable during routine oropharyngoscopy that should be considered during a preliminary evaluation of airway.

References

1. Ovassapian A, Glassenberg R, Randel GI, Klock A, Mesnick PS, Klapfta JM. The unexpected difficult airway and lingual tonsil hyperplasia: a case series and a review of the literature. *Anesthesiology* 2002;97:124-32.
2. Spinou C, Kubba H, Konstantinidis I, Johnston A. Role of tonsillectomy in histology for adults with unilateral tonsillar enlargement. *Br J Oral Maxillofac Surg* 2005;43(2):144-7.
3. Friedman M, Wilson MN, Pulver TM, Golbin D, Lee GP, Gorelick G, Joseph NJ. Measurements of adult lingual tonsil tissue in health and disease. *Otolaryngol Head Neck Surg* 2010;142:520-5.
4. Patel DR. Enlarged palatine tonsil causing parasthesia to the posterior one-third of the tongue. *Br J Oral Maxillofac Surg* 1996;34:201-2.
5. Orhan ME, Gözübüyük A, Sızlan A, Dere U. Unexpected difficult intubation due to lingual tonsillar hyperplasia in a thoracotomy patient: intubation with the double-lumen tube using stylet and fiberoptic bronchoscopy. *J Clin Anesth* 2009;21:439-41.

Corresponding author:

Milan B. Jovanovic, Department of Otorhinolaryngology and Maxillofacial surgery,
Clinical Hospital Center "Zemun",
Vukova 9 11080 Belgrade, Serbia
Email majov@eunet.rs
Phone +38163339915