



# Squamous intraepithelial lesions

Jadranka RAVIĆ<sup>1</sup>  
Marija TEŠIĆ<sup>2</sup>

*According to the Bethesda classification cervical epithelial lesions are divided into squamous intraepithelial lesions (SIL) of low grade (LG) and high grade (HG). These lesions are considered to be a premalignant disease. They are most often associated with HPV infection caused by viruses of high, intermediary or low oncogenic potential. Having in mind its malignant potential, early diagnosis and adequate treatment of SIL take very important place in the struggle against the cervical cancer. The aim of this paper was to analyze all diagnosed cases of SIL and to emphasize the importance of opportune screening of women in early detection of cervical precancerous lesions. Opportune screening implies systematic examination of each woman who comes to a gynecologist for any reason. Colposcopic and cytological cervical examination play the most important role in this examination. Over the period from 1993 to 2000, 231 cases of low-grade squamous intraepithelial lesions (LSIL) and 101 cases of high-grade squamous intraepithelial lesions (HSIL) were revealed. The highest number of patients with SIL were younger than 40 and had suspicious Pap smear. The colposcopic findings were atypical in more than 80%. The infection caused by high oncogenic HPV types (16,18) was rather high and it was present in 68.75%. We conclude that it is necessary to apply and respect cytological and colposcopic examinations as complementary methods for early detection of premalignant cervical changes. Opportune cervical screening is very applicable in practice and should be everyday, routine examination in each gynecological office.*

<sup>1</sup>HEALTH CENTER "RUMA", GYNECOLOGICAL DEPARTMENT,  
RUMA, YUGOSLAVIA  
<sup>2</sup>INSTITUTE OF ONCOLOGY SREMSKA KAMENICA, SREMSKA  
KAMENICA, YUGOSLAVIA

**KEY WORDS:** *Cervical Intraepithelial Neoplasia; Mass Screening*

*Archive of Oncology 2001,9(3):165-170©2001,Institute of Oncology Sremska Kamenica, Yugoslavia*

## INTRODUCTION

According to the Bethesda classification cervical epithelial lesions are divided into squamous intraepithelial lesions (SIL) of low grade (LG) and high grade (HG). The first group (low-grade squamous intraepithelial lesions-LSIL) consists of cervical intraepithelial lesions grade I (CIN I) and of changes with HPV cytopathic effect (condylomas and cervicitis chronic condylomatosa). LSIL are caused by HPV infection of low oncogenic potential, most often of the 6 and 11 types, and rarely of the 42, 43 and 44 types. The second group of changes (high-grade squamous intraepithelial lesions-HSIL) consists of CIN II and CIN III.

They are most often associated with HPV infection caused by viruses of high oncogenic potential (types 16,18,45 and 46) and somewhat less frequently with infection caused by viruses of intermediary oncogenic potential (types 31,33, 51 and 52) (1). Over the last ten years HPV infection has become one of the most frequent sexually transmittable diseases (2). One of the major problems in modern gynaecological oncology is early diagnosis of this premalignant disease of the uterine cervix but not treatment of progressive cervical carcinoma. Having in mind the prevalence of this disease as well as its malignant potential, early diagnosis and adequate treatment of SIL take very important place in the struggle against the cervical cancer. This attitude is justified in ethic sense (life quality of patients is better as less radical methods of therapy are being applied), personnel sense (a smaller medical team is involved) and financial sense (expensive radical operations, radio and hemio therapy and rehabilitation of patient are avoid). There are noninvasive, quick and simple methods for the follow-up of all changes of the cervix from their initial devel-

Address correspondence to:

Dr. Jadranka Ravić, Health Center "Ruma", Gynecological Department, Orlovićeva bb, 22400 Ruma, Yugoslavia

The manuscript was received: 12. 07. 2001.

Provisionally accepted: 23. 07. 2001.

Accepted for publication: 28. 08. 2001.

opments to malignant stages, and this is a relatively long period (from 15 to 20 years, even longer). It gives us enough time to detect them in the stages when they are completely curable. The aim of this paper was to analyze all diagnosed cases of SIL and to emphasize the importance of opportune screening of women in early detection of precancerous lesions of the uterine cervix.

**MATERIALS AND METHODS**

The retro-prospective data analysis used the eight-year material of the Outpatient Department of Women's Health Care in Ruma (from 1993 to 2000). The Outpatient Department of Women's Health care in Ruma introduced opportune screening of women from 1993, in order to prevent development of cervical cancer. Opportune screening implies systematic examination of each woman who comes to a gynecologist for any reason. It includes examination by the speculum, bimanual gynecological examination, cytological and colposcopic cervical examination with Schiller's trial, the analysis of the vaginal smear and, if necessary, bacteriological analysis of the vaginal and cervical smears as well as HPV typization (the following HPV types being determined: 6,11,16,18,31 and 33). Over this period, 231 cases of LSIL and 101 cases of HSIL were revealed by the opportune screening of women. All cases of the detected SIL were verified histologically and the biopsy was taken on the basis of cytological and/or colposcopic finding. All cytological smears were examined by the same gynecologist-cytologist. The colposcopic findings were obtained from three gynecologists and taken from the patients' files. Patients were analyzed according to their age prior to the comparison of colposcopic and cytological findings with histological results. The analysis of the HPV typization results was done at the end. Standard statistical methods were applied.

**RESULTS**

The mean age of patients with LSIL was 35 (range age: 18-66) and with HSIL was 35.6 (range age: 20-61). Table 1 shows that the highest number of patients with SIL were younger than 40 (65.80% for LSIL and 71.28% for HSIL).

**Table 1.** Distribution of patients by age

	< 20	20-24	25-29	30-34	35-39	40-44	45-49	50-54	55-59	>59	Σ
n	8	28	29	42	45	30	32	8	4	5	231
LSIL %	3.47	12.12	12.55	18.18	19.48	12.99	13.85	3.47	1.73	2.16	100.00
											<b>65.80 %</b>
n	0	5	15	27	25	19	8	1	0	1	101
HSIL %	0.00	4.95	14.85	26.73	24.75	18.82	7.92	0.99	0.00	0.99	100.00
											<b>71.28%</b>

Table 2 shows the cytological findings of SIL. The largest number of patients (52.81%) with LSIL, however, had suspicious Pap smear (in 11.69. % Pap smear was II with clearly defined koilocytosis without cell atypia and in 41.12% it was III and IV). And

the largest number of patients (61.38%) with HSIL had pathological Pap smear (in 50.49% Pap was III and in 10.89% Pap was IV), too.

**Table 2.** Cytological findings of SIL

	not done	II	Pap smear				Σ
			II (with koilocytosis)	III	IV	V	
n	14	95	27	93	2	0	231
LSIL %	6.06	41.13	11.69	40.26	0.86	0.00	100.00
				<b>52.81%</b>			
n	20	19	0	51	11	0	101
HSIL %	19.81	18.81	0.00	50.49	10.89	0.00	100.00
					<b>61.38%</b>		

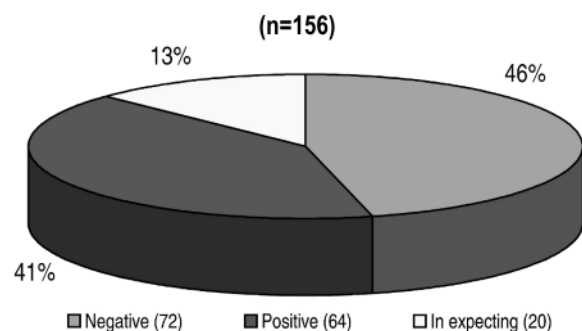
The colposcopic findings were atypical in 81.82% of LSIL and in 87.12% of HSIL as shown in Table 3. The table is showing that the most common atypical colposcopic findings were punctation for LSIL (19.05%) and atypical transformation zone (ATZ) for HSIL (34.65 %).

**Table 3.** Colposcopic findings of SIL

	LSIL		HSIL	
	n	%	n	%
Not done	2	0.87	3	2.97
Epithel squamous (Sch+)	6	2.60	2	1.98
Ectopia, TTZ.	34	14.71	8	7.93
Mosaic	36	15.58	16	15.84
Leucoplakia	16	6.93	3	2.97
Base	44	19.05	16	15.84
Acetowhite epithel	0	0.00	4	3.96
Condyloma	26	11.25	4	3.96
ATTZ	34	14.71	35	34.65
ATV	9	3.90	0	0.00
Iodine silent area	10	4.33	1	0.99
Atrophy	1	0.43	0	0.00
Erosion vera	2	0.87	3	2.97
Leucoplakia, Base	1	0.43	1	0.99
Mosaic, Base	9	3.90	4	3.96
Leucoplakia, Mosaic	2	0.87	1	0.99
Σ	231	100.00	101	100.00
Suspicious	189	81.82	88	87.12

TTZ: typical transformation zone, ATTZ: atypical transformation zone, ATV: atypical vascularisation

HPV typization was done only in patients with LSIL (n=156, because it was not performed in 75 patients from different reasons). Figure 1 shows the results of HPV typization performed in 67.53% patients.



**Figure 1.** Results of HPV tipization (n=156)

The infection caused by high oncogenic HPV types (16,18) was present in 44 patients (68.75%), as shown in Figure 2.

Figure 3 shows therapy which was done in patients with positive HPV 16,18 (n=44). Four women refused further therapy (the most frequent cause being gravidity developed in the meantime).

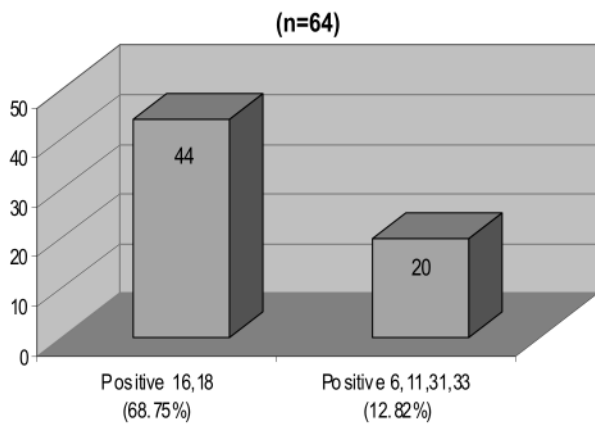


Figure 2. Results of positive HPV infection (n=64)

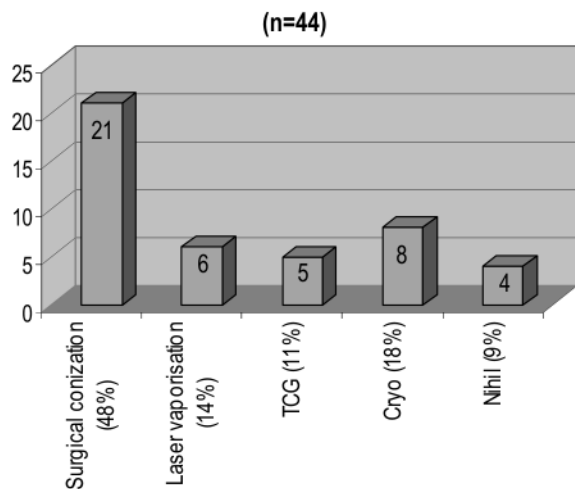


Figure 3. Therapy in cases of positive HPV 16,18 (n=44)

Figure 4 shows the results of histological findings of the conizates obtained by cervical conization in patients with LSIL and positive HPV 16,18 (n=21). It also shows that 34% patients were found to have a change with worse prognosis (HSIL and Ca microinvasivum).

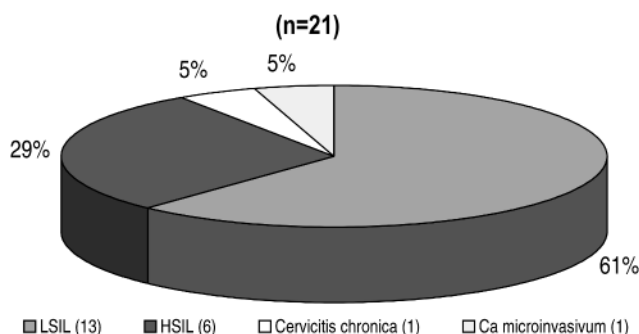


Figure 4. Histological results of the conizates (positive HPV 16,18) (n=21)

Figure 5 shows the therapy which was done in patient with HSIL (n=82; 9 patients are in preoperative preparing while 10 patients refused further therapy the most common reason being gravidity). Histological findings of the conizates obtained by cervical conization in patients with HSIL are shown in Figure 6. It shows that 5%

patients were found to have a change with worse prognosis (Ca microinvasivum).

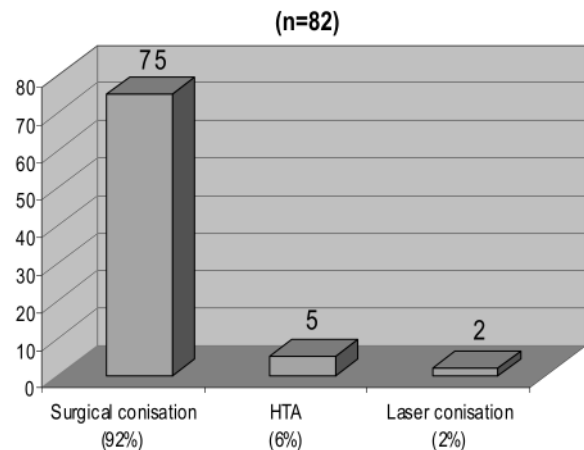


Figure 5. Therapy in HSIL cases (n=82)

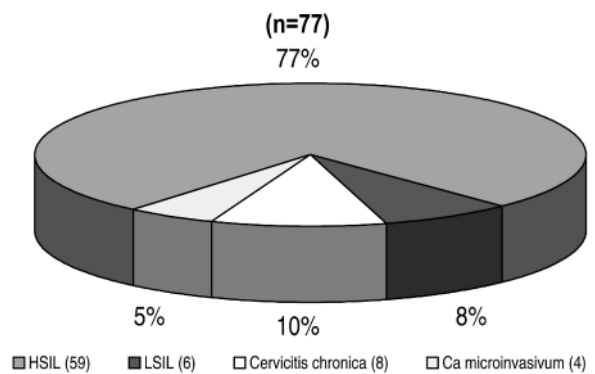


Figure 6. Histological results of the conizates in HSIL (n=77)

## DISCUSSION

Most of the authors agree that there is a clear causative relation between HPV infection, on one side, and the cervical cancer and its preinvasive forms, on the other (2-4). The increasing number of authors believes that the SIL incidence and prevalence are getting higher (5-7). According to Dexeus (8) HPV infection is a disease of all generations of women aged from 25 to 60. In his Canadian study, Meisels (9) stated that the majority of patients having HPV infection belonged to 20-40 age group. These results coincide with the range age of our patients with LSIL (18-66). Studies from the '50s had rarely detected dysplasia of the moderate and severe grade (current HSIL) in women less than 25 years of age, but in patients belonging to the 35-40 age group (10,11). Some recent studies from the '90s also provided similar results. Thus, Sadeghi (12) stated that peak for HSIL was 35-39 years of age and Bjorge (13) pointed rate in women under 40 years. Almost identical conclusion was obtained by our analyses, which showed that 71.28% patients with HSIL were 20-39 years old. Mean age of patients with LSIL as given by Insacco (14) was

39.71. According to Chon (15) and Pengsaa (16) the mean age of patient with HSIL was 44 and 38.19, respectively. Our results showed much lower mean age, 35.00 for LSIL and 35.6 for HSIL. The extreme data, as for the age of the diseased, are given by Schiffman (17), who states that HSIL is nowadays found even in adolescents under 15 years of age. According to our results, not a single person with HSIL was younger than 20, whereas only 19.8% were under 30 years of age. The greatest number of our diseased of SIL belongs to 30-45 age group. The data about cytological findings of SIL are different in literature. Thus, Sopracordevole diagnosed HPV infection on the basis of 66.67% of cytological findings (18). In his study, he found false negative smears in 15.38%. Becker pointed to a high percentage of normal cytological findings (Pap II was 55.90%) (19). The above stated contributes to the investigations done by Syrjanen (20) who found HPV infection in 15.20% of 109 patients with normal cytological findings and, thus, concluded that normal cytological finding could not guarantee the absence of HPV infection of the cervix. He also concluded that the Pap smear, although sensitive enough for detection of clinical manifestations of HPV infection, was insufficiently sensitive for detecting subclinical and latent HPV infection of the genital tract. Sadeghi and (12) pointed to a very poor cytological screening of SIL, by which he found CIN I and CIN II in 2.2% and CIN III only in 0.2% of all smears in the period from 1981 to 1983. Fetherson (21/) said that false negative cytological findings could be found in even up to 50% of patients with premalignant changes of the cervix as well as with cervical carcinoma, which was confirmed by Saks (22) and Kanajet (23), who found this percentage to be 40. Mitchell showed that 30% of women with HSIL had negative cervical cytology (24). Sopracordevole (18) pointed to the extraordinary good cytological detection of SIL. He diagnosed these changes on the basis of 84.62% cytological findings of the Pap III and IV groups, while only 15.38% of these findings were false negatives. Similar results were reported by Milojković (25), who had about 80% of cytological findings of the Pap III, IV and V group in HSIL. In our investigations SIL could be expected in more than 50% to 60% of the cases on the basis of all cytological findings. Bearing in mind a relatively high percentage of inadequate cytological findings (about 25% for both, LSIL and HSIL), it would be necessary to pay more attention when taking cervical smear, along with previous treatment of local inflammation. This should result in lower number of false negative findings and in higher number of the correct positive ones. According to Insacco (14) colposcopy confirmed HPV infection in only 2.02% and the most frequent colposcopic findings in cases of LSIL was ATZT (83.32%), followed by typical transformation zone (TZT) (14.66%). Kanajet (23) pointed to a very low number of suspicious colposcopic findings

(18.28%) in dysplasias of various grades and cervical carcinoma. Somewhat higher percentage of suspicious colposcopic findings (47.62%) was reported by Tuskan (26/) Contrary to these authors, Garrido (27) found even 88% of suspicious colposcopic findings in the patients with HSIL. Syrjanen (20) did not find even a single normal colposcopic finding in the examined patients; TZT was found only in 6.5% of the patients, whereas the finding was suspicious in all other patients. Diversity of colposcopic findings dominates in our investigations, which contributes to Garrido and Syrjanen's results. Normal squamous epithel, TZT and ectopy were found in 17.31% of the patients with LSIL and in 9.91% in HSIL, whereas in more than 80% of the examined women colposcopic finding was pathological with dominating punctation and mosaic (15.84%, respectively) of LSIL and mosaic and ATZT (15.58% and 14.71%, respectively) of HSIL. Peedicayil (28) concludes that if the Pap smear is negative and neoplasia is clinically suspected, colposcopy reveals at least grade II cervical intraepithelial neoplasia in 5% of patients. The analysis of our results showed that colposcopic correlation of SIL changes was excellent, because of sensitivity and accuracy of Pap test and colposcopy. The analysis of the results of HPV typization showed that the percentage of infection caused by HPV types of high oncogenic potential (16,18) was very high (68.75%). This percentage was even lower (44.83%) in the study performed by Thomas /1/, and Sopracordevole (only 16.67%) /18/. HPV tipization was not performed in 75 patients (32.47%). Of forty patients (17.32%) who had refused HPV typization (for financial reasons or mature age), 18 underwent destructive methods of treatment (cryotherapy, electrocauterization and laser vaporization), while 22 were being surveyed actively (regular cytological and colposcopic examinations). Cytological and colposcopic check-up, with repeated cervical biopsy, showed that LSIL progressed within two years into HSIL in two patients of those who had refused treatment. Both of them were subjected to the cervical conization. Thirty-five patients (15.15%) did not come for the gynecological check-up even after repeated invitation, death of non-gynecologic nature, total hysterectomy for other gynecologic surgical indications etc. No therapeutically measures were taken in these patients, for plausible reasons, and, therefore, there are no data on further development of LSIL.

In order to attain early cervical cancer detection many countries apply national screening programs for cervical cancer which give different results in reducing of cervical cancer morbidity and mortality (29, 30, 31). The majority of these programs has in common that accent is put on the organized summons of the wide female population for taking Pap smears (so called population screening) and colposcopy is not applied until abnormal Pap smear appears. Having in mind both advantages and disadvan-

tages of this method and the fact that it is almost impossible (and too expensive) to examine the whole sexually active female population in one country, the method suggested in this report could be acceptable in everyday routine practice in each gynecological outpatient department. Stanimirovic B. (32) and Kesic V. (33) also pointed out to the importance of the application of descriptive way of work.

## CONCLUSION

Cytological examination of the cervix indicated the presence of precancerous changes of the cervix in a high percentage (about 60%), but even higher percentage (81-87%) of these changes was revealed by the cervical colposcopic examination.

Both methods, applied individually, are relatively good methods in early detection of precancerous changes of the cervix. However, since the cervical biopsy was taken from all patients on the basis of cytological and/or colposcopic finding, it was necessary to apply and respect both of these methods as complementary methods for early detection of premalignant cervical changes.

High percentage (68.75%) of infection caused by HPV types of high oncogenic potential (16,18) justified absolutely the active attitude of the gynaecologist working at the Outpatient Department of Women's Health Care in Ruma regarding detection and identification of HPV.

Because conization, having been undertaken as a therapeutical measure in HPV infection by high oncogenic types, was followed by changes in 34% of the patients demanding such and even more radical treatment (HSIL, *Ca microinvasivum*), we concluded that the cervical conization in such cases was even more justifiable as a therapeutically method than destructive methods of treatment.

## REFERENCES

1. Thomas CW. VII Precancerous lesions of the cervix. In: Kurman JR, ed. Pathology of the female genital tract. 4 ed. Berlin: Springer Verlag; 1993. p. 229-61.
2. Koutsky LA, Galloway DA, Holmes KK. Epidemiology of genital human papillomavirus infection. *Epidemiol Rev* 1988;10:122-63.
3. Wright TC, Richart RM. Role of human papillomavirus in the pathogenesis of genital tract warts and cancer. *Gynecol Oncol* 1990;37:151-64.
4. zur Hausen H. Human papillomaviruses in the pathogenesis of anogenital cancer. *Virology* 1991;184:9-13.
5. Robboy SJ, Noller KL, O'Brien P, Sadeghi SB. Increased incidence of cervical and vaginal dysplasia in 3980 diethylstilbestrol (DES) exposed young woman: Experience of the National collaborative DES-Adenosis (DESAD) project. *JAMA* 1984;252:2979-83.
6. Sadeghi SB, Hsich EW, Gunn S. Prevalence of cervical intraepithelial neoplasia in sexually teenagers and young adults. *Am J Obstet Gynecol* 1984;148:726.
7. Klemm PR, Guarnieri C. Cervical cancer: a developmental perspective. *J Obstet Gynecol Neonatal Nurs* 1996;25(7):629-34.
8. Dexeus S, Rubio R, Bassols G, Jakob D, Ojeda J, Labastida R. Papilloma virus infection. Precancer and epidermoid cancer. *Eur J Gynaec Oncol* 1992;13:167-76.
9. Meisels A. Cytologic diagnosis of human papillomavirus. Influence of age and pregnancy stage. *Acta Cytol* 1992;36:480-2.
10. Cramer DW, Cutler SJ. Incidence and histopathology of the malignancies of female genital organs in the United States. *Am J Obstet Gynecol* 1974;118:443.
11. Patten SF Jr. Diagnostic cytology of the uterine cervix. Baltimore: Williams and Williams; 1969.
12. Sadeghi SB, Sadeghi A, Robboy SJ. Prevalence of dysplasia and cancer of the cervix in a nation wide Planned Parenthood population. *Cancer* 1988;61:2359-61.
13. Bjorge T, Gunbjorud AB, Langmark F, skare GB, Thoresen SO. Cervical mass screening in Norway - 510.000 smears a year. *Cancer Detect Prev* 1994;18(6):463-70.
14. Insacco E, De Matteis B et al. Risk of progression in Low grade squamous intraepithelial lesions. *Eur J Gynaec Oncol* 1992;13:326-30.
15. Chon P, Lai My, Chang Hy. Epidemiology of cervical cancer in the screened population in Taiwan, 1979-1984. *Chung-Hua-J-HSueh-Tsa-Chih-Taipei* 1990;45:209-21.
16. Pengsaa P, Vatanasapt V, Sri-Amporin S, Udomthavornsuk B. Cervical cancer in Khon Khaen University Hospital, Thailand 1985-1990. *Eur J Gynaec Oncol* 1993;14:331-5.
17. Schiffman MH. Recent progress in defining the epidemiology of human papillomavirus infection and cervical neoplasia. *J Natl Cancer Inst* 1992;84:394-8.
18. Sopracordevole F, Cadorin L, Muffato, De Benetti L, Parin A. Papanicolau smear chances to be diagnostic for cervical squamous intraepithelial lesions (SIL) with or without detectable HPV DNA in situ hybridization nalysis. *Eur J Gynaec Oncol* 1993;14:336-8.
19. Becker MT, Wheeler MC, McGough SN, Jordan WS, Dorin M, Miller J. Cervical Papillomavirus infection and cervical dysplasia in hispanic, native american and non hispanic white women in New Mexico. *Am J Pub Health* 1991;81:582-6.
20. Syrjanen S, Saastamoinen J, Chang F, Ji H, Syrjanen K. Colposcopy, punch biopsy, in situ DNA hybridization, and polymerase chain reaction in searching for genital human papillomavirus (HPV) infection in women with normal PAP smears. *J Med Virology* 1990;31:259-66.
21. Fetherson WC. False-negative cytology in invasive cancer of the cervix. *Clin Obstet Gynecol* 1983;26:929-37.
22. Saks A, Kodric T, Novak S, Vlavisavljevic V. Results of prospective cytologic diagnosis in cervical intraepithelial neoplasia. *Jug Ginecol Opstet* 1983;23:103-5.
23. Kanajet D, Grubišić G. Preinvasive malignant cervical changes. *Jug Ginek Opstet* 1977;17:1-7. (In Serbian)
24. Mitchell H, Higgins V. Recent negative cytologi prior to histologically confirmed carcinoma in situ of the cervix. *Aust-N-Z-J-Obstet Gynaecol* 1994;34(2):178-81.
25. Milojkovic M, Pajtler M, Makarovic Z, Ledererr B, Jarcov R. One-year results of precancerous and cervical cancer lesions detection in Baranja. *Jugosl Ginekol Perinatol* 1986;26:119-22. (in Serbian)
26. Tuskan E, Tyrolt B. Importance of systematic examinations in early cervical cancer detection in Karlovac. *Libri Oncol* 1972;1(4):165-70. (in Serbian)
27. Garrido JL. Analysis of the cancer cases in the Republic of Panama 1982-

1989. *Eur J Gynaec Oncol* 1993;14:419-24.

28. Peedicayil A, Regi A, Mathai M et al. Colposcopy in women with a normal Papanicolaou smear. *Natl Med J India* 1994;7(5):208-9.
29. de Ruiz AP. Screening Programs for Cervical Cancer in Mexico. In: 14th International Congress of Cytology, Amsterdam, May 2001:A:18.
30. Arbyn M, Vergote I, Wynsberghe C. Organised cervical screening in Belgium: Achievements and possibilities for the future. 14th International Congress of Cytology, Amsterdam, May 2001:A:37.
31. Della Palma P, Ronco G, Vettorazzi M, Scarinci M, Pilutti S, Iossa A, et al. Screening for Cervical Cancer in Italy. 14th International Congress of Cytology, Amsterdam, May, 2001:A:142.
32. Stanimirović B. Protocol of procedure in discovering and treatment neoplasias of lower genital tract in women. In: Stanimirović B, Antić N, Atanacković J, Babić M, Berisavac M, Bošković V et al, eds. Pathology of cervix, vagina and vulvae. Colposcopic atlas. Beograd: Elit-Medica; 1999. p. 203-5.
33. Kesic V. Normal and pathological colposcopic findings. In: Stanimirović B, Antić N, Atanacković J, Babić M, Berisavac M, Bošković V et al, eds. Pathology of cervix, vagina and vulvae. Colposcopic atlas. Beograd: Elit-Medica; 1999. p. 225-31.