

AGENESIS OF THE GALLBLADDER: A CASE REPORT

Aleksandar Zlatić¹, Miodrag Djordjević¹, Milan Korica^{3,4},
Goran Petaković^{3,4}, Radovan Veljković^{3,4}

Congenital agenesis of the gallbladder is a rare anatomical abnormality. A 75-year-old woman was admitted with a history of intermittent pain in the right upper abdominal quadrant in the past few weeks, suggestive of biliary colic. A physical examination showed some mild tenderness in the right upper abdominal quadrant. Abdominal ultrasonography was interpreted as "images consistent with a contracted gallbladder with multiple small stones". Multislice computerized tomography showed a common bile duct dilatation, and a mild intrahepatic dilatation of the left and right hepatic duct. Computerized tomography did not reveal any presence of gallbladder stones. Magnetic retrograde cholangiopancreatography did not show any anatomical variations and anomalies. Intraoperative ultrasonography failed to locate the gallbladder inside the liver. Intraoperative cholangiography confirmed the diagnosis of gallbladder absence, as well as absence of cystic duct and common bile duct stones. The patient recovered after surgery without any complications. A follow-up examination, one year after the surgery was without any complaints or complications.

Acta Medica Medianae 2018;57(1):103-108.

Key words: *gallbladder, gallbladder agenesis, biliary tract abnormality*

¹Clinic for Digestive Surgery, Department of Hepatobiliary and Pancreatic Surgery, Clinical Center, Nis, Serbia

²University of Nis, Faculty of Medicine, Nis, Serbia

³Clinic for Abdominal, Endocrine and Transplantation Surgery, Clinical Center of Vojvodina, Novi Sad, Serbia

⁴University of Novi Sad, Faculty of Medicine, Novi Sad, Serbia

Contact: Aleksandar Zlatić
Clinic of General Surgery, Clinical Center of Niš, Serbia
E-mail: drzlatiac@mts.rs

port was subjected to preoperative abdominal ultrasonography (US) which revealed gall stones. Other preoperative biliary imaging studies, such as multislice computerized tomography (MSCT) and MRCP, did not indicate any anatomic variations and anomalies. Both diagnostic imaging techniques suggested the need for a surgical intervention. The study presents a CAGB case detected by intraoperative exploration, as well as the shortcomings of the applied diagnostic and surgical methods.

Case report

A 75-year-old woman arrived to the surgical department with a history of intermittent pain for a few weeks in the right upper abdominal quadrant suggestive of biliary colic. The pain was exacerbated by eating, especially fatty foods. Recurrent episodes of pain occurred for six months. Clinically visible jaundice was found a week before admission. There was no relevant medical or family history of biliary disease.

Physical examination was in order, except for a mild tenderness in the right upper abdominal quadrant. Standard laboratory blood analyses showed atypical changes in total bilirubin - 50.1 µmol/L (normal range 1 to 20 µmol/L); serum glutamic-oxaloacetic transaminase - 276 U/L (normal range 5 to 48 U/L); alkaline phosphatase - 352 U/L (normal range 30 to 115 U/L); gamma-glutamyltransferase - 541 U/L (normal range 1 to 38 U/L); and lactate dehydrogenase - 491 U/L (normal range 120 to 246

Introduction

Congenital agenesis of the gallbladder (CAGB) is a rare anatomical abnormality. CAGB is usually asymptomatic; however, if symptomatic, it is accompanied with dyspepsia, nausea, vomiting or abdominal pain (1). Despite an absent gallbladder, half of the patients had symptoms resembling chronic cholecystitis or biliary colic (2). Isolated CAGB is extremely rare, with incidence ranging between 0.013 and 0.075% (3). CAGB may be associated with other congenital malformations (4, 5). Routine diagnostic methods frequently fail to diagnose gallbladder agenesis, and if not suspected, patients end up with a surgical intervention (5). However, nowadays, magnetic resonance cholangiopancreatography (MRCP) is a preoperative diagnostic method of choice for CAGB detection (1). The patient described in this case re-

U/L); leukocyte count - $9.1 \times 10^9/L$ (normal range 4 to $10 \times 10^9/L$). Other laboratory parameters and urine analysis were within normal limits.

Abdominal US was interpreted as "images consistent with a contracted gallbladder with multiple small stones". MSCT showed common bile duct dilatation (up to 18mm) and initial intrahepatic dilatation of the left and right intrahepatic duct (9 mm and 12 mm, respectively). MSCT did not show the presence of gallstones. Furthermore, MSCT showed common bile duct stones and one impacted stone in the region of the papilla of Vater. MRCP confirmed bile stones and showed no anatomic variations and anomalies. After a review of both imaging studies, the radiologist indicated the need for surgical consultation. Since the symptoms did not resolve after conservative treatment, surgery was indicated.

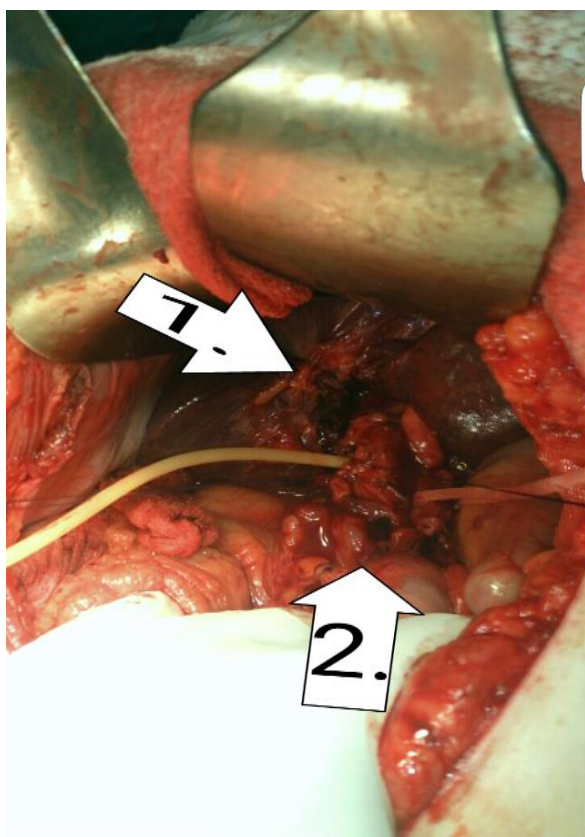


Figure 1. Position of the common bile duct before dissection (pointer 1), and position of the duodenal fistula after the separation (pointer 2) with T tube before cholangiography

The patient was classically operated because laparoscopy was not considered suitable for the case. Surprisingly, gallbladder was not found in the area of the gallbladder bed. An intraoperative dissection revealed that the common bile duct was deformed as protruding out of the liver (Figure 1, pointer 1). A very careful exploration of the falciform ligament, retrohepatic, retroduodenal, retropancrea-

tic, retroperitoneal space, left side of the abdominal cavity and within the lesser omentum did not reveal the presence of gallbladder or cystic duct. Moreover, intraoperative US failed to locate the gallbladder inside the liver. The detected fistula between the common bile duct and duodenum (Figure 1, pointer 2) was disassembled during surgery in the further course of the operation.

After insertion of a T tube, an intraoperative tube cholangiography confirmed the diagnosis of absent gallbladder, absent cystic duct and gallstones in the common bile duct (Figure 2).

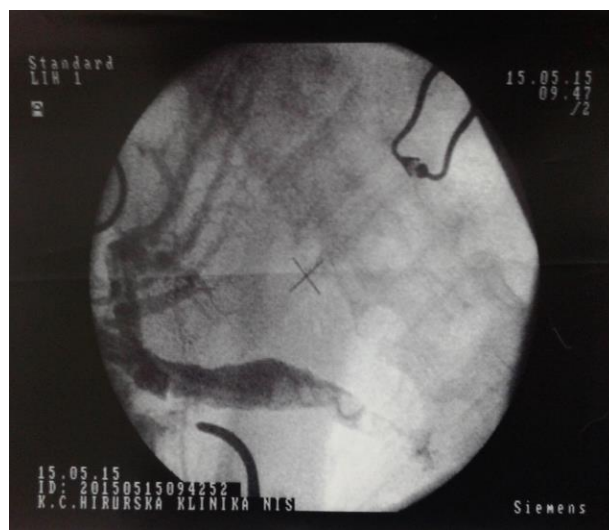


Figure 2. Intraoperative cholangiography confirming an absent gallbladder, absent cystic duct and common bile duct stones

The common bile duct was full of gallstones after the opening. The T tube was removed and the bile stones were washed out. After the removal of the stones from the common bile duct, the remaining digestive tract was operated with biledigestive Roux bypass. The procedure was chosen because of the suspicion of intrahepatic bile stones, bad quality of the common bile duct wall and duodenal wall, as well as bad duodenum contrast filling. The patient recovered well after surgery and was discharged on the 10th day after surgery. The follow-up visit 2 weeks after the discharge revealed no complications. The last follow-up visit one year after the surgery showed a healthy patient with no complaints and no signs of biliary system disease.

Discussion

CAGB is rare congenital anomaly characterized by the absence of the gallbladder with a normal bile duct system. CAGB is often associated with congenital abnormalities in other systems in approximately 30% (6). It can occur anytime during lifetime, most commonly at the median age of 46 years. The incidence in clinical series ranges from

0.007% to 0.027%, and in autopsy reports from 0.04% to 0.13% (6). The prevalence range is from 0.007% to 0.13% (3, 7). It is almost always an incidental finding at surgery or autopsy (1). Women to men ratio in clinical trials ranges three to one similar to other biliary diseases, but the autopsy reports suggest an equal (1:1) ratio (8).

Gallbladder agenesis is rare and occurs during embryonal development. In the fourth week of development, cranial and caudal part of the hepatic diverticulum develop from the hepatic diverticulum (9). From its larger caudal part, the liver parenchyma and intrahepatic biliary epithelium develop (4). The gallbladder and the cystic duct form from small vessels from the smaller caudal part (10). The anomalies that evolve during embryonal development may be in the form of gallbladder agenesis alone or with the absence of the cystic duct and many others congenital anomalies (1, 9, 11). The etiology of CAGB is unknown, but the reports of familial occurrence suggest a possible hereditary origin (4). Genetic factors may play an important role in the pathogenesis (12, 13).

Individuals with CAGB can be divided, according to Bennion (14), into 3 categories: 1) healthy subjects without symptoms (30% to 60%); 2) symptomatic patients (30% to 40%); and 3) patients with multiple congenital anomalies (15% to 30%). In his case report (12) in 2015, Li Ming Tang added 2 subcategories in the 3rd Bennion category: 3A) patients with lethal anomalies (15), and 3B) patients with nonlethal anomalies (5, 12).

Symptomatic patients have the symptoms suggestive of cholelithiasis (15). Most patients have right upper abdominal pain (90%), dyspepsia (30%), nausea and vomiting (66%), intolerance to fatty food and jaundice (12, 16, 17). With these patients it is difficult to determine what causes the symptoms. One of the explanations of the symptoms and clinical features is the combined biliary dyskinesia and constant pressure rise in the sphincter of Oddie. Some patients have a dilated common bile duct that takes up the function of bile storage. Finally, cholestasis arises from biliary dyskinesia and the resulting infection leads to future formation of common bile duct stones (5).

Around 40% to 60% of patients show the symptoms consistent with biliary disease: nausea, right upper abdominal pain, vomiting, bloating, and fatty food intolerance, as demonstrated in our case. In addition, 25% to 50% have choledocholithiasis with symptoms such as fever, chills, biliary colic and jaundice, as in our case presented above (18, 19).

Biliary tract diseases are diagnosed based on the usual imaging methods. Currently, these are abdominal US and MSCT. This led to a unique problem in diagnosing CABG, since cystic duct obstruction, chronic cholecystitis and gallbladder agenesis all lead to non-visualisation of the gallbladder and cystic duct with both modalities (8, 20, 21).

Preoperative diagnosis of CAGB is extremely difficult. Patient symptoms, ultrasonographic findings suggestive of gallbladder disease, lack of other reasonable clinical diagnoses, and rarity of this entity,

weigh heavily in favor of the diagnosis of biliary tract disease. Our 75-year-old patient presented the symptoms of biliary tract disease that was later determined to be caused by gallbladder agenesis. Our patient was jaundiced, with suspected common bile duct stones. Ultrasonography of the right upper abdominal quadrant showed multiple hyperechogenic loci with significant shadowing in the gallbladder bed region. Ultrasonography of the same patient further demonstrated similar findings suggestive of multiple gallstones in a contracted gallbladder.

Ultrasonography, with its high sensitivity, is now the modality of choice for preoperative imaging of the gallbladder and acute biliary disease. In CAGB, intestinal loops occupy the expected location of the gallbladder causing significant shadowing, with an appearance similar to that of a contracted gallbladder filled with stones. The cystic duct, if present, may not be visualized as the result of intense shadowing from intestinal gas (18, 19, 22). These findings were present in our case, in which gallbladder agenesis could not be distinguished from chronic cholecystitis associated with choledocholithiasis, or simply a contracted gallbladder with stones (23, 24).

MSCT scanning or ERCP may raise the suspicion of CAGB in patients with questionable sonographic findings (16). MSCT may be useful in detecting a gallbladder in an intrahepatic or abnormal location, or suggesting the diagnosis of CAGB if the gallbladder cannot be visualized (16, 22). In our case, biliary duct dilatation was noted on MSCT. Both imaging methods are useful preoperative and postoperative modalities for diagnosis confirmation and for clinical follow-up. ERCP may demonstrate an enlarged common bile duct without evidence of a cystic duct or its remnant. This leads to a misinterpretation typical for cystic duct obstruction in many biliary tract diseases (22). CABG is rarely thought of in the differential diagnosis (25). MRCP revealed no anatomic variations and anomalies, but after a review, the radiologist indicated consultation with a hepatobiliary surgeon. MRCP is a noninvasive procedure but is readily available (8, 26). It is able to indicate the diagnosis of CABG, as well as of other biliary anomalies and diseases (26). Hepatobiliary scintigraphy with ^{99m}Tc - IDA can now potentially detect gallbladder anomalies (19). Selective arteriography of the hepatic artery has been proposed as a diagnostic tool for CABG (16, 19), but it is a very invasive procedure (20, 23).

During the open surgery, we discovered a winding common bile duct in the gallbladder bed (Figure 1, pointer 1). The confirmation of a truly absent gallbladder was made with T tube intraoperative cholangiography (Figure 2). Intraoperative cholangiography (16) should always be performed when gallbladder agenesis is considered, because 25% to 50% of these patients have coinciding common bile duct stones, like it was in our case (15). Intraoperative US and cholangiography can help with the diagnosis (12). In our case we performed both these procedures.

We can propose a diagnostic-therapeutic algorithm for gallbladder agenesis. If the diagnosis is

made preoperatively:

A) Patients without common bile duct stones, should undergo ERCP searching for missing coinciding bile stones and to confirm the diagnosis; the treatment is medicamentous, conservative.

B) Patients with common bile duct stones, should undergo ERCP stone extraction (if possible) with endoscopic sphincterotomy. Further treatment is medical and conservative for symptomatic patients, or no treatment for patients without symptoms. If the extraction is not possible, open surgery is recommended. Some even propose laparoscopy to confirm the diagnosis (7, 21, 27).

In the case when the diagnosis is made during laparoscopy, procedure should be aborted after searching for ectopic gallbladder (7, 27). Laparoscopic exploration depends solely on surgical skills. The confirmation is made postoperatively using the imaging methods (7, 28). Some advocate a conversion to open procedure and confirmation of the diagnosis with intraoperative US and cholangiography, if available (21).

If the diagnosis is made during open surgery, a surgeon should proceed searching for ectopic gallbladder in all known localizations with intraoperative US and cholangiography (21, 28). The special circumstances are common bile duct stones and fistulas discovered during surgery, which dictate further operative solutions (21, 27, 28, 29). Interestingly, with most symptomatic patients with pain, the pain resolves after exploratory surgical procedure (8, 13, 24).

In our case, after searching for an absent gallbladder, a bilio-digestive fistula was found and separated (Figure 1, pointer 2). T tube cholangiography confirmed an absent gallbladder and common bile duct stones. After the removal of common bile

duct stones, the procedure was terminated with bilio-digestive anastomosis type side to side hepatico-jejunostomy. The reason for that was in the facts that common bile duct wall and duodenal wall were of bad quality and contrast duodenal filling was almost absent.

Conclusion

Agenesis of the gallbladder is a rare clinical entity most often diagnosed intraoperatively. Almost half of the patients have pain and symptoms of gallstones before the surgery. The other half are healthy subjects. The patients with CABG diagnosed preoperatively are referred for medical treatment, with or without potentially explorative laparoscopy. When CABG is incidentally diagnosed during laparoscopy, the procedure should be aborted and converted to laparotomy if the surgeon is not skilled enough to establish the diagnosis laparoscopically. When CABG is incidentally found during laparotomy, the procedure should continue and the diagnosis should be established. Although intraoperatively detected to have no gallbladder, most patients become asymptomatic postoperatively.

Acknowledgement: we are deeply thankful to the patient for allowing us and giving us a permission to use her information for this case report.

Informed consent: We obtained a written and signed consent from the patient to publish her information in the form of this case report. The manuscript was translated into her native language and she approved of its contents. The copy of the signed informed consent can be obtained from the Journal Editor or corresponding author.

References

1. Pierro A, Martucci M, Maselli G, Farchione A. Agenesis of the Gallbladder with the Presence of a Small Dysmorphic Cyst: Role of Magnetic Resonance Cholangiopancreatography. *J Clin Imaging Sci* 2012; 2(1), 2-17. [[CrossRef](#)][[PubMed](#)]
2. Singh B, Satyapal KS, Moodley J, Haffejee AA. Congenital absence of the gall bladder. *Surg Radiol Anat* 1999; 21(3): 221-224. [[CrossRef](#)][[PubMed](#)]
3. Singh S, Tayal A, Kaur V. Mystery of absent gall bladder: Surgical concerns and review of literature. *JIMSA* 2011; 24(2), 71.
4. Bani-Hani KE. Agenesis of the gallbladder: Difficulties in management. *Journal of Gastroenterology and Hepatology* 2005; 20(5), 671-5. [[CrossRef](#)][[PubMed](#)]
5. Waisberg J, Pinto Júnior PE, Gusson PR, Fasano PR, Godoy ACD. Agenesis of the gallbladder and cystic duct. *Sao Paulo Med J* 2002, 120(6), 192-4. [[CrossRef](#)][[PubMed](#)]
6. Lamah M, Karanjia ND, Dickson GH. Anatomical variations of the extrahepatic biliary tree: review of the world literature. *Clin Anat* 2001; 14(3), 167-72. [[CrossRef](#)][[PubMed](#)]
7. Chowbey PK, Dey A, Khullar R, Sharma A, Soni V, Bajjal M, et al. Agenesis of gallbladder - our experience and a review of literature. *Indian J Surg* 2009; 71(4), 188-92. [[CrossRef](#)][[PubMed](#)]
8. Malde, S. Gallbladder agenesis diagnosed intra-operatively: a case report. *J Med Case Rep* 2010; 4: 285. [[CrossRef](#)][[PubMed](#)]
9. Ando H. Embryology of the biliary tract. *Dig surg* 2010; 27(2), 87-9. [[CrossRef](#)][[PubMed](#)]
10. Joliat GR, Shubert CR, Farley DR. Isolated congenital agenesis of the gallbladder and cystic duct: Report of a case. *Journal of Surgical Education* 2013; 70(1): 117-20. [[CrossRef](#)][[PubMed](#)]
11. Serio S, Ghanem M. Gallbladder dysgenesis requiring reoperation for cholecystectomy: A case report. *Austin J Surg* 2015; 2(3): 1056.
12. Tang LM, Wang XF, Ren PT, Xu GG, Wang CS. The diagnosis of gallbladder agenesis: Two cases report. *Int J Clin Exp Med* 2015; 8(2): 3010-16. [[PubMed](#)]
13. Gotohda N, Itano S, Horiki S, Endo A, Nakao A, Terada N, et al. Gallbladder agenesis with no other biliary tract abnormality: report of a case and review of the literature. *J Hepatobiliary Pancreat Surg* 2000; 7: 327-30. [[CrossRef](#)][[PubMed](#)]
14. Bennion RS, Thompson JE Jr, Tompkins RK. Agenesis of the gallbladder without extrahepatic biliary atresia. *Arch Surg* 1988; 123: 1257-60. [[CrossRef](#)][[PubMed](#)]
15. Ishida M, Egawa S, Takahashi Y, Kohari M, Ohwada Y, Unno M. Gallbladder agenesis with a stone in the cystic duct bud. *J Hepatobiliary Pancreat Surg* 2008; 15(2): 220-3. [[CrossRef](#)][[PubMed](#)]
16. Cavazos-García R, Díaz-Elizondo JA, Flores-Villalba E, Rodríguez-García HA. Gallbladder agenesis. Case report. *Cir Cir* 2015; 83(5): 424-8. [[CrossRef](#)][[PubMed](#)]
17. Vijay KT, Kochar HH, Koti RS, Bapat RD. Agenesis of gallbladder - a diagnostic dilemma. *J Postgrad Med* 1996; 42: 80-2. [[PubMed](#)]
18. Chopra P J, Hussein SS. Isolated agenesis of the gallbladder. *Saudi Medical Journal* 2003; 24(4): 409-10.
19. Peloponissios N, Gillet M, Cavin R, Halkic N. Agenesis of the gallbladder: A dangerously misdiagnosed malformation. *World J Gastroenterol* 2005; 11(39):6228-31. [[CrossRef](#)][[PubMed](#)]
20. McCallum I, Jones MJ, Robinson SJ. Gallbladder agenesis. *Annals of the Royal College of Surgeons of England* 2014; 96(6): e28-e29. [[CrossRef](#)][[PubMed](#)]
21. Balakrishnan S, Singhal T, Grandy-Smith S, El-Hasani S. Agenesis of the gallbladder: lessons to learn. *JSL S* 2006; 10(4): 517-9. [[PubMed](#)]
22. Pradeep HDS, Prasad IHDS, Wickramarathna D, Liyanage CAH. (2015). An incidental finding of absent gall bladder in laparoscopic exploration - a rare occurrence in extra hepatic biliary anatomy. *Sri Lanka Journal of Surgery*; 33(2): 38-40. [[CrossRef](#)]
23. Fiaschetti V, Calabrese G, Viarani S, Bazzocchi G, Simonetti G. Gallbladder agenesis and cystic duct absence in an adult patient diagnosed by magnetic resonance cholangiography: report of a case and review of the literature. *Case Report Med* 2009; 2009: 674768. [[CrossRef](#)][[PubMed](#)]
24. Karatepe O, Altioek M, Battal M, Adas G, Bilgin Gülcicek O, Acet E, et al. Agenesis of the gallbladder as a rare misdiagnosis. *Open Medicine* 2009; 4(1): 128-30. [[CrossRef](#)]
25. Bayraktar Y, Balaban HY, Arslan S, Balkanci F. Agenesis of gallbladder and multiple anomalies of the biliary tree in a patient with portal thrombosis: A case report. *Turk J Gastroenterol* 2006; 17(3): 212-5. [[PubMed](#)]
26. Kasi PM, Ramirez R, Rogal SS, Littleton K, Fasanella KE. Gallbladder Agenesis. *Case Rep Gastroenter* 2011; 5: 654-62. [[CrossRef](#)][[PubMed](#)]
27. Laopodis V, Liasis L, Stephanidis P, Ntourakis D, Kadjianis F, Tzardis P. Congenital Agenesis of the Gallbladder: An Unpleasant Surprise During Laparoscopic Cholecystectomy. Case report. *Hellenic Journal of Surgery* 2010; 82(6): 378-80. [[CrossRef](#)]
28. Singh G, Rao K, Ghosh S, Chaudhry R. Congenital Absence of Gall Bladder. *Medical Journal Armed Forces India* 2003; 59(2): 152-3. [[CrossRef](#)]
29. Ayantunde AA. Symptomatic gallbladder agenesis in an elderly woman: Diagnosis and management dilemma. *Surgical Practice* 2006; 10(2): 84-6. [[CrossRef](#)]

Prikaz slučaja**UDC: 616.366-007**
doi:10.5633/amm.2018.0115**AGENEZA ŽUČNE KESE: PRIKAZ SLUČAJA***Aleksandar Zlatić¹, Miodrag Đorđević¹, Milan Korica^{3,4},
Goran Petaković^{3,4}, Radovan Veljković^{3,4}*¹Klinika za digestivnu hirurgiju, Departman za hepatobilijarnu i hirurgiju pankreasa, Klinički centar, Niš, Srbija²Univerzitet u Nišu, Medicinski fakultet, Niš, Srbija³Klinika za abdominalnu, endokrinu itransplantacionu hirurgiju, Klinički centar Vojvodina, Novi Sad, Srbija⁴Univerzitet u Novom Sadu, Medicinski fakultet, Novi Sad, Srbija*Kontakt: Aleksandar Zlatić**Klinika za opštu hirurgiju, Klinički centar Niš**Bul. dr Zorana Đinđića 48, 18000 NIŠ, Srbija**E-mail: drzlatiac@mts.rs*

Kongenitalna ageneza žučne kese je retka anatomska abnormalnost. Žena stara 75 godina hospitalizovana je sa istorijom intermitentnog bola u trajanju od nekoliko nedelja, u desnom gornjem abdominalnom kvadrantu, sa suspektom bilijarnom kolikom. Fizički pregled je ukazao na blagu bolnu osetljivost u desnom gornjem abdominalnom kvadrantu. Abdominalna ultrasonografija ukazala je na sliku "žučna kesa koegzistentna, kontrahovana, sa multiplim kamenjem manje veličine". Multislajsna kompjuterizovana tomografija ukazala je na dilataciju bilijarnog voda i blagu intrahepatičnu dilataciju levog i desnog hepaticnog voda. Kompjuterizovana tomografija nije ukazala na prisustvo kamenja u žuči. Holangiopankreatografska magnetna rezonanca nije pokazala nikakve anatomske abnormalne varijante, niti anomalije. Intraoperativna ultrasonografija nije uspela da otkrije žučnu kesu unutar tkiva jetre. Intraoperativna holangiografija potvrdila je dijagnozu odsustva žučne kese, kao i odsustvo cističnog voda i nalaza kalkuloze žučnog voda. Posle operacije, bolesnica se oporavila bez ikakvih komplikacija. Kontrolni pregled, godinu dana posle operacije, nije ukazao na bilo kakve tegobe, niti komplikacije.

*Acta Medica Medianae 2018;57(1):103-108.****Cljučne reči:*** žučna kesa, ageneza žučne kese, abnormalnost bilijarnog trakta