

## FLUORODEOXYGLUCOSE-POSITRON EMISSION TOMOGRAPHY INTEGRATED WITH COMPUTED TOMOGRAPHY IN SUSPECTED RECURRENT CERVICAL CANCER

### POZITRONSKA EMISIONA TOMOGRAFIJA SA KOMPJUTERIZOVANOM TOMOGRAFIJOM POMOĆU FLUORODEOKSIGLUKOZE KOD SUMNJE NA RECIDIV KARCINOMA GRLIĆA MATERICE

Milica Stojiljković<sup>1,2</sup>, Vera Artiko<sup>1,2</sup>

<sup>1</sup> Univerzitet u Beogradu, Medicinski fakultet, Beograd, Srbija

<sup>2</sup> Univerzitetski klinički centar Srbije, Centar za nuklearnu medicinu sa pozitronskom emisionom tomografijom, Beograd, Srbija

**Correspondence:** milica\_stoji@yahoo.com

#### Abstract

Carcinoma of the uterine cervix represents the fourth most common malignant tumor and the fourth leading cause of mortality from cancer in females, and approximately one third of women with cervical carcinoma diagnosis will develop relapse. In follow-up and suspicion of recurrence of cervical cancer, various imaging modalities such as computed tomography (CT), magnetic resonance imaging (MRI) and positron emission tomography/computed tomography (PET/CT) can be used. However, the role of PET/CT is constantly increasing in these patients and the latest National Comprehensive Cancer Network (NCCN) guideline Version 1.2023 recommends PET/CT as the imaging method of choice in follow-up of patients with disease stage II or higher, and in suspicion of recurrent or metastatic disease. PET/CT shows higher sensitivity and specificity than conventional imaging in suspected recurrent cervical cancer, particularly in the evaluation of distant recurrent sites. An additional benefit of PET/CT in these patients is its impact on treatment management in approximately half of them. Also, PET/CT has a prognostic role in progression-free and overall survival, and patients with positive PET/CT for recurrence have significantly worse prognosis.

#### Keywords:

cervical cancer,  
clinical impact,  
conventional imaging,  
positron emission  
tomography/computed  
tomography,  
prognosis,  
recurrence

## Sažetak

### Ključne reči:

karcinom grlića  
materice,  
klinički značaj,  
konvencionalni  
imidžing,  
pozitronska  
emisiona tomografija/  
kompjuterizovana  
tomografija,  
prognoza, recidiv

Karcinom grlića materice predstavlja četvrti najčešći malignitet i četvrti uzrok smrti od tumora kod žena u svetu. Približno trećina žena lečenih od cervikalnog karcinoma razvije recidiv bolesti tokom praćenja. U praćenju i kod sumnje na recidiv cervikalnog karcinoma koriste se različite imidžing metode kao što su kompjuterizovana tomografija (CT), magnetna rezonanca (MR) i pozitronska emisiona tomografija sa kompjuterizovanom tomografijom (PET/CT). Uloga PET/CT kod ovih pacijenata u konstantnom je porastu i najnoviji Vodič Nacionalne sveobuhvatne mreže za rak (engl. *National Comprehensive Cancer Network* - NCCN) ipak preporučuje PET/CT kao metodu izbora u praćenju pacijentkinja sa II - IV stadijumom bolesti, kao i kod sumnje na recidiv ili metastatsku bolest. Pozitronska emisiona tomografija sa kompjuterizovanom tomografijom je pokazala veću senzitivnost i specifičnost u odnosu na konvencionalni imidžing kod bolesnica sa sumnjom na recidiv karcinoma grlića materice, naročito u evaluaciji udaljene bolesti. Dodatna prednost PET/CT kod ovih pacijentkinja je njegov uticaj na odluku o terapiji kod približno polovine slučajeva. Takođe je pokazao prognostičku ulogu u predikciji preživljavanja bez pojave progresije, kao i ukupnog preživljavanja, s obzirom na to da pacijentkinje sa sumnjom na recidiv cervikalnog karcinoma koje imaju pozitivan nalaz na PET/CT imaju značajno lošiju prognozu.

## Introduction

Carcinoma of the uterine cervix represents the fourth most common malignant tumor and the fourth leading cause of mortality from cancer in females (1). It has even higher incidence and mortality rates in low and middle-income countries, representing the second most frequently diagnosed malignant tumor and having the third place in terms of cancer mortality in females (2). In Serbia, cervical cancer is the fourth most common malignancy in women and contributes to 5.6% of all newly diagnosed cancers (3).

Recurrent disease is characterized by tumor regrowth or occurrence of metastasis more than six months following the initial therapy. Approximately one-third of cervical carcinoma patients will present with relapse (4), and the greatest number of recurrences is shown to appear during the first 2 - 3 years of follow-up (2,5). In terms of treatment for cervical carcinoma relapse, choices are sparse. Women with local relapse could be eligible for radical therapy, where disease-free survival of a median of 57 months could be achieved in 45% of patients (6). On the other side, when the spread of disease is present, the only treatment options are either chemotherapy with a low success rate, or palliative treatment. Hence, prompt detection and improved localization of tumor relapse are important for better outcomes and longer survival times (7). In follow-up and suspicion of recurrence of cervical cancer, various visualization methods which include mainly morphological techniques such as computed tomography (CT) and magnetic resonance imaging (MRI), but also hybrid imaging with positron emission tomography/computed tomography (PET/CT), can be applied. Nonetheless, the latest National Comprehensive Cancer Network (NCCN) guideline Version 1.2023 recommends PET/CT as the imaging method of choice for follow-up of patients with disease stage II and higher, and for suspicion of recurrent or metastatic disease.

## Positron emission tomography with computed tomography

Fluorine-18 labeled analogue of glucose (2-deoxy-2-[<sup>18</sup>F]-fluoroglucose, i.e. FDG) is the most frequently used radiopharmaceutical for PET/CT examinations in oncology. It enters the cell via glucose transporter (GLUT), mainly GLUT1 and GLUT3, where it is subjected to phosphorylation by hexokinase to FDG-6-phosphate, which remains in the cell. After the phosphorylation process is completed, FDG is unable to leave the cells, subsequently being progressively accumulated within. According to the Warburg effect, malignant tumors show increased glycolysis levels, but also higher density of GLUT and higher hexokinase activity, and therefore, FDG accumulation is higher in malignant than normal cells. Since the FDG is being held in the cancer sites owing to its metabolic capture, that leaves sufficient time for imaging (8). Thus, PET/CT with flurodeoxyglucose represents a hybrid imaging modality – functional and morphological, with the functional imaging part (PET) obtaining information concerning glucose metabolic activity in all cancer sites, and the morphological CT part mostly being used for topographic localization and attenuation correction. Another important advantage of PET/CT over conventional imaging (CT and MRI) is its standard whole-body scan procedure, i.e. from the base of the skull to mid-tights, thus being able to assess potential distant metastatic sites together with local and regional disease. Still, there is no sufficient information regarding the use of FDG PET/CT in gynaecological tumours, and further research is necessary for establishing its role, particularly in cervical carcinoma (9).

## Diagnostic performances of PET/CT

According to various research, FDG PET/CT has proven useful in the follow-up of cervical cancer patients

and detection of recurrence, showing high sensitivity, specificity and diagnostic accuracy (10-14). Meads et al. (10) conducted a systematic review and meta-analysis where they included 9 papers on FDG PET/CT in patients with symptoms of cervical cancer recurrence. Calculated sensitivity and specificity in detecting recurrent disease were 94.8% and 86.9%, respectively (ranges 83 - 100% for sensitivity and 50 - 100% for specificity). That was in agreement with the results of a meta-analysis from Chu et al. (11), where they evaluated 8 papers and got 94% sensitivity and 84% specificity for FDG PET/CT in detection of cervical carcinoma relapse. They also performed two separate analyses, first for distant recurrence detection only, with 90% sensitivity (80 - 96%) and 99% specificity (98 - 100%), and the other for visualization of loco-regional relapse, with pooled sensitivity and specificity being 83% (69 - 93%) and 96% (89 - 99%), respectively (11). In a systematic review and meta-analysis by Ding et al. (12) that also evaluated 8 PET/CT studies in suspected cervical cancer recurrence, pooled sensitivity and specificity of PET/CT were 94% (95% confidence interval 89 - 97%), and 84% (95% confidence interval 74 - 91%), respectively, endorsing the results of Chu et al. and Meads et al. The area under the ROC curve (AUC) of PET/CT in their research was 0.9491. It is well known that diagnostic performances and results of any imaging test in oncology can correlate with tumor markers. Peng et al. (13) evaluated the diagnostic performance of PET/CT in 88 patients with suspected recurrent cervical cancer which they divided into two groups: group 1 which consisted of patients with elevated squamous-cell carcinoma antigen (SCC-Ag) and group 2 with normal SCC-Ag values. They found very high sensitivity in both groups (97.2% and 100%), and somewhat better specificity and accuracy in group 1 (92.9% vs 89.5% for specificity, and 96.8% vs 92.3% for accuracy), thus proving slightly better overall performance in settings with elevated SCC-Ag. All aforementioned studies covered patient-based analysis. On the other hand, Kitajima et al. (14) in their original research on 55 suspected recurrent cervical cancer patients did additional analysis for ten different lesion sites which included retrovesical area, pelvic lymph nodes, paraaortic lymph nodes, inguinal lymph nodes, mediastinal and hilar lymph nodes, supraclavicular lymph nodes, lungs, liver, skeleton and peritoneum. They obtained sensitivity, specificity, and accuracy of PET/CT based on the overall lesion-location basis of 89.5% (95% confidence interval 79.7 - 99.2%), 99.5% (95% confidence interval 98.9 - 100%), and 98.7% (95% confidence interval, 97.7 - 99.7%), respectively.

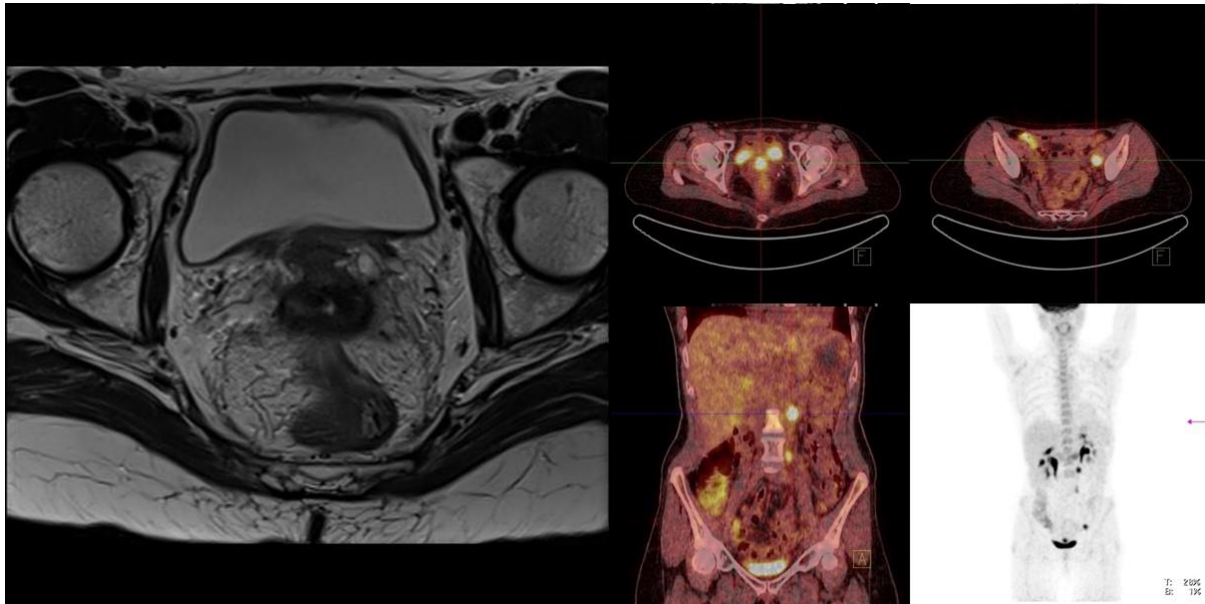
---

## PET/CT versus conventional imaging

---

Computed tomography, due to its availability and cost-efficiency has been widely used in women with cervical cancer. However, MRI should be given an advantage when available, particularly for evaluating local status, since it shows better soft tissue visualization. Magnetic resonance imaging has a crucial role in cervical

carcinoma patients, in all stages of patient management: initial diagnosis and staging, therapy planning, evaluation of response to therapy and restaging, and patient follow-up. Nevertheless, in women who were treated with irradiation, local relapse can frequently be misdiagnosed, since post-irradiation inflammation may have overlapping characteristics on MRI, and often there is a need for additional evaluation (15). The diagnostic accuracy of MRI for disease relapse in the pelvic area was assessed in a systematic review by Meads et al. (10), and the obtained values for sensitivity and specificity were 82% - 100% and 78 - 100%, respectively. The same authors reported diagnostic performances of FDG PET/CT in the range of 83 - 100% for sensitivity and 50 - 100% for specificity, as already mentioned, in both loco-regional and distant recurrent disease assessment, which seems comparable to MRI performances. However, diagnostic abilities were evaluated only for pelvic recurrence for MRI, while local disease and distant metastases as well were included in PET/CT performance evaluation, which can suggest a major PET/CT advantage. Original research by Bjurberg et al. (16) directly compared performances of PET scan, and traditional visualization modalities (CT and MRI) in 36 women with suspicion of cervical cancer relapse, where they obtained the highest values of sensitivity and specificity for PET/CT (100% each), with slightly worse sensitivity of conventional imaging - 92%, and moderately lower specificity of 78%. Pallardy et al. (17) also analyzed diagnostic performances of both hybrid (PET scan) and conventional imaging (CT/MRI) on 40 women who were treated for cervical carcinoma and were evaluated for recurrent disease. The PET/CT was shown to be superior to CT/MRI, with sensitivity values of 94% and 42.5%, respectively. A separate evaluation of only the abdominal and pelvic region on PET/CT versus conventional imaging has been performed, to exclude PET scan superiority due to the detection of disease sites out of examination areas on CT/MR. Sensitivity and accuracy values of PET scans remained the same, 93.3% and 91.8%, respectively, still showing enormous advantages over conventional imaging (17). Another prospective research confirmed inferiority of conventional imaging to PET/CT in detection of metastatic lesions in 40 suspected recurrent patients who were sent for restaging (sensitivities of 60% for CI and 92% for PET/CT) (18). Yen et al. (19) conducted another research where they analyzed restaging errors by both conventional imaging and PET/CT on 125 patients evaluated for cervical carcinoma recurrence. In this research, CT/MRI appointed lower disease stage to 38.4% of women, and higher stage to 17.6%, compared to the final diagnosis. More than 80% of the falsely down-staged females had lesions outside of the pelvis. On the other hand, PET/CT gave incorrect lower stage to approximately 15% of examinees, and higher stage to 16% of women. Main conclusion of their research is that PET shows a great advantage over CT and MRI in this population, due to its capability for detection of active disease sites outside of pelvis, and better overall diagnostic accuracy (**figure 1**).



**Figure 1.** Follow-up of a patient with FIGO IIB cervical cancer, 2 years after chemoradiation, on MRI (left) suspected recurrence in between cervix and bladder, PET/CT (right) confirms local recurrence in terms of high glucose metabolism in anterior cervix, but detects spread of disease in hypermetabolic iliac and paraaortic lymph nodes as well (from author's archive).

## Impact on treatment

It is shown that performing PET scan procedures in women with suspicion of recurrent cervical carcinoma can have a clinical impact leading to changes in therapy (16-17, 20-21). Pallardy et al. (17) reported modification of the treatment plan due to PET/CT findings in 55% of patients (22 out of 40). In the subgroup of 24 out of 40 patients that had normal conventional imaging results, these treatment changes due to PET were present in an even higher percentage (75%, that is 18 out of 24 women). In 15 out of 40 patients (37.5%), a completely different treatment option was applied subsequently, based on PET. In another original research by Bjurberg et al. (16) PET/CT findings caused utilization of different therapeutic procedures in one-third of women (12/36) and in 11/12 of those patients supportive care was chosen instead of curative treatment. In 8 out of 36 (22%) patients in their study, there were modifications in dosage or means of deliverance. Chung et al. (20) also reported alteration of management by PET/CT in almost one-fourth of patients (12/52), which consisted of modification of already planned therapeutic option (5/12), utilization of separate treatment modality (4/12), or elimination of additional diagnostics (3/12). Zhou et al. did a meta-analysis that included 6 studies, showing the pooled rate of overall therapeutic strategies modification caused by PET or PET/CT to be 57% (95% confidence interval 50 - 63%) (21).

## Prognostic role

The accumulation of FDG in cancers has an inverse correlation with their level of differentiation, and the greater the dedifferentiation of the tumor, the worse the prognosis (22-24). On the other hand, it must be noted that when it comes to evaluation of suspected recurrent patients on PET scan, metabolic activity of potential

relapse sites is always being taken into account for making the final diagnosis of recurrence. Accordingly, one should always bear in mind that some recurrent patients with low FDG uptake and only morphologically present lesions can be missed on PET/CT, however, those are the tumors that are prone to a better prognosis. Subsequently, this may explain the potential role of PET/CT in prognosis. In an original article by Bjurberg et al. (16) on 36 women with suspicion of cervical carcinoma recurrence, PET found no signs of disease in 25% of women (9/36), and their median overall (OS) and disease-free survival could not be calculated since there were no signs of recurrence during 60.9 months median follow-up (range 55 - 74 months). The remaining 75% of women (27/36), which had recurrent disease detected by FDG PET, had median OS of 30 months, with median follow-up time of 22.4 months (range 5 - 83 months). Chung et al. (25), showed significantly higher five-year progression-free survival and overall survival in women whose PET/CT results were normal compared to positive PET scan for relapse on 276 evaluated patients (PFS 98.62% and 17.83%, OS 99.31% and 85.38%, respectively). Pallardy et al. (17) conducted research on 40 patients with suspected recurrence and reported that the women with more than 3 active lesions on PET/CT had shorter OS (median 12 months, range 2 - 70) compared to subjects with no or only one active site on PET, whose median OS could not be obtained. They also performed multivariate analysis to determine potential factors of prognosis, which confirmed PET/CT (more than three FDG active sites) as the most significant factor in overall survival.

## Conclusion

The FDG PET/CT is an important diagnostic tool for suspected recurrent cervical carcinoma, showing higher sensitivity and specificity than conventional imaging such as CT and MRI, particularly in the evaluation of

distant recurrent sites. Additional benefit of PET/CT in these patients is its impact on treatment management in approximately half of the patients. The PET/CT also has a prognostic role in progression-free and overall survival, and patients with positive PET/CT for recurrence have significantly worse prognosis.

## Acknowledgements



Co-funded by the  
European Union

“Funded by the European Union. Views and opinions expressed are however those of the author(s) only and do not necessarily reflect those of the European Union or European Education and Culture Executive Agency (EACEA). Neither the European Union nor the granting authority can be held responsible for them.”

(EDUQUAN) ERASMUS-JMO-2021-HEI-TCH-RSCH

## Literature

1. Sung H, Ferlay J, Siegel RL, Laversanne M, Soerjomataram I, Jemal A, et al. Global Cancer Statistics 2020: GLOBOCAN Estimates of Incidence and Mortality Worldwide for 36 Cancers in 185 Countries. *CA Cancer J Clin*. 2021; 71(3):209-49.
2. Bhatla N, Aoki D, Sharma DN, Sankaranarayanan R. Cancer of the cervix uteri. *Int J Gynaecol Obstet*. 2018; 143(Suppl 2):22-36.
3. Miljuš D, Živković Perišić S, Božić Z, editors. Malignant tumours in Republic of Serbia: 2020. Serbian Cancer Registry. Belgrade: Institute of Public Health of Serbia “Dr Milan Jovanović Batut”; 2022.
4. de Foucher T, Bendifallah S, Ouldamer L, Bricou A, Lavoue V, Varinot J, et al. Patterns of recurrence and prognosis in locally advanced FIGO stage IB2 to IIB cervical cancer: Retrospective multicentre study from the FRANCOGYN group. *Eur J Surg Oncol*. 2019; 45(4):659-65.
5. Schieda N, Malone SC, Al Dandan O, Ramchandani P, Siegelman ES. Multi-modality organ-based approach to expected imaging findings, complications and recurrent tumour in the genitourinary tract after radiotherapy. *Insights Imaging*. 2014; 5(1):25-40.
6. Thomas GM, Dembo AJ, Myhr T, Black B, Pringle JF, Rawlings G. Long-term results of concurrent radiation and chemotherapy for carcinoma of the cervix recurrent after surgery. *Int J Gynecol Cancer*. 1993; 3(4):193-8.
7. Gandy N, Arshad MA, Park WE, Rockall AG, Barwick TD. FDG-PET Imaging in Cervical Cancer. *Semin Nucl Med*. 2019; 49(6):461-70.
8. Petrović J, Macut Đ, Šobić Šaranović D. Radionuclide imaging of neuroendocrine tumors. *MedPodml*. 2020; 71(3):36-42.
9. Palaniswamy SS, Borde CR, Subramanyam P. 18F-FDG PET/CT in the evaluation of cancer cervix: Where do we stand today? *Nucl Med Commun*. 2018; 39(7):583-92.
10. Meads C, Davenport C, Małysiak S, Kowalska M, Zapalska A, Guest P, et al. Evaluating PET-CT in the detection and management of recurrent cervical cancer: systematic reviews of diagnostic accuracy and subjective elicitation. *BJOG*. 2014; 121(4):398-407.
11. Chu Y, Zheng A, Wang F, Lin W, Yang X, Han L, et al. Diagnostic value of 18F-FDG-PET or PET-CT in recurrent cervical cancer: a systematic review and meta-analysis. *Nucl Med Commun*. 2014; 35(2):144-50.
12. Ding XP, Feng L, Ma L. Diagnosis of recurrent uterine cervical cancer: PET versus PET/CT: a systematic review and meta-analysis. *Arch Gynecol Obstet*. 2014; 290(4):741-7.
13. Peng NJ, Hu C, Chiu YL, Yu CC, Li CJ, Sheu JJ, et al. Detection of Recurrent Cervical Cancer and Prediction of Its Patient Survival with Serum Squamous-Cell Carcinoma-Antigen and 2-[18F] Fluoro-2-Deoxy-d-Glucose-Positron Emission Tomography/Computed Tomography. *Diagnostics (Basel)*. 2020; 10(9):657.
14. Kitajima K, Murakami K, Yamasaki E, Domeki Y, Kaji Y, Sugimura K. Performance of FDG-PET/CT for diagnosis of recurrent uterine cervical cancer. *EurRadiol*. 2008; 18(10):2040-7.
15. Patel-Lippmann K, Robbins JB, Barroilhet L, Anderson B, Sadowski EA, Boyum J. MR Imaging of Cervical Cancer. *Magn Reson Imaging Clin N Am*. 2017; 25(3):635-49.
16. Bjurberg M, Brun E. Clinical impact of 2-deoxy-2-[18F]fluoro-D-glucose (FDG)-positron emission tomography (PET) on treatment choice in recurrent cancer of the cervix uteri. *Int J Gynecol Cancer*. 2013; 23(9):1642-6.
17. Pallardy A, Bodet-Milin C, Oudoux A, Campion L, Bourbouloux E, Sagan C, et al. Clinical and survival impact of FDG PET in patients with suspicion of recurrent cervical carcinoma. *Eur J Nucl Med Mol Imaging*. 2010; 37(7):1270-8.
18. Lai CH, Huang KG, See LC, Yen TC, Tsai CS, Chang TC, et al. Restaging of recurrent cervical carcinoma with dual-phase [18F]fluoro-2-deoxy-D-glucose positron emission tomography. *Cancer*. 2004; 100(3):544-52.
19. Yen TC, Lai CH, Ma SY, Huang KG, Huang HJ, Hong JH, et al. Comparative benefits and limitations of 18F-FDG PET and CT-MRI in documented or suspected recurrent cervical cancer. *Eur J Nucl Med Mol Imaging*. 2006; 33(12):1399-407.
20. Chung HH, Jo H, Kang WJ, Kim JW, Park NH, Song YS, et al. Clinical impact of integrated PET/CT on the management of suspected cervical cancer recurrence. *Gynecol Oncol*. 2007; 104(3):529-34.
21. Zhou Z, Liu X, Hu K, Zhang F. The clinical value of PET and PET/CT in the diagnosis and management of suspected cervical cancer recurrence. *Nucl Med Commun*. 2018; 39(2):97-102.
22. Barbaro B, Leccisotti L, Vecchio FM, Di Matteo M, Serra T, Salsano M, et al. The potential predictive value of MRI and PET-CT in mucinous and nonmucinous rectal cancer to identify patients at high risk of metastatic disease. *Br J Radiol*. 2017; 90(1069):20150836.
23. Demura Y, Tsuchida T, Ishizaki T, Mizuno S, Totani Y, Ameshima S, et al. 18F-FDG accumulation with PET for differentiation between benign and malignant lesions in the thorax. *J Nucl Med*. 2003; 44(4):540-8.
24. Izuishi K, Yamamoto Y, Mori H, Kameyama R, Fujihara S, Masaki T, et al. Molecular mechanisms of [18F]fluorodeoxyglucose accumulation in liver cancer. *Oncol Rep*. 2014; 31(2):701-6.
25. Chung HH, Kim JW, Kang KW, Park NH, Song YS, Chung JK, et al. Predictive role of post-treatment [18F]FDG PET/CT in patients with uterine cervical cancer. *Eur J Radiol*. 2012; 81(8):e817-e22.