

CASE REPORT / ПРИКАЗ БОЛЕСНИКА

Dorzolamide in management of cystoid macular edema in a patient with retinitis pigmentosa sine pigmento

Jelena Karadžić^{1,2}, Igor Kovačević^{1,2}, Aleksandra Radosavljević^{1,2}, Ivan Stefanović^{1,2}

¹Clinical Centre of Serbia, Clinic for Eye Diseases, Belgrade, Serbia;

²University of Belgrade, School of Medicine, Belgrade, Serbia



SUMMARY

Introduction Retinitis pigmentosa (RP) is a group of inherited retinal dystrophies caused by mutations in various genes. The disease leads to progressive photoreceptors loss (rods predominantly) and retinal pigment epithelium alteration. RP can lead to blindness in the advanced stages of the disease, when the central retina is involved, mostly due to the presence of cystoid macular edema (CME). Several therapeutic approaches for CME in RP patients have been attempted but responses have been variable.

Case outline A 51-year-old man was referred due to progressive six-month-long blurring of vision in both eyes. The patient underwent complete ophthalmological examination at baseline. Based on the clinical presentation of mottled mid periphery of the retina and characteristic tubular visual field loss, hence typical fluorescein angiography and optical coherence tomography (OCT) findings, the patient was diagnosed as bilateral retinitis pigmentosa sine pigmento with CME. In an attempt to control the edema, treatment was started with dorzolamide, instilled three times daily in each eye, which resulted in reduction of macular edema in a one-month-period, as documented by OCT. This effect was further monitored for five months and was stable.

Conclusion In the presented case, we investigate the six-month therapeutic efficacy of dorzolamide for dealing with the CME secondary to RP. Topical carbonic anhydrase inhibitors are considered as the first option for treatment of CME in RP patients, due to their high efficacy and safety.

Keywords: retinitis pigmentosa sine pigmento; cystoid macular edema; topical carbonic anhydrase inhibitors; dorzolamide

INTRODUCTION

Retinitis pigmentosa (RP) is a group of inherited retinal dystrophies caused by mutations in various genes [1]. This disease leads to gradual and progressive loss of photoreceptors (predominantly rods) and alteration of retinal pigment epithelium [2]. RP can occur in sporadic form without any familial history, or it can be inherited as a dominant and recessive autosomal or X-linked disease [3]. The symptomatology consists of night blindness and gradual loss of visual fields [4]. This condition can lead to blindness in the advanced stages of the disease, when the central retina is involved, mostly because of the presence of cystoid macular edema (CME) [5]. The exact CME etiology is not well understood, but it is proposed that the retinal pigment epithelium pump dysfunction and/or compromise of the blood-retinal barrier bring the fluid to accumulate in cystoid spaces within the retina [6, 7]. Cystoid macular edema may cause blurred vision or reduced visual acuity and finally atrophic foveal changes with permanent loss of visual function. Thus, it is necessary to find an optimal and effective treatment for it [7]. Several therapeutic protocols have been considered, such as systemic or topical carbonic anhydrase inhibitors (CAI) (acetazolamide and

dorzolamide, respectively), systemic or intravitreal corticosteroids (triamcinolone, dexamethasone), laser photocoagulation and pars plana vitrectomy but responses have been variable [6, 8–12].

We have the opportunity to report a case of cystoid macular edema in a patient with RP sine pigmento treated with topical CAI (dorzolamide). The therapeutic response was monitored by visual acuity assessment, central visual field program (10-2 program) on Humphrey field analyzer, and by measuring central macular thickness on optical coherence tomography (OCT).

CASE REPORT

A 51-year-old man was referred to our clinic due to six-month long progressive blurring of vision in both eyes. He had a history of hypertension, with no family history of diabetes, glaucoma and RP. He reported he was an ex-smoker. The patient underwent complete ophthalmological examination at baseline including visual acuity assessment (measured by Snellen chart), applanation tonometry, and slit lamp examination, indirect ophthalmoscopy with 90D lens and immunological and biochemical investigation.

Примљено • Received:

April 21, 2015

Ревизија • Revised:

November 15, 2016

Прихваћено • Accepted:

November 17, 2016

Online first: March 3, 2017

Correspondence to:

Jelena KARADŽIĆ
Clinical Centre of Serbia,
Clinic for Eye Diseases,
Pasterova 2, Belgrade, Serbia
bjjelena@gmail.com

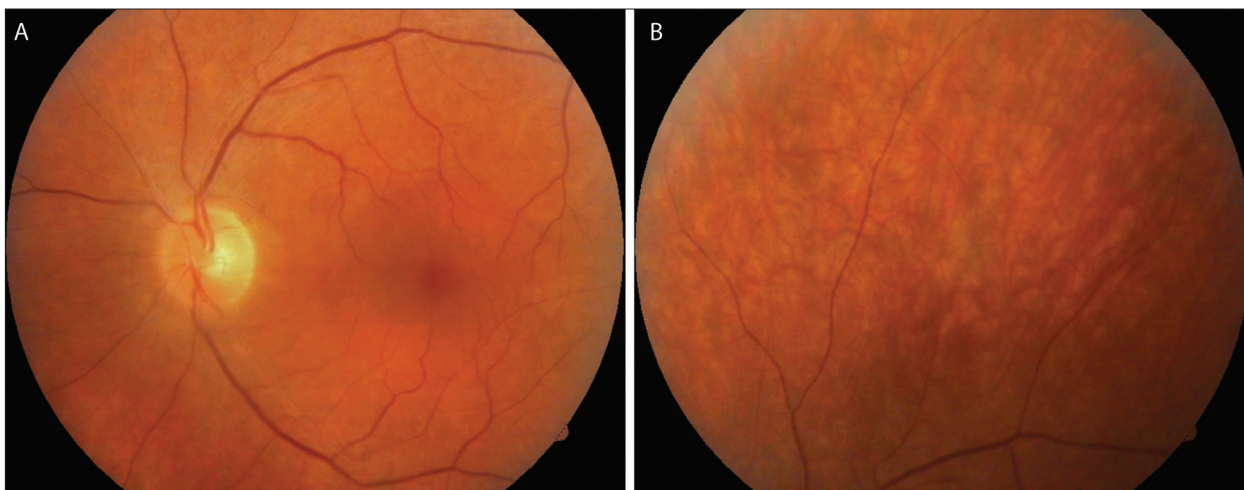


Figure 1. Fundus photo of the left eye (A: posterior pole; B: mid-periphery) with visible arteriolar narrowing and sheathing; note that there are no typical pigmentary clumps nor significant pallor of the optic nerve head

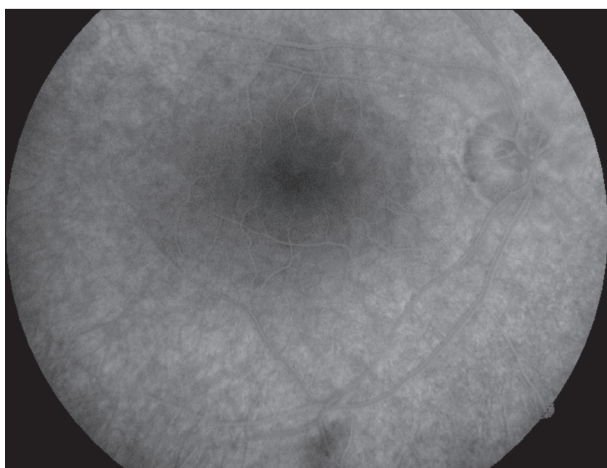


Figure 2. Fluorescein angiography of the right eye after the injection of the dye (posterior pole); note the unusual degree of choroidal hyperfluorescence surrounding darker macular area, indicating abnormality of retinal pigment epithelial layer




Figure 3. Abnormal fluorescein angiography of the right eye (mid-periphery); note diffuse mottled hyperfluorescence observed during the most of the period of the dye transit through the retina vessels which correspond to the retinal pigment epithelial changes

Upon examination, best corrected visual acuity (BCVA) was 0.9 in the right eye and 0.7 in the left eye. He had normal color vision and no relative afferent pupillary defect. Fundoscopy of both eyes revealed very discrete mid- and far-peripheral mottled retina, arteriolar narrowing, and sheathing. There were no typical pigmentary changes or clumps, nor significant pallor of the optic nerve heads (Figure 1). The intraocular pressure by applanation tonometry was within the normal range (10 mmHg). All investigations at presentation which included complete blood count, erythrocyte sedimentation rate, C-reactive protein, prothrombin and partial thromboplastin time, blood sugar level, renal and liver function tests, rheumatoid factor, and autoantibody profile were within normal range. The visual field tests, fluorescein angiography (FA), OCT, and dark adaptation testing were performed. Fluorescein angiography showed an unusual degree of choroidal hyperfluorescence which surrounded darker central macular zone (Figure 2), and diffuse mid and far periphery mottled hyperfluorescence extended to the equatorial region (Figure 3). Fluorescein angiography did not show any macular edema.

Thinned/disappeared retinal layers including the photoreceptor layer/junction between inner and outer segment of photoreceptors were shown by OCT in the parafoveal region. OCT also detected the subclinical CME (Figure 5a). Automated white-on-white threshold perimetry showed constricted peripheral visual field in both eyes (Figure 4). Dark adaptation testing showed prolonged rod dark adaptation in both eyes. We also performed magnetic resonance imaging of the brain with contrast which was unremarkable. Based on the clinical presentation of discrete mottled mid periphery of the retina and characteristic tubar visual field loss, hence typical FA and OCT findings, the patient was diagnosed with bilateral retinitis pigmentosa sine pigmento and cystoid macular edema. The patient was consulted about therapeutic options for CME. In an attempt to decrease the edema, treatment was started with instillation of dorzolamide three times daily in each eye. As a result of a one-month treatment, the reduction of macular edema was documented by OCT (Figure 5b), while BCVA improved to 1.0 in the right eye and 0.9 in the left eye. The patient was also seen five months later, and the improvement was

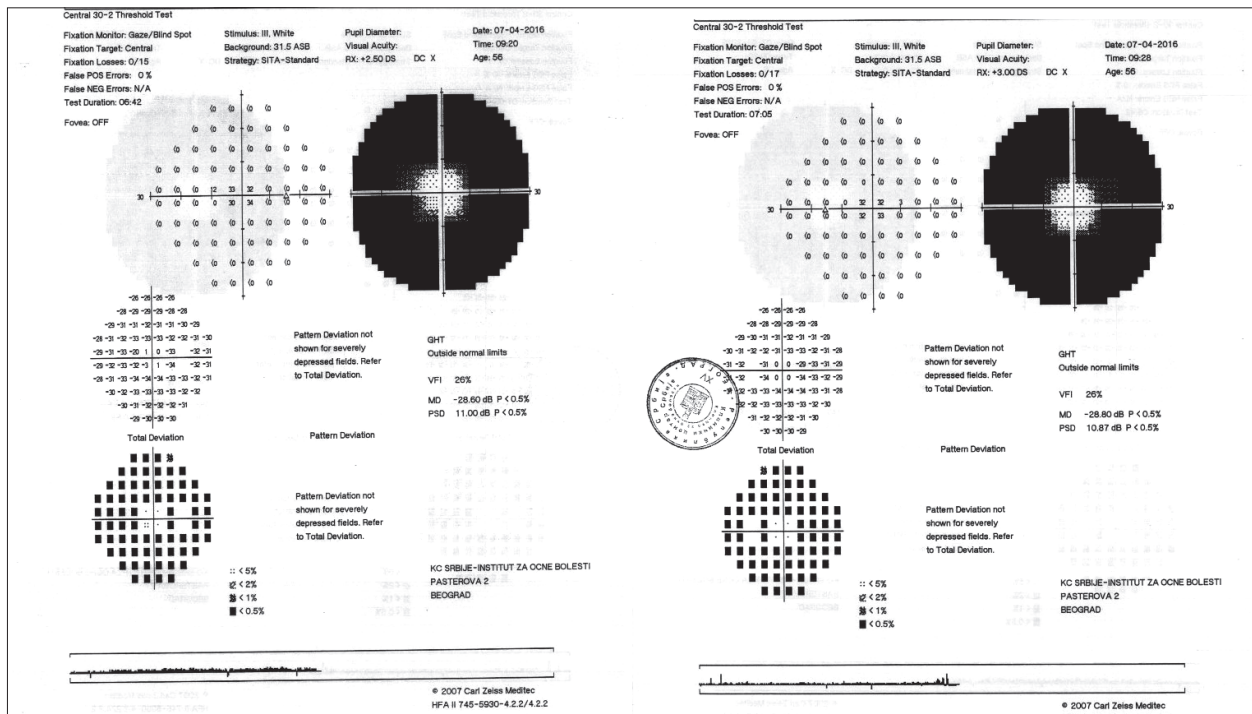


Figure 4. Automated white-on-white threshold perimetry showing constricted peripheral visual field in both eyes

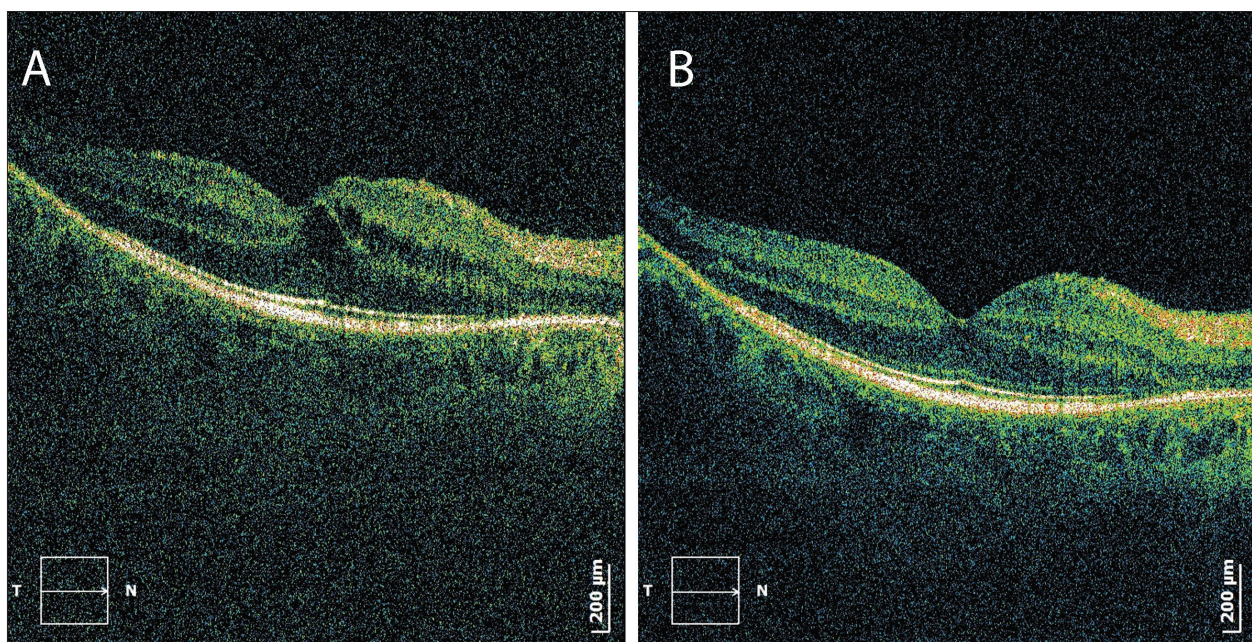


Figure 5. A: pretreatment optical coherence tomography (OCT) of the right eye, showing cystoid macular edema (CME); B: OCT of the same eye one month after the treatment, showing resolved CME

maintained with BCVA unchanged (1.0 for the right eye, 0.9 for the left one). The patient did not receive any other kind of therapy for his condition.

DISCUSSION

In the current paper, we showed the therapeutic effects of a topical CAI for the management of CME in patients with RP over a six-month period. Retinitis pigmentosa is retinal dystrophy characterized by night blindness, con-

stricted visual fields, pigmented clumps of the retina, and photoreceptor cell dysfunction and loss [13]. The long-term prognosis is unfavorable, as there is a final loss in central vision because of direct involvement of the macula from the photoreceptors loss and/or maculopathy [14]. The diagnosis of retinitis pigmentosa sine pigmento purely from retinal findings is more challenging than in the typical cases. The retinal pigment epithelial defects could be very subtle and discrete and therefore could easily be overlooked. The vascular attenuation is also not always obvious, and sometimes retinal vascular occlusion could

be considered and initially suspected. On the other hand, optic disc pallor may be discreet, partial, or even absent, as in our case [15]. Although the subjective symptomatology is typical for RP, such as night blindness and reduced visual field in its early stages, it could be completely obscured as it affects only the peripheral fundus [16]. Without this typical clinical finding, advances in imaging and testing could help in setting the diagnosis of RP sine pigmento, such as visual field and dark adaptation testing, FA, OCT, and conventional or full-field electroretinography.

CME is an uncommon complication of RP, occurring in 10–20% of patients [9]. Currently, there are no uniform guidelines how to treat this condition. The responses to the treatment seem to be individually variable. There are several therapeutic approaches for CME in RP, such as systemic or intravitreal corticosteroids, grid laser photocoagulation, systemic or topical carbonic anhydrase inhibitors [9], and in the recent years some authors found the inhibitors of the vascular endothelial growth factor (VEGF) to be effective [17]. In any case, many practitioners believe that carbonic anhydrase inhibitors are the mainstay of treatment [9]. These drugs stimulate the pumping mechanism of the retinal pigment epithelium [18]. Unfortunately, severe side effects could appear with oral administration of CAI (drowsiness, confusion, allergic reactions, paresthesias, myelosuppression, renal calculi, loss of potassium, or, with extended use, hyperchloremic metabolic acidosis). That is the reason why this treatment is not advised for any prolonged period of time. On the other hand, topical CAI is free from the adverse effects that are related to systemic administration and thus appropriate for prolonged use [19].

Ikeda et al. [7] found the dorzolamide to be an effective and safe treatment option for CME in RP patients, and consider it as the first treatment choice for CME. If the therapeutic efficacy is not sufficient, i.e. when CME does not completely resolve within six months, additional or change of the treatment could be required. They also believed that other therapeutic approaches such as intravitreal injections of corticosteroids, inhibitors of VEGF or vitrectomy are not standard therapy because of their potentially severe complications and because of the fact that safer and still effective alternative exists in the form of topical CAI [7].

REFERENCES

- Cotran PR, Bruns GA, Berson EL, Dryja TP. Genetic analysis of patients with retinitis pigmentosa using a cloned cDNA probe for the human gamma subunit of cyclic GMP phosphodiesterase. *Exp Eye Res.* 1991; 53(5):557–64.
- Jacobson JH, Stephens G. Unilateral retinitis pigmentosa sine pigmento. *Arch Ophthalmol.* 1962; 67:456–58.
- Kellner U, Renner AB, Tillack H. Hereditary retinohoroidal dystrophies. Part 2: differential diagnosis. *Ophthalmologie.* 2004; 101(4):397–412.
- Grover S, Fishman GA, Anderson RJ, Alexander KR, Derlacki DJ. Rate of visual field loss in retinitis pigmentosa. *Ophthalmology.* 1997; 104(3):460–5.
- Nguyen HV, Sujirakul T, Kulkarni N, Tsang SH. Understanding Retinitis Pigmentosa. *Retinal Physician.* 2013; (10):34–42. Available online: <http://www.retinalphysician.com/articleviewer.aspx?articleID=109105>
- Baumgartner WA. Etiology, pathogenesis, and experimental treatment of retinitis pigmentosa. *Med Hypotheses.* 2000; 54(5):814–24.
- Ikeda Y, Yoshida N, Notomi S, Murakami Y, Hisatomi T, Enaida H, et al. Therapeutic effect of prolonged treatment with topical dorzolamide for cystoid macular oedema in patients with retinitis pigmentosa. *Br J Ophthalmol.* 2013; 97(9):1187–91.
- Cox SN, Hay E, Bird AC. Treatment of chronic macular edema with acetazolamide. *Arch Ophthalmol.* 1988; 106(9):1190–5.
- Ozdemir H, Karacorlu M, Karacorlu S. Intravitreal triamcinolone acetonide for treatment of cystoid macular oedema in patients with retinitis pigmentosa. *Acta Ophthalmol Scand.* 2005; 83(2):248–51.
- Grover S, Apushkin MA, Fishman GA. Topical dorzolamide for the treatment of cystoid macular edema in patients with retinitis pigmentosa. *Am J Ophthalmol.* 2006; 141(5):850–8.

Pacella et al. [19] believed that although topical CAI are less potent than systemic ones, because of their lacking in systemic adverse effects it could be a reasonable option for the treatment of this condition, particularly if it is necessary to be used continuously. The reduction of CME commonly results in visual acuity improvement [20]. However, Chung et al. [18] found that, occasionally, improvement in visual acuity did not match the degree of edema resolution shown by OCT. This limitation of treatment could be explained by irreparable functional impairment within the fovea, arising from either chronic macular edema or photoreceptor cell dysfunction. Moustafa and Moschos [17] reported only 10% improvement in BCVA after the treatment, despite the significant resolution of macular edema in OCT scan. They deem that reasonable explanation is that CME is only one factor that affects the vision, while atrophy of the retina (particularly of the photoreceptors) also has impact on the visual function. Although our patient had anatomical and functional improvement after the treatment with topical CAI, the attention must be paid to the pre-intervention anatomical changes of the retina (photoreceptors and retinal pigment epithelium band shown on OCT), which have prognostic significance for the efficacy of the treatment. Thus, timely diagnosis and prompt treatment of CME in patients with RP are necessary before permanent photoreceptor loss occurs [16].

In the presented case we investigate the six-month therapeutic efficacy of dorzolamide for management of the cystoid macular edema secondary to RP. Our patient showed an anatomical and functional improvement after topical CAI. There are various therapeutic options for this condition, but because of their safety and efficacy, topical CAI are considered as the first treatment choice by many authors. Treatment of CME should be rapid and effective before structural changes of photoreceptors occur.

NOTE

The paper was presented at the 16th EURETINA Congress – Copenhagen 2016 and published electronically with identical title in the form of an abstract.

11. Saatci AO, Selver OB, Seymenoglu G, Yaman A. Bilateral intravitreal dexamethasone implant for retinitis pigmentosa-related macular edema. *Case Rep Ophthalmol*. 2013; 4(1):53–8.
12. Newsome DA, Blacharski PA. Grid photocoagulation for macular edema in patients with retinitis pigmentosa. *Am J Ophthalmol*. 1987; 103(2):161–6.
13. Garcia-Arumi J, Martinez V, Sararols L, Corcostegui B. Vitreoretinal surgery for cystoid macular edema associated with retinitis pigmentosa. *Ophthalmology*. 2003; 110(6):1164–9.
14. Chang S, Vaccarella L, Olatunji S, Cebulla C, Christoforidis J. Diagnostic Challenges in Retinitis Pigmentosa: Genotypic Multiplicity and Phenotypic Variability. *Curr Genomics*. 2011; 12(4):267–75.
15. Schmidt JG, Zinser J. Long-term follow-up of deterioration of the visual field in visual acuity in retinitis pigmentosa. *Fortschr Ophthalmol*. 1989; 86(6):614–8.
16. Pearlman JT, Saxton J, Hoffman G. Unilateral retinitis pigmentosa sine pigmento. *Br J Ophthalmol*. 1976; 60(5):354–60.
17. Moustafa GA, Moschos MM. Intravitreal aflibercept (Eylea) injection for cystoid macular edema secondary to retinitis pigmentosa – a first case report and short review of the literature. *BMC Ophthalmol*. 2015; 15:44.
18. Chung H, Hwang JU, Kim JG, Yoon YH. Optical coherence tomography in the diagnosis and monitoring of cystoid macular edema in patients with retinitis pigmentosa. *Retina*. 2006; 26(8):922–7.
19. Pacella E, Arrico L, Santamaria V, Turchetti P, Carbotti MR, La Torre G, et al. Dorzolamide chlorhydrate versus acetazolamide in the management of chronic macular edema in patients with retinitis pigmentosa: description of three case reports. *Ophthalmol Eye Dis*. 2014; 6:21–6.
20. Pacella E, Vestri AR, Muscella R, Carbotti MR, Castellucci M, Coi L, et al. Preliminary results of an intravitreal dexamethasone implant (Ozurdex®) in patients with persistent diabetic macular edema. *Clin Ophthalmol*. 2013; 7:1423–8.

Дорзоламид у лечењу цистоидног едема макуле код болесника са *Retinopathia pigmentosa sine pigmento*

Јелена Караџић^{1,2}, Игор Ковачевић^{1,2}, Александра Радосављевић^{1,2}, Иван Стефановић^{1,2}

¹Клинички центар Србије, Клиника за очне болести, Београд, Србија;

²Универзитет у Београду, Медицински факултет, Београд, Србија

САЖЕТАК

Увод Пигментна ретинопатија (ПР) јесте група дистрофија ретине проузрокованих мутацијама различитих гена. Она доводи до прогресивног губитка фоторецептора (посебно штапића) и промена у ретиналном пигментном епителу. ПР може да доведе до слепила у узнапредовалим случајевима болести, када је захваћен централни део ретине, најчешће присуством цистоидног макуларног едема (ЦМЕ). Постоји неколико опција у лечењу ЦМЕ код болесника са ПР, иако су одговори на лечење различити.

Приказ болесника Мушкарац стар 51 годину је прегледан због прогресивног замаглења вида на оба ока уназад шест месеци. Болесник је комплетно офталмолошки прегледан. На основу клиничког налаза ишаране средње периферије ретине и карактеристичног тубарног налаза видног поља, потом карактеристичних налаза флуоресцеинске ангио-

графије и оптичке кохерентне томографије, постављена је дијагноза билатералне *Retinopathia pigmentosa sine pigmento* са цистоидним едемом макуле. Започет је третман дорзоламидом у оба ока три пута на дан, у жељи да се контролише едем макуле. После месец дана примене дошло је до смањења едема макуле, што је доказано и оптичком кохерентном томографијом. Овај налаз је потом праћен још пет месеци и није било знакова рецидива.

Закључак У приказаном случају смо пратили шестомесечни ефекат дорзоламида у лечењу цистоидног едема макуле код ПР. Локални инхибитори угљене анхидразе сматрају се третманом првог избора за ЦМЕ код ПР због високе ефикасности и безбедности.

Кључне речи: *Retinopathia pigmentosa sine pigmento*; цистоидни едем макуле; локални инхибитор угљене анхидразе; дорзоламид