

## CASE REPORT / ПРИКАЗ БОЛЕСНИКА

# Myoepithelioma originating from the floor of the mouth

Vinícius Rio Verde Melo Muniz, Pauline Magalhães Cardoso, Rafael Fernandes de Almeida Neri, Leonardo de Araújo Melo, Bráulio Carneiro Júnior, Jean Nunes dos Santos

Federal University of Bahia, School of Dentistry, Salvador, Bahia, Brazil

**SUMMARY**

**Introduction** Myoepithelioma primarily affects the parotid gland and usually presents as a slow-growing painless lump.

The aim of this paper is to report a case of myoepithelioma in the mouth floor.

**Case outline** A young man noticed a painless increased volume in the left side of the mouth floor region, which after one year of evolution presented as a sessile tumor with normal colored mucosa and the absence of secretion output. Computed tomography with contrast showed an image with slightly heterogeneous density, with well-defined limits. Incisional biopsy was performed under local anesthesia, and pathology examination of the sample revealed a myoepithelial neoplasm. Total excision of the lesion was performed under general anesthesia, and histopathological examination confirmed the diagnosis of the salivary gland myoepithelioma. The patient did not present signs of relapse after a year of follow up.

**Conclusion** Despite the fact that myoepithelioma originating in the salivary gland are considered rare, especially in the mouth floor, this tumor should be considered in the differential diagnosis of similar lesions. Proper treatment appears to be complete surgical excision and post-operative follow-ups shows should be carried out as long as possible, despite the fact that relapses are extremely rare.

**Keywords:** salivary gland; oral pathology; myoepithelioma

**INTRODUCTION**

Myoepithelioma was first described in 1943 [1]. However, it was only in 1991 that it was considered by the World Health Organization as a distinct pathological entity. Also known as myoepithelial adenoma, this tumor is composed entirely of myoepithelial cells, without duct formation in its interior and makes up about 1–1.5% of all salivary gland tumors [2, 3–14]. It affects both minor and major salivary glands, but is more commonly found in the parotid (about 50%), sublingual (33%), and submandibular glands (13%) [13, 15]. Patients between the fourth and sixth decades of life are the most often affected [4, 7, 11, 15], and there is no predilection for gender [11, 14]. It usually present as a painless nodule with slow growth [13, 14, 15].

Myoepithelial cells are part of the normal composition of the salivary glands and are important components of many types of salivary gland tumors such as pleomorphic adenoma, adenoid cystic carcinoma, and terminal duct carcinoma [16, 17]. These cells are located between the basal lamina and the acinar and ductal cells. They have structural characteristics similar to epithelial and smooth muscle cells [3, 18].

Myoepithelioma is rarely found, with more than 200 cases reported [18]. Thus, this paper aims to report what we believe to be the second case of myoepithelioma in the mouth floor described in the English language literature in the

past 20 years, highlighting its clinical and pathologic characteristics and appropriate treatment.

**CASE REPORT**

A 28-year-old black male attended the Oral and Maxillofacial Surgery and Traumatology Clinic at the Baiano's Center for Dental Studies, Salvador, Brazil, complaining of a painless swelling in the left mouth floor region which lasted for one year. Regarding its previous medical history, there was nothing to consider. At physical examination, a swelling, firm to palpation and lined by normal mucosa, could be noticed. It was located in the floor of the mouth, in the left anterior region (Figure 1A).

Computed tomography imaging with contrast showed a hyperdense lesion in a region close to the left base of the tongue, with contours well-defined and of slightly heterogeneous density, measuring about  $4 \times 2.5 \times 1.5$  cm in its greatest diameter (Figure 1B). At the ultrasound examination it was possible to observe epithelial, subcutaneous, and muscle tissues within normal limits, and the presence of fluid collection within the lesion was not detected.

An incisional biopsy under local anesthesia was performed and histopathological examination revealed a well-circumscribed neoplasm characterized by the presence of plasmacytoid myoepithelial, epithelioid, and eventually cuboid cells in a fibrous or hyaline matrix (Figure 1E).

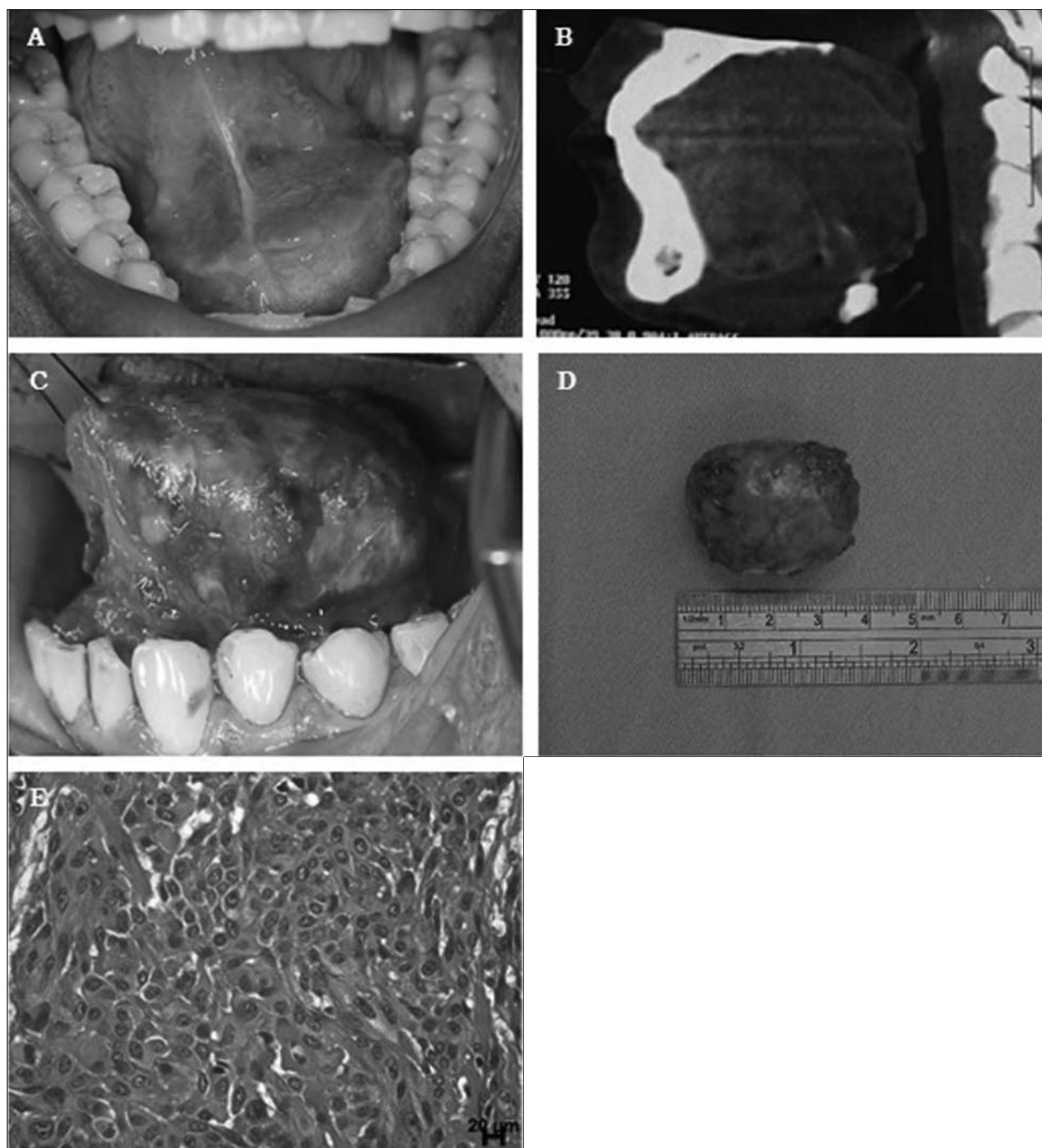
**Примљено • Received:**  
October 10, 2016

**Прихваћено • Accepted:**  
May 24, 2017

**Online first:** May 30, 2017

**Correspondence to:**

Vinícius Muniz  
Rodrigues Dorea 237, Apt 1004,  
Armação  
Salvador, Bahia, Brazil  
[viniciusctbmf@gmail.com](mailto:viniciusctbmf@gmail.com)



**Figure 1.** A) Clinical image showing a swelling located in the floor of the mouth; B) tomographic image (sagittal multiplanar reconstruction) presenting a well located lesion; C) nodular and well-delimited lesion within the floor of the mouth; D) nodular lesion measuring 4 × 2.5 × 1.5 cm; E) a solid area showing proliferation of plasmacytoid, epithelioid, and, eventually, spindle-shaped cells

The patient thereafter underwent excisional biopsy under general anesthesia through intraoral access in the left anterior floor of the mouth region. During the surgery we could notice that the lesion had well-defined boundaries, easy identification and cleavage, with rubber consistency and predominantly yellowish color with purplish spots (Figure 1 C and D).

The surgical specimen was stored in 10% formaldehyde and sent for histopathological examination, and a diagnosis of myoepithelioma was established. The patient's recovery was uneventful and after two years of follow-up he showed no signs of recurrence.

## DISCUSSION

The occurrence of myoepithelioma in the head and neck area is rare, while the involvement of the oral cavity is extremely rare, representing about 1–1.5% of all salivary gland tumors [5, 18, 19, 20]. According to Table 1, only one article was published about myoepithelioma located in the floor of the mouth, and maxilla was the most frequent site. There was no predilection for gender. In regard to the age group predilection, the most affected were persons in the third and fifth decades of life.

**Table 1.** Summarization of clinical cases of face myoepitheliomas reported in the last 20 years

Autors	Year	Age	Sex	Color	Site	Treatment	Follow-up	Recurrence
Kanazawa et al. [3]	1999	42	Female	Yellow	Hard palate	Local excision	2 years	No
Piatelli et al. [4]	1999	47	-	-	Jugal mucosa	Excisional biopsy	3 years	No
Carinci et al. [5]	2001	30	Male	-	Tongue base	Local resection + chemotherapy	4 years and 4 months	No
Isogai et al. [6]	2003	47	Female	Yellow	Buccal mucosa	-	6 months	No
Nair et al. [14]	2004	58	Male	Brown	Hard palate	Local excision	6 months	No
Onbas et al. [7]	2005	65	Female	-	Hemiface	-	-	-
Woo et al. [22]	2005	22	Female	-	Dorsal tongue	Excisional biopsy	1 year and 2 months	No
Cuesta Gil et al. [20]	2008	54	Female	White	Maxilla	Hemimaxillectomy	3 years	No
Patrocino et al. [8]	2009	38	Male	-	Maxilla	Local resection	9 years	No
Nikitakis et al. [19]	2010	45	Male	White	Dorsal tongue	Excisional biopsy	2 years	No
Hunt et al. [18]	2011	21	Male	White	Mouth floor	Excision of the	-	-
Park and Seo [9]	2011	23	Male	Yellow	Buccal mucosa	Submandibular gland local excision	2 years	No
Rishabh et al. [10]	2011	22	Male	Brown	Orbit	Local excision	5 months	No
Sperandio et al. [2]	2011	42	Female	Black	Soft palate	Local excision	1 year	No
Badal et al. [11]	2013	55	Male	-	Maxilla	Hemimaxillectomy	-	-
Gore et al. [12]	2013	70	Female	-	Maxilla	-	-	-
Gore et al. [12]	2013	62	Female	-	Maxilla	-	-	-
Gore et al. [12]	2013	30	Female	-	Maxilla	-	-	-
Mochizuki et al. [13]	2013	40	Female	White	Parotid gland	Enucleation	1 year	No
Yadav et al. [17]	2013	40	Male	-	Soft palate	Local excision	6 months	No
Present case	2016	28	Male	Black	Mouth floor	Local excision	2 years	No

Clinically, myoepithelioma presents itself as a slow-growing, circumscribed, and painless swelling [4, 10, 12, 13, 18, 19, 21]. The presented case showed an evolution period of two years, without painful symptoms associated, and imaging examinations revealed a circumscribed lesion in the floor of the mouth in the left anterior region. Myoepithelioma shows no predilection for gender and affects a wide age range but some authors claim that the fifth decade of life is the most affected age group [13, 14, 18, 19, 20, 21].

Most myoepitheliomas of salivary glands occur in parotid glands (50%), sublingual (33%) and submandibular gland (13%) [2, 6, 13, 15]. Rarely, it affects locations such as the maxillary sinus, lacrimal gland, nasal cavity, larynx or dermis [6]. The origin of the tumor described in this study appears to be a minor salivary gland and its site is extremely rare, with only one case of the mouth floor myoepithelioma documented in the researched English language literature [20].

The reported case fulfills the criteria for myoepithelioma. Myoepithelial cells are similar to smooth muscle cells, probably of ectodermal origin, but they perform functions of mesodermal cells [22]. Usually, myoepithelioma presents multiple cellular patterns as fusiform, plasmacytoid, epithelioid, clear cell, mixed pattern, and abundant presence of mucoid acellular stroma [3, 4, 6, 9, 12, 18, 19, 20]. The plasmacytoid type tends to occur more often in the oral cavity, especially in the palate, when compared with other types of myoepithelioma, although the fusiform pattern is the most common and often primarily affects the parotid gland [3, 4, 18]. Patterns containing epithelioid cells and clear cells develop in the parotid glands and often suffer malignant transformation [6]. Histological pattern does not influence the biological behavior of the lesion [18].

Myoepithelioma is often confused with pleomorphic adenomas due to the large amount of myoepithelial cells present in these two tumors [3, 9, 19, 20]. Myoepitheliomas were once considered a variant of pleomorphic adenoma [13]. However, since 1991, the World Health Organization has clearly differentiated myoepithelioma from pleomorphic adenoma, showing that myoepithelioma presents epithelial cells, but it has no duct differentiation or presence of chondroid or myxochondroid matrix.

The differential diagnosis includes pleomorphic adenoma and other salivary gland tumors, including cancer. The first suspect in the presented case was pleomorphic adenoma, followed by plunging ranula. However, in the floor of the mouth, other tumors such as lipomas and neurofibromas can also be found.

Myoepitheliomas are less likely to recur than pleomorphic adenoma. However, they can undergo malignant transformation, especially when there are recurrent relapses or tumor existence for a long time without treatment [9]. The prognosis is based on histopathology, being favorable for the benign form, which does not eliminate the need for regular monitoring to detect local recurrence, though it is rare when the lesion is completely removed [9, 18, 20].

According to Table 1 and the current literature, the treatment usually consists of complete removal of the lesion, with no reports of recurrence after an average time of 25 months following surgery [2, 9, 12, 13, 18]. Recurrence rates of 10% and 18% are reported, probably due to incomplete removal of the lesion. The prognosis is favorable [12, 14]. In the present case, after two years of postoperative follow-up, there were no signs of recurrence. However, it is wise to carry out follow-ups as long as possible, despite the fact that relapses are extremely rare.

## REFERENCES

- Sheldon W. So-called mixed tumors of the salivary glands. *Arch Pathol.* 1943; 35:1–20.
- Sperandio FF, Giudice FS, Pinto-Junior DS, de Sousa SCOM. Myoepithelioma of the soft palate: a case report giving special attention to the differential diagnosis. *J Oral Maxillofac Res.* 2011; 2:4.
- Kanazawa H, Furuya T, Watanabe T, Kato J. Plasmacytoid myoepithelioma of the palate. *J Oral Maxillofac Surg.* 1999; 57:857–860.
- Piatelli A, Fioroni M, Rubini C. Myoepithelioma of the gingiva. Report of a case. *J Periodontol.* 1999; 70(6):683–7.
- Carinci F, Grasso DL, Grandi E, Pelucchi S, Pastore A. Malignant myoepithelioma of the tongue base: Case report and literature review. *J Craniofac Surg.* 2001; 12(6):544–6.
- Isogai R, Kawada A, Ueno K, Aragane Y, Tezuka T. Myoepithelioma possibly originating from the accessory parotid gland. *Dermatology.* 2004; 208(1):74–8.
- Onbas O, Karasen RM, Gursan N, Kantarci M, Alper F, Okur A. Giant myoepithelioma of the face: MDCT with 2D AND 3D images. *AJR Am J Roentgenol.* 2006; 187(4):W418–9.
- Patrocinio LG, Damasceno PG, Patrocinio JA. Malignant myoepithelioma of the hard palate: 9-year follow-up. *Braz J Otorhinolaryngol.* 2009; 75(4):620.
- Park TH, Seo SW. Diagnostic challenges of myoepithelioma arising from a minor salivary gland. *J Oral Maxillofac Surg.* 2011; 69(11):2830–2.
- Rishabh K, Ashwarya T, Sudhir R. A Rare Case of myoepithelioma around the left orbit. *J Dent Res Dent Clin Dent Prospects.* 2011; 5(4):141–3.
- Badal S, Ahmed S, Patil PS, Badal A. Malignant myoepithelioma of the maxilla posing a diagnostic dilemma. *Natl J Maxillofac Surg.* 2013; 4(2):235–8.
- Gore CR, Panicker N, Chandanwale S, Singh BK. Myoepithelioma of minor salivary glands – A diagnostic challenge: Report of three cases with varied histomorphology. *J Oral Maxillofac Pathol.* 2013; 17(2):257–60.
- Mochizuki Y, Omura K, Tanaka K, Sakamoto K, Yamaguchi A. Myoepithelioma of the parotid gland presenting as a retroauricular cutaneous nodule: A case report. *J Clin Diagn Res.* 2013; 7(6):1165–8.
- Nair BJ, Vivek V, Sivakumar TT, Joseph AP, Varun BR, Mony V. Clear cell myoepithelioma of palate with emphasis on clinical and histological differential diagnosis. *Clin Pract.* 2014; 4(1):628.
- Rosai J. *Ackerman's surgical pathology.* 8th ed. St. Louis: CV Mosby; 1996. p. 833.
- Takeda Y. Malignant myoepithelioma of minor salivary gland origin. *Acta Pathol Jpn.* 1992; 42(7):518–22.
- Yadav AK, Nadarajah J, Chandrashekhara SH, Tambade VD, Acharya S. Myoepithelioma of the soft palate: a case report. *Case Rep Otolaryngol.* 2013; 2013:642806.
- Hunt KT, Stevens MR, Abdelsayed RA, Nguyen CT. Benign myoepithelioma of floor of mouth with mandibular involvement: A case report and literature review. *J Oral Maxillofac Surg.* 2011; 69(12):3001–5.
- Nikitakis NG, Argyris P, Sklavounou A, Papadimitriou JC. Oral myoepithelioma of soft tissue origin: report of a new case and literature review. *Oral Surg Oral Med Oral Pathol Oral Radiol Endod.* 2010; 110(5):e48–51.
- Cuesta Gil M, Bucci T, Navarro Cuellar C, Duarte Ruiz B, Pannone G, Bufo P, et al. Intraosseous myoepithelioma of the maxilla: clinicopathologic features and therapeutic considerations. *J Oral Maxillofac Surg.* 2008; 66(4):800–3.
- Peel RL, Gnepp DR. *Diseases of the salivary glands.* In Barnes L. *Surgical Pathology of the head and neck*, 2th ed. vol. 1. New York: Marcel Dekker; 1985. p. 534.
- Woo VL, Angiero F, Fantasia JE. Myoepithelioma of the tongue. *Oral Surg Oral Med Oral Pathol Oral Radiol Endod.* 2005; 99(5):581–9.

## Миоепителиом пода уста

Винисијус Рио Верде Мело Муниз, Паулине Магаљаис Кардозо, Рафаел Фернандес де Алмеида Нери, Леонардо де Араужо Мело, Браулио Карнеиро Жуниор, Жан Нунес дос Сантос

Државни универзитет Баије, Стоматолошки факултет, Салвадор, Баија, Бразил

### САЖЕТАК

**Увод** Миоепителиоми се првенствено налазе на паротидној жлезди, обично као безболни израштај са спорим растом. Циљ овог рада је да опише случај миоепителиома у поду уста.

**Приказ болесника** Младић је приметио безболну отеклину на левој страни пода уста, са једногодишњом еволуцијом у сесилан тумор, нормално пребојен, без секреције. Компјутеризована томографија са контрастом приказала је добро ограничену промену мале хетерогене густине. Биопсија је урађена у локалној анестезији, а хистопатолошки преглед указао је на миоепителну неоплазму. Промена је у целости

одстрањена у општој анестезији, а патохистолошки налаз потврдио дијагнозу миоепителиома пљувачне жлезде. Болесник је праћен годину дана и није испољио знаке рецидива болести.

**Закључак** Миоепителиоми пљувачних жлезда су ретки, посебно у поду уста, али овај тумор треба размотрити у диференцијалној дијагнози сличних лезија. Неопходна је потпуна хируршка ексцизија, а време постоперативног праћења би требало да је што је могуће дуже иако су рецидиви изузетно ретки.

**Кључне речи:** пљувачна жлезда; орална патологија; миоепителиом